

Intra-thyroid blood flow in Plummer's disease.

メタデータ	言語: eng 出版者: 公開日: 2017-10-03 キーワード (Ja): キーワード (En): 作成者: メールアドレス: 所属:
URL	http://hdl.handle.net/2297/11571

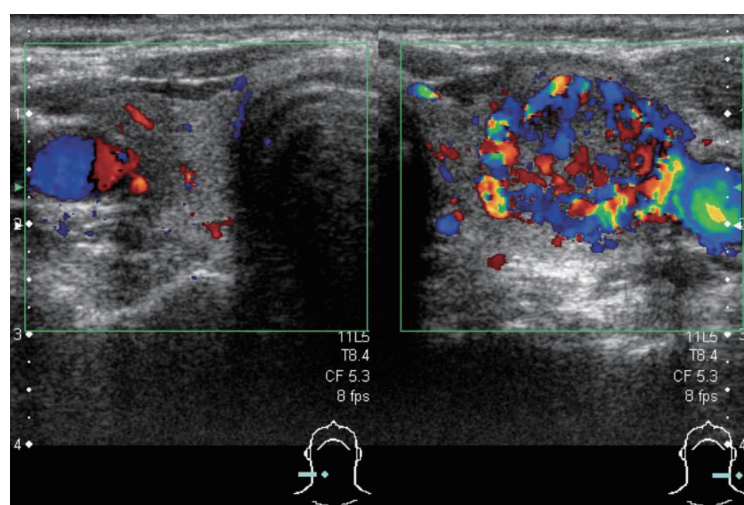
Intra-thyroid Blood Flow in Plummer's Disease

Seiichiro Kurita, Hitoshi Ando, Shuichi Kaneko and Toshinari Takamura

Key words: Plummer's disease, thyrotoxicosis, thyroid, toxic adenoma, thyroidectomy, color Doppler ultrasonography

(Inter Med 47: 1-20, 2008)

(DOI: 10.2169/internalmedicine.47.1091)



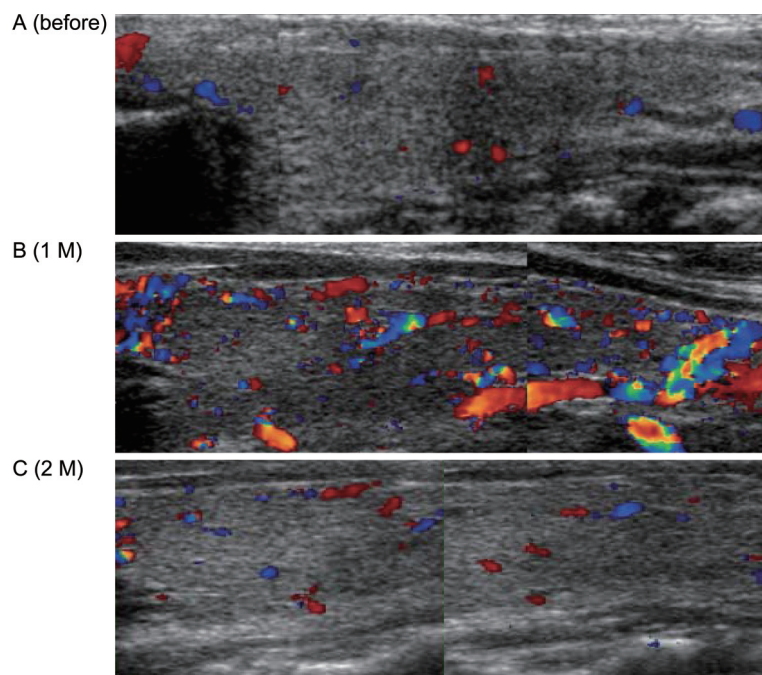
Picture 1. Color Doppler ultrasonography of the left thyroid lobe (tumor side) before the partial thyroidectomy. The thyroid blood flow area in the tumor increased to 75.0% whereas that in the non-tumor region was 9.1%.

A 58-year-old woman developed thyrotoxicosis (serum FT_3 7.10 pg/mL, normal 2.20-4.30; FT_4 2.24 ng/dL, normal 0.80-1.80; TSH 0.01 μ U/mL, normal 0.27-4.67) without an increased level of serum thyroid stimulating antibody (138%, normal <180%). Ultrasonography detected a tumor (4.8×2.5×1.5 cm) in the left thyroid lobe. The thyroid blood flow area (TBFA) was evaluated using color Doppler ultrasonography because the TBFA is useful in the etiologic diagnosis of thyrotoxicosis (1-3). The TBFA in the tumor was increased to 75.0% (Picture 1). Ultimately, she was diagnosed with Plummer's disease based on a hot nodule on ^{131}I thyroid uptake and underwent a partial thyroidectomy.

One month postoperatively, she developed hypothyroidism (FT_3 2.14 pg/mL, FT_4 0.56 ng/dL, TSH 11.36 μ U/mL). Interestingly, the TBFA in the right thyroid lobe (non-tumor side) had increased dramatically from 7.2% (Picture 2A) to 33.4% (Picture 2B), which is equivalent to the level in a pa-

tient with Graves' disease (1). Two months postoperatively, the thyroid hormones (FT_3 2.81 pg/mL, FT_4 0.83 ng/dL, TSH 4.51 μ U/mL) and TBFA (6.6%; Picture 2C) had recovered to the normal ranges without any treatment. These time courses for the thyroid hormones and TBFA are similar to those during the recovery stage of subacute thyroiditis, although the range of fluctuation is narrow in subacute thyroiditis (2). The significance of the compensatory increase in the intra-thyroid blood flow during the recovery phase after removal of a toxic adenoma may be important in the homeostasis of thyroid hormone production.

Inter Med 47: 1-20, 2008 DOI: 10.2169/internalmedicine.47.1091



Picture 2. Time course of the thyroid blood flow area in the right thyroid lobe (non-tumor side) on color Doppler ultrasonography: (A) before the partial thyroidectomy; (B) 1 month postoperatively; and (C) 2 months postoperatively.

References

1. Kurita S, Sakurai M, Kita Y, et al. Measurement of thyroid blood flow area is useful for diagnosing the cause of thyrotoxicosis. *Thyroid* **15**: 1249-1252, 2005.
2. Hiromatsu Y, Ishibashi M, Miyake I, et al. Color Doppler ultrasonography in patients with subacute thyroiditis. *Thyroid* **9**: 1189-1193, 1999.
3. Erdoğan MF, Anil C, Cesur M, Başkal N, Erdoğan G. Color flow Doppler sonography for the etiologic diagnosis of hyperthyroidism. *Thyroid* **17**: 223-228, 2007.