

Neuro-Sweet disease mimicking recurrent anaplastic astrocytoma associated with therapy-related myelodysplastic syndrome: A case report

メタデータ	言語: eng
	出版者:
	公開日: 2017-10-03
	キーワード (Ja):
	キーワード (En):
	作成者:
	メールアドレス:
	所属:
URL	https://doi.org/10.24517/00013679

This work is licensed under a Creative Commons Attribution-NonCommercial-ShareAlike 3.0 International License.



Neuro-Sweet disease mimicking recurrent anaplastic astrocytoma associated with therapy-related myelodysplastic syndrome: A case report

Introduction

Sweet's syndrome (SS), an acute febrile neutrophilic dermatosis, is characterized by fever, neutrophilia, tender erythematous skin lesions (papules, nodules, and plaques), and a diffuse infiltrate predominantly composed of mature neutrophils. Neuro-Sweet disease (NSD) is an extracutaneous manifestation of SS [1]. SS can also present as a paraneoplastic syndrome, which is a malignancy-associated form of the condition that is most commonly related to acute myelogenous leukemia (AML) or myelodysplastic syndrome (MDS).

Therapy-related myelodysplastic syndrome (t-MDS) is rare but one of the most lethal complications of alkylating agents such as temozolomide (TMZ) and ACNU [2], which are widely used for adjuvant chemotherapy with or without radiotherapy for malignant glioma. In this study, we provide the first report of NSD mimicking the recurrence of anaplastic astrocytoma (AA), which was accompanied by t-MDS, after standard chemoradiotherapy for AA.

Case report

First presentation

In July 2004, a previously healthy 52-year-old man presented with focal seizure. Magnetic resonance (MR⁺) imaging of the brain showed a lesion in the

right frontal lobe (Fig. 1A). A gross total resection was performed, and the pathology was found to be consistent with AA. Postoperative regional radiotherapy with 40 Gy was administered over 4 weeks, followed by 15 cycles of chemotherapy with ACNU at an initial dose of 80 mg and an extended dose of 138 mg from the ninth to the fifteenth course. In August 2007, however, chemotherapy was discontinued because of leukocytopenia. Despite the administration of granulocyte colony-stimulating factor (G-CSF), his hematologic findings did not normalize. In January 2008, bone marrow aspiration and biopsy were performed, which showed a hypocellular marrow with moderate fibrosis and dysplasia. There was no increase in the bone marrow blasts, which constituted <5% of the nucleated cells. These findings were found to be consistent with t-MDS according to the WHO classification. Despite ACNU withdrawal, AA did not recur (Fig. 1B).

Second presentation

In June 2010, he was admitted to our hospital because of painful erythema on the extremities and intractable focal seizure of the left hand. On admission, his skin lesions were purple-red, nonpruritic, and tender and measured 1–2 cm in diameter (Fig. 2A). MR imaging showed hyperintensity on FLAIR at the periphery of the resected cavity. The margin of the tumor resection cavity was enhanced by contrast medium (Fig. 1C). At the time, we suspected the recurrence of AA. However, an intractable fever over 38.5°C, which was resistant

to antibiotics, appeared. Hematological examination showed a white blood cell count of $1.63 \times 10^9/L$ (of which, $0.87 \times 10^9/L$ were neutrophils); however, erythrocyte sedimentation rate (ESR), and C-reactive protein (CRP) were within normal limits. Skin biopsy showed deep dermal infiltration of mature neutrophils, spared epidermis, and absence of vasculitis, strongly suggesting SS (Fig. 2B). On the seventh hospital day, treatment with oral prednisolone (20 mg/day x 5 days) was initiated, and the fever was rapidly alleviated. However, on the 13th hospital day, a fever of over 39°C recurred. Furthermore, consciousness disturbance, focal seizure, left hemiparesis, and neck stiffness appeared. MR imaging showed enlargement of the FLAIR hyperintensity surrounding the cavity (Fig. 1D). Cerebrospinal fluid (CSF) analysis showed 3720 cells/ μL (of which, 36% were neutrophils), 262 mg/dL protein, 47 mg/dL glucose; moreover, CSF cultures were negative in 2 samples tested separately. Because fever and neurological symptoms did not improve for 2 days despite an intensive carbapenem antibiotic treatment (6 g/day), we suspected that his meningitis must have been caused by NSD. On the 16th hospital day, he was treated with intravenous methylprednisolone (1 g/day for 3 days), followed by oral prednisolone treatment (50 mg/day). Thereafter, his clinical symptoms and abnormal MR findings improved (Fig. 1E), indicating a dramatic response to steroid pulse therapy.

Discussion

Various neurological manifestations of NSD have been reported, such as benign encephalitis, aseptic meningitis, polyneuropathy, and psychiatric symptoms [1]. Clinical diagnostic criteria for NSD were proposed by Hisanaga et al. in 2005. The 3 main features of NSD patients have been described. First, NSD patients have neurological features that are highly responsive to systemic glucocorticoid treatment; however, they frequently experience recurrent encephalitis or meningitis, which are usually accompanied with fever of over 38°C. The second feature is dermatologic, in that the patients develop painful or tender, dull red erythematous plaques or nodules with predominantly neutrophilic infiltration of the dermis and spared epidermis without leukocytoclastic vasculitis. The third feature is the absence of cutaneous vasculitis, thrombosis, and typical uveitis, which are seen in Behçet's disease [3]. Because our patient exhibited all the 3 features, he was diagnosed as having NSD. However, HLA-B54, which is associated with SS [3], was not detected in our patient, suggesting that the pathogenic mechanism of NSD in our patient might be unusual.

SS presents in 3 clinical settings: classical (or idiopathic), malignancy-associated, and drug-induced. Twenty-one percent of patients with SS either have a solid tumor or a hematologic malignancy, as that observed in our patient [1]. Malignancy-associated SS is most commonly related to hematologic malignancy, especially AML and MDS [4]. The nature of the relationship between these dermatoses and the underlying hematologic malignancy is unknown. However, it is known that the infiltrate is mostly

composed of mature neutrophils even when the patient's blood or bone marrow contains few mature neutrophils, as observed in the present case [4]. This finding had lead many authors to conclude that neutrophilic infiltrates in the skin of these patients are “nonspecific” inflammatory processes [4].

In the pre-TMZ era, nitrosoureas constituted the primary alkylator-based chemotherapy for the treatment of malignant gliomas. t-MDS/AML have been described as life-threatening complications following therapy of primary brain tumors with classic alkylating agents such as nitrosoureas or procarbazine, RT alone, or combined chemotherapy and RT [2]. Therapy-related myeloid neoplasms account for approximately 20% of all cases of myeloproliferative neoplasms. The incidence among patients treated with cytotoxic agents varies according to the underlying disease, specific agents, time of exposure, and dose.

The pathogenesis of SS is unknown. It is currently thought that cytokine dysregulation accounts for most of the clinical, pathological, and laboratory changes seen in SS; the cytokines include interleukin (IL)-1, IL-3, IL-6, IL-8, G-CSF, and interferon γ [1]. Vergara et al. reported that previously irradiated skin may behave as a *locus minoris resistentiae* (a place of less resistance) that favors the localization of SS lesions [5]. Not only irradiation but also epidermal damage caused by mechanical, surgical, chemical, or solar stimuli can directly promote cutaneous lesions or result in a common etiology such as injury to the dermal connective tissue, which subsequently contributes to the development of skin lesions [1]. However, development of NSD in the irradiated brain after glioma

resection has not yet been reported. Interestingly, a hyperintensity lesion on FLAIR was observed only within the irradiated field (Fig. 1D). Expression of various immunoregulatory molecules such as IL-1, IL-6, TNF- α , and NF- κ B are affected due to delayed responses as a result of brain irradiation. These findings lead us to speculate that brain irradiation after surgical resection increases the risk of NSD development.

Conclusion

It was difficult to distinguish NSD from AA until the brain lesions dramatically disappeared after glucocorticoid administration. In this case, t-MDS, a lethal complication of alkylating agent chemotherapy, played an important role in NSD pathogenesis; moreover, brain irradiation may influence the location of NSD development. Thus, this case presents a wealth of information on glioma therapy-related complications.

References

1. Cohen PR. Sweet's syndrome - a comprehensive review of an acute febrile neutrophilic dermatosis. *Orphanet J Rare Dis* 2007;2:34.
2. Noronha V, Berliner N, Ballen KK, Lacy J, Kracher J, Baehring J, Henson JW. Treatment-related myelodysplasia/AML in a patient with a history of breast cancer and an oligodendroglioma treated with temozolomide: case study and review of the literature. *Neuro Oncol* 2006;8:280-283.
3. Hisanaga K, Iwasaki Y, Itoyama Y. Neuro-Sweet disease: clinical manifestations and criteria for diagnosis. *Neurology* 2005;64:1756-1761.
4. Tomasini C, Aloï F, Osella-Abate S, Dapavo P, Pippione M. Immature myeloid precursors in chronic neutrophilic dermatosis associated with myelodysplastic syndrome. *Am J Dermatopathol* 2000;22:429-433.
5. Vergara G, Vargas-Machuca I, Pastor MA, Farina MC, Martin L, Requena L. Localization of Sweet's syndrome in radiation-induced locus minoris resistentiae. *J Am Acad Dermatol* 2003;49:907-909.

Legend

Figure 1

Gadolinium-enhanced axial T1 weighted images (upper panel) and axial FLAIR images (lower panel) are shown. In 2004 July, heterogeneous enhanced lesion in right frontal lobe was detected (A). Gross total resection was achieved (B), followed by regional radiotherapy and ACNU-based chemotherapy. Histological examination revealed AA. In 2010 June, the margin of the tumor resection cavity became enhanced by contrast medium and FLAIR hyper-intensity lesion was detected (C). After two weeks, FLAIR hyper-intensity lesion markedly expanded during neurological deterioration (D). White square indicates the range formerly irradiated. Note that FLAIR hyper-intensity lesion was not seen outside of irradiated field. After the treatment with glucocorticoid, MR findings were improved dramatically (E).

Figure 2

Cutaneous lesion of lower leg (dorsal). Erythematous eruption was observed (A). Hematoxylin-Eosin staining of cutaneous lesion showed dense infiltration of neutrophils in the dermis without vasculitis (B).

***Highlights**

Highlight

- (1) We report a case of neuro-Sweet disease (NSD) mimicking the recurrence of anaplastic astrocytoma (AA), which was accompanied by therapy-related myelodysplastic syndrome (t-MDS) after ACNU-based chemo-radiotherapy AA.
- (2) It was difficult to distinguish NSD from AA until the brain lesions dramatically disappeared after glucocorticoid administration. In this case, t-MDS, a lethal complication of alkylating agent chemotherapy, played an important role in NSD pathogenesis. Moreover, brain irradiation may influence the location of NSD development.

Figure(s)

Figure 1

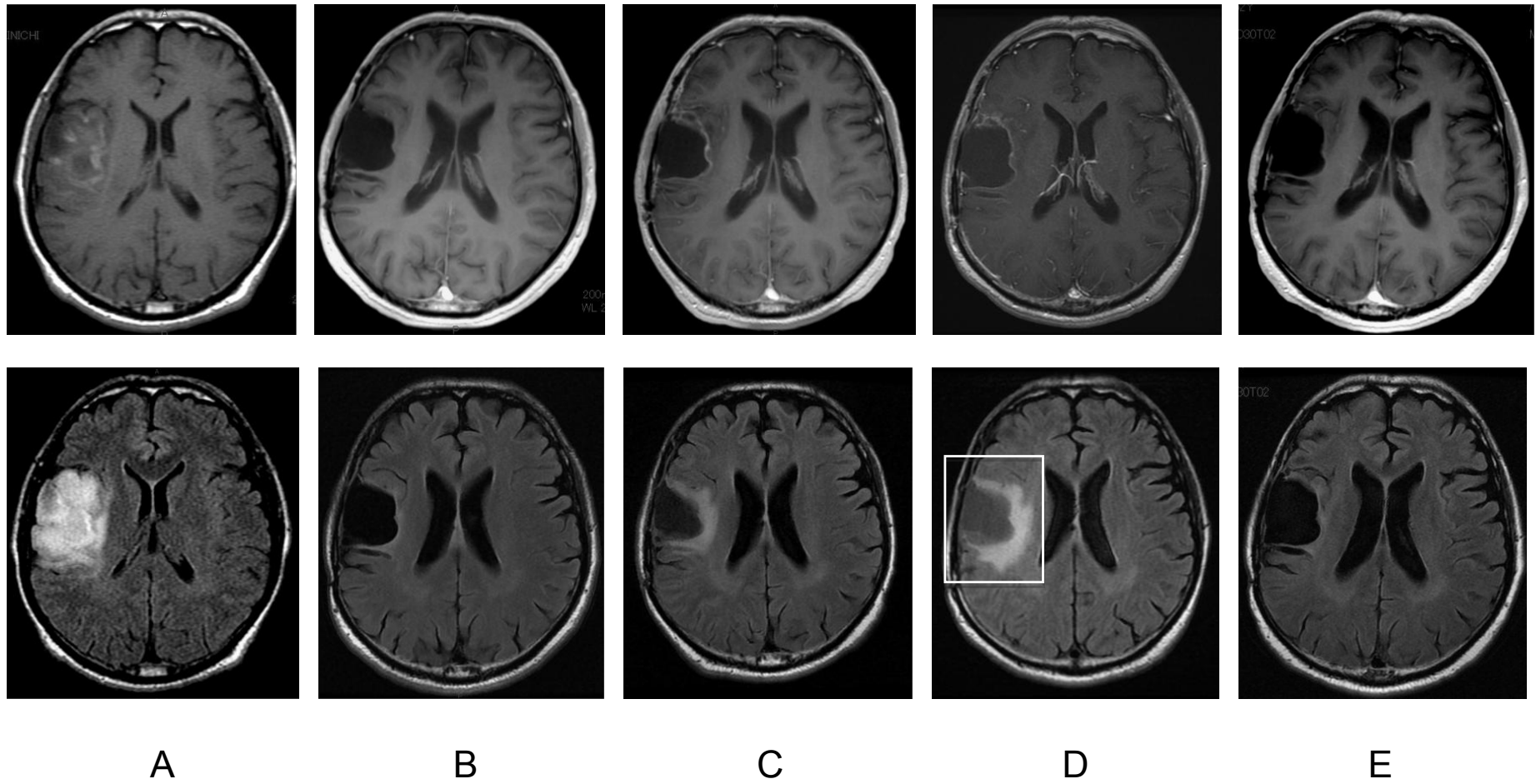
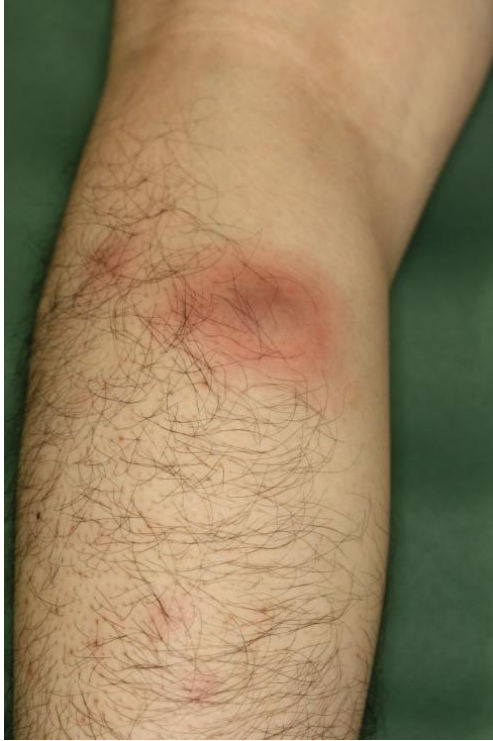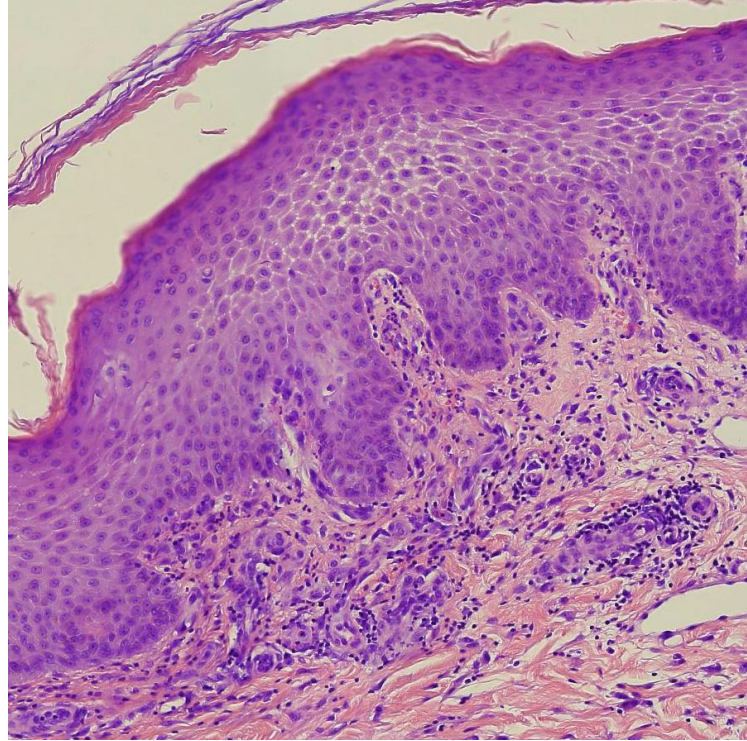


Figure 2



A



B