

# Medial blepharosynechioplasty: A new surgical concept for severe dry eye

|       |   |
|-------|---|
| メタデータ | 言語: eng<br>出版者:<br>公開日: 2017-10-03<br>キーワード (Ja):<br>キーワード (En):<br>作成者:<br>メールアドレス:<br>所属: |
| URL   | <a href="http://hdl.handle.net/2297/32002">http://hdl.handle.net/2297/32002</a>             |

## Medial blepharosynechioplasty: a new surgical concept for severe dry eye

Tsugihisa Sasaki<sup>123</sup> M.D., Ph.D., Taeko Ota<sup>4</sup> M.D., Youko Ookura<sup>5</sup> M.D.

Kazuhisa Sugiyama<sup>2</sup> M.D., Ph.D.

<sup>1</sup>Sasaki Eye Clinic, Mikuni, Fukui, 913-0016, Japan.

<sup>2</sup>Department of Ophthalmology, Kanazawa University School of Medicine, Kanazawa, Ishikawa, 920-8610, Japan.

<sup>3</sup>Department of Ophthalmology, Fukui Prefectural Hospital, Fukui, 910-0846, Japan.

<sup>4</sup>Department of Ophthalmology, Tonami General Hospital, Tonami-city, Toyama, 939-1395, Japan.

<sup>5</sup>Department of Ophthalmology, Saiseikai Kanazawa Hospital, Kanazawa, Ishikawa, 920-0353, Japan.

Send all correspondence to: Tsugihisa Sasaki, Sasaki Eye Clinic, 5-2-6 Mikuni-higashi, Mikuni, Sakai, 913-0016, Japan.

TEL: +81-776-88-0033

FAX: +81-776-88-0233

e-mail: [sasatsug@gmail.com](mailto:sasatsug@gmail.com)

The authors did not receive financial or material support from the manufacturer of any commercial product discussed in this paper.

Key words: dry eye, lacrimal pump suppression, medial blepharosynechioplasty

## **Abstract**

**Purpose:** To report on the performance of medial blepharosynechioplasty (MBSP), a newly devised technique for treating severe dry eye.

**Design:** Retrospective, non-randomized clinical trial.

**Methods:** Three cases with severe dry eye (Sjögren's syndrome) associated with repeated punctal plug loss were treated by MBSP to create a synechia between the upper and lower lid medial borders of the puncta to suppress the lacrimal pump.

**Results:** Postoperative follow-up showed improvement in corneal conditions for all three cases that persisted for 12 to 35 months. None of the patients had visual impairment.

**Conclusion:** MBSP is a promising treatment for severe dry eye and merits further study.

## Introduction

Although punctal plug and occlusion of the lacrimal puncta is an established treatment for dry eyes<sup>1-3</sup>, the risk of complications including epiphora, intrusion or extrusion of punctal plugs, canalicular stenosis<sup>1,4</sup> and insufficient results in case of mono-punctal closure, have annoyed surgeons to perform surgery involving permanent closure of the puncta. Development of alternative surgical methods to suppress the lacrimal pump and tear evaporation with fewer complications could represent a valuable advance to produce the milder effect than upper and lower punctal plugging.

We encountered three patients after dacryocystorhinostomy (DCR), who developed blepharosynechia (BS) bordering the punctum characterized by epiphora, although the lacrimal ducts remained patent. Epiphora improved after excision of their BS. These observations suggested that BS-induced epiphora was caused by suppression of the lacrimal pump, which in turn led to us devising medial blepharosynechioplasty (MBSP) as a novel treatment for dry eyes.

## Methods

The study protocol and data collection methods were approved by the Institutional Review Board of Fukui Prefectural Hospital. This study reports on three patients suffering from repeated punctal plug loss.

Surgical procedure: the infratrochlear nerve was anesthetized with an injection of a mixture of 0.01% epinephrine and 2% lidocaine. Two strips of tissue from the

palpebral conjunctiva, each measuring 2 x 3 x 0.5 mm, were excised from the medial side of the upper and lower puncta to facilitate formation of a synechia (Fig. 1). Eyelid tissues in the immediate vicinity of the puncta were sewn together with 7-0 nylon in conjunction with insertion of a lacrimal probe into the canaliculus to prevent damage to it. Antibiotic ophthalmic drops and 0.1% fluorometholone were applied postoperatively for 2-4 weeks. The area of the uncovered ocular surface was calculated with NAVIS (Nidek, Japan) and Photoshop CS (Adobe systems, USA) software from slit lamp images of the patients.

#### Cases:

**Patient 1.** A 73-year-old woman had a 20-year history of Sjögren's syndrome (SS) and keratoconjunctivitis sicca (KCS). The Schirmer test (ST) was 0 mm in each eye pre-operatively. Slit-lamp examination revealed a bilateral shortened tear film break-up time (2 sec, R=L) and moderate superficial punctate keratoconjunctivitis (SPK). She underwent MBSP in her left eye. Post-operative ST was still 0 mm in both eyes. Slit lamp examination showed improvement of SPK in the left eye and an increase in tear meniscus height from 0.1 mm to 0.2 mm (Fig. 2). The area of the uncovered ocular surface was reduced 78.3% postoperatively from the preoperative value. Postoperative follow-up for 35 months showed no recurrence of severe SPK.

**Patient 2.** A 79-year-old woman had a long history of SS, dry eye and bilateral persistent filamentary keratopathy (FK) (Fig. 2). ST was 0 mm in both eyes. She underwent MBSP in her left eye. After the operation, FK improved dramatically

(Fig. 2). These improvements persisted postoperatively for 30 months.

Patient 3. A 76-year-old woman had a long history of SS and chronic dacryocystitis on the left side. Dacryocystitis was treated with DCR. She subsequently showed severe SPK in each eye at which time ST was 1 mm in each eye. She underwent MBSP in her right eye 1 year after her DCR (Fig. 2). Her SPK improved. Postoperative ST was 5 mm in the right eye and 2 mm in the left eye. FK improvement was observed at her 12 month postoperative follow-up visit.

In all cases, the lacrimal ducts remained patent with no visual impairment and no punctal displacement.

## Discussion

MBSP increased the quantity of tear fluid in the treated eyes. Punctal plug, punctal closure and punctal tarsorrhaphy are surgical treatments for severe dry eye.<sup>3</sup> MBSP resembles punctal tarsorrhaphy, but there is a difference in the patency of the lacrimal passage in MBSP. Conventional punctal tarsorrhaphy was devised for a complete blockage of lacrimal drainage. However, MBSP aims to partially reverse the pump mechanism. The mechanism of action for MBSP is obscure. We hypothesize that MBSP blocks the movement of the puncta and canaliculi during blinking and reduces evaporation of tears from the ocular surface through the mini-tarsorrhaphy. However, reducing evaporation is not thought to cause a major effect, because MBSP improved the corneal condition even in the uncovered area of the cornea. Moreover, tarsorrhaphy-induced ocular coverage reduced tear evaporation by 22% in case 1. It has also been postulated

that apposition of the puncta during blinking is an important component of the valve mechanism in the lacrimal pump.<sup>5</sup> By creating a misalignment of the puncta during blinking, MBSP may interfere with this valve mechanism.

Periorbital injection of botulinum toxin has been reported to improve dry eye<sup>6,7</sup> by mechanisms involving paralysis of the orbicularis oculi muscle around the canaliculi. MBSP may operate by a mechanism similar to that of botulinum toxin injection. Treatments involving pump suppression may well become a treatment of choice in the future. Further studies, including a clinical trial of MBSP utilizing a control group, remain necessary.

1) Willis RM, Folberg R, Krachmer JH, Holland EJ. The treatment of aqueous-deficient dry eye with removable punctal plugs. A clinical and impression-cytologic study. *Ophthalmology*. 1987; May;94(5):514-518.

2) Kaido M, Goto E, Dogru M, Tsubota K. Punctal occlusion in the management of chronic Stevens-Johnson syndrome. *Ophthalmology*. 2004; 111(5): 895-900.

3) Murube J, Murube E. Treatment of dry eye by blocking the lacrimal canaliculi. *Surv Ophthalmol*, 1996;40(6):463-80.

4) Balaram M, Schaumberg DA, Dana MR. Efficacy and tolerability outcomes after punctal occlusion with silicone plugs in dry eye syndrome.



Am J Ophthalmol. 2001; 131(1): 30-36.

5) Doane MG. Blinking and the mechanics of the lacrimal drainage system. Ophthalmology. 1981; 88(8): 844-851.

6) Spiera H, Asbell PA, Simpson DM. Botulinum toxin increases tearing in patients with Sjögren's syndrome: a preliminary report. J Rheumatol. 1997; 24(9): 1842-1843.

7) Sahlin S, Chen E, Kaugesaar T, Almqvist H, Kjellberg K, Lennerstrand G. Effect of eyelid botulinum toxin injection on lacrimal drainage. Am J Ophthalmol. 2000; 129(4): 481-486.

## Legends

### Figure 1

Schematic view of medial blepharosynechioplasty (MBSP) in the right eye.

**a** Excision of two strips of palpebral conjunctiva, each measuring 2 x 3 x 0.5 mm (width x length x thickness), from the medial side of the upper and lower puncta to facilitate formation of a synechia.

**b** The incised eyelids were sewn together in the immediate vicinity of the puncta with 7-0 nylon in conjunction with insertion of a lacrimal probe into the canaliculus

to prevent damage to it.

**c** Enlarged view near the lacrimal puncta after MBSP.

## Figure 2

Pre- and post-operative photographs of cases 1-3.

**a** Pre-operative photo of fluorescent dye-stained ocular surface in case 1. White spots imply superficial punctate keratitis.

**b** Post-operative photo of fluorescent dye-stained ocular surface in case 1. Superficial punctate keratitis improved.

**c** Pre-operative photo of same patient of figure 2a.

**d** Post-operative photo of same patient of figure 2b. Tear meniscus height elevation (white arrow head) in case 1 is identified. Synechia near the puncta are identified (arrow).

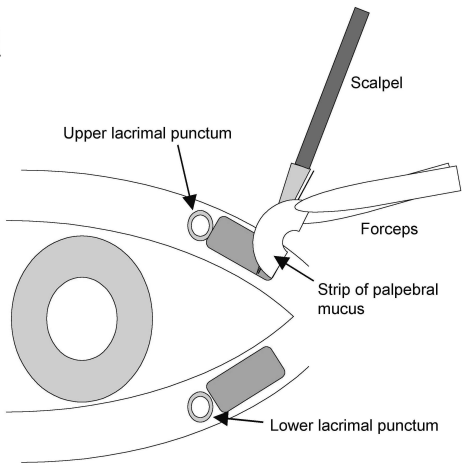
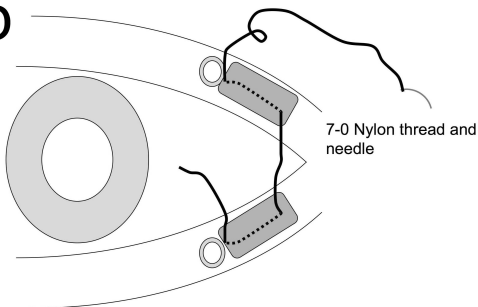
**e** Pre-operative photo in case 2. Severe dry eye is observed.

**f** In case 2, improvements in corneal condition and blepharo-synechia (black arrow head) are observed following MBSP. Synechia near the puncta (arrow) are still open.

**g** Pre-operative photo in case 3. Corneal filamentosa is observed.

**h** In case 3, improvements in corneal filamentosa and blepharo-synechia (black arrow head) are observed postoperatively. The puncta (arrows) near synechia are still open.



**a****b****c**

Upper canaliculus

Upper lacrimal punctum

Lower lacrimal punctum

Lower canaliculus

Blepharosynechia

