The Effect of Susceptibility of Gadolinium Contrast Media on Diffusion-weighted Imaging and the Apparent Diffusion Coefficient

The effect of susceptibility of Gadolinium contrast media on diffusion weighted image and the apparent diffusion coefficient

Akio Ogura, MS [1,2)]
Katsumi Hayakawa, MD [1)]
Tosiaki Miyati, PhD[2)]
Fumie Maeda, RT [1)]

1) Department of Radiology, Kyoto city hospital
2) Graduate School of Medical Science, Kanazawa University

Corresponding author's contact information:
Akio Ogura
Department Radiology, Kyoto City Hospital
1- 2, takada-cho, Mibu-higashi, nakagyo-ku, Kyoto, JAPAN
TEL: +8175-311-5311(2183)
E-mail address: a-ogura@mbox.kyoto-inet.or.jp

Running Title: The effect of Gd-contrast media on DWI

The Abbreviated Title Page

The effect of susceptibility of Gadolinium contrast media on diffusion weighted image and the apparent diffusion coefficient

Abstract

Purpose: The development of parallel MRI has resulted in the frequent use of diffusion-weighted imaging (DWI) in clinical medicine, and it usually involves the use of contrast medium. However, the gadolinium (Gd) contrast medium may have some effect on DWI and the apparent diffusion coefficient (ADC). The present study was performed to determine whether the magnetic susceptibility of contrast medium alters the DWI signal and the value of ADC in some imaging techniques.

Materials and Methods: Non-fat suppression DWI, STIR combination and CHESS combination DWI were performed to examine 10 phantoms with Gd-DTPA dissolved at concentrations from 0.0005 to 0.1 mmol in physiological saline as contrast medium. The average pixel value and ADC of each method were determined.

Results: ADC showed no differences between before and after treatment with contrast medium for all imaging techniques with Gd considered to be distributed over the whole tumour. The signal intensity did not change on non-fat suppression or CHESS combination DWI but deteriorated on STIR. Therefore, ADC was not influenced by the magnetic susceptibility of contrast medium. In addition, it was suggested that the ability of tumour detection may be reduced if STIR is used as fat suppression.

Key words: Diffusion-weighted image, susceptibility, Gadolinium contrast medium, Apparent diffusion coefficient

Introduction

Diffusion-weighted imaging (DWI) has contributed to diagnosis as a new compliment to MRI. In particular, it has become the most important imaging technique in the diagnosis of acute stroke. With the recent development of parallel MRI, DWI has often been used in clinical medicine to both search for tumours and for discrimination diagnosis (1–13).

However, the application of DWI in routine clinical examinations has not been established. Therefore, DWI is often performed after use of contrast medium. Therefore, there is concern regarding whether gadolinium (Gd) contrast medium influences the DWI signal and the value of the apparent diffusion coefficient (ADC).

There are two major concerns regarding the possible effects of Gd contrast medium on DWI and ADC.

1. Effects on ADC due to the shrinkage of blood vessels and changes in blood viscosity by contrast medium.
2. Effects on DWI and ADC due to the magnetic susceptibility of the contrast medium.

There have been a number of reports regarding the effects on ADC due to the shrinkage of blood vessels and changes in blood viscosity caused by contrast medium (14–17). However, these studies in both mice and humans examined the effects on ADC of blood vessel shrinkage and changes in blood viscosity due to contrast medium as well as those caused by magnetic susceptibility of contrast medium together. In the present study,

we treated these effects separately.

The present study was performed to determine whether the magnetic susceptibility of contrast medium alters the signal of DWI and the value of ADC.

Materials and Methods

A 1.5T superconducting scanner unit (Magnetom Symphony; Siemens, Erlangen, Germany) with high-sensitivity quadrature-coils was used. The study design and review of patient records and images were approved by our institutional review board.

First, we examined the amount of contrast medium distributed over the tumour following administration at a concentration of 0.1 mmol/kg body weight in human subjects by comparing the signal intensity after with that before contrast enhancement. We compared pixel values of the ROI in the tumour mass with T1 weighted (TR650 ms,TE17 ms) images before and after contrast enhancement in 20 meningiomas and 20 brain metastatic lesions which were homogeneous and high-enhancement. In addition, each signal value was measured in fifteen phantoms obtained with Gd contrast medium with the concentration increased to 0.01 mmol from in physiological saline using the above scanning factor.

The quantities of Gd distribution in brain tumours before and after contrast enhancement were estimated from the relation between the Gd contrast medium content and signal value.

Next, to review the effects of Gd contrast medium on DWI, ten phantoms were subjected to non-fat suppression DWI, STIR combination

DWI and CHESS combination DWI in b=0, 500, 1000 x 10^{-3} s/mm^2 in motion-probing gradient (MPG). The ten phantoms with Gd-DTPA at concentrations from 0.0005 to 0.1 mmol in physiological saline were supported in a water tank. The scanning parameters were EPI (TR1000 ms, TE50 ms, slice thickness 5 mm, 128×128 matrix). The arrangement position of phantoms was changed twice to avoid position-dependent artefacts and image non-uniformity. In addition, these images were scanned four times at each position. T1-weighted images and DWI of these phantoms are shown in Fig. 1. The average pixel values of each phantom of b=1000 x 10^{-3} s/mm^2 of ten images were measured. In addition, ADC was calculated for three points: b=0, 500, 1000 x 10^{-3} s/mm^2.

Results

In meningioma and metastatic tumours in the brain, the quantity of distribution of Gd contrast medium was estimated based on the increases in pixel values after contrast enhancement. The quantitative Gd distributions before and after contrast enhancement of 20 meningiomas and 20 metastatic brain tumours are shown in Fig. 2. Based on the results in 40 tumours shown in Fig. 2, the quantity of Gd contrast medium distributed in tumours was estimated with contrast medium at concentrations ranging from 0.001–0.005 mmol.

The ten phantom images with contrast medium consisting of Gd in physiological saline at concentrations of 0.0005–0.1 mmol were subjected to DWI non-fat suppression, STIR combination DWI and CHESS combination DWI in b=1000 x 10^{-3} s/mm^2 in MPG. The pixel values of

phantom images are shown in Fig. 3. Both non-fat suppression DWI and CHESS combination DWI showed similar signal intensities for Gd density. In addition, no changes were observed in signal value up to a Gd concentration of 0.005 mmol, but tended to decrease at concentrations above this level. The signal value was generally lower for STIR combination DWI than for other imaging techniques and decreased with increases in Gd concentration. The contrast medium density distribution in the tumour is surrounded with a solid line on this graph. For non-fat suppression DWI and CHESS combination DWI, only tumours in which the contrast effect was very high showed a decrease in the DWI signal in the tumour. However, no drop in signal was seen in tumours with a general contrast effect. However, in STIR combination DWI, a drop in the signal was observed when scanning was performed after contrast enhancement. The values of ADC calculated with MPG from b=0, 500, 1000 x 10^{-3} s/mm^2 in the three imaging techniques—non-fat suppression DWI, STIR-DWI and CHESS-DWI—using ten phantoms with Gd dissolved in physiological saline at concentrations of 0.0005–0.1 mmol are shown in Fig. 4. No changes in ADC were observed in non-fat suppression DWI or CHESS combination DWI up to a Gd density of 0.05 mmol, but ADC tended to decrease at Gd densities above this level. In addition, in STIR combination DWI, no changes in ADC were seen up to 0.008 mmol Gd, but the value tended to decrease above this density. The distribution of contrast medium level in the tumour described above is surrounded with a solid line in Fig. 4. In all imaging techniques, no changes in ADC were seen with contrast medium distributed in the tumour.

Discussion

The present study was performed to determine whether the magnetic susceptibility of contrast medium alters the body-DWI signal and the value of ADC in various imaging techniques

We used phantoms of different Gd density and performed analyses with three imaging sequences: non-fat suppression DWI, STIR combination DWI and CHESS combination DWI.

Non-fat suppression DWI and CHESS combination DWI showed similar signal intensity curves for Gd density (Fig. 3). In addition, signal values of DWI did not change until a Gd density 0.005 mmol, but showed a tendency to decrease at densities above this level. This was regarded as an effect of magnetic susceptibility of the Gd contrast medium. The effect of susceptibility is dependent on the imaging parameters used. Therefore, in this study, no signal changes were observed up to a Gd density of 0.005 mmol, but signal intensity may change at other Gd densities or with the use of other devices and/or parameters.

It was suggested that the signal intensity of DWI would not change after contrast enhancement if optimal parameters were selected. Therefore, the detectability would not alter the tumour search ability after contrast enhancement if CHESS is used as the fat suppression method. However, for STIR combination DWI, the signal value dropped with increases in Gd density and was lower than in the other imaging techniques. This was regarded as due to the influence of T1 relaxation and low SNR caused by the use of STIR. Therefore, it was suggested that tumour detection is

decreased if STIR is used for fat suppression. Images using CHESS-DWI before and after contrast enhancement of meningioma on the brain are shown in Fig. 5. Signal intensity did not change after contrast enhancement. Images obtained using STIR-DWI before and after contrast enhancement on a brain tumour are shown in Fig. 6. A marked reduction in the signal was observed in the image after as compared with that before contrast enhancement.

When ADC was used for tumour discrimination, it was not influenced by contrast medium density distributed over the tumour in any of the imaging techniques used in the present study (Fig. 4). Therefore, the ADC calculation was revised to ensure an equal effect of susceptibility for each b value of MPG.

However, this experiment reviewed the influence only with regard to susceptibility of the contrast medium using a phantom. In references 14–16, it was reported that the ADC of tumour was reduced by increasing the concentration of contrast medium. Thus, blood vessel shrinkage by contrast medium and changes in blood viscosity were considered to affect ADC. However, it has been reported that contrast medium had no influence on ADC in mice (17). Therefore, further detailed studies including calculation of the precision of ADC and imaging parameters are necessary.

Conclusions

The effects of the magnetic susceptibility of contrast medium on the signal intensity and ADC of body-DWI after contrast enhancement were examined. Phantoms of different Gd density were examined using three

different imaging techniques: *i.e.*, non-fat suppression DWI, STIR combination DWI and CHESS combination DWI.

Considering Gd density to be distributed over the entire tumour, ADC showed no change after contrast enhancement for all imaging techniques. The signal intensity did not change in non-fat suppression and CHESS combination DWI, but decreased on STIR after contrast enhancement.

However, the present study examined only the effects of magnetic susceptibility of contrast medium. Further detailed studies regarding the use of contrast medium in human subjects are required.

References

1. Takahara T, Imai Y, Yamashita T, et al. Diffusion weighted whole body imaging with background body signal suppression (DWIBS): technical improvement using free breathing, STIR and high resolution 3D display. Radiat Med (22), 275-282, 2004.

2. Nasu K, Kuroki Y, Nawano S, et al. Hepatic mrtastases: Diffusion weighted sensitivity-encoding versus SPIO-enhanced MR imaging. Radiology(239), 122-130, 2006.

3.Moteki T,Ishizuka H. Diffusion-weighted EPI of cystic ovarian lesions: evaluation of cystic contents using apparent diffusion coefficients. J Magn Reson Imaging(12), 1014-1019, 2000.

4.Moteki T, Horikoshi H, Endo K. Diffusion coefficient and signal intensity in endometrial and other pelvic cysts. Magn Reson Imaging (20), 463-470, 2002.

5.Sato C, Naganawa S, Nakamura T, et al. Differentiation of noncancerous

tissue and cancer lesions by apparent diffusion coefficient values in transition and peripheral zones of the prostate. J.Magn.Reson.Imaging (21), 258-262, 2005.

6.Shimofusa R, Fujimoto H, Akamoto H,et al. Diffusion-weighted imaging of prostate cancer. J Compt Assist Tomogr(29), 149-153, 2005.

7.Naganawa S, Sato C, Kumada H, et al. Apparent diffusion coefficient in cervical cancer of the uterus: comparison with the normal uterine cervix. Eur Radiol(15), 71-78, 2005.

8.K Hosseinzadeh, SD Schwarz. Endorectal diffusion-weighted imaging in prostate cancer to differentiate malignant and benign peripheral zone tissue; J.Magn.Reson.Imaging (20), 654-661, 2004.

9. Naganawa S, Kawai H, Fukatsu H, et al. Difusion-weighted imaging of the liver: Technical challenges and prospects for the future; Magnetic Resonance in Medical Sciences(4) , 175-186, 2005.

10.MD Pickles, P Gibbs, M Sreenivas, et al. Diffusion-weighted imaging of normal and malignant prostate tissue at 3T; J.Magn.Reson.Imaging (23), 130-134, 2006.

11.M Koinuma, I Ohashi, K Hanafusa, et al. Apparent diffusion coefficient measurements with diffusion-weighted magnetic resonance imaging for evaluation of hepatic fibrosis; J.Magn.Reson.Imaging (22), 80-85, 2005.

12.Sun XJ, Quan XY, Huang FH, et al. Quantitative evaluation of diffusion-weighted magnetic resonance imaging of focal hepatic lesions; World J Gastroenterol, 11(41), 6535-6537, (2005).

13.T Yoshikawa, H Kawamitsu, DG Mitchell, et al. ADC measurement of abdominal organs and lesions using parallel imaging technique; AJR(187),

1522-1530, (2006).

14. Dose MD, Zhong J, Gore JC. In vivo measurement of ADC change due to intravasucular susceptibility variation. Magn Reson Med (41), 236-240, 1999.

15. Zhong J, Kennan RP, Fulbringht RK, et al. Quantification of intravascular and extravascular contributions to bold effects induced by alteration in oxygenation or intravascular contrast agents. Magn Reson Med (40), 526-536, 1998

16.Yamada K, Kubita H, Kizu O, et al.. Effect of Intravenous Gadolinium-DTPA on Diffusion Weighted images: Stroke 1799-1802, 2002

17.Chen G, Jespersen SN, Pederson M, et al..Intravenous administration of Gd-DTPA prior to DWI dose not affect the apparent diffuision constant. Magn Reson Imaging, 685-689, 2005.

Figure legend

Fig.1 T1-weighted image and DWI of the nine phantoms that dissolved in a physiology solution of salt from 0.0005 to 0.1mmol in Gd-DTPA into a water tank.

Fig.2 Quantity of Gd distribution before and after contrasting of 20 meningiomas and 20 metastases to brain. the quantity of Gd-DTPA distribution to a tumor by the contrast media dosage estimated it with 0.001-0.005mmol.

Fig.3 The pixel value of ten phantoms that dissolved in a physiology solution of salt from 0.0005 to 0.1mmol in Gd-DTPA were perforemed on

DWI non-fat suppression, STIR combination DWI and CHESS combination DWI in b=1000 $x10^{-3}$ s/mm^2 in MPG. Both non-fat suppression DWI and CHESS combination DWI showed similar signal intensity for Gd density. And a signal value did not show a change to Gd density 0.005mmol but showed a tendency to fall when density rose more than it.

Fig.4 A value of ADC which calculated MPG from b=0,500, 1000 $x10^{-3}$ s/mm^2 in three imaging technique of DWI that non-fat suppression DWI, STIR-DWI and CHESS-DWI using ten phantoms who dissolved in a physiology solution of salt to 0.0005 to 0.1mmol.

Fig.5 Images using CHESS-DWI before and after contrasting of meninngioma on the brain. Signal intensity understands that there is not a change at before and after contrasting.

Fig.6 Images using STIR-DWI before and after contrasting on a brain tumor. A signal of image after contrasting is decrease conspicuously compare from one of before contrasting.

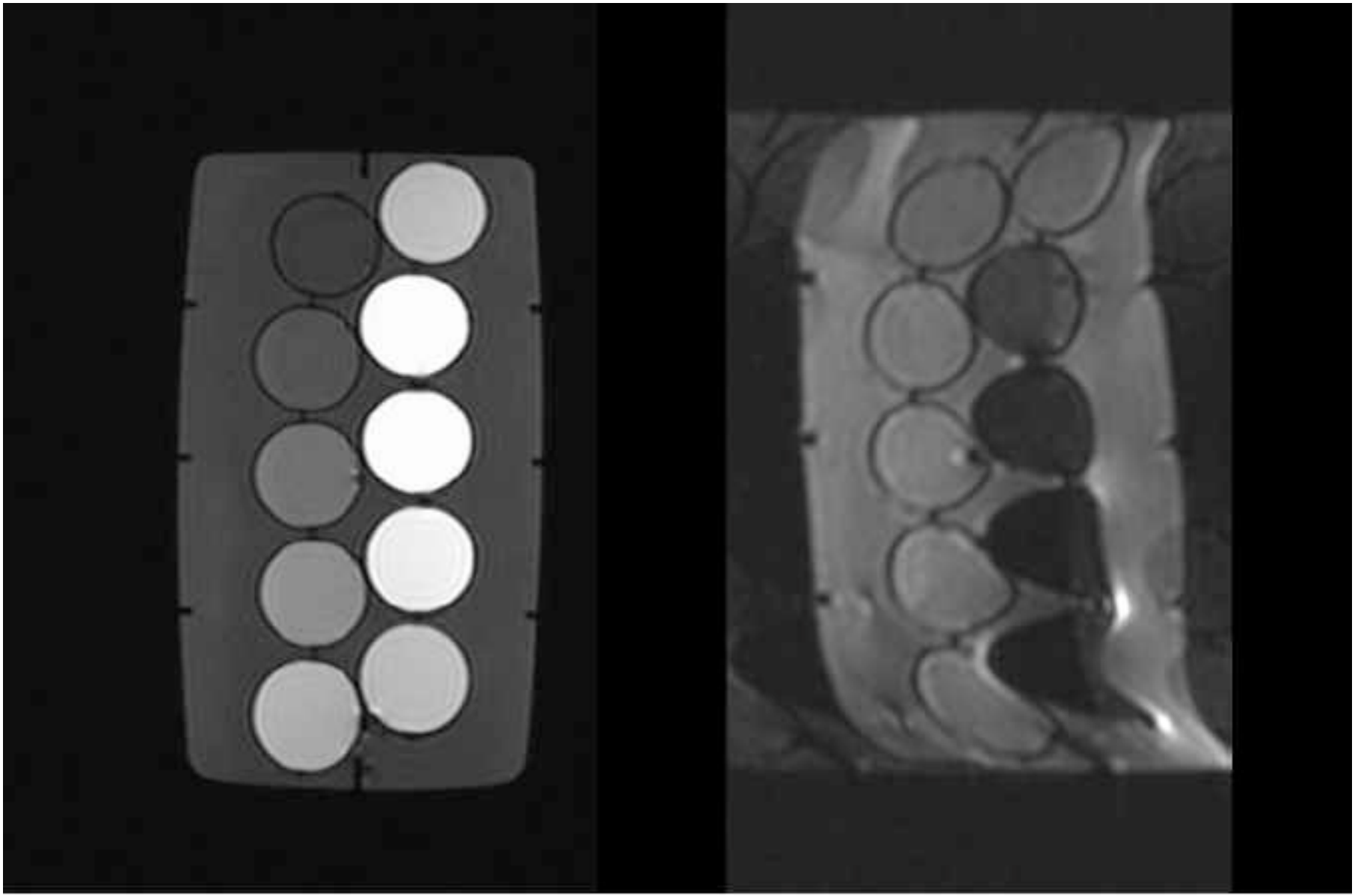

Fig.1

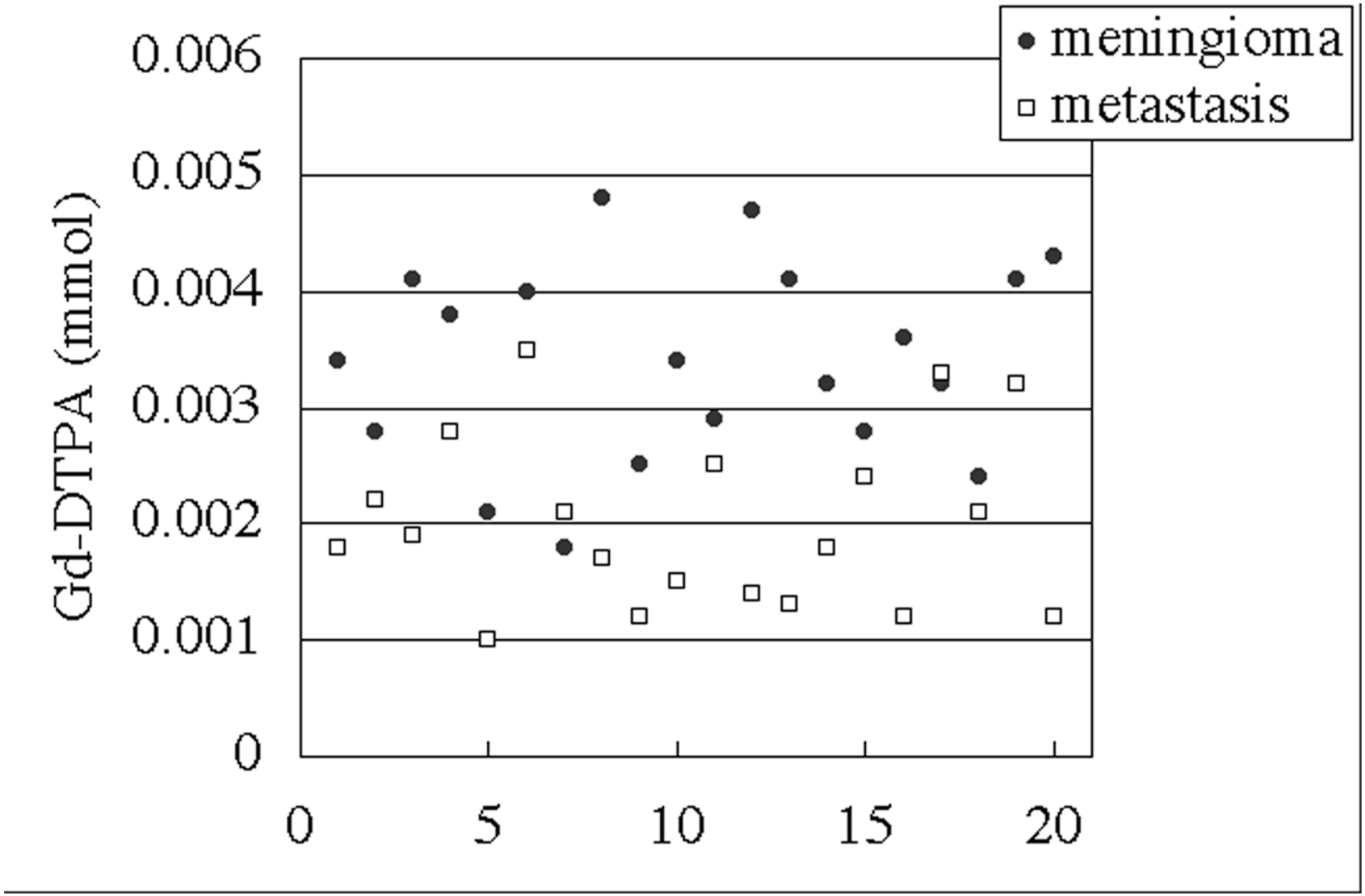
meningioma
metastasis
Gd-DTPA (mmol)
0.006
0.005
0.004
0.003
0.002
0.001
0
0
5
10
15
20

Fig.2

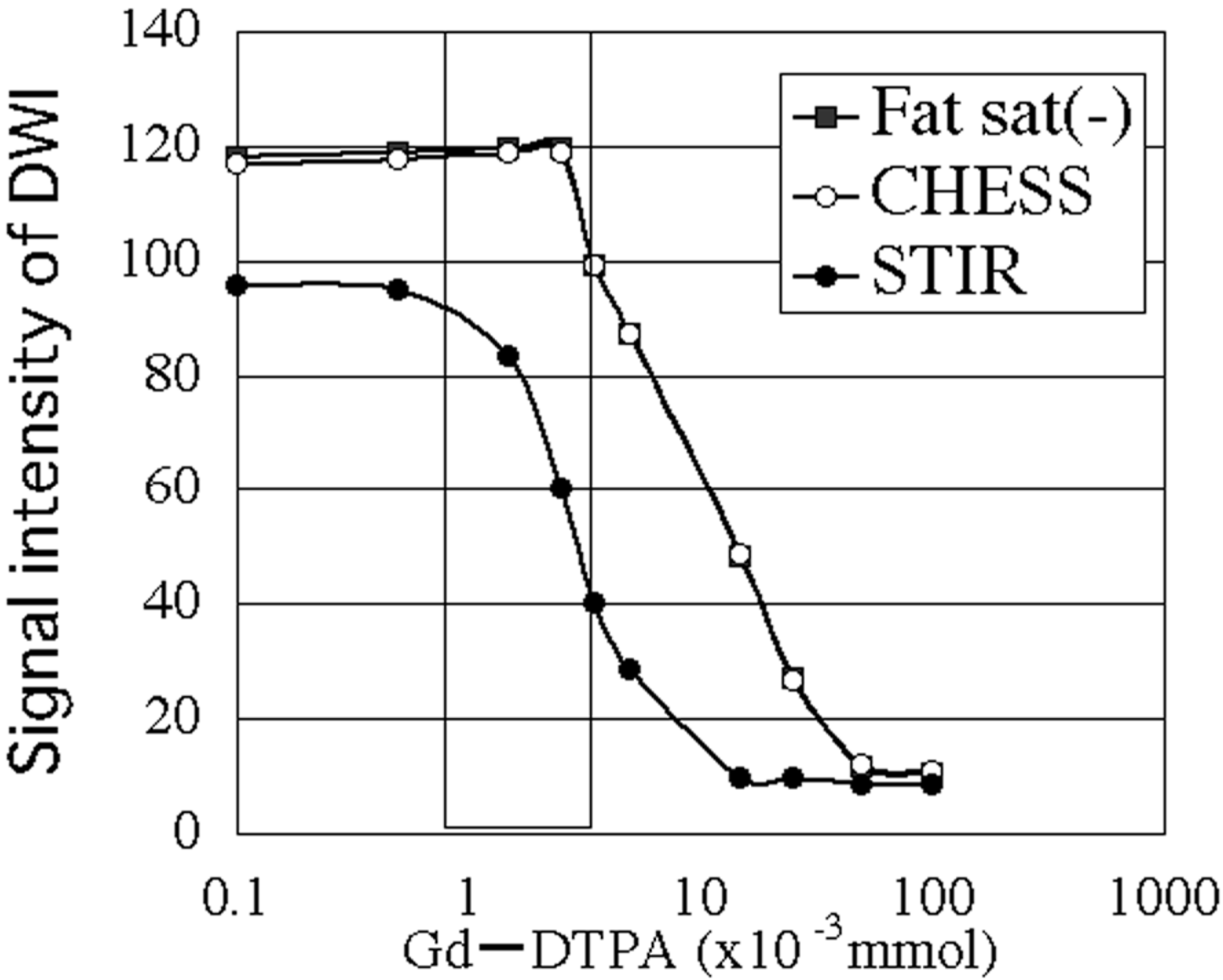
Signal intensity of DWI
140
120
100
80
60
40
20
0
0.1
1
10
100
1000
Gd−DTPA (x10 -3 mmol)
Fat sat(-)
CHESS
STIR

Fig.3

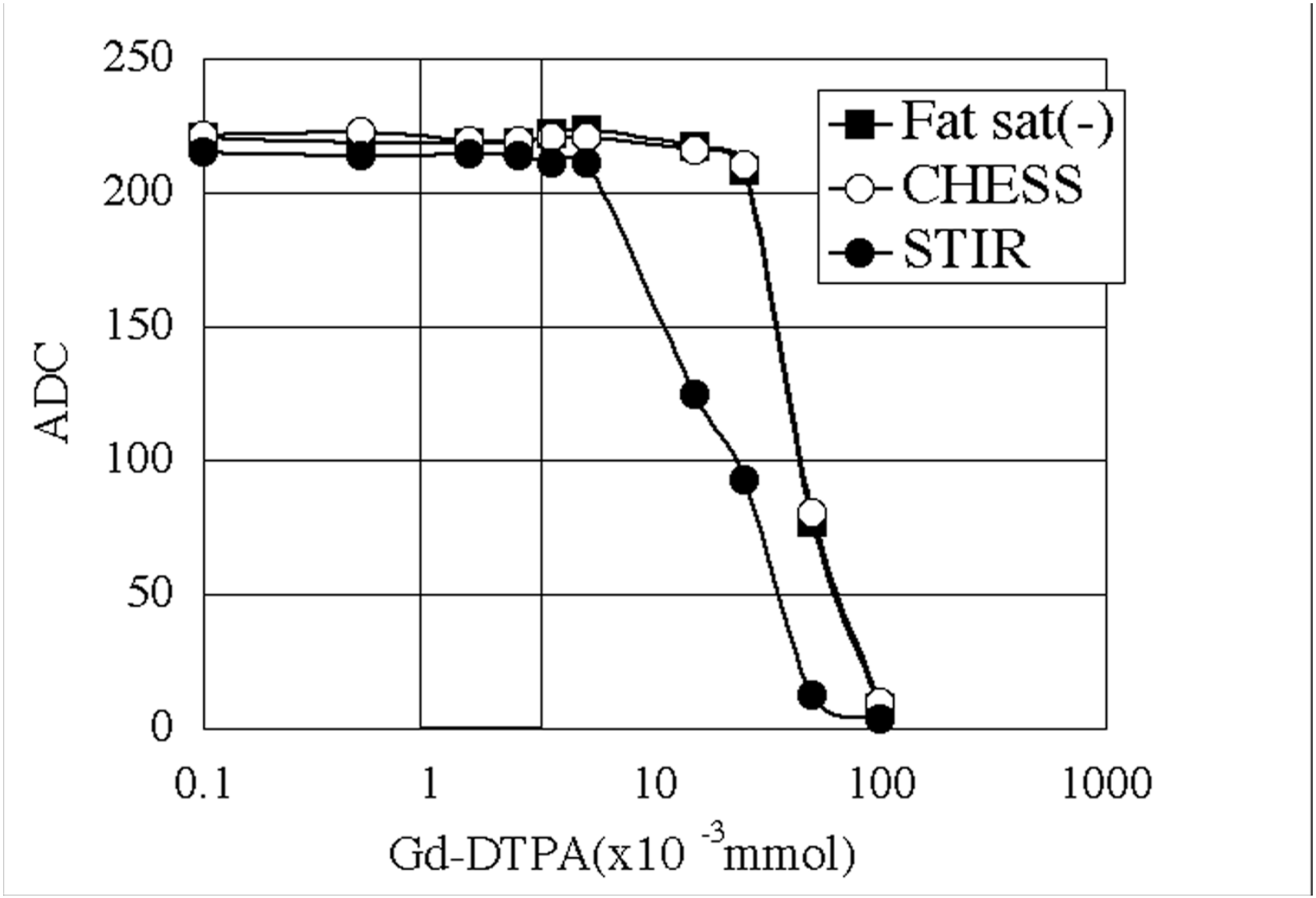
250
200
150
100
50
0
ADC
0.1
1
10
100
1000
Gd-DTPA(x10 -3mmol)
Fat sat(-)
CHESS
STIR

Fig.4

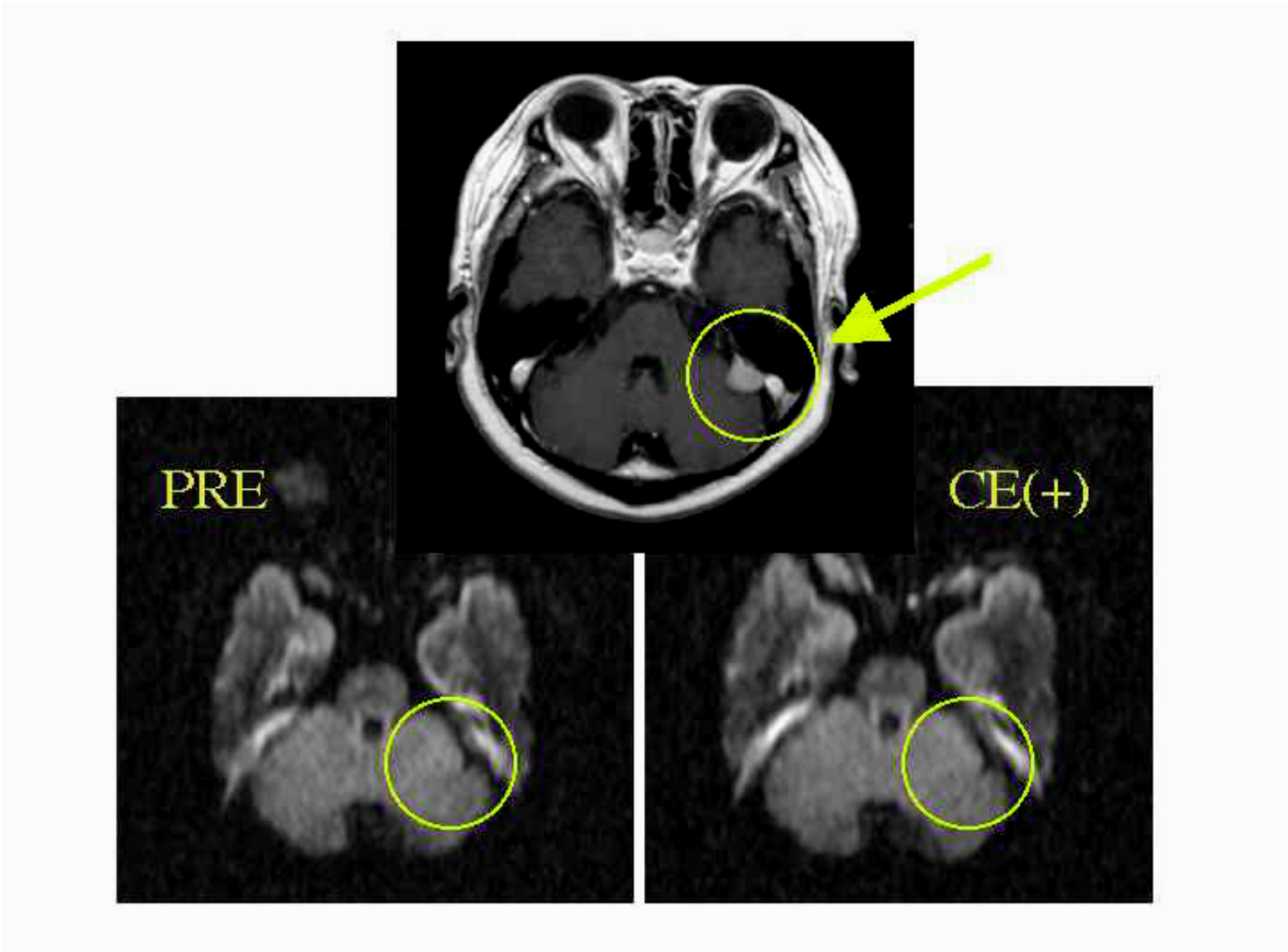

Fig.5

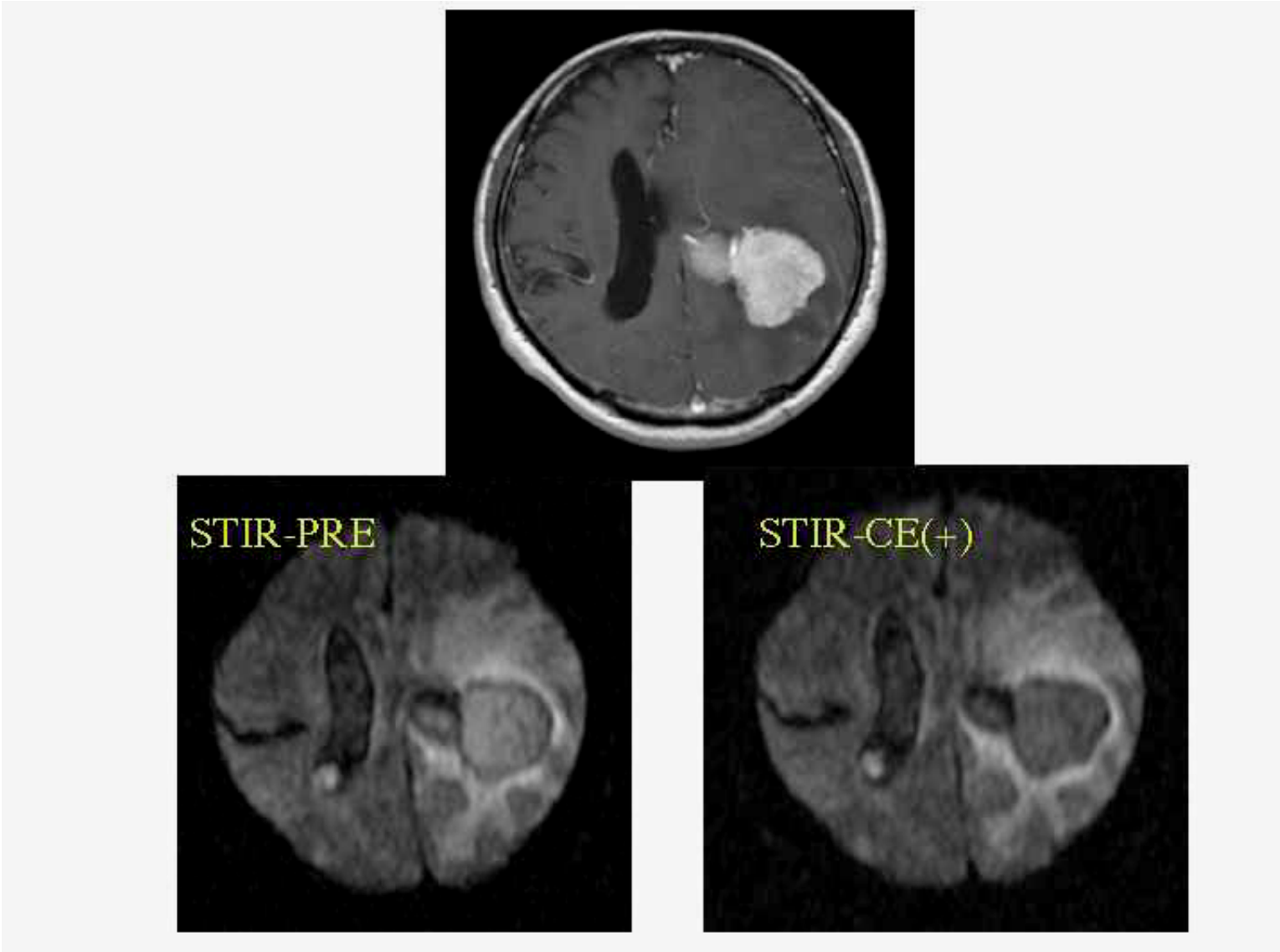

Fig.6