

Microvascular ischemia in patients with myotonic dystrophy

著者	Itoh Hideki, Shimizu Masami, Horita Yuki, Ino Hidekazu, Taguchi Tomio, Kajinami Kouji, Yagi Kunimasa, Chujo Daisuke, Mabuchi Hiroshi
journal or publication title	Japanese Circulation Journal
volume	64
number	9
page range	720-722
year	2000-01-01
URL	http://hdl.handle.net/2297/7530

doi: 10.1253/jc.64.720

Microvascular Ischemia in Patients With Myotonic Dystrophy

Hideki Itoh, MD; Masami Shimizu, MD; Yuki Horita, MD*;
Hidekazu Ino, MD; Tomio Taguchi, MD*; Kouji Kajinami, MD;
Kunimasa Yagi, MD; Daisuke Chujo, MD; Hiroshi Mabuchi, MD

Two women with myotonic dystrophy underwent dipyridamole thallium-201 (²⁰¹Tl) myocardial perfusion imaging, after which one patient developed flat T waves in lead I and aVL, and inverted T waves in leads V2–6. The other patient developed a nonspecific intraventricular block that progressed to complete left bundle branch block and was associated with chest discomfort. Reversible scintigraphic defects were observed in both women. Although there was evidence that suggested myocardial ischemia on the ECG changes and ²⁰¹Tl scintigraphic findings, coronary angiography demonstrated no significant stenoses in either patient. These findings suggest that microvascular dysfunction may lead to myocardial ischemia and conduction disturbances in patients with myotonic dystrophy. (*Jpn Circ J* 2000; 64: 720–722)

Key Words: Dipyridamole; Microvascular ischemia; Myotonic dystrophy; Thallium-201 myocardial scintigraphy

Myotonic dystrophy (DM) is a multisystem disorder with a prevalence rate of 1 in 8,000 patients. The primary genetic defect responsible for DM is an expanded trinucleotide (CTG) repeat in a gene on chromosome 19, encoding myotonin protein kinase (MT-PK). Patients with DM are reported to have a higher incidence of sudden death than the general population, caused by either complete atrioventricular block or ventricular arrhythmias.² It has been suggested that a blunted coronary reserve, resulting from impairment of vascular smooth muscle function is an early component of DM cardiomyopathy.³ We describe 2 patients with DM who had evidence of microvascular ischemia on thallium-201 (²⁰¹Tl) scintigraphy as well as electrocardiographic changes during dipyridamole infusion.

Case Reports

Case 1

A 50-year-old woman with diabetes mellitus was evaluated for ischemic heart disease. She had ptosis and muscle weakness on physical examination, and was diagnosed as having typical DM. Genetic examination revealed 1,500 CTG repeats at the 3' end of the MT-PK gene.

Her 12-lead ECG showed first degree atrioventricular block and a nonspecific intraventricular block, but the QT and QTc intervals were normal. Echocardiography revealed decreased left ventricular systolic function (ejection fraction, 39%). She complained of chest discomfort during dipyridamole stress testing (dipyridamole 0.56 mg/kg), which induced myocardial ischemia and complete left bundle

branch block developed (Fig 1). ²⁰¹Tl myocardial scintigraphy revealed a reversible perfusion defect in the septum induced by dipyridamole infusion (Fig 2). Although ischemic heart disease was suspected, coronary angiography revealed normal coronary arteries. Left ventriculography showed diffuse hypokinesis.

Case 2

A 53-year-old woman underwent cardiac evaluation before surgery to remove a thyroid adenoma. On physical examination, the patient had ptosis, cataracts, muscle weakness, and myotonia. Southern blot analysis of her DNA revealed 1,000 CTG repeats at the 3' end of the MT-PK gene. Her father had died suddenly at 37 years of age and her brother of congestive heart failure at 27 years of age. Therefore, we hypothesized that her family members died of cardiac complications of DM.

The 12-lead electrocardiogram showed no abnormalities at rest. Echocardiography revealed normal left ventricular function and no evidence of hypertrophy. Electrocardiography showed inversion and variability of the T waves in I, aVL, and V1–6 during dipyridamole infusion (dipyridamole 0.56 mg/kg) (Fig 3). ²⁰¹Tl myocardial scintigraphy showed a perfusion defect in the anteroseptal wall with dipyridamole infusion (Fig 4). Coronary angiography revealed normal coronary arteries. Left ventriculography showed almost normal systolic function (ejection fraction, 69%). Endomyocardial biopsy samples from the right ventricle showed evidence of marked fatty infiltration, myocyte hypertrophy and lymphocytic infiltration, but no myofiber disarray in the interstitial fibrosis.

Discussion

The present cases demonstrate that microvascular dysfunction can exist in patients who suffer from DM and have normal coronary angiograms. Although the 2 patients had patent coronary arteries, there was evidence on ECG and ²⁰¹Tl myocardial scintigraphy during dipyridamole infusion

(Received May 1, 2000; revised manuscript received June 5, 2000; accepted June 9, 2000)

Second Department of Internal Medicine, School of Medicine, Kanazawa University, Kanazawa, and *Department of Cardiology, Keiju General Hospital, Nanao, Ishikawa, Japan

Mailing address: Hideki Itoh, MD, The Second Department of Internal Medicine, School of Medicine, Kanazawa University, 13-1 Takara-machi, Kanazawa 920-8640, Japan

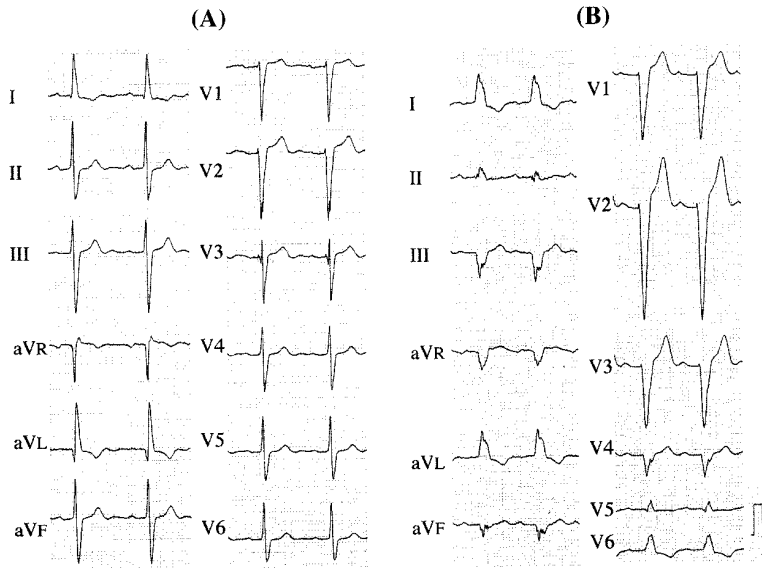


Fig 1. Case 1. Electrocardiograms at rest (A) and after dipyridamole infusion (B). After dipyridamole infusion, the ECG changed from a nonspecific intraventricular block (A) to complete left bundle branch block (B). The patient complained of chest discomfort when the ECG showed complete left bundle branch block.

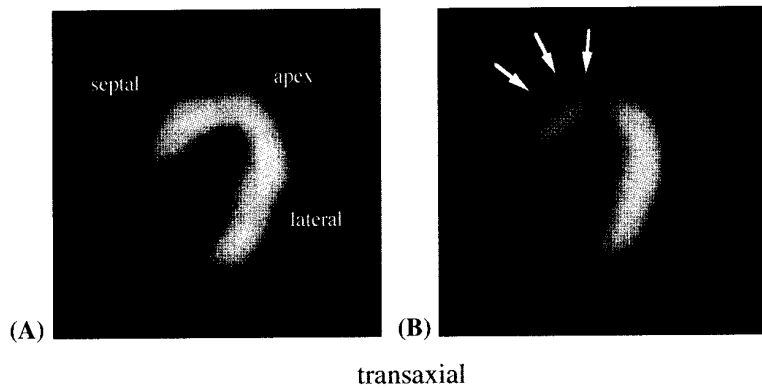


Fig 2. Case 1. ²⁰¹Tl myocardial scintigrams at rest (A) and after dipyridamole infusion (B), showing a reversible perfusion defect in the septum.

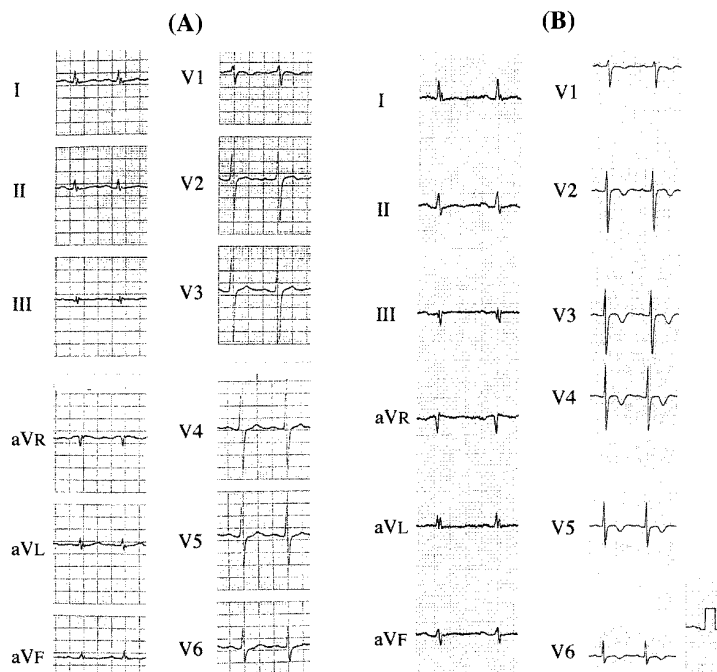


Fig 3. Case 2. Electrocardiograms at rest (A) and after dipyridamole infusion (B). After dipyridamole infusion, the ECG showed flat T waves in lead I and aVL, and inverted T waves in lead V2-6 (B).

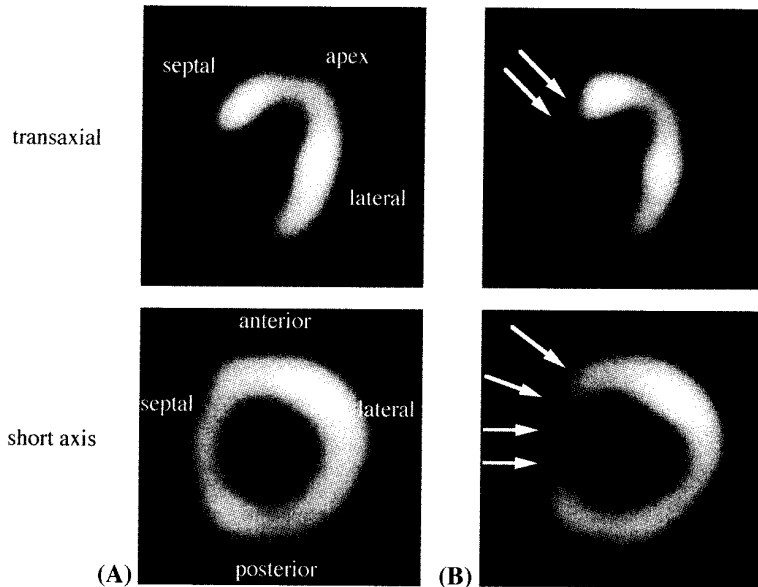


Fig 4. Case 2. ^{201}Tl myocardial scintigrams at rest (A) and after dipyridamole infusion (B), showing a reversible perfusion defect in the anteroseptal wall.

that suggested ischemia. Djillali et al reported that a blunted coronary reserve, because of impairment of vascular smooth muscle function, is an early component of DM cardiomyopathy. Furthermore, they showed a strong relationship between the number of CTG repeats and coronary flow reserve.³ Myocardial ischemia could appear in all myocardial areas in cases of DM, but the current findings from the ^{201}Tl myocardial scintigrams suggest that the septum, as in case 1, and the anteroseptal wall, as in case 2, particularly could have more significant ischemia as compared with the rest of the myocardium.

Gert et al demonstrated that the CTG repeat length varies among tissues and it is not clear whether CTG repeats in DNA from peripheral blood samples correlate with cardiac injury in DM.⁴ Although the number of CTG repeats in cardiac tissue from the present patients is unknown, the findings on ^{201}Tl myocardial scintigrams and ECG during dipyridamole stress testing strongly suggest the existence of microvascular ischemia.

Study Limitations

We did not perform stress testing with infusion of ergo-

novine or acetylcholine and so we cannot exclude vasospastic angina. However, the coronary artery were not spastic before infusion of isosorbide dinitrate and neither patient had clinical evidence of vasospastic angina.

In case 1, the diabetes mellitus has been well controlled (HbA1c, 5.0–6.0%) with medication for 10 years. She had not received an insulin injection nor had she any diabetic complications.

References

1. Ptacek LJ, Johnson KJ, Criggs RC: Genetics and physiology of the myotonic muscle disorders. *N Engl J Med* 1993; **328**: 482–489
2. Hawley RJ, Milner MR, Gottdiener JS, Cohen A: Myotonic heart disease: A clinical follow-up. *Neurology* 1991; **41**: 259–262
3. Djillali A, Pascal M, Helene R, Bernard M, Bruno E, Marco F, et al: Blunted coronary reserve in myotonic dystrophy. *Circulation* 1996; **94**: 973–977
4. Gert J, Patrick W, Marga C, Willy N, Hubert S, Lieve V, et al: Gonosomal mosaicism in myotonic dystrophy patients: Involvement of mitotic events in (CTG)_n repeat variation and selection against extreme expansion in sperm. *Am J Hum Genet* 1994; **54**: 575–585