

Maxillary stability after Le Fort I osteotomy with self-setting β -tricalcium phosphate and an absorbable plate

著者	Ueki Koichiro, Okabe Katsuhiko, Marukawa Kohei, Mukozawa Aya, Moroi Akinori, Miyazaki Mao, Sotobori Megumi, Ishihara Yuri, Yoshizawa Kunio, Ooi Kazuhiro, Kawashiri Shuichi
journal or publication title	International Journal of Oral and Maxillofacial Surgery
volume	42
number	5
page range	597-607
year	2013-03-01
URL	http://hdl.handle.net/2297/33413

doi: 10.1016/j.ijom.2012.10.026

Maxillary stability after Le Fort I osteotomy with self-setting α -tricalcium phosphate and an absorbable plate

KOICHIRO UEKI¹, KATSUHIKO OKABE², KOHEI MARUKAWA², AYA MUKOZAWA², AKINORI MOROI¹, MAO MIYAZAKI², MEGUMI SOTOBORI¹, YURI ISHIHARA¹, KUNIO YOSHIKAWA², KAZUHIRO OOI², SHUICHI KAWASHIRI²

Key words:

Self-setting α -tricalcium phosphate (Biopex®), Le Fort I osteotomy, Maxillary stability, Absorbable plate

¹Department of Oral and Maxillofacial Surgery, Division of Medicine, Interdisciplinary Graduate School of Medicine and Engineering, University of Yamanashi, 1110 Shimokato Chuo Yamanashi 409-3893, Japan

²Department of Oral and Maxillofacial Surgery, Graduate School of Medicine, Kanazawa University, 13-1 Takaramachi, Kanazawa 920-8641, Japan

Address correspondence to: Koichiro Ueki, DDS, PhD.

Department of Oral and Maxillofacial Surgery, Division of Medicine, Interdisciplinary Graduate School of Medicine and Engineering, University of Yamanashi, 1110 Shimokato Chuo Yamanashi 409-3893, Japan

Tel: +81-55-273-9673; Fax; +81-55-273-8210

E-mail: kueki@yamanashi.ac.jp

Abstract

The purpose of this study was to compare postoperative changes in maxillary stability after Le Fort I osteotomy with an unsintered hydroxyapatite (u-HA) / poly-L-lactic acid (PLLA) plate and self-setting α -tricalcium phosphate (Biopex®).

Subjects comprised 45 patients diagnosed of mandibular prognathism with maxillary retrognathism and mandibular prognathism with bimaxillary asymmetry. All patients underwent Le Fort I osteotomy and bilateral sagittal split ramus osteotomy by the uHA/PLLA plate. All patients were divided into 4 groups that consisted of 9 maxillary impaction cases with Biopex® (group 1) to fill the gap between the bone segments, 14 maxillary advancement cases with Biopex® (group 2), 8 maxillary impaction cases without Biopex® (group 3) and 14 maxillary advancement cases without Biopex® (group 4). Changes in time intervals (1, 3 and 12 months) between the groups were compared using cephalography.

The stability did not depend on the Biopex®. However, there were significant differences between groups 1 and 2 in SNA ($P=0.0479$) and between groups 3 and 4 in S-ANS parallel to SN ($P=0.0347$) in the change from 1 to 3 months.

Introduction

Poly-L-lactic acid (PLLA) is one of the various types of absorbable materials that have been used for fixation after Le Fort I osteotomy and sagittal split ramus osteotomy (SSRO). PLLA miniplates promote osteosynthesis of the oral and maxillofacial skeleton, and PLLA screws have been used in patients undergoing orthognathic surgery.^{23,24} In our previous study, we found that PLLA plates and screws (Fixorb[®]-MX, Takiron Co., Osaka, Japan) were useful in Le Fort I osteotomy with SSRO and intraoral vertical ramus osteotomy (IVRO), as well as the conventional titanium plate system.²⁴ Furthermore, a fixation plate system (Super-FIXSORB[®]-MX, Takiron Co. Ltd, Osaka) has been newly developed for use in orthopedic or cranio-facial, oral and maxillofacial or plastic and reconstructive surgeries.²⁰⁻²² These devices are made from composites of uncalcined and unsintered hydroxyapatite (u-HA) particles and PLLA, and they are produced by a forging process, which is a unique compression molding, and machining treatment. They have a modulus of elasticity close to that of natural cortical bone, and can retain a high strength during the period required for bone healing. They can also show optimal degradation and resorption behavior, osteoconductivity, and bone bonding capability. The previous study suggested that there were no significant differences in postoperative time-course changes among the u-HA/PLLA plate system, PLLA plate system and conventional titanium plate system in orthognathic surgery.²⁷

On the other hand, the previous study showed that bony healing could occur in spaces between the segments of the maxilla and pterygomaxillary regions as well as the region of the anterior and lateral walls in the maxilla, but it is not always complete within 1 year after Le Fort I osteotomy.²⁵ To obtain long-term stability, use of various alternative materials between segments should be considered. Autogenous bone from the iliac crest or rib has been recommended,^{1,2} although freeze dried bone,¹¹ proplast blocks,⁶ and the solid-block form of hydroxy apatite have also been advocated.¹⁷ Recently, self-setting α -tricalcium phosphate (Biopex[®]) (Pentax Co, Tokyo, Japan) has been recognized as one of the very useful bone alternative materials.^{16, 26}

The comparative study regarding the maxillary stability with absorbable plate in

combination with bone substitute material has never been reported. The purpose of this study was to compare postoperative changes in maxillary stability after Le Fort I osteotomy between groups using an unsintered hydroxyapatite (u-HA) / poly-L-lactic acid (PLLA) plate with self-setting α -tricalcium phosphate (Biopex®) and groups using uHA/PLLA without Biopex®.

Patients and Methods

Patients:

Subjects comprised 45 Japanese adults (18 men, 27 women) presenting with jaw deformities diagnosed as mandibular prognathism with maxillary retrognathism and mandibular prognathism with bimaxillar asymmetry. At the time of orthognathic surgery, mean patient age ranged from 16 to 48 years), with a mean age and standard deviation of 25.5 ± 7.6 years. This study was a retrospective study. Informed consent was obtained from the patients and the study was approved by Kanazawa University Hospital.

Surgery:

All 45 patients underwent Le Fort I osteotomy and bilateral SSRO (by the Obwegeser method) to advance or impact the maxilla and set back the mandible. The patients were divided into 4 groups on the basis of movement in A-point that consisted of 9 maxillary impaction cases with Biopex® (group 1), 14 maxillary advancement cases with Biopex® (group 2), 8 maxillary impaction cases (group 3) and 14 maxillary advancement cases without material (group 4). The cases whose postoperative A-point moved anteriorly parallel to the SN plane were defined as advanced cases, and the cases whose postoperative A-point moved posteriorly parallel and superiorly perpendicular to the SN plane were defined as impaction cases. The impaction cases were diagnosed as mandibular

prognathism with bimaxillary asymmetry. These cases underwent the unilateral maxillary vertical excess shortening to correct the occlusal cant.

In all patients, 2 uHA/PLLA L-type mini-plates (10×22×1.4 mm with 4 screws (2×8 mm), Super-Fixorb[®]-MX; Takiron Co., Osaka, Japan) and 2 straight uHA/PLLA plates (28×4.5×1.4 mm with 4 screws (2×8 mm), Super-Fixorb[®]-MX; Takiron Co.) were used to fix the maxilla and 2 uHA/PLLA mini-plates (28×4.5×1.5 mm with 4 screws (2×8 mm), Super-Fixorb[®]-MX; Takiron Co.) were used for bilateral internal fixation of the mandible (the u-HA/PLLA group). In groups 1 and 2, Biopex[®] was inserted and covered at the anterior and lateral part of the gap between the segments after plate fixation (Fig. 1). After a few days of inter maxillary fixation (IMF), an elastic was placed to maintain an ideal occlusion in the same manner in all the groups.

Cephalographic assessment:

All patients underwent lateral and posteroanterior (PA) cephalography to assess skeletal changes at 1, 3, and 12 months postoperative (Fig. 2). To assess maxillary stability, arbitrary points for the anterior nasal spine (ANS), and posterior nasal spine (PNS), point A and incisor edge were defined and measured as follows: from the preoperative images, and subsequently transferred to all remaining radiographs. One skilled observer performed all the digitizations to minimize errors in the cephalometric method and that was acceptable for the purposes of this study. Error analysis by digitization and remeasurement of 10 randomly selected cases generated an average error of less than 0.4 mm for the linear measurements and 0.5 degrees for the angular measurements.

Lateral cephalometric analysis

S-A parallel to SN: the distance between point A and sella parallel to the SN plane

S-A perpendicular to SN: the distance between point A and sella perpendicular to the SN

plane

S-PNS parallel to SN: the distance between the arbitrary PNS and sella parallel to the SN plane

S-PNS perpendicular to SN: the distance between the arbitrary PNS and sella perpendicular to the SN plane

Mx1-S parallel to SN: the distance between the incisor edge and sella parallel to the SN plane

Mx1-S perpendicular to SN: the distance between the incisor edge and sella perpendicular to the SN plane

S-ANS parallel to SN: the distance between the arbitrary ANS and sella parallel to the SN plane

S-ANS perpendicular to SN: the distance between the arbitrary ANS and sella perpendicular to the SN plane

PA cephalometric analysis

Mx-Md Midline: the angle between the ANS-Menton line and the line perpendicular to the bilateral zygomatic frontal suture line.

Occlusal cant: the angle between Zy-Zy and the line from the most buccal point at the right first molar crown to the most buccal point at the left molar crown.

Statistical analysis:

Data were statistically analyzed with StatView software, version 4.5 (ABACUS Concepts, Inc., Berkeley, CA, USA). Each serial period was defined, and the differences between measurements were calculated as shown below.

T1: (baseline to 1 month)

T2: (1 month to 3 months)

T3: (3 months to 1 year)

Time-dependent changes in the cephalometric measurements were examined using analysis of variance (ANOVA). The data between the groups were then analyzed by the multiple comparison method in each period. Differences were considered significant at $p < 0.05$.

Results

After surgery, no patient experienced complications such as wound infection or dehiscence, bone instability, or long-term malocclusion. Mean setback was 4.6 ± 3.2 mm on the right and 3.5 ± 3.4 mm on the left in group 1, 5.4 ± 4.6 mm on the right and 6.5 ± 4.5 mm on the left in group 2, 6.1 ± 4.0 mm on the right and 3.6 ± 3.4 mm on the left in group 3, and 7.3 ± 2.7 mm on the right and 5.8 ± 3.0 mm on the left in group 4. There was no significant difference between the four groups.

Each cephalometric value of the T1 showed the detail degree of movement in each site of maxilla (Table.2).

Significant differences were identified in S-A perpendicular to SN by repeated-measures ANOVA ($F=4.771$; $df=3$; $P=0.0061$, within subjects, $F=3.445$; $df=3$; $P=0.0189$; between subjects, $F=0.500$; $df=9$; $P=0.8724$) and S-ANS perpendicular to SN ($F=4.943$; $df=3$; $P=0.0051$, within subjects, $F=4.2591$; $df=3$; $P=0.0067$; between subjects, $F=0.998$; $df=9$; $P=0.445$). However, there were no significant differences in the other measurements by repeated measure ANOVA (Table 1).

In T1 in SNA, group 2 was significantly larger than groups 1 ($P < 0.0001$) and 3 ($P < 0.0001$). Group 4 was also significantly larger than groups 1 ($P < 0.0001$) and 3 ($P < 0.0001$). In T2 in SNA, group 2 was significantly smaller than groups 1 ($P=0.0479$) and 3 ($P=0.0080$).

In T1 in S-A parallel to SN, group 2 was significantly larger than groups 1 ($P=0.0009$) and 3 ($P=0.0010$). Group 4 was also significantly larger than groups 1 ($P=0.0009$) and 3

(P=0.0009). In T2 in S-A parallel to SN, group 2 was significantly smaller than group 1 (P=0.0232).

In T1 in S-ANS parallel to SN, group 2 was significantly larger than groups 1 (P=0.0347) and 3 (P=0.0004). Group 4 was also significantly larger than groups 1 (P=0.0106) and 3 (P<0.0001). In T2 in S-ANS parallel to SN, group 4 was significantly smaller than group 3 (P=0.0255).

There was no significant difference between the groups in T3. Furthermore, no significant differences were identified among the 4 groups in the other measurements on lateral cephalometric analysis and in all measurements in the PA cephalometric analysis (Table. 2).

Discussion

Numerous studies have examined the stability of different resorbable osteosynthesis materials but these studies often involved heterogenous, mixing Angle Class II, Angle Class III and /or trauma cases.^{4,13, 19}

Norholt et al¹⁷ found significant differences in the vertical positioning of the maxilla in a lateral cephalometric analysis after 6 weeks as the position became more superior compared with the postoperative situation in a study using Lactosorb® (Lorenz Surgical, Jacksonville, Fla, USA). In the study by Cheung et al⁵ maxilla with bioresorbable plate fixation (2.0 compact plating system, Inion Ltd., Tampere, Finland) were confirmed to have minimal relapse compared to titanium plate fixation starting from the 6th postoperative week, but vertical instability occurred in the early postoperative period. Costa et al⁶ found that superior displacement of the maxilla occurred mainly within the first 8 postoperative weeks in the study with Lactosorb®. On the other hand, in our previous study using the PLLA plate (Fixsorb®-MX), we found that the maxilla was stable in the horizontal plane but tended to displace superiorly following Le Fort I osteotomy with SSRO or IVRO.²⁴ The plate systems used in each study were different making it difficult to compare the results. However, it

seemed that superior displacement at the anterior part of the maxilla could occur after Le Fort I osteotomy with an absorbable plate.

However, there remain some problems, such as those given below, which still need to be addressed in the search for better resorbable devices. The rigidity should be increased, although the bending strength is adequate in some devices. The degradation rate of high strength PLLA devices should be enhanced and the time period up to complete resorption should be shortened. Bioactivity such as bone conduction and bone bonding capability should be made available by using other bioactive materials. This is for the reason that u-HA/PLLA (Super-Fixsorb[®]-MX) was developed to overcome these problems.²¹

u-HA denotes an inorganic compound which is neither calcined at 800-900 °C nor sintered at 1000-1400 °C, and is a raw material of a HA ceramic with almost the same composition as natural bone. Sintered HA is surface bioactive, but not bioresorbable. On the other hand, u-HA is bioabsorbable allowing the u-HA/PLLA plate and screw to be absorbed in vivo. The u-HA/PLLA plate systems that have completed clinical tests in orthopedic, oral and maxillofacial surgeries exhibit total resorbability and osteological bioactivity such as the ability to directly bond to bone and enhance osteoconductivity.^{14,22,28} In addition, there is good biocompatibility and high stiffness retainable for a long period of time that is needed for bone union to take place.⁹ The u-HA/PLLA plate and screw could be recognized in the computed tomography image, although the PLLA plate was completely radiolucent. Therefore, it is easy to judge whether the u-HA/PLLA plate or screw breaks or becomes displaced. However, it was thought that breakage of the screw head by the driver of the system device in the u-HA/PLLA occurred more frequently than with the PLLA system. Perhaps the u-HA content might reduce the elasticity of the screw.

Clinically, our previous study proved that there were no significant differences in postoperative time-course changes between the u-HA/PLLA plate system, PLLA plate system and the conventional titanium plate system in bilateral SSRO.

On the other hand, for the graft between the segments after Le Fort I osteotomy, previous studies have recommended the use of autogenous interpositional grafts in orthognathic surgery because of the ease of acquisition, their biological acceptability, and

the rapid healing obtained.² The grafts seem to provide sufficient structural integrity to accelerate osseous healing and provide a matrix for secondary reconstruction.⁸ Porous block hydroxyapatite (PBHA) implants used as bone graft substitute in orthognathic surgery have been reported to be biocompatible based on clinical, histological, and radiographic findings.¹⁰ Wardrop et al²⁹ found that vertical and /or horizontal relapse was 1 mm or less for 21 patients who underwent maxillary advancement and/or downgraft procedures. Mehla et al¹⁵ also concluded that maxillary advancement with Le Fort I osteotomies by using rigid fixation and interpositional PBHA grafting is a stable and predictable procedure regardless of the direction of vertical maxillary movement. However, there was no report compared with the designed control group regarding to the maxillary stability with the materials.

Regarding the Biopex® used in this study, we reported that inserting Biopex® in the gap between the proximal and distal segments was useful for new bone formation and it did not prevent the recovery of lower lip hypoesthesia after SSRO with bent absorbable plate fixation.²⁶

Monma et al¹⁶ have originally developed a self-setting cement-type calcium phosphate material consisting of α -TCP, dicalcium phosphate dibasic (DCPD) and tetracalcium phosphate monoxide (TeCP). According to their extensive studies, this cement-type material could be refined, demonstrating better biocompatibility and direct integration to bone without any participation of peripheral soft tissues.^{11,12,30} As it is free of the infiltration over time of residual monomers of methacrylate resin, which has long been used for orthopedic treatment, this self-setting cement came to be rapidly targeted for clinical use in Japan.

A previous experimental study using rabbit suggested that the use of an absorbable plate (Super FIXSORB®-MX) in combination with Biopex® was useful and both Super FIXSORB®-MX and Biopex® could provide adequate bone regeneration and maintain strength and stability in the surgical bone space.¹⁸

In the lateral cephalometric analysis, there were significant differences in the time-course changes in S-A perpendicular to SN and S-ANS perpendicular to SN among

the 4 groups examined, but there were no significant differences between the subjects in both measurements. For these reasons, it could be understood that postoperative superior displacement tended to occur in all groups, but significant differences among the 4 groups could not be identified. On the other hand, in T1 in SNA, S-A parallel to SN and S-ANS parallel to SN, group 2 was significantly larger than groups 1 and 3. Group 4 was also significantly larger than groups 1 and 3. This result reflected the direction and amount of movement in the maxillary segment. In T2 in SNA and S-A parallel to SN, group 2 was significantly smaller than group 1. Mandibular setback surgery was performed in all cases so that relapse tendency in the mandible might induce the maxillary advancement tendency in order to keep the normal anterior teeth guidance.

In the time-course of change in the result of the PA cephalogram, no significant differences were identified among the 4 groups. This study could not detect the difference between the 4 groups. Sample size was so small in this study that further examination with a larger sample size would be necessary.

Bone strength of the maxilla should be considered when stability after Le Fort I osteotomy is examined. Our previous study showed that there were no significant differences in area of bone defect between the segmental gaps after Le Fort I osteotomy among the plate types using 3-dimensional computed tomography.²⁵ Various factors such as preoperative bone thickness, occlusion, inter-maxillary traction, moving direction and amount, age and gender etc. were considered to be associated with healing at the anterior and lateral walls of the maxilla. The change in stress distribution at the region of the space between the segments might also affect the change in bone area. This study showed that the direction of maxillary movement affected the stability more than the use of Biopex. The absorption of the plate was not observed in this study for 1 year follow-up. The strength of absorbable plate might keep for 1 year after surgery. Therefore, it will be necessary to confirm the replacement from the Biopex[®] to new bone in further study for longer period.

Conclusion

The Biopex® and the Super FIXSORB®-MX are so different from PBHA and conventional titanium plate, that this study could have significant information for clinicians, although the study sample was small.

In this study, there was no significant difference between use of Biopex® and nothing else. However, there was significant a difference between maxillary advancement and impaction. This suggested that use of Biopex® could not change the stability after Le Fort I osteotomy with the uHA/PLLA plate system for 1 year follow up, although the direction in the maxillary movement could affect the stability.

References

- 1) Araujo A, Schendel SA, Wolford LM, Epker BN. Total maxillary advancement with and without bone grafting. *J Oral Surg* 1978; 36: 849-58.
- 2) Bloomquist DS. Long-term results of subperiosteal implants combined with cancellous bone graft. *J Oral Maxillofac Surg* 1982; 10: 348-52.
- 3) Burton DM, Berarducci JP, Scheffer RB. Proplast grafting: A new method for stabilization of maxillary advancements. *J Oral Surg* 1980; 50: 387-9.
- 4) Cheung LK, Chow LK, Chiu WK. A randomized controlled trial of resorbable versus titanium fixation for orthognathic surgery. *Oral Surg Oral Med Oral Pathol Oral Radiol Endod* 2004; 98: 386-397.
- 5) Cheung LK, Yip IH, Chow RL. Stability and morbidity of Le Fort I osteotomy with bioabsorbable fixation: a randomized controlled trial. *Int J Oral Maxillofac Surg* 2008; 37: 232-41.
- 6) Costa F, Robiony M, Zorzan E, Zerman N, Politi M. Stability of skeletal Class III malocclusion after combined maxillary and mandibular procedures: Titanium versus resorbable plates and screws for maxillary fixation. *J Oral Maxillofac Surg* 2006; 64: 642-51.
- 7) Epker BN, Friedlaender NC, Wolford LM, West RA. The use of freeze-dried bone in middle-third face advancements. *J Oral Surg* 1976; 42: 278-89.
- 8) Epker BN, Schendel SA. Total maxillary surgery. *Int J Oral Surg* 1980; 9:1-24.
- 9) Furukawa T, Matsusue Y, Yasunaga T, Nakagawa Y, Okada Y, Shikinami Y, Okuno M, Nakamura T. Histomorphometric study on high-strength hydroxyapatite/poly (L-lactide) composite rods for internal fixation of bone fractures. *J Biomed Mater Res* 2000; 50: 410-9.
- 10) Holmes RE, Wardrop RW, Wolford LM. Hydroxyapatite as a bone graft substitute in orthognathic surgery: Histologic and histometric findings. *J Oral Maxillofac Surg* 1988; 46: 661-71.
- 11) Kurashina K, Kurita H, Hirano M, Kotani A, Klein CP, de Groot K. In vivo study of

calcium phosphate cements: implantation of an alpha-tricalcium phosphate/dicalcium phosphate dibasic/tetracalcium phosphate monoxide cement paste. *Biomaterials* 1997; 18: 539-43.

- 12) Kurashina K, Kurita H, Kotani A, Takeuchi H, Hirano M: In vivo study of a calcium phosphate cement consisting of alpha-tricalcium phosphate/dicalcium phosphate dibasic/tetracalcium phosphate monoxide. *Biomaterials* 1997; 18: 147-51.
- 13) Landes CA, Ballon A, Roth C. Maxillary and mandibular osteosynthesis with PLGA and P(L/dL)LA implants: a 5 year inpatient biocompatibility and degradation experience. *Plast Reconstr Surg* 2006; 117: 2347-2360.
- 14) Matsumoto M, Chosa E, Nabeshima K, Shikinami Y, Tajima N: Influence of bioresorbable, unsintered hydroxyapatite/poly-L-lactide composite films on spinal corc, nerve roots, and epidural space. *J Biomed Mater Res* 2002; 60: 101-9.
- 15) Mehra P, Castro V, Freitas RZ, Wolford LM: Stability of the Le Fort I osteotomy for maxillary advancement using rigid fixation and porous block hydroxyapatite grafting. *Oral Surg Oral Med Oral Pathol Oral Radiol Endod* 2002; 94:18-23.
- 16) Monma H, Ohta K, Takahashi S: A study of the newly developed α -tricalcium phosphate cement. *FC Rep* 6: 475, 1988.
- 17) Norholt SE, Pedersen TK. Le Fort I miniplate osteosynthesis: a randomized, prospective study comparing resorbable PLLA/PGA with titanium. *Int J Oral Maxillofac Surg* 2004; 33: 245-52.
- 18) Okabe K, Ueki K, Marukawa K, Mukozawa A, Miyazaki M, Nakagawa K. An experimental study of use of absorbable plate in combination with self-setting alpha-tricalcium phosphate for orthognathic surgery. *Oral Surg Oral Med Oral Pathol Oral Radiol Endod* 2010; 110: 560-9.
- 19) Shand JM, Heggie AA. Use of a resorbable fixation system in orthognathic surgery. *Br J Oral Maxillofac Surg* 2000; 38: 335-337.
- 20) Shikinami Y, Matsusue Nakamura T. The complete process of bioresorption and bone replacement using devices made of forged composite of raw hydroxyapatite particles/poly L-lactide (F-u-HA/PLLA). *Biomaterials* 2005; 26: 5542-51.

- 21) Shikinami Y, Okuno M. Bioresorbable devices made of forged composites of hydroxyapatite (HA) particles and poly-l-lactide (PLLA): Part I. Basic characteristics. *Biomaterials* 1999; 20: 859-77.
- 22) Shikinami Y, Okuno M. Bioresorbable devices made of forged composites of hydroxyapatite (HA) particles and poly-l-lactide (PLLA): Part II. Practical properties of miniscrews and miniplates. *Biomaterials* 2001; 22: 3197-211.
- 23) Ueki K, Hashiba Y, Marukawa K, Okabe K, Nakagawa K, Alam S, Yamamoto E. Evaluation of bone formation after sagittal split ramus osteotomy with bent plate fixation using computed tomography. *J Oral Maxillofac Surg* 2009; 67: 1062-8.
- 24) Ueki K, Marukawa K, Shimada M, Nakagawa K, Alam S, Yamamoto E. Maxillary stability following Le Fort I osteotomy in combination with sagittal split ramus osteotomy and intraoral vertical ramus osteotomy: a comparative study between titanium miniplate and poly-L-lactic acid plate. *J Oral Maxillofac Surg* 2006; 64: 74-78.
- 25) Ueki K, Miyazaki M, Okabe K, Mukozawa K, Moroi A, Nakagawa K, Yamamoto E. Assessment of bone healing after Le Fort I osteotomy with 3-dimensional computed tomography. *J Cranio-Maxillofac Surg* 2011; 39: 237-43.
- 26) Ueki K, Okabe K, Marukawa K, Mukozawa A, Moroi A, Miyazaki M, Nakagawa K, Yamamoto E: Effect of self-setting α -tricalcium phosphate between segments for bone healing and hypoesthesia in lower lip after sagittal split ramus osteotomy. *J Craniomaxillofac Surg* 2011 (Epub ahead).
- 27) Ueki K, Okabe K, Miyazaki M, Mukozawa A, Moroi A, Marukawa K, Nakagawa K, Yamamoto E: Skeletal stability after mandibular setback surgery: Comparisons among unsintered hydroxyapatite (u-HA) / poly-L-lactic acid (PLLA) plate, PLLA plate and titanium plate. *J Oral Maxillofac Surg* 2011; 69: 1464-8.
- 28) Yasunaga T, Matsusue Y, Furukawa T, Shikinami Y, Okuno M, Nakamura T. Bonding behavior of ultrahigh strength unsintered hydroxyapatite particles/poly (L-lactide) composites to surface of tibia cortex in rabbits. *J Biomed Mater Res* 1999; 47: 412-9.
- 29) Wardrop R, Wolford LM. Maxillary stability following downgraft and/or

advancement procedures with stabilization using rigid fixation and porous block hydroxyapatite implants. *J Oral Maxillofac Surg* 1989; 47: 336-342.

- 30) Yuan H, Li T, de Bruijn JD, de Groot K, Zhang X. Tissue response of calcium phosphate cement: a study in dogs. *Biomaterials* 2000; 21: 1283-90.

Legends

Fig.1 Intra-operative photograph. Biopex® was inserted between the segments at the anterior and lateral walls.

Fig.2 Measurement points on PA and the lateral cephalograms

Table 1. Cephalometric measurements. SD indicates standard deviation.

Table 2. Time interval value of cephalometric data. SD indicates standard deviation. T1: (baseline to 1 month), T2: (1 month to 3 months), and T3: (3 months to 1 year). a-n: significant difference between same letter at $P < 0.05$ (non-paired t-test).

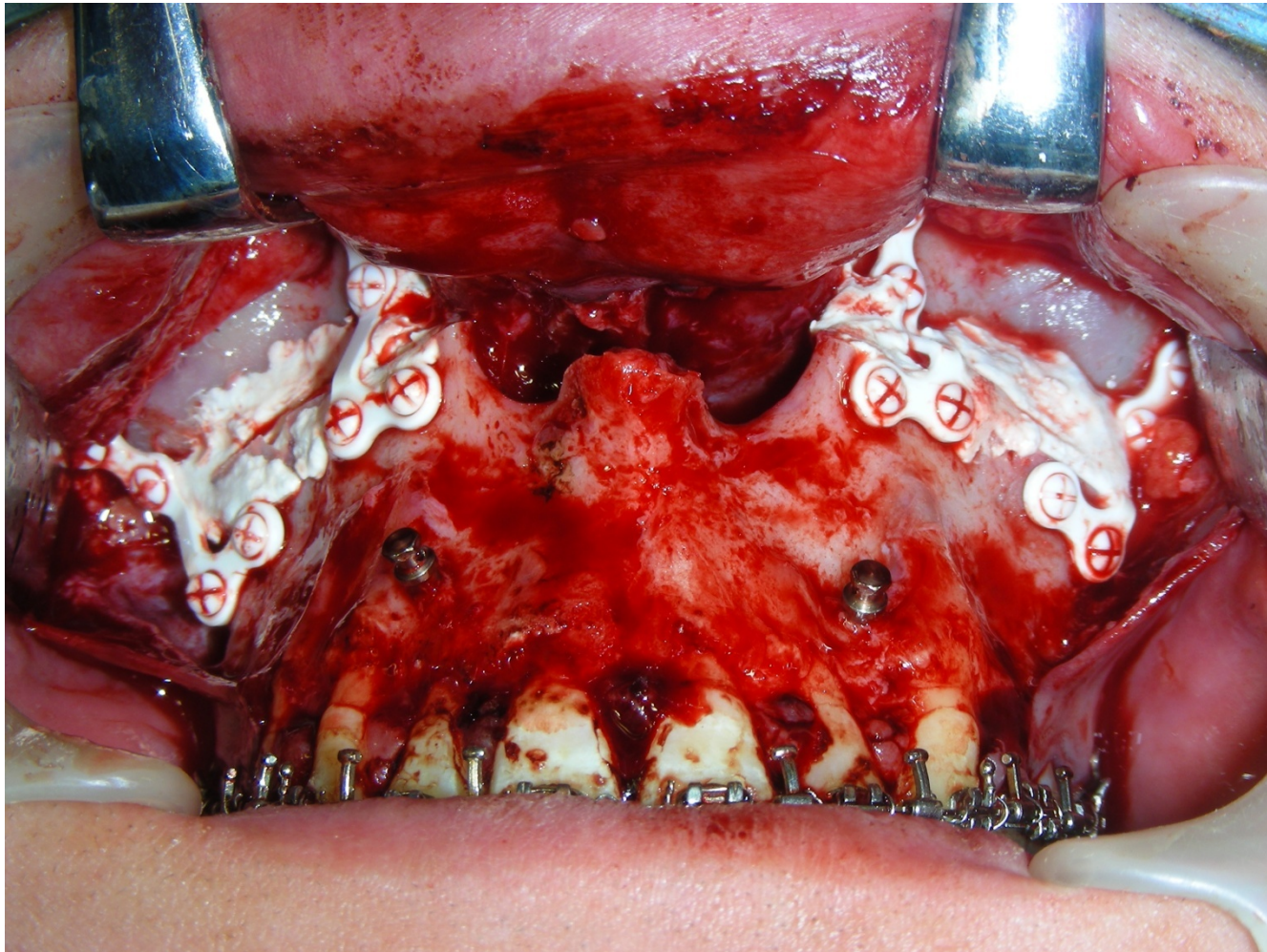


Fig.1

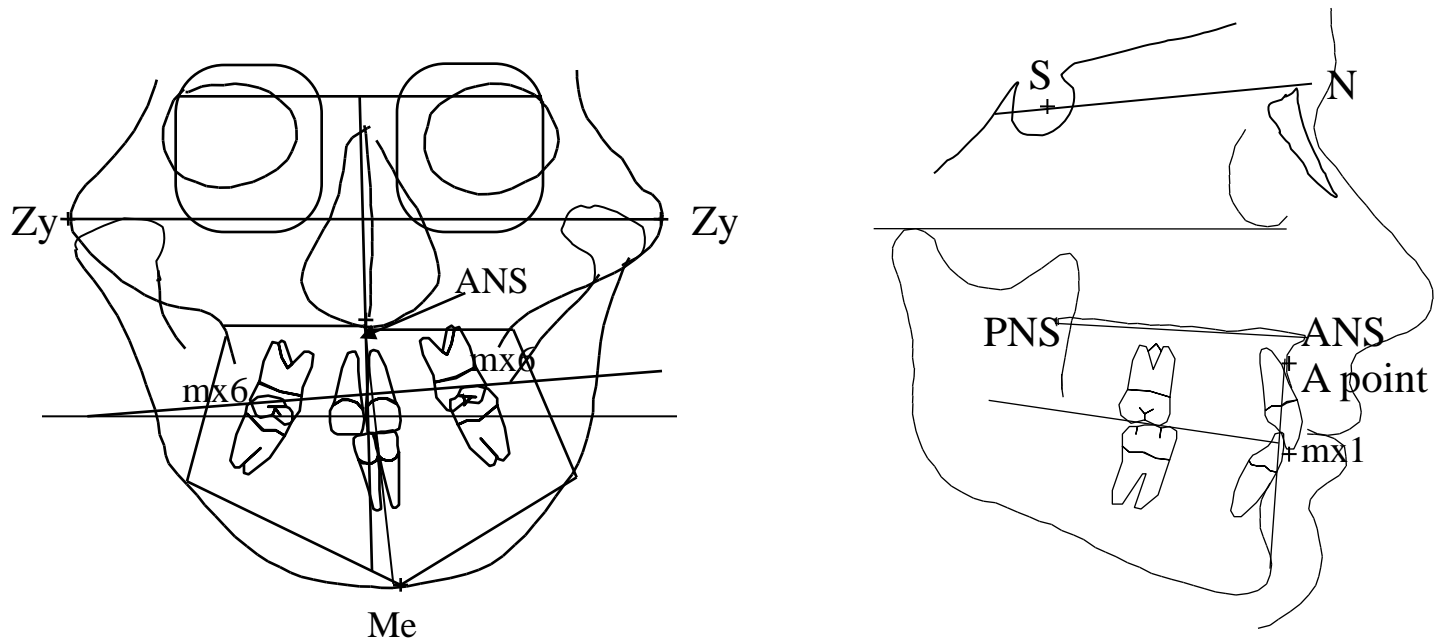


Fig.2

group1		Baseline		1month		3months		1year	
		Mean	SD	Mean	SD	Mean	SD	Mean	SD
SNA	(dg)	83.4	4.4	81.5	4.2	83.6	3.8	82.5	3.6
S-A parallel to SN	(mm)	61.6	6.5	60.6	5.9	62.1	5.3	61.4	5.9
S-A perpend SN	(mm)	65.0	3.1	65.3	3.4	64.2	2.5	65.0	3.6
S-PNS parallel to SN	(mm)	17.0	2.4	16.0	3.3	17.0	3.4	16.8	2.5
S-PNS perpend to SN	(mm)	50.8	3.1	49.0	2.9	49.0	2.9	48.8	2.9
mx1-S parallel to SN	(mm)	63.0	8.3	62.1	8.1	63.1	6.4	61.7	8.2
mx1-S perpend to SN	(mm)	68.8	2.6	69.8	2.0	69.1	2.5	69.6	2.9
S-ANS parallel to SN	(mm)	67.0	5.8	67.2	5.6	68.1	4.7	67.5	6.2
S-ANS perpend to SN	(mm)	58.2	2.5	58.9	3.5	58.1	3.2	57.9	3.5
Mx-Md Midline	(dg)	-0.1	4.9	-1.4	1.1	-0.8	1.5	-0.5	1.7
Occlusal cant	(dg)	0.9	2.5	2.5	1.3	2.2	2.0	1.9	2.0

group2		Baseline		1month		3months		1year	
		Mean	SD	Mean	SD	Mean	SD	Mean	SD
SNA	(dg)	81.3	3.7	84.4	3.0	84.2	2.7	83.8	2.6
S-A parallel to SN	(mm)	59.5	3.7	63.2	3.2	63.2	3.3	62.7	3.4
S-A perpend SN	(mm)	66.6	3.3	66.1	5.3	64.7	5.3	65.6	4.7
S-PNS parallel to SN	(mm)	14.4	2.8	17.3	3.1	18.6	3.2	18.5	2.0
S-PNS perpend to SN	(mm)	50.1	3.8	49.2	4.0	48.8	3.6	49.5	4.1
mx1-S parallel to SN	(mm)	60.4	6.4	64.8	5.5	65.2	5.8	63.9	5.7
mx1-S perpend to SN	(mm)	69.2	2.9	69.5	2.6	69.5	2.6	69.6	2.7
S-ANS parallel to SN	(mm)	66.1	4.1	69.5	3.4	69.2	3.9	68.8	3.5
S-ANS perpend to SN	(mm)	59.3	3.1	59.0	5.1	57.3	3.7	58.4	3.6
Mx-Md Midline	(dg)	0.9	6.5	-0.7	1.3	-0.3	1.6	-1.0	1.8
Occlusal cant	(dg)	-0.6	2.7	1.3	2.0	1.7	2.4	2.1	1.6

group3		Baseline		1month		3months		1year	
		Mean	SD	Mean	SD	Mean	SD	Mean	SD
SNA	(dg)	84.0	3.5	81.9	4.5	84.6	3.2	84.7	3.6
S-A parallel to SN	(mm)	60.9	3.2	59.7	4.3	61.4	3.7	63.0	3.0
S-A perpend SN	(mm)	60.4	6.8	58.5	5.6	58.8	6.3	60.4	6.0
S-PNS parallel to SN	(mm)	17.0	2.8	17.9	3.1	16.4	3.4	18.0	3.1
S-PNS perpend to SN	(mm)	46.1	5.2	45.0	3.7	44.7	4.1	45.3	3.7
mx1-S parallel to SN	(mm)	64.1	2.7	64.7	2.9	65.5	3.4	66.9	3.3
mx1-S perpend to SN	(mm)	67.1	3.4	68.0	3.0	67.2	3.5	69.2	2.4
S-ANS parallel to SN	(mm)	65.3	3.9	63.5	4.7	65.3	3.8	67.4	4.2
S-ANS perpend to SN	(mm)	53.7	5.6	53.0	5.9	52.4	6.3	54.4	5.6
Mx-Md Midline	(dg)	3.1	4.4	-0.3	2.1	0.3	2.3	1.4	3.2
Occlusal cant	(dg)	-1.1	1.9	2.0	1.7	0.3	1.9	-1.9	5.3

group4		Baseline		1month		3months		1year	
		Mean	SD	Mean	SD	Mean	SD	Mean	SD
SNA	(dg)	80.3	3.6	84.0	4.7	84.8	4.1	83.3	4.1
S-A parallel to SN	(mm)	57.8	6.2	61.5	5.9	61.4	5.5	62.0	7.5
S-A perpend SN	(mm)	61.6	4.6	60.8	5.8	60.2	5.0	61.5	5.4
S-PNS parallel to SN	(mm)	15.3	4.1	16.9	3.6	17.3	2.7	17.0	5.2
S-PNS perpend to SN	(mm)	48.0	3.7	46.9	4.8	46.3	4.3	47.4	5.8
mx1-S parallel to SN	(mm)	61.0	8.3	64.6	6.8	64.9	7.2	65.4	9.7
mx1-S perpend to SN	(mm)	67.9	5.9	67.8	5.7	66.8	6.5	68.9	6.8
S-ANS parallel to SN	(mm)	62.9	6.2	66.9	5.8	65.4	5.8	66.4	7.9
S-ANS perpend to SN	(mm)	55.3	3.9	53.5	4.9	53.1	4.2	54.6	5.0
Mx-Md Midline	(dg)	-0.9	4.4	-1.1	1.6	-1.1	2.2	-0.4	1.2
Occlusal cant	(dg)	1.8	2.9	1.3	2.0	1.7	2.2	1.4	2.0

Table.1

group1		T1		T2		T3		
		Mean	SD	Mean	SD	Mean	SD	
SNA	(dg)	-1.9	a,b	1.6	2.0	2.0	-1.0	1.5
S-A parallel to SN	(mm)	-1.0	e,g	1.6	1.6	3.1	-0.8	1.5
S-A perpend SN	(mm)	0.3		3.1	-1.1	1.6	0.8	2.2
S-PNS parallel to SN	(mm)	-1.0		2.1	0.9	3.8	-0.2	3.2
S-PNS perpend to SN	(mm)	-1.8		2.4	0.0	2.2	-0.2	2.4
mx1-S parallel to SN	(mm)	-1.0		3.3	1.0	2.1	-1.4	3.4
mx1-S perpend to SN	(mm)	1.1		1.2	-0.7	1.9	0.4	2.0
S-ANS parallel to SN	(mm)	0.2	j,l	2.0	0.9	3.3	-0.6	3.0
S-ANS perpend to SN	(mm)	0.7		2.7	-0.8	2.7	-0.3	2.7
Mx-Md Midline	(dg)	-1.3		4.5	0.6	1.1	0.2	0.8
Occlusal cant	(dg)	1.6		3.3	-0.3	2.6	-0.2	1.9

group2		T1		T2		T3		
		Mean	SD	Mean	SD	Mean	SD	
SNA	(dg)	3.1	a	2.4	-0.2	1.1	-0.5	1.6
S-A parallel to SN	(mm)	3.7	e,f	2.9	-0.1	1.1	-0.4	2.1
S-A perpend SN	(mm)	-0.5		3.5	-1.4	2.2	0.9	2.5
S-PNS parallel to SN	(mm)	2.8		3.2	1.3	3.1	-0.1	4.2
S-PNS perpend to SN	(mm)	-0.9		1.4	-0.4	1.6	0.7	1.6
mx1-S parallel to SN	(mm)	4.4		4.7	0.4	1.6	-1.3	2.7
mx1-S perpend to SN	(mm)	0.4		1.2	0.0	1.2	0.1	1.1
S-ANS parallel to SN	(mm)	3.4	jk	2.7	-0.4	1.0	-0.4	2.5
S-ANS perpend to SN	(mm)	-0.3		3.1	-1.6	2.3	1.0	2.0
Mx-Md Midline	(dg)	-1.6		6.1	0.4	1.4	-0.7	1.8
Occlusal cant	(dg)	1.9		2.8	0.4	1.8	0.4	2.1

group3		T1		T2		T3		
		Mean	SD	Mean	SD	Mean	SD	
SNA	(dg)	-2.1	b	1.7	2.7	2.4	0.1	2.0
S-A parallel to SN	(mm)	-1.2	f,h	1.8	1.7	2.4	1.6	3.2
S-A perpend SN	(mm)	-1.9		2.7	0.4	1.9	1.6	2.9
S-PNS parallel to SN	(mm)	0.9		2.1	-1.5	2.4	1.7	2.5
S-PNS perpend to SN	(mm)	-1.1		3.8	-0.3	2.4	0.6	2.1
mx1-S parallel to SN	(mm)	0.6		2.0	0.8	2.1	1.4	2.9
mx1-S perpend to SN	(mm)	0.8		1.0	-0.8	1.9	2.1	2.7
S-ANS parallel to SN	(mm)	-1.8	k,m	2.1	1.8	2.0	2.1	3.9
S-ANS perpend to SN	(mm)	-0.8		3.7	-0.6	2.1	2.1	2.3
Mx-Md Midline	(dg)	-3.3		4.1	0.6	1.5	1.1	1.7
Occlusal cant	(dg)	3.0		2.1	-1.6	2.8	-2.2	6.0

group4		T1		T2		T3		
		Mean	SD	Mean	SD	Mean	SD	
SNA	(dg)	3.7		2.5	0.8	1.7	-1.4	2.5
S-A parallel to SN	(mm)	3.7	g,h	2.7	-0.1	1.7	0.6	4.5
S-A perpend SN	(mm)	-0.8		3.7	-0.6	3.0	1.3	4.3
S-PNS parallel to SN	(mm)	1.7		2.9	0.3	2.5	-0.3	4.4
S-PNS perpend to SN	(mm)	-1.1		1.8	-0.5	2.0	1.0	3.8
mx1-S parallel to SN	(mm)	3.6		5.2	0.3	2.6	0.5	6.1
mx1-S perpend to SN	(mm)	-0.2		1.6	-0.9	2.1	2.0	4.1
S-ANS parallel to SN	(mm)	3.9	l,m	2.6	-1.5	2.8	1.1	5.3
S-ANS perpend to SN	(mm)	-1.7		3.1	-0.4	2.1	1.5	4.0
Mx-Md Midline	(dg)	-0.1		4.3	0.0	2.4	0.7	2.2
Occlusal cant	(dg)	-0.5		4.0	0.4	2.7	-0.3	2.6

Table.2