

Is Estrogen Effective for Full-Thickness Cutaneous Wound Healing in Young Male Mice ?

| | |
|------------------------------|---|
| 著者 | Nakajima Yukari, Eno Yuka, Hirata Mariko, Kobori Sawako, Sugiura Ayano, Takeuchi Maiko, Taniguchi Miho, Tanisaki Megumi, Hayashi Asuka, Hikishima Keiko, Matsuo Naoki, Wada Natsumi, Mukai Kanae, Murakado Naoko, Okuwa Mayumi, Nakatani Toshio |
| journal or publication title | Wounds : a compendium of clinical research and practice |
| volume | 25 |
| number | 10 |
| page range | 278-286 |
| year | 2013-10-15 |
| URL | http://hdl.handle.net/2297/35866 |

Title Page

Is estrogen effective for full-thickness cutaneous wound healing in young male mice?

Short title: Young male mice and estrogen

Key word: estrogen, young male mouse, castration, cutaneous wound healing, testosterone,

Authors: Yukari Nakajima, RN; Yuka Eno, RN; Mariko Hirata, RN; Sawako Kobori, RN; Ayano Sugiura, RN; Maiko Takeuchi, RN; Miho Taniguchi, RN; Megumi Tanisaki, RN; Asuka Hayashi, RN; Keiko Hikishima, RN; Naoki Matsuo, RN; Natsumi Wada, RN; Kanae Mukai, RN, MSc; Naoko Murakado, RN, PhD; Mayumi Okuwa, RN, PhD; Toshio Nakatani, MD, PhD

Corresponding author: Professor Toshio Nakatani, MD, PhD Department of Clinical Nursing Graduate Course of Nursing Science Division of Health Sciences Graduate School of Medical Science Kanazawa University

5-11-80 Kodatsuno Kanazawa 9200942 Japan

nakatosi@staff.kanazawa-u.ac.jp

Abstract

The aim of this study is to show the effects of estrogen upon its topical application on the wound healing process in young male mice. Forty-nine male mice aged 7 weeks old were divided into four groups: sham operation, castration, estrogen treatment after sham operation and estrogen treatment after castration. Wound healing was observed daily until day 14 after wounding. Specimens were harvested on days 3, 7, 10 and 14, and stained to evaluate re-epithelialization, inflammation, contraction and collagen accumulation. Wound healing periods of all groups were almost the same, although the concentration of serum estrogen in the estrogen-applied mice was very high and that in the non-applied groups was low. The numbers of macrophages in the castrated, estrogen-treated after sham operation and estrogen-treated after castration groups were significantly decreased compared with that in the sham group in the inflammatory phase; however, the ratio of wound area in these groups did not decrease, and other histological data did not reveal any effects of estrogen. These results indicate that estrogen may show limited effectiveness for full-thickness cutaneous wound healing in young male mice, and decreased inflammation may not always be associated with decreased wound area.

Introduction

The skin, the largest organ in the body, undergoes numerous age-related structural and functional changes, including a delayed wound healing response. Delayed or failed healing of wounds poses a major problem, leading to increased morbidity and mortality, as well as increased costs for healthcare systems.¹

In recent years, the important role of hormones in age-related delayed healing has become apparent, and skin has emerged as a clear target of hormonal action. Cutaneous wounds heal more slowly in elderly males than in elderly females, suggesting a role of the sex hormones in the healing process.²⁻⁴ In the context of wound healing, hormonal factors act to mask underlying differences in repair. The influence on repair of intrinsic gender differences in such processes as tissue morphogenesis and perinatal hormonal imprinting may be exposed only when these hormonal factors are removed.⁵ Estrogens, especially 17β -estradiol, have long been known to accelerate healing in females:⁶ they decrease wound size,⁷ affect macrophages by reducing the production of a range of pro-inflammatory cytokines including interleukin 6 (IL-6), tumor necrosis factor- α (TNF- α) and macrophage migration inhibitory factor (MIF),^{1,5} stimulate keratinocyte proliferation, and accelerate re-epithelialization and fibroblasts, increasing dermal collagen production.¹ On the other hand, wounds in ovariectomized (OVX) mice, by virtue of negligible systemic estrogen, take substantially longer to heal and contain significantly increased numbers of inflammatory cells compared with intact mice.^{1,8}

In contrast, androgens inhibit wound healing in males. Testosterone, the major androgen in circulation, which is mostly produced by Leydig cells in the testis, appears to modulate healing by directly altering wound cell populations and cytokine profiles, thereby enhancing the inflammatory response and reducing matrix deposition.^{1,9} In addition, recent studies demonstrated that androgen receptor (AR) suppressed wound healing by enhancing the inflammatory response through a localized increase in TNF- α expression via multiple mechanisms, including increasing the inflammatory monocyte population, enhancing monocyte chemotaxis and enhancing TNF- α expression in macrophages.^{2,10} Castrated mice

with reduced systemic testosterone display accelerated healing through a dampened inflammatory response, increased matrix deposition, downregulation of TNF- α ^{3,4,11} and reduced wound area.^{5,9}

Many studies have suggested that estrogen promotes wound healing in females. However, there is little understanding of the roles of estrogen in wound healing in males. Ashcroft et al.⁷ reported that estrogen treatment decreased wound size and neutrophil numbers, and increased collagen levels in elderly human males. On the other hand, Gilliver et al.⁶ reported that sustained exposure to estrogen markedly delays wound re-epithelialization, while estrogen minimally influences wound inflammation and reduces collagen accumulation by increasing gelatinase activities in the wounds of estrogen-treated male mice. Therefore, the role of estrogens in males remains to be established, and further studies on this issue are necessary. Therefore, the aim of this study was to explore the effects of topically applied estrogen on the wound healing process in young male mice.

Methods

Animals

Fifty-six BALB/cCrSlc male mice aged 7 weeks (Sankyo Labo Service Corporation, Inc., Toyama, Japan) and weighing 16.9-21.8 g were used. They were caged individually in an air-conditioned room at 25.0 ± 2.0 °C with a 12 hour light/dark cycle. Water and laboratory chow were given ad libitum. The experimental protocol and animal care were in accordance with the Guidelines for the Care and Use of Laboratory Animals of Kanazawa University, Japan (AP-101739).

Wounding

Nine-week-old male mice that had undergone castration or sham operation 2 weeks previously were used for the experiments on wound healing. The mice were divided into four groups: sham-operated (Sham), castrated (CSX), sham-operated treated with 17β -estradiol (Sham+E) and CSX treated with 17β -estradiol (CSX+E). They were anesthetized by an intraperitoneal (IP) injection of pentobarbital sodium (0.05 mg/g weight) and the dorsum was shaved. Two circular (4 mm in diameter) full-thickness skin wounds including the panniculus carnosus muscle on both sides of the dorsum of the mouse were made with a Kai sterile disposable biopsy punch (Kai Industries, Gifu, Japan). Wounds were covered with hydrocolloid dressing (Tegaderm; 3M Health Care, Tokyo, Japan) to maintain a moist environment, and then mice were wrapped twice with adhesive bandages (Mesh pore tape; Nichiban, Tokyo, Japan). They were changed every day. Wound healing was observed daily until day 14 after wounding.

Estrogen treatment and measurement of hormone levels

0.01mL of 17β -estradiol gel (l'estrogele 0.06%; Bayer, Tokyo, Japan) was dribbled on the sterilization gauze of 28 mm x 10 mm in size by using 1mL syringe tube without needle, which was topically applied on the left abdominal side (not on the wound site) every day until day 14. The gauze was wrapped with adhesive bandage (Mesh pore tape; Nichiban, Tokyo, Japan) so that it did not slip out of position. Serum 17β -estradiol and testosterone

levels on day 14 were determined by radio immunoassay (Mitsubishi Chemical Medience Corporation, Tokyo, Japan) on each mouse. The limit of detection of serum estradiol was 10 pg/ml. Values of less than 10 pg/ml were regarded as 10 pg/ml.

Macroscopic observation

The day when wounds were made was designated as day 0, and the process of wound healing was observed from days 0 to 14 after wounding. Wounded edges were traced on polypropylene sheets and photographs were taken every day. The traces on the sheets were captured with a scanner onto a personal computer using Adobe Photoshop Elements 7.0 (Adobe System Inc., Tokyo, Japan), and the areas of wounds were calculated using image analysis software Scion Image Beta 4.02 (Scion Corporation, Frederick, Maryland, USA).

Tissue processing

On days 3, 7, and 10 after wounding, 3 mice from each group were euthanized by a massive pentobarbital sodium intraperitoneal injection. On day 14 after wounding, 5 mice from each group were euthanized using the same method. The wounds and the surrounding intact skin were harvested, stapled onto transparent plastic sheets to prevent over-contraction of specimens and fixed in 4% paraformaldehyde in 0.2 mol/L phosphate buffer (pH 7.4) for 15 hours. Specimens were dehydrated in an alcohol series, cleaned in xylene and embedded in paraffin to prepare 5 μ m serial sections. These sections were stained with hematoxylin-eosin (H & E) or subjected to Azan staining, and immunohistologically stained with anti-neutrophil antibody (Abcam Japan, Tokyo, Japan) for detecting neutrophils, anti-mouse Mac-3 antibody (BD Pharmingen, Tokyo, Japan) for detecting macrophages or anti- α -smooth muscle actin (α -SMA) antibody, prediluted (Abcam KK, Tokyo, Japan) for detecting myofibroblasts. The procedure for unmasking antigens was antigen-dependent, as detailed below.

Immunohistochemical staining

After deparaffinization and rehydration, antigen unmasking was accomplished by heating slides in a water bath containing sodium citrate buffer (10 mM sodium citrate, 0.05% Tween 20, pH 6.0) for 20 minutes near 100 °C. Slides for Mac-3 antibody and α -SMA were

washed with phosphate-buffered saline (PBS), and slides for anti-neutrophil antibody were washed with 0.3% TritonX-100 in PBS. Then, slides were incubated with anti-neutrophil antibody or Mac-3 antibody at a concentration of 1:100 in PBS, or undiluted anti- α -SMA at 4°C overnight. Slides were again washed with PBS or 0.3% TritonX-100 in PBS. For detection of primary antibodies, slides for Mac-3 antibody and anti-neutrophil antibody were incubated with polyclonal rabbit anti-rat immunoglobulins/HRP (Dako North America, Carpinteria, CA) at a concentration of 1:300 in 0.3% mouse serum (normal) (Dako North America, Carpinteria, CA) in PBS for 30 minutes at 4°C, and slides for α -SMA antibody were exposed to Dako Envision+System-HRP-labeled polymer anti-rabbit (ready to use) (Envision+ System- HRP Labelled Polymer Anti-Rabbit, Dako North America, Carpinteria, CA) for 30 minutes at room temperature. Slides were again washed with PBS or 0.3% TritonX-100 in PBS and then incubated in brown chromogen (Dako Liquid DAB+ Substrate Chromogen System, Dako North America, Carpinteria, CA) for 5 minutes or until staining was detected at room temperature. Light hematoxylin counterstaining for 1 minute was applied for visualization of cell nuclei. Finally, slides were rinsed in distilled water, dehydrated, cleared and mounted for analysis. Negative control slides were obtained by omitting each primary antibody.

Microscopic observations

In accordance with Haryanto et al.¹², for evaluation over the course of the wound healing process, photographic images were prepared, and quantifications of wound areas and the extent of re-epithelialization, as well as the cell numbers of each cell type per unit area (neutrophils and macrophages, central area of granulation tissue; myofibroblasts, average value from both edges of the wound and either top or bottom of the wound at $\times 400$ magnification), were undertaken using the microscope digital camera system (DP72, Olympus, Tokyo, Japan). Briefly, the wound area was defined as being the area bounded by the panniculus carnosus muscle at the base of the wound, the scab and migrating epithelium at the top of the wound and the margins of normal skin on either side. We measured the ratio of re-epithelialization (%) = length of new epithelium/length of wound between wound

edges, the number of neutrophils/mm² granulation tissue, macrophages/mm² granulation tissue, myofibroblasts/mm² granulation tissue, and the ratio of collagen fibers in granulation tissue = number of pixels of collagen fibers/number of pixels of granulation tissue area using Adobe Photoshop Element 7.0.

Statistical analysis

Data are expressed as mean \pm SD and analyzed with ANOVA and multiple comparison Tukey-Kramer using JMP 8.0.1 (SAS, Cary, NC). The differences were considered significant at $P < 0.05$.

Results

Serum estradiol and testosterone levels on day 14 (Table 1)

Estrogen-treated groups revealed significantly higher estradiol levels than the untreated groups: Sham+E and CSX ($p < 0.0001$), CSX+E and CSX ($p < 0.0001$), Sham+E and Sham ($p < 0.0001$), CSX+E and Sham ($p=0.0001$). These levels reached about three times those of the untreated groups (Table 1). Testosterone somewhat decreased in Sham+E on day 14 and this value was almost the same as in the castrated groups. There were trends between Sham and CSX ($p=0.06$), and Sham and CSX+E ($p=0.071$). These results suggest that estrogen treatment influences systemic androgen levels, while endogenous androgen does not affect exogenous estrogen levels.

Effect of estrogen on wound areas

In all groups, the wound healing processes seemed to be almost the same. New epithelium was observed at the wound edge on day 3 after wounding and, for some wounds, the whole wound surface was covered with new epithelium on day 10. On day 14, all wounds had completed re-epithelialization.

On days 0 to 14, the ratios of wound areas to the initial wound area on day 0 were calculated. The wound area of CSX+E significantly increased on day 1 after wounding (Figure 1). There were significant differences between Sham and CSX+E ($p < 0.0001$), CSX and CSX+E ($p=0.001$) and Sham+E and CSX+E ($p=0.003$). Wound areas in all groups increased after wounding. In Sham, the wound area peaked on day 4 at 1.04 ± 0.35 compared with that on day 0 after wounding, namely, initial wound area, and decreased gradually to 0.84 ± 0.40 on day 7 and 0.12 ± 0.06 on day 14. In CSX, the wound area peaked on day 2 after wounding at 1.12 ± 0.22 compared with the initial wound area, and decreased to 0.66 ± 0.14 on day 7 and 0.17 ± 0.06 on day 14. In Sham+E, wound area peaked on day 2 at 1.25 ± 0.25 compared with that on day 0 after wounding, and decreased to 0.82 ± 0.22 on day 7 and 0.18 ± 0.08 on day 14. In CSX+E, the wound area peaked on day 1 after wounding at 1.29 ± 0.27 compared with the initial wound area, and decreased rapidly to 0.74 ± 0.38 on day 7 and 0.12 ± 0.06 on day 14. There were no significant

differences between all groups on days 2 to 14.

Effect of estrogen on re-epithelialization (Figure 2)

There were no significant differences between all groups in terms of the ratio of re-epithelialization. On day 10 after wounding, the ratios of re-epithelialization were $91.3 \pm 17.4\%$ in Sham, $87.0 \pm 18.9\%$ in CSX, $100 \pm 0.0\%$ in Sham+E and $98.7 \pm 3.0\%$ in CSX+E.

Effect of estrogen on inflammation (Figure 3)

On day 3 after wounding, the number of neutrophils in CSX+E seemed to be lower than those of Sham, CSX and Sham+E (Figures 3A-E). There was a trend between Sham and CSX+E ($p=0.0926$) on day 3. On day 10, the numbers of neutrophils/mm² in Sham, CSX, Sham+E and CSX+E were 692.45 ± 523.33 , 663.92 ± 453.84 , 215 ± 226.65 and 85.59 ± 134.13 , respectively. There was a significant difference between Sham and CSX+E ($p=0.0463$), and a trend between CSX and CSX+E ($p=0.0607$) on day 10 (Figures 3F-I).

On day 3 after wounding, the numbers of macrophages/mm² in Sham, CSX, Sham+E and CSX+E were 1250.03 ± 235.71 , 762.47 ± 364.43 , 868.80 ± 230.26 and 894.73 ± 152.70 , respectively (Figure 3J). The numbers of macrophages in CSX, Sham+E and CSX+E seemed to be lower than that of Sham on day 3 (Figures 3K-N). There was a significant difference between only Sham and CSX ($p=0.0216$), and trends between Sham and Sham+E ($p=0.0707$), and Sham and CSX+E ($p=0.0996$), on day 3. On day 7, there were significant differences between Sham and CSX ($p=0.0248$), Sham and Sham+E ($p=0.0072$) and Sham and CSX+E ($p=0.0293$). There were no significant differences between all groups on days 10 and 14 (Figure 3O-R).

Effect of estrogen on contraction

On day 3 after wounding, a few myofibroblasts were observed along the wound edge in all groups (Figure 4A). On day 7, there were significant differences between Sham and CSX ($p=0.0175$), and CSX and CSX+E ($p=0.0029$). In this regard, CSX peaked on day 7, and the other groups did so on day 10 (Figures 4B-E). All groups decreased on day 14. There were no significant differences on days 3, 10 and 14.

Effect of estrogen on collagen accumulation

On day 3 after wounding, collagen fibers were already synthesized in all wounds (Figure 4F). There were significant differences between CSX and CSX+E ($p=0.0285$), and Sham+E and CSX+E ($p=0.0228$) on day 7 (Figures 4G-J), and between Sham and CSX ($p=0.0232$), and CSX and CSX+E ($p=0.0175$) on day 14 (Figures 4K-N). The ratio of collagen fibers in CSX+E rapidly increased (Figure 4J); however, it eventually decreased to half the peak value (Figure 4N). In CSX, it increased gradually and peaked on day 14 (Figure 4L).

Discussion

It is well known that estrogen has a beneficial effect on cutaneous wound healing in females.^{1,5-7,13} However, its effect in males have remained unclear¹³; one report stated a beneficial effect of estrogen,⁷ while another reported a limited effect.⁶

Although some amount of the 17 β -estradiol may be soaked up into the gauze, the serum estradiol levels in Sham+E and CSX+E groups are almost the same high as that in the proestrus of female mice, 20-30 pg/ml.¹⁴ Thus this indicates that the applied estradiol is absorbed enough to act on the wounds. Gilliver et al.⁶ reported that estrogen treatment from two weeks before wounding in 8-week-old male mice increased day 3 wound areas in intact male mice. Ashcroft et al.⁷ reported that estrogen treatment for 24 hours from wounding decreased wound size at day 7 in both elderly males and females. Our result revealed an increase in wound areas on day 1 in only CSX+E; subsequently, there were no significant differences between all groups (Figure 1). Considering these results, estrogen may be less effective at reducing wound areas, and it may increase wound area in castrated young male mice with low androgen levels. Moreover, Gilliver et al.⁶ reported that estrogen treatment greatly retarded wound re-epithelialization in castrated estrogen-treated mice compared with the level in castrated mice on day 3, while it did not affect the extent of re-epithelialization at that time in intact mice. In our results, there was no significant difference between all groups until day 14 (Figure 2A). This indicates that estrogen treatment does not retard or promote re-epithelialization in young male mice.

We evaluated the inflammation by counting the numbers of neutrophils and macrophages. According to Gilliver et al.⁶, the numbers of neutrophils were comparable in estrogen-treated and untreated castrated mice on day 3. Our result also supported this, and there were no significant differences between all groups on day 3 (Figure 3A). Estrogen impairs neutrophil chemotaxis, reducing the rate of migration to the wound site while increasing phagocytic function,¹ while testosterone increases the production of pro-inflammatory mediator, TNF- α , by macrophages via AR and wound TNF- α production is down-regulated by castration.¹⁵ These facts indicate that acute estrogen treatment

decreases the numbers of neutrophils in castrated mice during the inflammatory phase; however, our result did not show a reduction in neutrophil numbers. Therefore, estrogen treatment in young male mice may be less effective for decreasing neutrophil numbers. Similarly, estrogens inhibit macrophages' inflammatory functions.¹⁶ Gilliver et al.⁶ showed that macrophage population sizes were unaffected by estrogen, and Ashcroft et al.^{1,3} stated that estrogen affects macrophages by reducing the production of a range of pro-inflammatory cytokines including interleukin 6 (IL-6), tumor necrosis factor- α (TNF- α) and macrophage migration inhibitory factor (MIF). In review, chronic exposure of peritoneal macrophages to estradiol in vivo was shown to increase their subsequent secretion of IL-1 and IL-6.¹⁶ Our results showed the reduction of macrophage population size in estrogen-treated mice and castrated estrogen-treated mice (Figures 3J~N). In addition, CSX decreased the number of macrophages on days 3 and 7. Our study supported previous studies,²⁻⁴ and these findings show us that macrophages were regulated by both androgen and estrogen, in particular, estrogen treatment in young males. However, the ratio of wound area did not decrease in the inflammatory phase, which suggests that decreased inflammation may not always be an index of decreasing wound area.

In vitro preliminary studies suggest that estrogen stimulates fibroblast matrix production.⁷ However, Liman et al.¹⁷ reported that estradiol benzoate inhibits fibroblast proliferation in wound healing upon tracheal surgery by intramuscular administration for 4 weeks. In our results, the estrogen-treated group did not reveal an increase in myofibroblasts differentiated from fibroblasts; therefore, we think that estrogen treatment in young male mice has less effect on increasing myofibroblast numbers. On the other hand, castrated mice with reduced systemic testosterone display accelerated healing through a dampened inflammatory response and increased matrix deposition.⁴ The number of myofibroblasts in CSX peaked on day 7, and CSX significantly increased its number (Figure 4A). These data may indicate that the proliferation of myofibroblasts is promoted by castration rather than estrogen treatment.

We calculated the ratio of blue collagen fibers on Azan staining to evaluate tissue remodeling. Estrogens, especially 17β -estradiol, have long been known to increase dermal collagen production.¹ Our results revealed increased collagen deposition in CSX+E on day 7 (Figure 4F) and agreed with this previous study. However, this rate had decreased by about half on day 14 (Figures 4G-N) as opposed to the reduction of wound area. Gilliver et al.⁶ reported that the collagen of the lower dermis was highly disorganized in estrogen-treated castrated mice compared with that of castrated mice, which suggests that reduced wound collagen accumulation in estrogen-treated mice resulted from increased wound MMP-2 activity. Moreover, Liman et al.¹⁷ reported that estradiol benzoate inhibits massive collagen deposition in wound healing upon tracheal surgery by intramuscular administration. Therefore, it is suggested that estrogen reduces wound collagen accumulation in castrated estrogen-treated mice, but has less effect in estrogen-treated mice. This issue should be examined by further study.

In summary, we have shown the effects of estrogen upon its topical application during the wound healing process in male mice. Estrogen reduced macrophage number in the inflammatory phase; however, its effects did not lead to a reduction in wound area. Our results suggest that estrogen treatment in young male mice has less effect on the promotion of wound healing in terms of reducing wound area, promoting re-epithelialization, increasing contraction and accumulating collagen fibers.

Acknowledgements

The authors wish to thank Tamae Urai, MSN, Kanazawa University Hospital, Kanazawa, Japan, and Haryanto, MSN, The Muhammadiyah Institute of Nursing, Pontianak, Indonesia, for their useful advice regarding the experimental techniques. Part of this work was supported by a Grant-in-Aid for Scientific Research, Japan (no. 22592363).

References

1. Hardaman MJ, Ashcroft GS. Hormonal influences on wound healing: a review of current experimental data. *Wounds*. 2005;17:313-320.
2. Lai JJ, Lai KP, Chuang KH, et al. Monocyte/macrophage androgen receptor suppresses cutaneous wound healing in mice by enhancing local TNF-alpha expression. *J Clin Invest*. 2009;119:3739-3751.
3. Dao H, Kazin RA. Gender differences in skin: a review of the literature. *Gender Medicine*. 2007;4:308-328.
4. Ashcroft GS, Mills SJ. Androgen receptor-mediated inhibition of cutaneous wound healing. *J Clin Invest*. 2002;110:615-624.
5. Gilliver SC, Ruckshanthi JPD, Hardman MJ, et al. Sex dimorphism in wound healing: the roles of sex steroids and macrophage migration inhibitory factor. *Endocrinology*. 2008;149:5747-5757.
6. Gilliver SC, Emmerson E, Campbell L, et al. 17 β -Estradiol inhibits wound healing in male mice via estrogen receptor- α . *Am J Pathol*. 2010;176:2707-2721.
7. Ashcroft GS, Greenwell-Wild T, Horan MA, et al. Topical estrogen accelerates cutaneous wound healing in aged humans associated with an altered inflammatory response. *Am J Pathol*. 1999;155:1137-1146.
8. Routley CE, Ashcroft GS. Effect of estrogen and progesterone on macrophage activation during wound healing. *Wound Repair Regen* 2009;17:42-50.
9. Gilliver SC, Ashworth JJ, Mills SJ, Hardman MJ, Ashcroft GS. Androgens modulate the inflammatory response during acute wound healing. *J Cell Sci*. 2006;119:722-732.
10. Zouboulis ChC, Degitz K. Androgen action on human skin-from basic research to clinical significance. *Exp Dermatol*. 2004;13 (suppl. 4):5-10.
11. Gilliver SC, Ruckshanthi JPD, Atkinson SJ, Ashcroft GS. Androgens influence expression of matrix proteins and proteolytic factors during cutaneous wound healing. *Lab Invest*. 2007;87:871-881.
12. Haryanto, Urai T, Mukai K, et al. Effectiveness of Indonesian Honey on the acceleration

of cutaneous wound healing: an experimental study in mice. *Wounds*. 2012;24:110-119.

13. Gilliver SC, Ashcroft GS. Sex steroids and cutaneous wound healing: the contrasting influences of estrogens and androgens. *Climacteric*. 2007;10:276-288.

14. Nelson JF, Felicilo LS, Osterburg HH et al. Altered profiles of estradiol and progesterone associated with prolonged estrous cycles and persistent vaginal cornification in aging C57BL/6J mice. *Bio Rep* 1981;24:784-794.

15. Gilliver SC, Wu F, Ashcroft GS. Regulatory roles of androgens in cutaneous wound healing. *Thromb Haemost*. 2003;90:978-985.

16. Gilliver SC. Sex steroids as inflammatory regulators. *J Steroid Biochem Mol Biol*. 2010;120:105-115.

17. Liman ST, Kara CO, Bir F, et al. The effects of estradiol and progesterone on the synthesis of collagen in tracheal surgery. *Int J Pediatr Otorhinolaryngol*. 2005;69:1327-1331.

Tables**Table 1:** Serum estradiol and testosterone levels following topical application.

| | Sham | CSX | Sham+E | CSX+E |
|----------------------|---------------------------|---------------------------|---------------------------|---------------------------|
| Estradiol (pg/ml) | 12.67 ± 2.05 ^a | 11.17 ± 2.20 ^a | 37.33 ± 6.24 ^b | 36.67 ± 3.68 ^b |
| testosterone (ng/ml) | 6.61 ± 6.59 ^a | 0.28 ± 0.05 ^b | 0.35 ± 0.04 ^{ab} | 0.28 ± 0.12 ^b |

Values are expressed as mean ± SD. Statistical significance was determined by ANOVA and Tukey-Kramer. There are significant differences between “a” and “b” in the estradiol column and in the testosterone column ($P < 0.05$). The limit of detection for estradiol levels was 10 pg/ml. Less than 10 pg/ml was regarded as 10 pg/ml. n = 3 in sham, sham + E, and CSX + E; n = 5 in CSX for serum estradiol levels; n = 3 in sham; n = 5 in CSX, sham + E and CSX + E for serum testosterone levels.

Figure Legends

Figure 1

The ratio of wound area to initial area on day 0. Values are expressed as mean \pm SD, as determined by ANOVA and Tukey-Kramer $*p < 0.05$ $**p < 0.01$. n=8 in Sham, n=10 in CSX and CSX+E, n=6 in Sham+E.

Figure 2

Effect of estrogen on re-epithelialization. This graph shows the ratio of re-epithelialization. Values are expressed as mean \pm SD, ANOVA, Tukey-Kramer $*p < 0.05$ $**p < 0.01$. There were no significant differences between all groups. n=4-6 in Sham, n=4-7 in CSX, n=4-5 in Sham+E, n=5-7 in CSX+E.

Figure 3

Effects of estrogen on inflammation. Values are expressed as mean \pm SD, ANOVA, Tukey-Kramer $*p < 0.05$ $**p < 0.01$. A: The number of neutrophils in granulation tissues. n=5-7 in Sham, n=6-8 in CSX, n=5-6 in Sham+E, n=6-10 in CSX+E. B-I: Immunostaining for the neutrophil marker anti-neutrophil in day 3 and 10 wounds from all groups (B & F: Sham, C & G: CSX, D & H: Sham+E, E & I: CSX+E). J: The number of macrophages in granulation tissues. n=5-8 in Sham, n=5-8 in CSX, n=4-6 in Sham+E, n=5-6 in CSX+E. K-R: Immunostaining for the macrophage marker Mac-3 in day 7 and 10 wounds from all groups (K & O: Sham, L & P: CSX, M & Q: Sham+E, N & R: CSX+E). Arrows (B-I, K-R) identify cell immunostaining.

Figure 4

Effects of estrogen on contraction and collagen accumulation. Values are expressed as mean \pm SD, ANOVA, Tukey-Kramer $*p < 0.05$ $**p < 0.01$. A: The number of myofibroblasts in granulation tissues. n=4-6 in Sham, n=4-5 in CSX, n=4-6 in Sham+E, n=5-6 in CSX+E. B-E: Immunostaining for the myofibroblast marker α -SMA in day 7 wounds from all groups (B: Sham, C: CSX, D: Sham+E, E: CSX+E). Arrows (B-E) identify cell immunostaining. F: The ratio of collagen fibers in granulation tissues. n=4-5 in Sham, n=5-6 in CSX, n=3-5 in Sham+E, n=4-6 in CSX+E. G-N: Azan staining for collagen fibers in day 7 and 14 wounds

from all groups (G & K: Sham, H & L: CSX, I & M: Sham+E, J & N: CSX+E). Arrows (G-N) define the granulation margins.

Figures

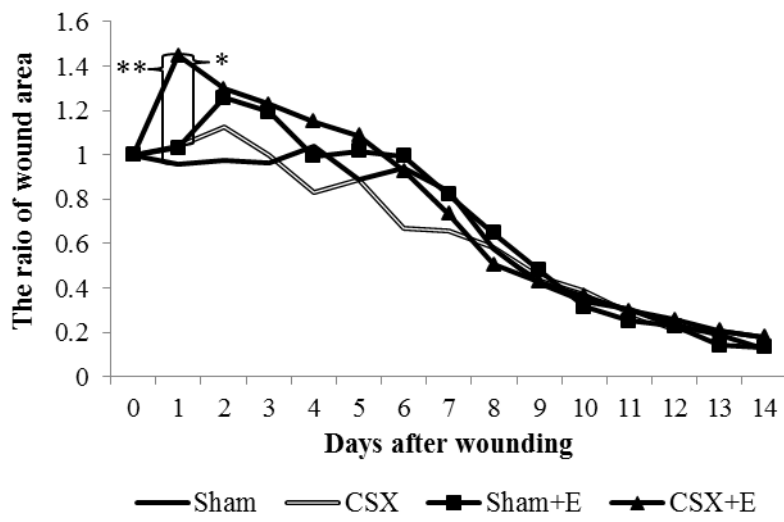


Figure 1

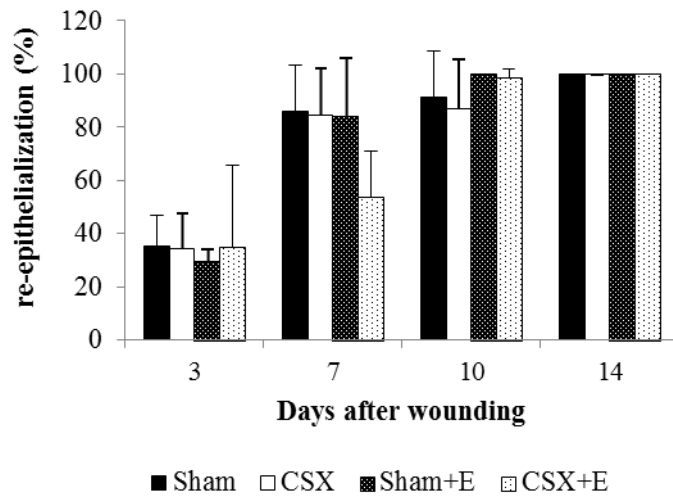


Figure 2

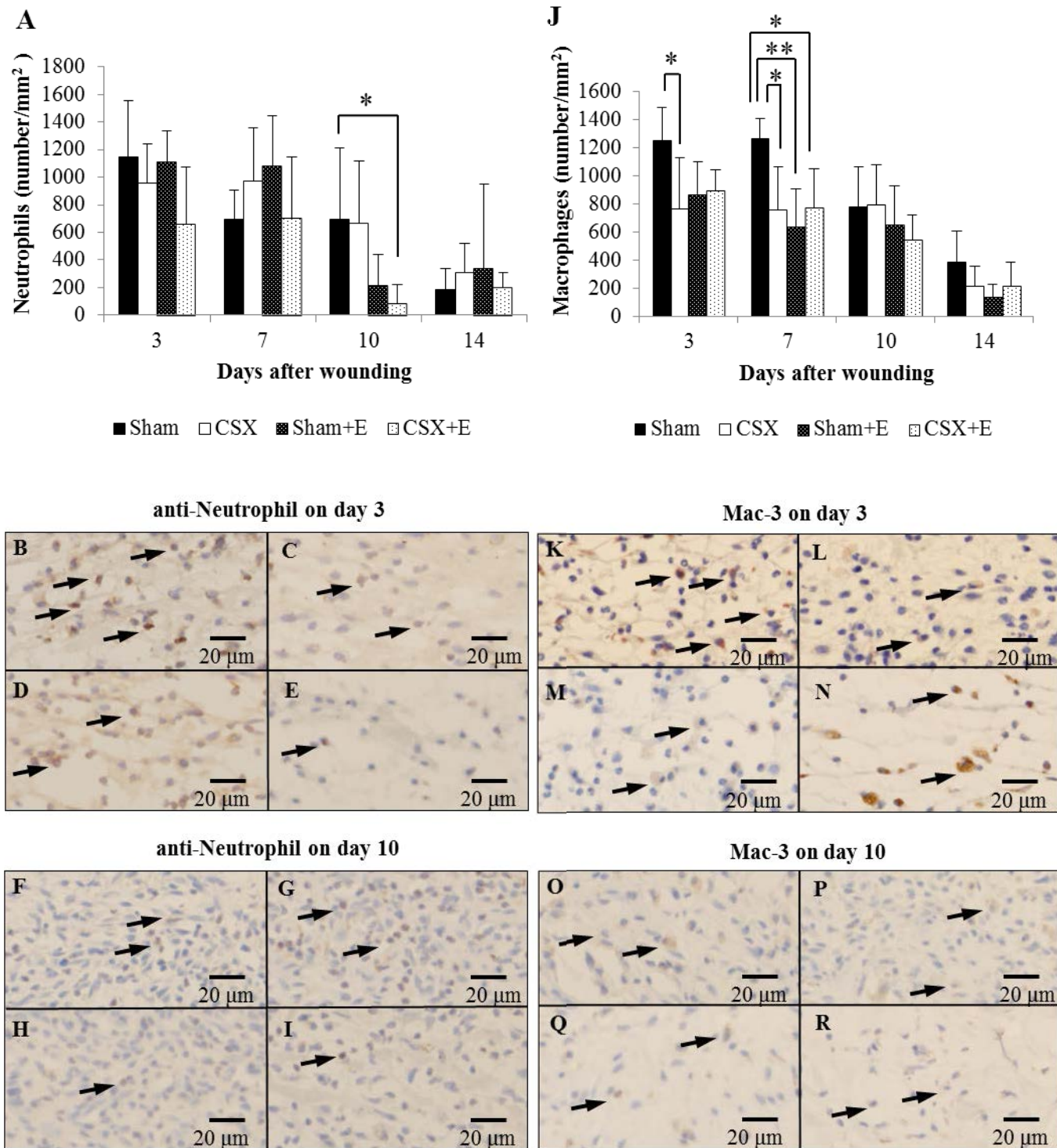
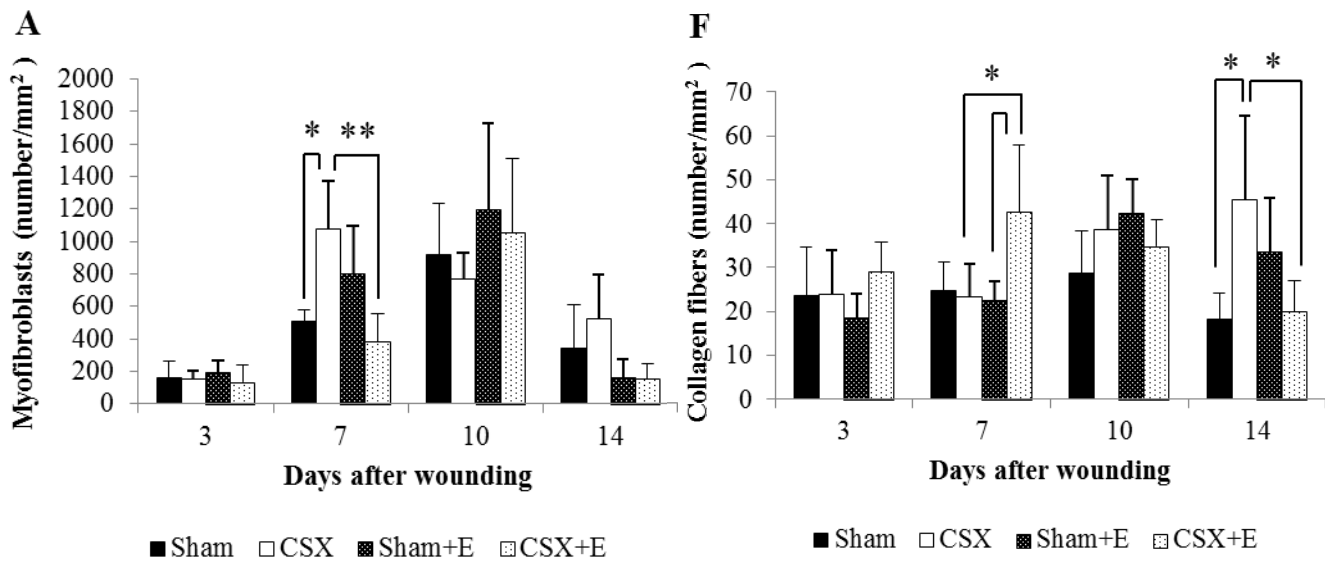
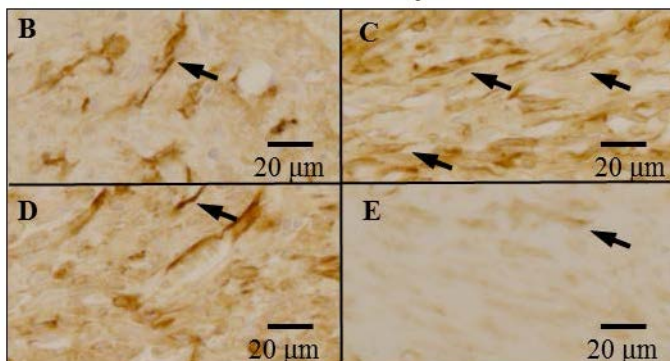


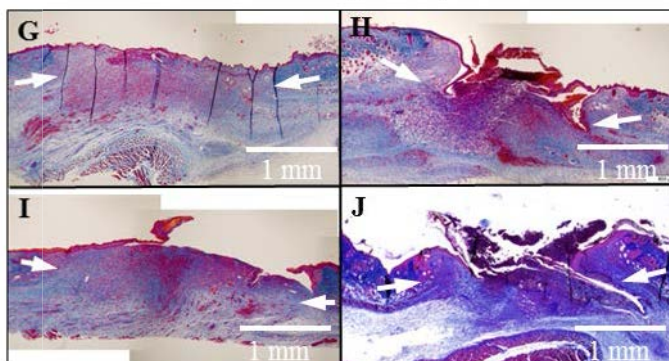
Figure 3



α -SMA on day 7



Azan staining on day 7



Azan staining on day 14

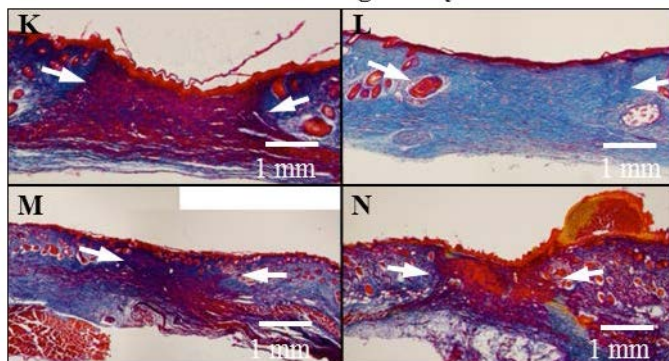


Figure 4