

# Relationship between the skeletal maturation of the distal attachment of the patellar tendon and physical features in preadolescent male football players

著者	Nakase Junsuke, Aiba Tomohiro, Goshima Kenichi, Takahashi Ryohei, Toratani Tatsuhiro, Kosaka Masahiro, Ohashi Yoshinori, Tsuchiya Hiroyuki
journal or publication title	Knee Surgery, Sports Traumatology, Arthroscopy
volume	22
number	1
page range	195-199
year	2014-01-01
URL	<a href="http://hdl.handle.net/2297/36490">http://hdl.handle.net/2297/36490</a>

doi: 10.1007/s00167-012-2353-3

**Relationship between the skeletal maturation of the distal  
attachment of the patellar tendon and physical features  
in preadolescent male football players**

Junsuke Nakase, Tomohiro Aiba, Kenichi Goshima,  
Ryohei Takahashi, Tatsuhiro Toratani, Masahiro Kosaka,  
Yoshinori Ohashi, Hiroyuki Tsuchiya

## ABSTRACT

**Purpose:** The aim of this study was to compare ultrasonography stages of the tibial tuberosity development and physical features.

**Methods:** This study examined 200 knees in 100 male football players aged 10 to 15 years. Tibial tuberosity development on ultrasonography was divided into 3 stages: Sonolucent stage (stage S), Individual stage (stage I), and Connective stage (stage C). Age, height, quadriceps and hamstring muscle tightness, and muscle strength in knee extension and flexion were determined. These findings were compared with the respective stages of development.

**Results:** The tibial tuberosity was stage S in 27 knees, stage I in 69 knees, and stage C in 104 knees, with right and left sides at the same stage in 95%. Average age and height significantly increased with advancing tibial tuberosity development. Quadriceps tightness increased with tibial tuberosity development. Hamstring tightness decreased with development. The strength of both knee extension and flexion increased with advancing development, with a greater change seen in knee extension; hamstring/quadriceps ratio: Stage C, 0.74; Stage A, 0.64; Stage E, 0.53.

**Conclusions:** Osgood–Schlatter pathogenesis reportedly involves increased quadriceps tightness with rapidly increasing femoral length during tibial tuberosity development. In this study, it was confirmed that quadriceps tightness increased, yet hamstring tightness decreased, suggesting that quadriceps tightness is not due to femoral length alone. Other factors, including muscle strength, may be involved. The study shows that thigh muscle tightness and thigh muscle performance change with the skeletal maturation of the distal attachment of the patellar tendon. These results add new information to the pathogenesis of Osgood–Schlatter disease.

Level of evidence: III (Cross-sectional study)

Key Words: Osgood–Schlatter disease, Ultrasonography, Physical features, lower limb muscle tightness, lower limb muscle strength

## Introduction

Osgood–Schlatter disease (OSD), named for the physicians that first described it in 1903 [15, 17], is a traction apophysitis of the tibial tuberosity caused by repetitive strain from the quadriceps muscle and chronic avulsion of the tibia. It may occur in either the preossification or ossified phase of the secondary ossification center. OSD is characterized by localized pain, swelling, and tenderness. It appears between the ages of 8 to 14 in girls, and 10 to 15 in boys, most commonly in children and adolescents who participate in sporting activities [2, 6]. Treatment is usually conservative, with medication, application of ice, protective knee padding and physical therapy to relieve pain [9]. It has been reported that symptoms tend to subside within 2 years and the prognosis is excellent in the majority of cases [9, 13]; however, Kaya et al reported that only half of patients totally recover according to ultrasonography results 2 years after diagnosis [11]. The most important considerations in OSD are prevention [14] and early diagnosis [9, 10], but in order to prevent a disorder, it is necessary to identify its risk factors [1]. An animal model of OSD has not been established, and the pathogenesis of OSD remains unknown.

Ultrasonography is effective in the early diagnosis of OSD [21]. It has been reported that early detection of OSD and conservative treatment can enable early return to sporting activities [9, 10]. Sonographic features include pretibial soft tissue swelling, cartilage swelling, fragmentation of the ossification center of the tibial tuberosity, thickening at the insertion of the patellar ligament, and inflammation of the deep infrapatellar bursa [3, 4]. Ultrasonography can also be used to observe the development of the tendon insertion (Achilles tendon insertion at the calcaneal tuberosity [8], and patellar tendon insertion at the tibial tuberosity [5, 21]). Ehrenborg et al. evaluated the tibial tuberosity radiographically and classified its development into 4 stages: cartilaginous stage, apophyseal stage, epiphyseal stage, and bony stage [7]. Ducher et al. used ultrasonography to classify development of the tibial tuberosity into 3 stages [5]. This classification includes the apophyseal stage of Ehrenborg's classification in the cartilaginous stage. The present study determined that development of tibial tuberosity cannot be examined in detail using this classification. The present study investigated the cause of Osgood–Schlatter disease by comparing subjects' physical features with stages that were created for a new classification of skeletal maturation of the distal attachment of the patellar tendon, defined by ultrasonography. The aim of this study was to compare ultrasonographic stages of the tibial tuberosity development and physical features of the subjects. The hypothesis was that thigh muscle

tightness and thigh muscle performance change with the skeletal maturation of the distal attachment of the patellar tendon.

### **Materials and Methods**

The subjects comprised 114 preadolescent male football players (soccer practice: 2 hours every day); 228 knees in subjects aged 10 to 15 years (mean,  $12.0 \pm 1.3$  years) were examined. The players were informed of the aims of the study and the procedures involved and, along with their parents, gave written informed consent. The study was reviewed and approved by the university ethics committee.

The skeletal maturation of the distal attachment of the patellar tendon was examined using ultrasonography. The HI VISION Avius (Hitachi Medical Corporation; Tokyo, Japan) and MyLabFive machines (Esaote; Genoa, Italy) were used with a 12 MHz (10–14 MHz) high-resolution linear probe, with musculoskeletal calibration. Subjects were in the supine position, with the back of the knee supported. A new ultrasonographic classification was created to evaluate the skeletal maturation of the distal attachment of the patellar tendon referred to by the Ehrenborg classification. Ultrasonography images of asymptomatic knees that are representative of the three stages of the maturation process of the patellar tendon insertion were used in the new classification system. The Sonolucet stage (Stage S) is characterized by a large amount of apophyseal cartilage (“Sonolucet”). The Individual stage (Stage I) is characterized by apophyseal cartilage with an “individual ossicle”. The Connective stage (Stage C) is characterized by a connection of the secondary ossification and tibial epiphysis (Figure 1). To investigate the relationship between the immature tibial tuberosity and subjects’ physical features, 13 boys who were affected by OSD and 1 boy who had completion of groove on ultrasonography were excluded. The study therefore involved 100 patients and 200 knees. To confirm the diagnosis of OSD, a patient had to fulfill all of the following clinical criteria: pain with direct pressure on the tibial apophysis; pain before, during, and after physical activities; enlargement or prominence of the tibial apophysis; pain with resisted knee extension; and pain with jumping. The following ultrasonographic findings were also required: delamination tear/fracture of the tibial tuberosity epiphysis; deep infrapatellar bursitis; and superficial infrapatellar bursitis.

In study participants, height was measured with a portable stadiometer using graduations of 0.1 cm. To assess the tightness of the quadriceps and hamstring muscles, respectively, heel-buttock distance (mm) in the prone position and straight-leg-raise angle (degrees) in the supine position were measured.

Quadriceps and hamstring tightness was measured by the following method. One examiner applied increasing force on the subject's lower limb until just before the examiner felt resistance. While the first examiner continued to apply the force, the second examiner made the measurements using a ruler and goniometer. The same examiner made all the measurements of lower limb muscle tightness. To assess muscle strength in knee extension and flexion, a hand-held dynamometer ( $\mu$ TAS-F1; ANIMA Co., Tokyo, Japan) was used with the subject in the seated position. A systematic review found that a hand-held dynamometer can be regarded as a reliable and valid instrument for assessment of muscle strength in a clinical setting [19]. No special warm up was performed. One practice trial was performed to measure muscle strength in each of the left and right lower limbs in knee extension and flexion. Subsequently, the muscle strength measurement was begun with a knee extension. There was a 30 s rest period after muscle strength was measured in knee extension. Next, muscle strength was measured in knee flexion. Measurements were made by one examiner. A dynamometer was placed on the distal third of the tibia during the measurement in knee extension. It was placed on the Achilles tendon area during the measurement in knee flexion. The maximum muscle strength was measured over 10 min. All measurements were made three times, and the mean value of the three trials was used for statistical analysis.

These physical findings were compared with the respective stages of tibial tuberosity development.

#### Statistical analysis

The data were analyzed with Statistical Package for the Social Sciences 19.0 (SPSS Inc., Chicago, IL, USA). One-way ANOVA and the Bonferroni correction were used for comparisons among the 3 groups. The level of significance for all statistical analyses was set at an  $\alpha$  value of 0.05.

### **Results**

The development of the tibial tuberosity was at Stage S in 27 knees, Stage I in 69 knees, and Stage C in 104 knees. The right and left sides were at the same stage of development in 95% of cases. The average age and height significantly increased with advancing development of the tibial tuberosity. Quadriceps tightness increased with the development of the tibial tuberosity. On the other hand, hamstring tightness decreased with tibial tuberosity development, measuring. The strength of both knee extension and knee flexion increased with advancing tibial tuberosity development. The change in muscle strength was greater in knee extension compared with flexion. The hamstring/quadriceps ratio was 0.74

in Stage S, 0.64 in Stage I, and 0.53 in Stage C (Table 1).

## **Discussion**

The most important finding of the present study was that thigh muscle tightness and thigh muscle performance change with the skeletal maturation of the distal attachment of the patellar tendon. This result was consistent with our hypothesis.

It is currently widely accepted that OSD is a traction apophysitis of the tibial tubercle, caused by overload/microfractures in the attachment of the patellar tendon [2, 3, 10]. The repetitive strain, in turn, is caused by the strong pull produced by the quadriceps muscle during sporting activities.

A number of studies have approached the importance of rectus femoris shortening [9, 14]. It is well known that the quadriceps femoris muscle contracts eccentrically during the stance phase of running until the beginning of propulsion when the knee reaches the highest level of flexion [16]. And shortening of the rectus femoris may substantially affect the biomechanical function of the knee with respect to the lever arm, peak torque, and discharge of compressive forces at 30° and 60° [9]. This study establishes the relationship between skeletal maturation of the distal attachment of the patellar tendon and lower limb muscle strength. In particular, the strength of knee extension increased dramatically between Stage I and Stage C. Furthermore, quadriceps tightness increased along with the development of the tibial tuberosity. It was concluded that partial avulsion of the secondary ossification center occurs because of this observed increase in muscular strength and quadriceps tightness. Although the increase in quadriceps tightness may be attributable to sudden growth in femur length, an increase in hamstring tightness should also have been seen; instead, a decrease was observed. There must be an explanation other than, or in addition to, femoral growth. The femoral neck detorsion that occurs around 5 years of age may influence and may influence muscle insertion and muscle fatigue. Further future investigation is planned.

Hirano et al. [10], evaluating magnetic resonance imaging studies, stated that some type of injury occurs in the secondary ossification center of the tibial tuberosity during apophyseal stage by Ehrenborg classification in patients with OSD. The injury leads to a crack which progresses to separation of the epiphysis from the tibial shaft. In our experience, medical examinations revealed no subjective or objective knee symptoms during Stage I, yet 1 month later OSD was diagnosed in 2 of these patients. In both patients, ultrasonographic findings at disease onset were characteristic of OSD

[4], the secondary ossification center was avulsed, and patients had progressed to Stage C. These results suggest that OSD is caused by overuse in the period from Stage I to Stage C [3, 9], and that the tibial tuberosity changes dramatically in the short period between these stages. Ultrasonography was beneficial to evaluate immature tibial tuberosity.

Muscle-tendon complexes are stretched as bones grow in length; adaptation occurs in which muscle fibers increase their numbers of sarcomeres. If the increase in sarcomeres does not catch up to the increase in bone length, muscle tightness is said to increase [12, 18], although this increase can be prevented by stretching [12]. This increase might have implications in avoiding OSD (for example, avoiding particular exercises and using stretching programs), but further studies are needed. If the timing of each stage, particularly Stage I, can be predicted from parameters such as the growth rate of height, it will be very useful in the prevention of OSD and medical examinations can become more effective.

This study has several limitations. The subjects of this study were soccer players who generally have high incidences of OSD. It is known that repeated mechanical stimulation may promote epiphyseal closure [20]. Most of the subjects played soccer for 2 hours every day. Thus, one limitation of this study was that the tibial tuberosity could have matured earlier than their chronological age would suggest. Another limitation is that quadriceps tightness was measured using HBD (heel-buttock distance). Therefore, the measured values could have changed depending on the muscle tone in the gluteal area, and accurate measurement might not have been made. Furthermore, test-retest reliability for HBD and straight-leg-raise angle were not confirmed. However, no study that examined the growth process of tibial tuberosity and the muscle strength and tightness of lower limbs has been previously reported. The clinical relevance of this study is that we can be useful in teaching quadriceps stretching in preadolescent male football players in stage I.

## **Conclusions**

The results of this study suggest that increased quadriceps tightness is not necessarily caused by increased femoral length alone. Various other factors may be involved, such as muscle strength in knee extension and flexion. The study shows that thigh muscle tightness and thigh muscle performance change with the skeletal maturation of the distal attachment of the patellar tendon.



## References

1. Bahr R, Krosshaug T (2005) Understanding injury mechanisms: a key component of preventing injuries in sport. *Br J Sports Med* 39: 324–329
2. Blankstein A, Cohen I, Heim M, Salai M, Checkick A, Ganel A (2001) Ultrasonography as a diagnostic modality in Osgood-Schlatter disease: A clinical study and review of the literature. *Arch Orthop Trauma Surg* 121:536–539
3. Czynny Z (2010) Osgood-Schlatter disease in ultrasound diagnostic – a pictorial essay. *Medical Ultrasonography* 12: 323–335
4. De Flaviis L, Nessi R, Scaglione P, Balconi G, Albisetti W, Derchi LE (1989) Ultrasonic diagnosis of Osgood-Schlatter and Sinding-Larsen-Johansson diseases of the knee. *Skeletal Radiol* 18: 193–197
5. Ducher G, Cook J, Spurrier D, Coombs P, Black J, Bass S (2010) Ultrasound imaging of the patellar tendon attachment to the tibia during puberty: a 12-month follow up in tennis players. *Scand J Med Sci Sports* 20: e35–e36
6. Dupuis CS, Westra SJ, Makris J, Wallace EC (2009) Injuries and conditions of the extensor mechanism of the pediatric knee. *Radiographics* 29:877–886
7. Ehrenborg G (1962) The Osgood-Schlatter lesion: a clinical study of 170 cases. *Acta Chir Scand* 124: 89–105
8. Grechenig W, Mayr JM, Peicha G, Hammerl R, Schtz B, Grechnig S (2004) Sonoanatomy of the Achilles tendon insertion in children. *J Clin Ultrasound* 32:338–43
9. Gholve PA, Scher DM, Khakharia S, Widmann RF, Green DW (2007) Osgood Schlatter syndrome. *Curr Opin Pediatr* 19:44–50
10. Hirano A, Fukubayashi T, Ishii T, Ochiai N (2002) Magnetic resonance imaging of Osgood-Schlatter disease: the course of the disease. *Skeletal Radiol* 31:334–342
11. Kaya DO, Toprak U, Baltaci G, Yosmaoglu B, Ozer H (2012) Long-term functional and sonographic outcomes in Osgood-Schlatter disease. *Knee Surg Sports Traumatol Arthrosc DOI* 10.1007/s00167-012-2116-1
12. Koh TJ, Herzog W (1998) Excursion is important in regulating sarcomere number in the growing rabbit tibialis anterior. *J Physiol* 508: 267–280

13. Krause BL, Williams JP, Catterall A (1990) Natural history of Osgood-Schlatter disease. *J Pediatr Orthop* 10: 65-68
14. Lucena GL, Gomes CS, Guerra RO (2011) Prevalence and associated factors of Osgood-Schlatter syndrome in a population-based sample of Brazilian adolescents. *Am J Sports Med* 39: 415–420
15. Osgood RB (1903) Lesions of the tibial tubercle occurring during adolescence. *Boston Med Surg J* 148:114–117
16. Sarcevic Z (2008) Limited ankle dorsiflexion: a predisposing factor to Morbus Osgood Schlatter? *Knee Surg Sports Traumatol Arthrosc* 16: 726–728
17. Schlatter C (1903) Verletzungen der schnabelformigen fortsatzes der oberen tibia epiphyse. *Beitr Klin Chir* 38:874–887
18. Simpson AH, Williams PE, Kyberd P, Goldspink G, Kenwright J (1995) The response of muscle to leg lengthening. *J Bone Joint Surg Br* 77: 630-636
19. Stark T, Walker B, Phillips JK, Fejer R, Beck R (2011) Hand-held dynamometry correlation with the gold standard isokinetic dynamometry: a systematic review. *PM R* 3: 472-9
20. Ueki M, Tanaka N, Tanimoto K, Nishio C, Honda K, Lin YY, Tanne Y, Ohkuma S, Kamiya T, Tanaka E, Tanne K (2008) The effect of mechanical loading in the metabolism of growth plate chondrocytes. *Ann Biomed Eng* 36:793-800
21. Vreju F, Ciurea P, Rosu A (2010) Osgood-Schlatter disease – ultrasonographic diagnostic. *Med Ultrason* 12:336–339

### **Legends of figures and tables**

Fig. 1 New ultrasonographic classification of tibial tuberosity development.

Table 1. Age, height, lower-limb muscle tightness and lower-limb muscle strength

## **ABSTRACT**

**Purpose:** The aim of this study was to compare ultrasonography stages of the tibial tuberosity development and physical features.

**Methods:** This study examined 200 knees in 100 male football players aged 10 to 15 years. Tibial tuberosity development on ultrasonography was divided into 3 stages: Sonolucent stage (stage S), Individual stage (stage I), and Connective stage (stage C). Age, height, quadriceps and hamstring muscle tightness, and muscle strength in knee extension and flexion were determined. These findings were compared with the respective stages of development.

**Results:** The tibial tuberosity was stage S in 27 knees, stage I in 69 knees, and stage C in 104 knees, with right and left sides at the same stage in 95%. Average age and height significantly increased with advancing tibial tuberosity development. Quadriceps tightness increased with tibial tuberosity development. Hamstring tightness decreased with development. The strength of both knee extension and flexion increased with advancing development, with a greater change seen in knee extension; hamstring/quadriceps ratio: Stage C, 0.74; Stage A, 0.64; Stage E, 0.53.

**Conclusions:** Osgood–Schlatter pathogenesis reportedly involves increased quadriceps tightness with rapidly increasing femoral length during tibial tuberosity development. In this study, it was confirmed that quadriceps tightness increased, yet hamstring tightness decreased, suggesting that quadriceps tightness is not due to femoral length alone. Other factors, including muscle strength, may be involved. The study shows that thigh muscle tightness and thigh muscle performance change with the skeletal maturation of the distal attachment of the patellar tendon. These results add new information to the pathogenesis of Osgood–Schlatter disease.

Level of evidence: III (Cross-sectional study)

Key Words: Osgood–Schlatter disease, Ultrasonography, Physical features, lower limb muscle tightness, lower limb muscle strength

## Introduction

Osgood–Schlatter disease (OSD), named for the physicians that first described it in 1903 [15, 17], is a traction apophysitis of the tibial tuberosity caused by repetitive strain from the quadriceps muscle and chronic avulsion of the tibia. It may occur in either the preossification or ossified phase of the secondary ossification center. OSD is characterized by localized pain, swelling, and tenderness. It appears between the ages of 8 to 14 in girls, and 10 to 15 in boys, most commonly in children and adolescents who participate in sporting activities [2, 6]. Treatment is usually conservative, with medication, application of ice, protective knee padding and physical therapy to relieve pain [9]. It has been reported that symptoms tend to subside within 2 years and the prognosis is excellent in the majority of cases [9, 13]; however, Kaya et al reported that only half of patients totally recover according to ultrasonography results 2 years after diagnosis [11]. The most important considerations in OSD are prevention [14] and early diagnosis [9, 10], but in order to prevent a disorder, it is necessary to identify its risk factors [1]. An animal model of OSD has not been established, and the pathogenesis of OSD remains unknown.

Ultrasonography is effective in the early diagnosis of OSD [21]. It has been reported that early detection of OSD and conservative treatment can enable early return to sporting activities [9, 10]. Sonographic features include pretibial soft tissue swelling, cartilage swelling, fragmentation of the ossification center of the tibial tuberosity, thickening at the insertion of the patellar ligament, and inflammation of the deep infrapatellar bursa [3, 4]. Ultrasonography can also be used to observe the development of the tendon insertion (Achilles tendon insertion at the calcaneal tuberosity [8], and patellar tendon insertion at the tibial tuberosity [5, 21]). Ehrenborg et al. evaluated the tibial tuberosity radiographically and classified its development into 4 stages: cartilaginous stage, apophyseal stage, epiphyseal stage, and bony stage [7]. Ducher et al. used ultrasonography to classify development of the tibial tuberosity into 3 stages [5]. This classification includes the apophyseal stage of Ehrenborg's classification in the cartilaginous stage. The present study determined that development of tibial tuberosity cannot be examined in detail using this classification. The present study investigated the cause of Osgood–Schlatter disease by comparing subjects' physical features with stages that were created for a new classification of skeletal maturation of the distal attachment of the patellar tendon, defined by ultrasonography. The aim of this study was to compare ultrasonographic stages of the tibial tuberosity development and physical features of the subjects. The hypothesis was that thigh muscle

tightness and thigh muscle performance change with the skeletal maturation of the distal attachment of the patellar tendon.

### **Materials and Methods**

The subjects comprised 114 preadolescent male football players (soccer practice: 2 hours every day); 228 knees in subjects aged 10 to 15 years (mean,  $12.0 \pm 1.3$  years) were examined. The players were informed of the aims of the study and the procedures involved and, along with their parents, gave written informed consent. The study was reviewed and approved by the university ethics committee.

The skeletal maturation of the distal attachment of the patellar tendon was examined using ultrasonography. The HI VISION Avius (Hitachi Medical Corporation; Tokyo, Japan) and MyLabFive machines (Esaote; Genoa, Italy) were used with a 12 MHz (10–14 MHz) high-resolution linear probe, with musculoskeletal calibration. Subjects were in the supine position, with the back of the knee supported. A new ultrasonographic classification was created to evaluate the skeletal maturation of the distal attachment of the patellar tendon referred to by the Ehrenborg classification. Ultrasonography images of asymptomatic knees that are representative of the three stages of the maturation process of the patellar tendon insertion were used in the new classification system. The Sonolucet stage (Stage S) is characterized by a large amount of apophyseal cartilage (“Sonolucet”). The Individual stage (Stage I) is characterized by apophyseal cartilage with an “individual ossicle”. The Connective stage (Stage C) is characterized by a connection of the secondary ossification and tibial epiphysis (Figure 1). To investigate the relationship between the immature tibial tuberosity and subjects’ physical features, 13 boys who were affected by OSD and 1 boy who had completion of groove on ultrasonography were excluded. The study therefore involved 100 patients and 200 knees. To confirm the diagnosis of OSD, a patient had to fulfill all of the following clinical criteria: pain with direct pressure on the tibial apophysis; pain before, during, and after physical activities; enlargement or prominence of the tibial apophysis; pain with resisted knee extension; and pain with jumping. The following ultrasonographic findings were also required: delamination tear/fracture of the tibial tuberosity epiphysis; deep infrapatellar bursitis; and superficial infrapatellar bursitis.

In study participants, height was measured with a portable stadiometer using graduations of 0.1 cm. To assess the tightness of the quadriceps and hamstring muscles, respectively, heel-buttock distance (mm) in the prone position and straight-leg-raise angle (degrees) in the supine position were measured.

Quadriceps and hamstring tightness was measured by the following method. One examiner applied increasing force on the subject's lower limb until just before the examiner felt resistance. While the first examiner continued to apply the force, the second examiner made the measurements using a ruler and goniometer. The same examiner made all the measurements of lower limb muscle tightness. To assess muscle strength in knee extension and flexion, a hand-held dynamometer ( $\mu$ TAS-F1; ANIMA Co., Tokyo, Japan) was used with the subject in the seated position. A systematic review found that a hand-held dynamometer can be regarded as a reliable and valid instrument for assessment of muscle strength in a clinical setting [19]. No special warm up was performed. One practice trial was performed to measure muscle strength in each of the left and right lower limbs in knee extension and flexion. Subsequently, the muscle strength measurement was begun with a knee extension. There was a 30 s rest period after muscle strength was measured in knee extension. Next, muscle strength was measured in knee flexion. Measurements were made by one examiner. A dynamometer was placed on the distal third of the tibia during the measurement in knee extension. It was placed on the Achilles tendon area during the measurement in knee flexion. The maximum muscle strength was measured over 10 min. All measurements were made three times, and the mean value of the three trials was used for statistical analysis.

These physical findings were compared with the respective stages of tibial tuberosity development.

#### Statistical analysis

The data were analyzed with Statistical Package for the Social Sciences 19.0 (SPSS Inc., Chicago, IL, USA). One-way ANOVA and the Bonferroni correction were used for comparisons among the 3 groups. The level of significance for all statistical analyses was set at an  $\alpha$  value of 0.05.

### **Results**

The development of the tibial tuberosity was at Stage S in 27 knees, Stage I in 69 knees, and Stage C in 104 knees. The right and left sides were at the same stage of development in 95% of cases. The average age and height significantly increased with advancing development of the tibial tuberosity. Quadriceps tightness increased with the development of the tibial tuberosity. On the other hand, hamstring tightness decreased with tibial tuberosity development, measuring. The strength of both knee extension and knee flexion increased with advancing tibial tuberosity development. The change in muscle strength was greater in knee extension compared with flexion. The hamstring/quadriceps ratio was 0.74

in Stage S, 0.64 in Stage I, and 0.53 in Stage C (Table 1).

## **Discussion**

The most important finding of the present study was that thigh muscle tightness and thigh muscle performance change with the skeletal maturation of the distal attachment of the patellar tendon. This result was consistent with our hypothesis.

It is currently widely accepted that OSD is a traction apophysitis of the tibial tubercle, caused by overload/microfractures in the attachment of the patellar tendon [2, 3, 10]. The repetitive strain, in turn, is caused by the strong pull produced by the quadriceps muscle during sporting activities.

A number of studies have approached the importance of rectus femoris shortening [9, 14]. It is well known that the quadriceps femoris muscle contracts eccentrically during the stance phase of running until the beginning of propulsion when the knee reaches the highest level of flexion [16]. And shortening of the rectus femoris may substantially affect the biomechanical function of the knee with respect to the lever arm, peak torque, and discharge of compressive forces at 30° and 60° [9]. This study establishes the relationship between skeletal maturation of the distal attachment of the patellar tendon and lower limb muscle strength. In particular, the strength of knee extension increased dramatically between Stage I and Stage C. Furthermore, quadriceps tightness increased along with the development of the tibial tuberosity. It was concluded that partial avulsion of the secondary ossification center occurs because of this observed increase in muscular strength and quadriceps tightness. Although the increase in quadriceps tightness may be attributable to sudden growth in femur length, an increase in hamstring tightness should also have been seen; instead, a decrease was observed. There must be an explanation other than, or in addition to, femoral growth. The femoral neck detorsion that occurs around 5 years of age may influence and may influence muscle insertion and muscle fatigue. Further future investigation is planned.

Hirano et al. [10], evaluating magnetic resonance imaging studies, stated that some type of injury occurs in the secondary ossification center of the tibial tuberosity during apophyseal stage by Ehrenborg classification in patients with OSD. The injury leads to a crack which progresses to separation of the epiphysis from the tibial shaft. In our experience, medical examinations revealed no subjective or objective knee symptoms during Stage I, yet 1 month later OSD was diagnosed in 2 of these patients. In both patients, ultrasonographic findings at disease onset were characteristic of OSD

[4], the secondary ossification center was avulsed, and patients had progressed to Stage C. These results suggest that OSD is caused by overuse in the period from Stage I to Stage C [3, 9], and that the tibial tuberosity changes dramatically in the short period between these stages. Ultrasonography was beneficial to evaluate immature tibial tuberosity.

Muscle-tendon complexes are stretched as bones grow in length; adaptation occurs in which muscle fibers increase their numbers of sarcomeres. If the increase in sarcomeres does not catch up to the increase in bone length, muscle tightness is said to increase [12, 18], although this increase can be prevented by stretching [12]. This increase might have implications in avoiding OSD (for example, avoiding particular exercises and using stretching programs), but further studies are needed. If the timing of each stage, particularly Stage I, can be predicted from parameters such as the growth rate of height, it will be very useful in the prevention of OSD and medical examinations can become more effective.

This study has several limitations. The subjects of this study were soccer players who generally have high incidences of OSD. It is known that repeated mechanical stimulation may promote epiphyseal closure [20]. Most of the subjects played soccer for 2 hours every day. Thus, one limitation of this study was that the tibial tuberosity could have matured earlier than their chronological age would suggest. Another limitation is that quadriceps tightness was measured using HBD (heel-buttock distance). Therefore, the measured values could have changed depending on the muscle tone in the gluteal area, and accurate measurement might not have been made. Furthermore, test-retest reliability for HBD and straight-leg-raise angle were not confirmed. However, no study that examined the growth process of tibial tuberosity and the muscle strength and tightness of lower limbs has been previously reported. The clinical relevance of this study is that we can be useful in teaching quadriceps stretching in preadolescent male football players in stage I.

## **Conclusions**

The results of this study suggest that increased quadriceps tightness is not necessarily caused by increased femoral length alone. Various other factors may be involved, such as muscle strength in knee extension and flexion. The study shows that thigh muscle tightness and thigh muscle performance change with the skeletal maturation of the distal attachment of the patellar tendon.



## References

1. Bahr R, Krosshaug T (2005) Understanding injury mechanisms: a key component of preventing injuries in sport. *Br J Sports Med* 39: 324–329
2. Blankstein A, Cohen I, Heim M, Salai M, Checkick A, Ganel A (2001) Ultrasonography as a diagnostic modality in Osgood-Schlatter disease: A clinical study and review of the literature. *Arch Orthop Trauma Surg* 121:536–539
3. Czynny Z (2010) Osgood-Schlatter disease in ultrasound diagnostic – a pictorial essay. *Medical Ultrasonography* 12: 323–335
4. De Flaviis L, Nessi R, Scaglione P, Balconi G, Albisetti W, Derchi LE (1989) Ultrasonic diagnosis of Osgood-Schlatter and Sinding-Larsen-Johansson diseases of the knee. *Skeletal Radiol* 18: 193–197
5. Ducher G, Cook J, Spurrier D, Coombs P, Black J, Bass S (2010) Ultrasound imaging of the patellar tendon attachment to the tibia during puberty: a 12-month follow up in tennis players. *Scand J Med Sci Sports* 20: e35–e36
6. Dupuis CS, Westra SJ, Makris J, Wallace EC (2009) Injuries and conditions of the extensor mechanism of the pediatric knee. *Radiographics* 29:877–886
7. Ehrenborg G (1962) The Osgood-Schlatter lesion: a clinical study of 170 cases. *Acta Chir Scand* 124: 89–105
8. Grechenig W, Mayr JM, Peicha G, Hammerl R, Schtz B, Grechnig S (2004) Sonoanatomy of the Achilles tendon insertion in children. *J Clin Ultrasound* 32:338–43
9. Gholve PA, Scher DM, Khakharia S, Widmann RF, Green DW (2007) Osgood Schlatter syndrome. *Curr Opin Pediatr* 19:44–50
10. Hirano A, Fukubayashi T, Ishii T, Ochiai N (2002) Magnetic resonance imaging of Osgood-Schlatter disease: the course of the disease. *Skeletal Radiol* 31:334–342
11. Kaya DO, Toprak U, Baltaci G, Yosmaoglu B, Ozer H (2012) Long-term functional and sonographic outcomes in Osgood-Schlatter disease. *Knee Surg Sports Traumatol Arthrosc DOI* 10.1007/s00167-012-2116-1
12. Koh TJ, Herzog W (1998) Excursion is important in regulating sarcomere number in the growing rabbit tibialis anterior. *J Physiol* 508: 267–280

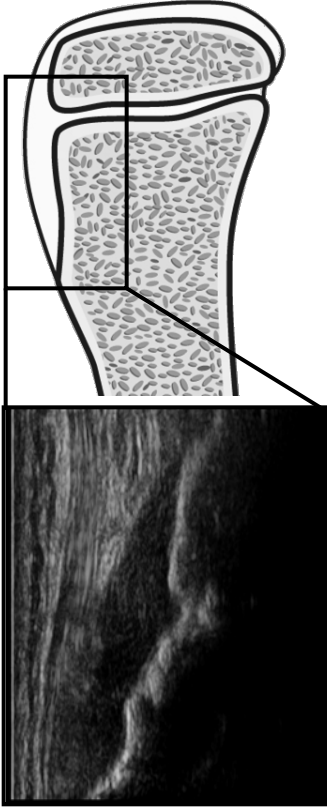
13. Krause BL, Williams JP, Catterall A (1990) Natural history of Osgood-Schlatter disease. *J Pediatr Orthop* 10: 65-68
14. Lucena GL, Gomes CS, Guerra RO (2011) Prevalence and associated factors of Osgood-Schlatter syndrome in a population-based sample of Brazilian adolescents. *Am J Sports Med* 39: 415–420
15. Osgood RB (1903) Lesions of the tibial tubercle occurring during adolescence. *Boston Med Surg J* 148:114–117
16. Sarcevic Z (2008) Limited ankle dorsiflexion: a predisposing factor to Morbus Osgood Schlatter? *Knee Surg Sports Traumatol Arthrosc* 16: 726–728
17. Schlatter C (1903) Verletzungen der schnabelformigen fortsatzes der oberen tibia epiphyse. *Beitr Klin Chir* 38:874–887
18. Simpson AH, Williams PE, Kyberd P, Goldspink G, Kenwright J (1995) The response of muscle to leg lengthening. *J Bone Joint Surg Br* 77: 630-636
19. Stark T, Walker B, Phillips JK, Fejer R, Beck R (2011) Hand-held dynamometry correlation with the gold standard isokinetic dynamometry: a systematic review. *PM R* 3: 472-9
20. Ueki M, Tanaka N, Tanimoto K, Nishio C, Honda K, Lin YY, Tanne Y, Ohkuma S, Kamiya T, Tanaka E, Tanne K (2008) The effect of mechanical loading in the metabolism of growth plate chondrocytes. *Ann Biomed Eng* 36:793-800
21. Vreju F, Ciurea P, Rosu A (2010) Osgood-Schlatter disease – ultrasonographic diagnostic. *Med Ultrason* 12:336–339

### **Legends of figures and tables**

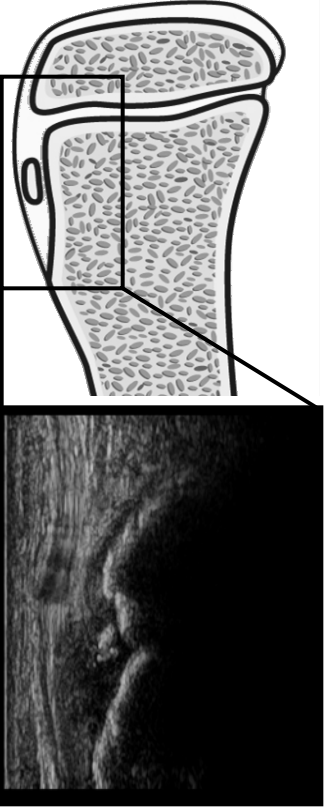
Fig. 1 New ultrasonographic classification of tibial tuberosity development.

Table 1. Age, height, lower-limb muscle tightness and lower-limb muscle strength

Sonolucent stage



Individual stage



Connective stage

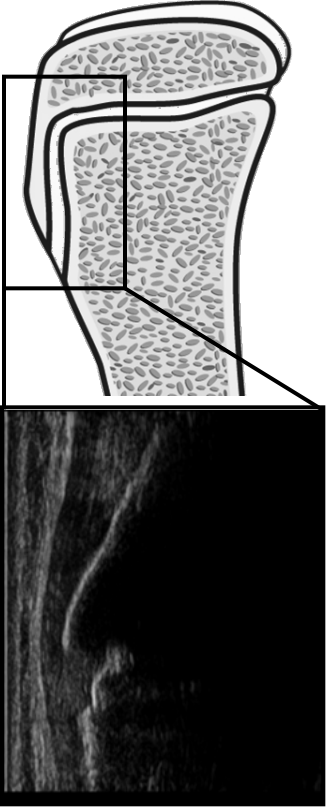


Figure 1

\**P* < 0.05

	Lower-limb muscle tightness				Lower-limb muscle strength		H/Q ratio
	Age (years)	Height (cm)	Quadriceps (mm)	Hamstrings (degree)	Knee extension (N)	Knee flexion (N)	
Stage S (27 knees)	10.7 ± 0.7 *	136.9 ± 4.5 *	16 ± 20 *	67 ± 11 *	158 ± 61 *	108 ± 32 *	0.74 *
Stage I (69 knees)	11.3 ± 0.9 *	* 145.0 ± 7.4 *	* 20 ± 31 *	* 72 ± 10 *	* 202 ± 60 *	* 123 ± 31 *	* 0.64 *
Stage C (104 knees)	12.8 ± 1.0	156.9 ± 7.8	33 ± 30	79 ± 11	308 ± 92	156 ± 35	0.53

Table 1