

# Acute correction using focal dome osteotomy for deformity about knee joint

著者	Watanabe Koji, Tsuchiya Hiroyuki, Sakurakichi Keisuke, Matsubara Hidenori, Tomita Katsuro
journal or publication title	Archives of Orthopaedic and Trauma Surgery
volume	128
number	12
page range	1373-1378
year	2008-01-01
URL	<a href="http://hdl.handle.net/2297/12410">http://hdl.handle.net/2297/12410</a>

doi: 10.1007/s00402-008-0574-1

## **Acute correction using focal dome osteotomy for deformity around the knee joint**

Koji Watanabe, Hiroyuki Tsuchiya, Keisuke Sakurakichi, Hidenori Matsubara, Katsuro Tomita

Department of Orthopaedic Surgery, Graduate School of Medical Science,  
Kanazawa University  
920-8641, 13-1 Takara-machi, Kanazawa, Japan

Running title: Acute correction for deformity around the knee

Correspondence to Hiroyuki Tsuchiya, MD, PhD  
Department of Orthopaedic Surgery, Graduate School of Medical Science,  
Kanazawa University,  
920-8641, 13-1 Takara-machi, Kanazawa, Japan  
Phone: +81-76-265-2373, Fax: +81-76-234-4261,  
E-mail: [tsuchi@med.kanazawa-u.ac.jp](mailto:tsuchi@med.kanazawa-u.ac.jp)

## **ABSTRACT**

**Background:** Correction of deformities around the knee joint may prevent or delay the onset of osteoarthritis or mitigate its effects. Accurate correction of such deformities without production of secondary deformities depends on precise localization and quantification of the deformities.

**Methods:** We corrected deformities around the knee using acute correction with focal dome osteotomy in 21 segments (15 patients). Five segments underwent limb lengthening postoperatively.

**Results:** The mean correction angle was 16.0°. We were able to correct all segments. In the five lengthening cases, the mean external fixation index (EFI) was 70.9 days/cm, which is much higher than the generally reported EFI. There were eight complications, all but one of which occurred in lengthening cases.

**Conclusions:** We believe that acute correction with focal dome osteotomy is very useful for cases of alignment correction, but is not indicated for cases of alignment correction with lengthening, due to a high risk of complications related to poor callus formation.

## **INTRODUCTION**

Deformities around the knee joint are frequently observed secondary to growth plate injury or congenital bone disease. Currently, the most common method for correcting these deformities is the center of rotation of angulation (CORA) method developed by Paley et al.<sup>1,2</sup> By determining the CORA and using the Ilizarov technique with a hinge system guide, deformities can be accurately corrected. Both traditional transverse osteotomy and focal dome osteotomy can be performed based on CORA measurements. Focal dome osteotomy is a cylindrically shaped osteotomy, with corresponding bone cuts rotating around the central axis of the deformity. This method provides high adjustability of the bone ends, optimal bone contact, and high primary stability. Therefore, focal dome osteotomy is more effective than transverse osteotomy for acute deformity correction, particularly for deformity around the knee joint.<sup>3</sup> In addition, postoperative management using an external fixator is relatively simple, as no deformity correction is required. In this study, we report our experience with using acute correction with focal dome osteotomy for deformity around the knee joint.

## **PATIENTS AND METHODS**

Between 1995 and 2004, 16 patients (5 males and 10 females) with deformities around the knee joint were treated with acute correction using focal dome osteotomy at the authors' institution. The mean age at surgery was 31 years (range, 6-68 years). A total of 21 lower limb segments were treated, including 5 femurs and 16 tibias. Five patients underwent bilateral tibial correction. All segments underwent acute correction during surgery using focal dome osteotomy, and were fixed with an Ilizarov external fixator (Smith and Nephew, Memphis,

Tennessee, USA). To prevent compromising patellofemoral function and to reduce the risk of intra-articular fractures, all tibial osteotomies were performed below the tibial tuberosity. Five segments underwent limb lengthening postoperatively at a rate of 0.5 to 1.0 mm/day at the same site as the deformity correction. Deformity etiology included osteoarthritis of the knee joint in four segments (3 patients), Blount's disease in five segments (3 patients), and growth plate injury in nine segments (9 patients); in addition, one segment in 1 patient had metaphyseal chondrodysplasia, and two segments in 1 patient caused short stature. A total of 17 segments had a frontal plane deformity, including 12 varus and 5 valgus deformities; 4 segments had a sagittal plane deformity, including 3 recurvatum and 1 procurvatum deformities. All segments had a monoplane deformity. Sites of deformity included the distal femur in 5 segments and proximal tibia in 16 segments (Table 1). The amount of deformity correction, length gained, external fixation time (EFT), external fixation index (EFI), angulation correction combined with limb lengthening, and all complications were reviewed. The EFI was obtained by dividing the total duration of external fixation by the length gained.

### **Surgical Technique**

A malalignment test was used to determine the joint alignment and joint orientation in a standing position, with anteroposterior and lateral radiographs taken from the hip to the ankle.<sup>1,2</sup> We determined the CORA based on these radiographs. The Ilizarov frames were constructed preoperatively and applied with the hinge at the level of the CORA. Using one ring in the periarticular segment, we inserted at least four wires at different heights and directions in all cases to increase frame stability. For focal dome osteotomies, multiple K-wire holes were drilled in a semicircular pattern based on the CORA and were then connected using a chisel. The hinge system was replaced by straight rods postoperatively after confirming the mechanical axis passed through the planned point at the level of the knee joint, and full weight bearing was permitted. All osteotomies were performed at the metaphyseal

level, which has great osteogenic potential (Fig. 1).

## **RESULTS**

The mean deformity correction angle was 16.0° (range, 5°-37°). The mean amount of deformity correction without limb lengthening was 15.3° (range, 6°-37°), and that with limb lengthening was 14.0° (range, 5°-22°). All deformities were corrected as planned. There was no loss of correction after the procedure. The mean EFT was 172.4 days (range, 67-498 days). The EFT without limb lengthening was 112.8 days (range, 67-227 days) and that with limb lengthening was 351.0 days (range, 258-498 days). Average lengthening was 4.9 cm (range, 4.3-5.5 cm) in five segments. The average EFI was 70.9 days/cm (range, 59.8–90.5 days/cm). There were no deep infections. There were eight complications: three pin-tract infections, three delayed unions, one knee joint contracture, and one transient peroneal nerve palsy. Pin-tract infections were treated successfully with oral antibiotics. Delayed unions were treated with low-intensity pulsed ultrasound, and there was no bone grafting. One patient developed a transient peroneal nerve palsy following acute correction, but function recovered completely without treatment. All complications except for one delayed union occurred in cases of limb lengthening (Table 2).

### **Case Reports**

#### **Case 1**

A 19-year-old female suffered from bilateral varus deformities of the proximal tibia resulting from bilateral Blount's disease. The medial proximal angle was 80° on the right side and 76° on the left side, and the mechanical axis line at the level of the knee joint was 20.5% from the medial edge on the right side and 10.8% on the left side. The CORA was at the

epiphysis, so focal dome osteotomy and acute deformity correction were performed. The external fixation time was 104 days. The mechanical axis at the level of the knee joint improved to 53.8% on the right side and 50.0% on the left side. Physiologic limb alignments were restored (Fig. 2).

## **Case 2**

A 15-year-old male suffered from developing valgus deformity of the left distal femur and limb shortening resulting from growth plate injury. The mechanical lateral distal femoral angle was 65° and limb length discrepancy was 40 mm. The CORA was at the epiphysis, so focal dome osteotomy and acute deformity correction were performed. After a 1-week latency period, gradual lengthening was initiated at a rate of 0.5 mm/day. The external fixation time was 239 days and the external fixation index was 59.8 days/cm. Physiologic limb alignment was achieved, with limb length restored (Fig. 3).

## **DISCUSSION**

Realigning the mechanical axis and joint orientation around the knee joint by metaphyseal osteotomy requires a combination of angulation and translation. However, conventional surgical treatment,<sup>4-8</sup> such as a closing wedge, opening wedge, or dome-shape osteotomy with internal fixation, cannot precisely correct angulation and translation because the levels of the center of the deformity and the correction are different. When osteotomy is performed at a level different from that of the CORA and the angular correction is performed around a point on the osteotomy line, a translational deformity may be created. Thus, while conventional surgical treatment can correct the mechanical axis, it cannot correct the joint orientation angle. Paley et al. reported that the CORA method is highly effective for restoring

the mechanical axis and achieving correct joint orientation.<sup>1-3</sup> By determining the CORA and using the Ilizarov technique with a hinge system guide, deformities can be accurately corrected. For deformity correction around the knee joint, the CORA is located near or outside the joint; therefore, the osteotomy cannot be performed at the CORA. Acute correction using transverse osteotomy is not preferable for deformity around the knee joint, because the amount of bony contact after deformity correction at the osteotomy site is too small. Instead, acute correction with focal dome osteotomy is preferred, because it increases the bony contact after deformity correction at the osteotomy surface, which theoretically facilitates early union and decreases the period of external fixation wear.<sup>9</sup> Thus, focal dome osteotomy based on the CORA method is most effective for acute correction. However, in cases with a longer radius of focal dome osteotomy or a larger deformity correction angle, the bony contact after deformity correction would be smaller, thereby increasing the risk of delayed union or nonunion. In these cases, gradual correction would be indicated.

In our study, the average EFI for lengthening following acute correction with focal dome osteotomy was 70.9 days/cm, which is much higher than that reported in the literature (30-60 days/cm),<sup>10-12</sup> and all complications except for one occurred in lengthening cases. Kamegaya et al.<sup>13</sup> reported that the healing index with limb lengthening following acute correction was 32.6 days/cm; however, these investigators performed this procedure for skeletally immature segments (mean age, 12.0 years; range, 4.8-15.3 years) that had great osteogenic potential. Noonan et al.<sup>14</sup> reported that with acute deformity correction and subsequent gradual lengthening, skeletally mature segments (>13.8 years old) had statistically significant decreased bone formation, increased prevalence of callus complications, and a higher healing index than immature segments. The higher EFI and complication rate in our lengthening cases following acute correction with focal dome osteotomy were most likely due to the fact that segments were skeletally mature (mean age, 22.0 years; range, 12-35 years)



and the periosteum may have been disrupted due to dome-shape osteotomy and acute correction.

Based on this experience, we conclude that acute correction with focal dome osteotomy is suitable for segments without limb length discrepancy, while for segments with limb length discrepancy, particularly mature segments, gradual correction and limb lengthening should be considered.

## REFERENCES

1. Paley D, Tetsworth K. Mechanical axis deviation of the lower limbs: preoperative planning of uniapical angular deformities of the tibia or femur. *Clin Orthop* 1992;280:48–64.
2. Paley D, Tetsworth K. Mechanical axis deviation of the lower limbs: preoperative planning of multiapical frontal plane and angular bowing deformities of the femur and tibia. *Clin Orthop* 1992;280:65–71.
3. Paley D, Maar DC, Herzenberg JE. New concepts in high tibial osteotomy for medial compartment osteoarthritis. *Orthop Clin North Am* 1994;25:483-98.
4. Loder RT, Schaffer JJ, Bardenstein MB. Late-onset tibia vara. *J Pediatr Orthop* 1991;11:162–7.
5. Scheffer MM, Peterson HA. Opening-wedge osteotomy for angular deformities of long bones in children. *J Bone Joint Surg Am* 1994;76:325–34.
6. Smith DN, Harrison MHM. The correction of angular deformities of long bones by osteotomy-osteoclasia. *J Bone Joint Surg Br* 1979;61:410–4.
7. Henderson RC, Kemp GJ Jr, Greene WB. Adolescent tibia vara: alternatives for operative treatment. *J Bone Joint Surg Am* 1992;74:342–50.
8. Maquet P. The treatment of choice in osteoarthritis of the knee. *Clin Orthop* 1985;192:108–12.
9. Sakurakichi K, Tsuchiya H, Kabata T, Yamashiro T, Watanabe K, Tomita K. Correction of juxtaarticular deformities in children using the Ilizarov apparatus. *J Orthop Sci* 2005;10:360-366.
10. Tsuchiya H, Uehara K, Abdle-Wanis ME, Sakurakichi K, Tamon K, Tomita K. Deformity correction followed by lengthening with the Ilizarov method. *Clin Orthop*

2002;402:176–83.

11. Sakurakichi K, Tsuchiya H, Uehara K, et al: The relationship between distraction length and treatment indices during distraction osteogenesis. *J Orthop Sci.* 7(3):298-303, 2002.
12. Donnan LT, Saleh M, Rigby AS: Acute correction of lower limb deformity and simultaneous lengthening with a monolateral fixator. *J Bone Joint Surg Br.* 85(2):254-60, 2003.
13. Kamegaya M, Shinohara Y, Shinada Y. Limb lengthening and correction of angulation deformity: immediate correction by using a unilateral fixator. *J Pediatr Orthop* 1996;16:477–9.
14. Noonan KJ, Price CT, Sproul JT, Bright RW. Acute correction and distraction osteogenesis for the malaligned and shortened lower extremity. *J Pediatr Orthop* 1998;18:178–86.

**Table 1. Patient demographics**

Case	Limb	Age/ Sex	Diagnosis	Def.	Site	Angle (°)	Length (cm)	EFT (days)	EFI (days/cm)	Complication
1	1	56/F	OA	Var.	P	17		95		
	2									
2	3	64/F	OA	Var.	P	7		112		
3	4	59/M	OA	Var.	P	13		104		
4	5	10/F	Blount's disease	Var.	P	7		106		
	6									
5	7	19/F	Blount's disease	Var.	P	7		104		
	8									
6	9	20/F	Blount's disease	Var.	P	14		227		Delayed union
7	10	18/M	GPI	Pro.	D	27		139		
8	11	17/F	GPI	Val.	D	11		84		
	12									
9	13	42/F	GPI	Re.	P	28		128		
10	14	18/F	GPI	Val.	D	13		81		
11	15	6/F	MCD	Var.	P	10		67		
12	16	68/M	GPI	Re.	P	37		168		
13	17	18/M	GPI	Re.	P	21	43	258	60.0	Peroneal nerve palsy
14	18	35/F	GPI	Val.	P	15	50	328	65.6	Pin-tract infection Contracture
15	19	15/M	GPI	Val.	D	22	40	239	59.8	
16	20	21/M	Short stature	Var.	P	7	55	432	78.5	Pin-tract infection Delayed union
	21									

OA, osteoarthritis of knee joint; GPI, growth plate injury;  
MCD, metaphyseal chondrodysplasia; Def., deformity; Var., varus; Val., valgus;  
Re., recurvatum; Pro., procurvatum; P, proximal tibia; D, distal femur;  
EFT, external fixation time; EFI, external fixation index

**Table 2. Overall results and comparison between segments without and with lengthening**

Parameter	Overall (n=21)	Without lengthening (n=16)	With lengthening (n=5)
Mean correction, ° (range)	15.0 (5-37)	15.3 (6-37)	14.0 (5-22)
External fixation time, days (range)	172.4 (67-498)	112.8 (67-227)	351.0 (258-498)
Mean length gained, cm (range)			4.9 (4.3-5.5)
External Fixation Index, days/cm			70.9
Complications	8	1	7

## FIGURE LEGENDS

**Fig. 1.** Illustrations and photographs showing the treatment course of acute correction with focal dome osteotomy.

**Step 1.** The malalignment test.

**Step 2.** Ilizarov frames construction with the hinge at the level of the CORA.

**Step 3.** For focal dome osteotomies, multiple K-wire holes were drilled in a semicircular pattern based on the CORA, and were then connected using a chisel.

**Step 4.** Acute correction during the operation.

**Step 5.** The hinge system was replaced by straight rods postoperatively after confirming that the mechanical axis passed through the planned point at the level of the knee joint.

CORA: center of rotation of angulation

**Fig. 2.** Case 1: 19-year-old female with bilateral varus deformities of the proximal tibia resulting from bilateral Blount's disease.

**A.** Anteroposterior radiographs of the lower limb, taken with the patient standing, showing varus alignment of the lower limb.

**B.** Schematic diagram showing the correction procedure strategy.

**C.** Anteroposterior radiograph after acute correction with focal dome osteotomy and the Ilizarov external fixator application.

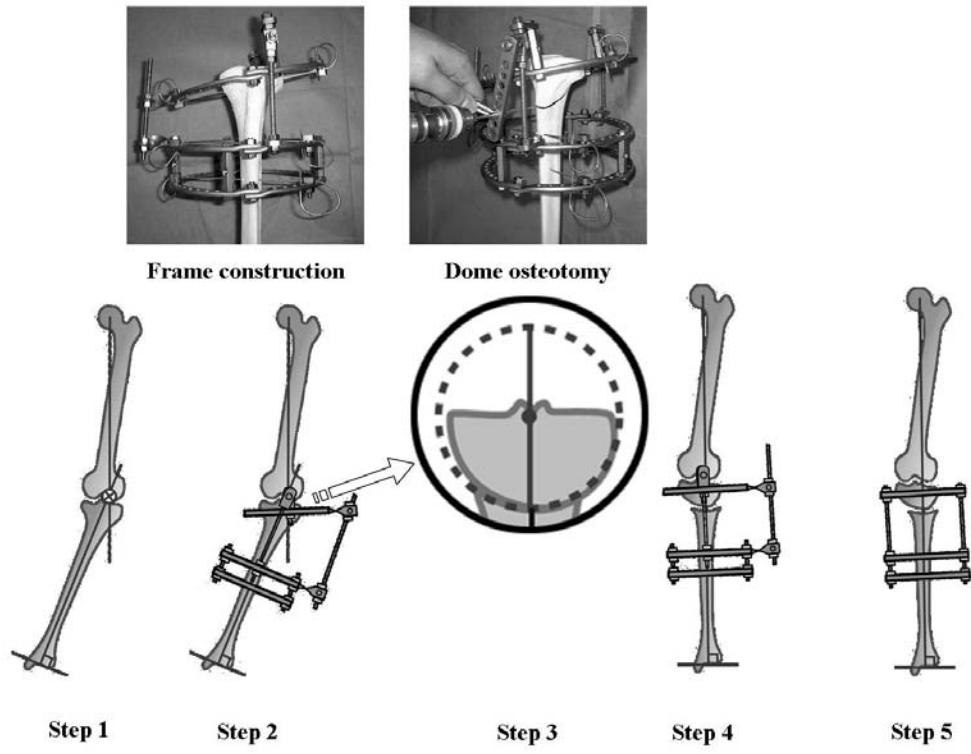
**D.** Anteroposterior radiographs of the lower limb after Ilizarov removal, taken with the patient standing. The mechanical axis passed through 53.8% on the right side and 50.0% on the left side.

**Fig. 3.** Case 2: 15-year-old male with valgus deformity of the left distal femur and limb shortening resulting from growth plate injury.

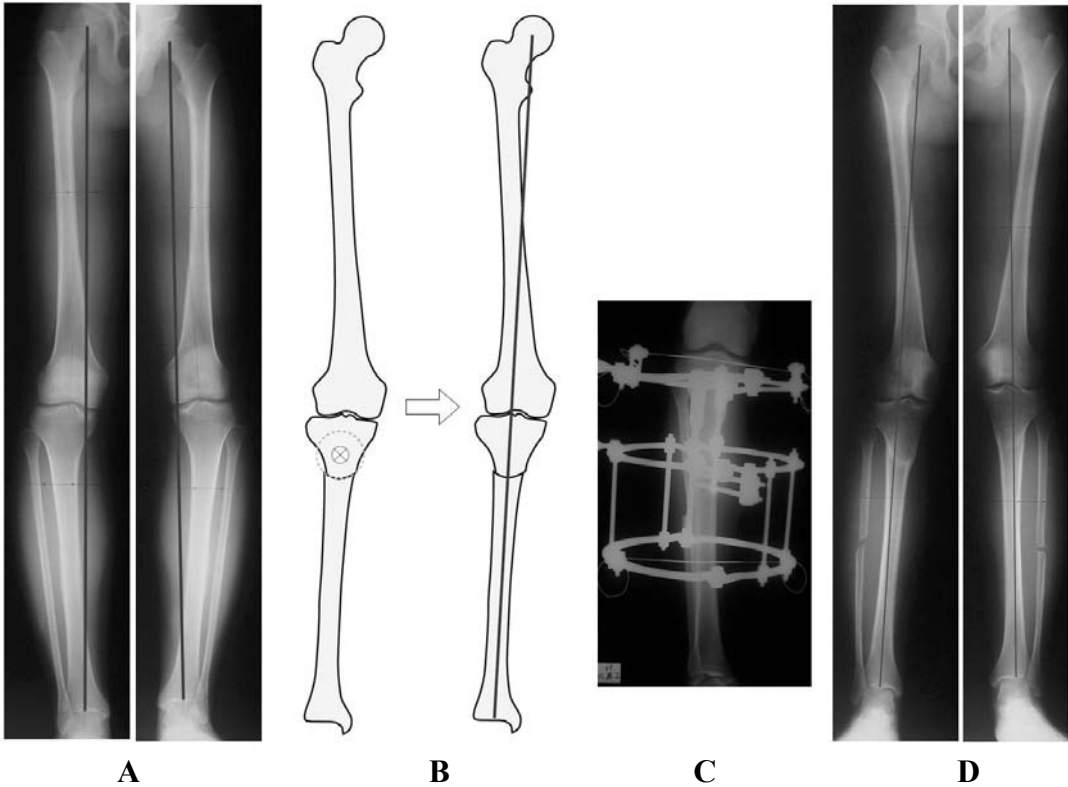
**A.** Anteroposterior radiograph showing the 22° valgus deformity of the left distal femur and limb shortening.

**B.** Anteroposterior radiograph after acute correction with focal dome osteotomy and Ilizarov external fixator application.

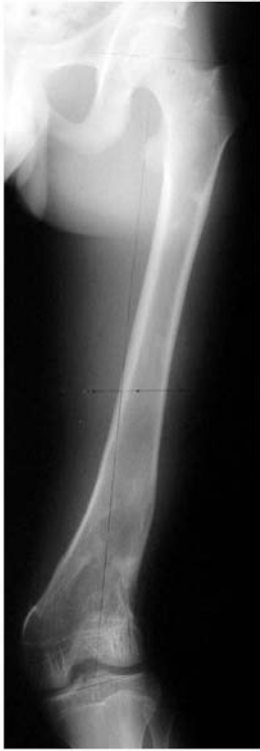**C.** Anteroposterior radiograph after Ilizarov removal. Physiologic limb alignment was achieved, with restoration of limb length.




**Fig. 1**



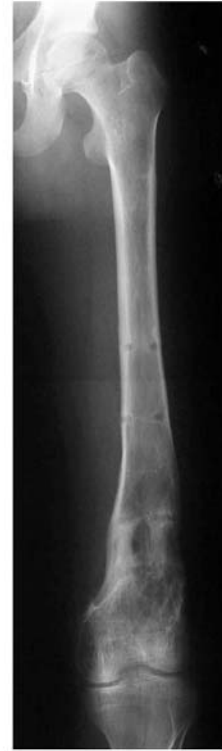**Fig. 2**



**A**



**B**



**C**

**Fig. 3**