

# Repeated total en bloc spondylectomy for spinal metastases at different sites in one patient

著者	Sugita Shurei, Murakami Hideki, Demura Satoru, Kato Satoshi, Yoshioka Katsuhito, Yokogawa Noriaki, Tanaka Sakae, Tsuchiya Hiroyuki
journal or publication title	European Spine Journal
volume	24
number	10
page range	2196-2200
year	2015-10-01
URL	<a href="http://hdl.handle.net/2297/43036">http://hdl.handle.net/2297/43036</a>

doi: 10.1007/s00586-015-4091-y

Title: Repeated total *en bloc* spondylectomy for spinal metastases at different sites in one patient.

Shurei Sugita, M.D., Ph.D.,<sup>1</sup> Hideki Murakami M.D., Ph.D.,<sup>1</sup> Satoru Demura, M.D., Ph.D.,<sup>1</sup>

Satoshi Kato M.D., Ph.D.,<sup>1</sup> Katsuhito Yoshioka M.D., Ph.D.,<sup>1</sup> Noriaki Yokogawa M.D.,<sup>1</sup>

Sakae Tanaka M.D., Ph.D.,<sup>2</sup> and Hiroyuki Tsuchiya M.D., Ph.D.<sup>1</sup>

1) Department of Orthopaedic Surgery, Kanazawa University, Kanazawa, Japan

2) Department of Orthopaedic Surgery, Faculty of Medicine, the University of Tokyo,  
Tokyo, Japan

Correspondence should be addressed to:

Shurei Sugita, M.D., Ph.D.

13-1, Takaramachi, Kanazawa, Ishikawa, 920-8641, Japan

Tel: +81762652374 Fax: +81762344261

email: [ssugita-tky@umin.ac.jp](mailto:ssugita-tky@umin.ac.jp)

Conflict of interest; none

1  
2  
3  
4  
5  
6  
7  
8  
9  
10  
11  
12  
13  
14  
15  
16  
17  
18  
19  
20  
21  
22  
23  
24  
25  
26  
27  
28  
29  
30  
31  
32  
33  
34  
35  
36  
37  
38  
39  
40  
41  
42  
43  
44  
45  
46  
47  
48  
49  
50  
51  
52  
53  
54  
55  
56  
57  
58  
59  
60  
61  
62  
63  
64  
65

Title: Repeated total *en bloc* spondylectomy for spinal metastases at different sites in one patient.

Keywords:

spinal metastases; total en bloc spondylectomy; preoperative artery embolization; nerve root ligation and cut; repeated times

Abstract

Purpose: Total *en bloc* spondylectomy (TES) is accompanied by preoperative embolization of segmental arteries, which is limited to three consecutive levels to avoid the risk of spinal cord ischemia. We retrospectively examined the efficacy and safety of repeated TES with embolization of more than three levels of segmental arteries.

Methods: Seven patients underwent TES twice for spinal metastases at different levels. Every patient underwent embolization of the bilateral segmental arteries before each surgery. We assessed the total number of segmental arteries embolized, the existence of Adamkiewicz arteries during the embolization procedure, intraoperative blood loss and the motor function of the lower limbs, using the American Spinal Injury Association (ASIA) motor score.

Results: No patient experienced any motor deficit after embolization. During the

1  
2  
3  
4  
5  
6  
7  
8 embolization procedure, an Adamkiewicz artery was depicted in five patients, which  
9  
10 precluded embolization at that level. The median number of segmental arteries embolized  
11  
12 in total was 9 (9-11). Intraoperative blood loss (median, IQR) was 480 (420 – 630) g during  
13  
14 the first surgery and 520 (280 – 600) g during the second surgery. The ASIA motor scores  
15  
16 (median, IQR) were as follows; 100 (98 – 100) (first admission), 100 (100 – 100) (first  
17  
18 discharge), 100 (98 – 100) (second admission), and 97 (94 – 100) (second discharge). No  
19  
20 patients had developed statistically significant neurological deterioration, and there had  
21  
22 been no local recurrence after a median follow-up of 17.8 months (range 1 - 51 months).  
23  
24  
25  
26  
27  
28  
29  
30  
31  
32  
33 Conclusion: Repeated TES procedures can be performed safely even if more than three  
34  
35  
36 levels of segmental arteries are embolized.  
37  
38  
39  
40  
41  
42

## 43 Introduction

44  
45 Spinal metastases is a clinically challenging condition, with a morbidity rate of  
46  
47 approximately 30% among cancer patients [1]. Additionally, 5% of cancer patients will  
48  
49 develop neurological deterioration during their clinical course [2-5]. The resulting clinical  
50  
51  
52 burden of these conditions is substantial due to the increasing life expectancy  
53  
54  
55  
56  
57  
58  
59 accompanying the recent advances in oncological therapies.  
60  
61  
62  
63  
64  
65

1  
2  
3  
4  
5  
6  
7  
8  
9  
10  
11  
12  
13  
14  
15  
16  
17  
18  
19  
20  
21  
22  
23  
24  
25  
26  
27  
28  
29  
30  
31  
32  
33  
34  
35  
36  
37  
38  
39  
40  
41  
42  
43  
44  
45  
46  
47  
48  
49  
50  
51  
52  
53  
54  
55  
56  
57  
58  
59  
60  
61  
62  
63  
64  
65

The purposes of treatment for spinal metastases are to prevent tumor recurrence, to decompress the spinal cord to avoid paralysis, and to restore the mechanical stability of the spine. To achieve these purposes, we developed a new procedure, total *en bloc* spondylectomy, which aims to provide a the local cure for the spinal metastases [6]. This technique of *en bloc* resection has proved to be effective in improving the prognosis of both primary and metastatic bone tumors of the spine [7, 8]. To prevent massive intraoperative bleeding, we routinely embolize the segmental artery at the level of the affected vertebrae one or two days before surgery [9]. However, the extent of embolization is limited up to three levels to help prevent spinal cord ischemia [10, 11].

In some cases, after the first TES, another spinal metastasis emerges at a different level, and it is sometimes necessary to perform another TES procedure. As part of this procedure, we have also had to embolize the segmental arteries, corresponding to the newly-emerged spinal metastases. As a result, the total number of embolized arteries exceeded three levels, which could potentially induce spinal cord ischemia, leading to neurologic compromise

The purpose of this study was to retrospectively examine the efficacy and safety of repeated TES, with embolization of more than three levels of segmental arteries.

1  
2  
3  
4  
5  
6  
7  
8  
9  
10  
11  
12  
13  
14  
15  
16  
17  
18  
19  
20  
21  
22  
23  
24  
25  
26  
27  
28  
29  
30  
31  
32  
33  
34  
35  
36  
37  
38  
39  
40  
41  
42  
43  
44  
45  
46  
47  
48  
49  
50  
51  
52  
53  
54  
55  
56  
57  
58  
59  
60  
61  
62  
63  
64  
65

Materials and methods

Patients

We retrospectively reviewed the records of seven patients (four males and three females, median age: 51 years old, (IQR 42 – 57) Table 1) who underwent TES twice for spinal metastases at different levels and times within study period between April 2010 and December 2014. The cases consisted of four patients with renal cell carcinoma, two with thyroid carcinoma and one with chondrosarcoma.

We collected the data regarding arterial embolization (the total number of segmental arteries embolized, the existence of an Adamkiewicz artery depicted during the embolization procedure), the surgical procedure (intraoperative blood loss, months between the first and second operation) and the clinical outcome (motor function of the lower limbs, using the American Spinal Injury Association (ASIA) motor score, local recurrence during the study period)

Embolization procedure

Before each TES procedure was accompanied by preoperative embolization of segmental arteries. The patients underwent diagnostic angiography and embolization under local anesthesia using a femoral approach. Selective catheterization of the corresponding

1  
2  
3  
4  
5  
6  
7  
8 segmental arteries, including one level above and one below the tumor site, was performed  
9  
10 followed by selective angiography of suspected tumor feeder arteries to the tumor. Coils  
11  
12 were used in combination with polyvinyl alcohol as the embolic material. If an  
13  
14 Adamkiewicz artery was depicted during angiography procedure embolization at the origin  
15  
16  
17 of this segmental artery was avoided.  
18  
19  
20  
21  
22

### 23 Surgical procedure

24  
25  
26 All patients underwent the routine surgical procedure as has been described in the literature  
27  
28 [6]. Decompression of the spinal cord was accomplished by *en bloc* corpectomy following  
29  
30 *en bloc* laminectomy. The anterior column was then reconstructed by inserting a vertebral  
31  
32  
33 spacer packed with autograft bone. During each surgery, posterior fixation extended two  
34  
35  
36 levels above and two below the tumor site. If the proposed levels of fixation in the second  
37  
38  
39 surgery were to overlap the fixation placed during the first surgery, rod connectors or  
40  
41  
42  
43  
44  
45  
46 converting rods were used.  
47

### 48 Statistical analysis

49  
50  
51  
52 Statistical analyses were performed using the JMP<sup>®</sup> version 11 software program (SAS,  
53  
54  
55 Cary, NC) Descriptive statistics were used to analyze clinical information, demographic  
56  
57  
58 factors and other test data. Continuous variables are expressed as the medians and  
59  
60  
61  
62  
63  
64  
65

1  
2  
3  
4  
5  
6  
7  
8 interquartile range (IQR). The differences in the motor scores before and after treatment  
9  
10  
11 were examined using Mann-Whitney *U* test. A P value < 0.05 was considered to be  
12  
13  
14 statistically significant.

## 15 16 17 Results

### 18 19 20 Embolization

21  
22  
23 Every patient underwent preoperative embolization of the segmental arteries before each  
24  
25  
26 surgery. The mean total number of segmental arteries embolized was nine (range 8-11).  
27

28  
29  
30 Detailed data about embolization procedure are shown in Table 2. During the embolization  
31  
32  
33 procedure, an Adamkiewicz artery was depicted in five patients (Table 2), and embolization  
34  
35  
36 at the origin of this segmental artery was avoided in these cases. No patient experienced  
37  
38  
39 deterioration of his or her baseline neurologic status post-embolization.  
40

### 41 42 43 Surgery

44  
45  
46 Detailed data about the surgical procedure are shown in Table 3. The median interval  
47  
48  
49 between the first and second surgeries (median, IQR) was 21 (5 – 49.1) months. In the  
50  
51  
52 thoracic spine, the nerve roots corresponding to the tumor level were ligated and cut; as  
53  
54  
55 necessary, nerve roots one level above and/or below were also ligated and cut. In the  
56  
57  
58 lumbar spine, the nerve roots below the L3 level were not cut, but only dissected from  
59  
60  
61  
62  
63  
64  
65



1  
2  
3  
4  
5  
6  
7  
8 surrounding tissues. If the corresponding nerve roots were at L1 or L2, we also ligated and  
9  
10 cut these roots. Based on our experience, sacrificing the nerve roots above the L1 or L2  
11  
12 level does not lead to a significant loss of neurologic function.  
13  
14

15  
16  
17 The intraoperative blood loss (median, IQR) was 480 (420 – 630) g during the  
18  
19 first surgery, and 520 (280 – 600) g during the second surgery. Only one patient needed a  
20  
21 blood transfusion postoperatively.  
22  
23

#### 24 25 26 Outcomes

27  
28  
29 The ASIA motor scores of the lower limbs are shown in Fig. 1. No patients had developed  
30  
31 statistically significant neurological deterioration and all were free from local recurrence  
32  
33 after a median follow-up of 17.8 months (range 1- 51 months). Significant surgical  
34  
35 complications were two hardware failures which required revision surgery, and a case of  
36  
37 postural hypotension of unknown etiology.  
38  
39

#### 40 41 42 Illustrative case

43  
44  
45  
46 Case.7 was a 68-year-old male with spinal metastases from renal cell carcinoma to T7 who  
47  
48 presented at our hospital. After embolization of the bilateral segmental arteries from T6 to  
49  
50 T8, he underwent TES of T7 and experienced no perioperative complications (Fig. 2a).  
51  
52

53  
54  
55 However, 20 months later, rod breakage was found on follow-up radiographs and newly  
56  
57  
58  
59  
60  
61  
62  
63  
64  
65

1  
2  
3  
4  
5  
6  
7  
8 emerged metastases at T8 and T9 were discovered on MRI (Fig. 2b). A second TES  
9  
10 procedure was planned and during preoperative embolization, a communicating branch had  
11  
12 developed from the T9 segmental artery to the T8 segmental artery (Fig. 2c). The patient  
13  
14 underwent a second TES procedure at T8 and T9 without complications (Fig. 2d). Since  
15  
16  
17 surgery, no local recurrence has been observed during the 17-month follow-up period.  
18  
19  
20  
21  
22

## 23 Discussion

24  
25  
26 In our study, repeated TES and preoperative embolization caused no neurological  
27  
28 deterioration arising from spinal cord ischemia or the surgical procedure. The local control  
29  
30 of the affected spine was favorable.  
31  
32  
33  
34  
35

36 Preoperative embolization to prevent excessive intraoperative bleeding when  
37  
38 surgically treating metastatic spinal tumors is now widely used [12]. At our institution, the  
39  
40 extent of embolization has been limited up to three levels to prevent spinal cord ischemia  
41  
42 [10, 11]. In this case series, though embolization was performed twice at separate times, the  
43  
44 total number of embolized arteries exceeded three levels, which may increase the risk of  
45  
46 neurological deterioration due to decreased blood flow to the spinal cord. However the  
47  
48 outcomes with regard to the neurological function did not worsen even after the second  
49  
50  
51  
52  
53  
54  
55  
56  
57  
58  
59 TES. There have been several studies which have indicated that occlusion of the segmental  
60  
61  
62  
63  
64  
65

1  
2  
3  
4  
5  
6  
7  
8 arteries leads to the development of collateral pathways of intraspinal and paraspinous  
9  
10 arteries and arterioles [13-16], and these collateral pathways developed within five days  
11  
12 after occlusion in those cases. These studies may explain the reasons for the preservation of  
13  
14 the neurological function after the multiple-level embolization of the segmental arteries in  
15  
16 our case series. The time interval between the first and second embolizations was long  
17  
18 enough to allow the development of a collateral artery network. An example of this is seen  
19  
20 in case 7, where collateral blood flow from the T9 segmental artery to the T8 segmental  
21  
22 artery was depicted during the second embolization procedure (Fig. 2).  
23  
24  
25  
26  
27  
28  
29  
30  
31  
32

33           Regarding the surgical procedure, nerve roots at the operative level had to be  
34  
35 sacrificed if the level was above L3. In this case series, the number of sacrificed nerve roots  
36  
37 was multiple and often exceeded three levels. Despite this, neurological function remained  
38  
39 preserved. We previously reported that ligation of nerve roots in the thoracic region did not  
40  
41 lead to worsening of the neurological function [17]. We have also observed that neurologic  
42  
43 function is also preserved following the ligation and transection of the L1 or L2 nerve roots.  
44  
45  
46  
47  
48  
49 Further studies will be needed to confirm these studies, but they support our experiences  
50  
51  
52  
53  
54  
55 indicating that repeat TES is safe.  
56  
57

58           The TES procedures in this case series were without any perioperative  
59  
60  
61  
62  
63  
64  
65

1  
2  
3  
4  
5  
6  
7 complications. The intraoperative blood loss was minimized, and only one of the seven  
8  
9  
10 patients required a blood transfusion, which indicates that the embolization had succeeded  
11  
12  
13  
14 in limiting the intraoperative blood loss, as reported previously[9, 12, 18, 19].  
15

16  
17 There are several limitations associated with this study that should be kept in mind when  
18  
19  
20 interpreting the results. First, the number of cases in this study was relatively small (seven)  
21  
22  
23 and we are unable to extrapolate the result of this study to future cases. Secondly, we had  
24  
25  
26 two cases of hardware failure in these seven cases, both of which required revision surgery.  
27  
28  
29 Furthermore, improvements in reconstruction after the resection of tumor-containing  
30  
31  
32 vertebra are needed.  
33

### 34 35 36 Conclusion

37  
38  
39 Repeated TES procedures can be performed safely and can provide good surgical outcomes,  
40  
41  
42 even if preceded by embolization of segmental arteries in more than three levels.  
43  
44

### 45 46 47 48 49 References

- 50  
51  
52  
53  
54 1. Ortiz Gomez JA (1995) The incidence of vertebral body metastases. International  
55 orthopaedics 19:309-311  
56  
57 2. Black P (1979) Spinal metastasis: current status and recommended guidelines for  
58  
59  
60  
61  
62  
63  
64  
65

1  
2  
3  
4  
5  
6  
7 management. *Neurosurgery* 5:726-746

8 3. Rades D, Blach M, Nerreter V, Bremer M, Karstens JH (1999) Metastatic spinal cord  
9 compression. Influence of time between onset of motoric deficits and start of irradiation on  
10 therapeutic effect. *Strahlentherapie und Onkologie : Organ der Deutschen Rontgengesellschaft*  
11 [et al] 175:378-381

12 4. Constans JP, de Divitiis E, Donzelli R, Spaziante R, Meder JF, Haye C (1983) Spinal  
13 metastases with neurological manifestations. Review of 600 cases. *J Neurosurg* 59:111-118. doi:  
14 10.3171/jns.1983.59.1.0111

15 5. Bach F, Larsen BH, Rohde K, Borgesen SE, Gjerris F, Boge-Rasmussen T, Agerlin N,  
16 Rasmussen B, Stjernholm P, Sorensen PS (1990) Metastatic spinal cord compression.  
17 Occurrence, symptoms, clinical presentations and prognosis in 398 patients with spinal cord  
18 compression. *Acta neurochirurgica* 107:37-43

19 6. Tomita K, Kawahara N, Baba H, Tsuchiya H, Nagata S, Toribatake Y (1994) Total en bloc  
20 spondylectomy for solitary spinal metastases. *Int Orthop* 18:291-298

21 7. Boriani S, Bandiera S, Donthineni R, Amendola L, Cappuccio M, De Iure F, Gasbarrini A  
22 (2010) Morbidity of en bloc resections in the spine. *Eur Spine J* 19:231-241. doi:  
23 10.1007/s00586-009-1137-z

24 8. Kato S, Murakami H, Demura S, Yoshioka K, Kawahara N, Tomita K, Tsuchiya H (2014)  
25 More than 10-year follow-up after total en bloc spondylectomy for spinal tumors. *Annals of*  
26 *surgical oncology* 21:1330-1336. doi: 10.1245/s10434-013-3333-7

27 9. Guzman R, Dubach-Schwizer S, Heini P, Lovblad KO, Kalbermatten D, Schroth G, Remonda  
28 L (2005) Preoperative transarterial embolization of vertebral metastases. *Eur Spine J*  
29 14:263-268. doi: 10.1007/s00586-004-0757-6

30 10. Fujimaki Y, Kawahara N, Tomita K, Murakami H, Ueda Y (2006) How many ligations of  
31 bilateral segmental arteries cause ischemic spinal cord dysfunction? An experimental study  
32 using a dog model. *Spine (Phila Pa 1976)* 31:E781-789. doi: 10.1097/01.brs.0000238717.51102.79

33 11. Kato S, Kawahara N, Tomita K, Murakami H, Demura S, Fujimaki Y (2008) Effects on  
34 spinal cord blood flow and neurologic function secondary to interruption of bilateral segmental  
35 arteries which supply the artery of Adamkiewicz: an experimental study using a dog model.  
36 *Spine (Phila Pa 1976)* 33:1533-1541. doi: 10.1097/BRS.0b013e318178e5af

37 12. Pikiš S, Itshayek E, Barzilay Y, Hasharoni A, Kaplan L, Gomori M, Cohen JE (2014)  
38 Preoperative embolization of hypervascular spinal tumors: current practice and center  
39 experience. *Neurological research* 36:502-509. doi: 10.1179/1743132814y.0000000361

- 1  
2  
3  
4  
5  
6  
7 13. Etz DC, Luehr M, Aspern KV, Misfeld M, Gudehus S, Ender J, Koelbel T, Debus ES, Mohr  
8 FW (2014) Spinal cord ischemia in open and endovascular thoracoabdominal aortic aneurysm  
9 repair: new concepts. *The Journal of cardiovascular surgery* 55:159-168
- 10  
11 14. Luehr M, Salameh A, Haunschild J, Hoyer A, Girrback FF, von Aspern K, Dhein S, Mohr FW,  
12 Etz CD (2014) Minimally invasive segmental artery coil embolization for preconditioning of the  
13 spinal cord collateral network before one-stage descending and thoracoabdominal aneurysm  
14 repair. *Innovations (Philadelphia, Pa)* 9:60-65. doi: 10.1097/imi.0000000000000038
- 15  
16 15. Etz CD, Kari FA, Mueller CS, Brenner RM, Lin HM, Griep RB (2011) The collateral  
17 network concept: remodeling of the arterial collateral network after experimental segmental  
18 artery sacrifice. *The Journal of thoracic and cardiovascular surgery* 141:1029-1036. doi:  
19 10.1016/j.jtcvs.2010.06.017
- 20  
21 16. Geisbusch S, Schray D, Bischoff MS, Lin HM, Griep RB, Di Luozzo G (2012) Imaging of  
22 vascular remodeling after simulated thoracoabdominal aneurysm repair. *The Journal of*  
23 *thoracic and cardiovascular surgery* 144:1471-1478. doi: 10.1016/j.jtcvs.2012.08.062
- 24  
25 17. Murakami H, Kawahara N, Demura S, Kato S, Yoshioka K, Tomita K (2010) Neurological  
26 function after total en bloc spondylectomy for thoracic spinal tumors. *Journal of neurosurgery*  
27 *Spine* 12:253-256. doi: 10.3171/2009.9.spine09506
- 28  
29 18. Kato S, Murakami H, Minami T, Demura S, Yoshioka K, Matsui O, Tsuchiya H (2012)  
30 Preoperative embolization significantly decreases intraoperative blood loss during palliative  
31 surgery for spinal metastasis. *Orthopedics* 35:e1389-1395. doi: 10.3928/01477447-20120822-27
- 32  
33 19. Kato S, Hozumi T, Takaki Y, Yamakawa K, Goto T, Kondo T (2013) Optimal schedule of  
34 preoperative embolization for spinal metastasis surgery. *Spine (Phila Pa 1976)* 38:1964-1969.  
35 doi: 10.1097/BRS.0b013e3182a46576
- 36  
37  
38  
39  
40  
41  
42  
43  
44  
45  
46  
47  
48  
49  
50  
51  
52  
53  
54  
55  
56  
57  
58  
59  
60  
61  
62  
63  
64  
65

1  
2  
3  
4  
5  
6  
7  
8  
9  
10  
11  
12  
13  
14  
15  
16  
17  
18  
19  
20  
21  
22  
23  
24  
25  
26  
27  
28  
29  
30  
31  
32  
33  
34  
35  
36  
37  
38  
39  
40  
41  
42  
43  
44  
45  
46  
47  
48  
49  
50  
51  
52  
53  
54  
55  
56  
57  
58  
59  
60  
61  
62  
63  
64  
65

Figure legends.

Figure 1.

The ASIA motor scores in this case series.

Figure 2.

- (a) A postoperative radiograph of the thoracic spine after first surgery.
- (b) MRI images showing recurring metastasis at T8,9 (a high intensity area around the pedicle screw in the axial image)
- (c) The angiography findings before the second operation. The right T8 segmental artery with a collateral pathway to T9 was depicted during angiography of the T9 artery (arrow).
- (d) A postoperative radiograph of the thoracic spine after the second surgery.

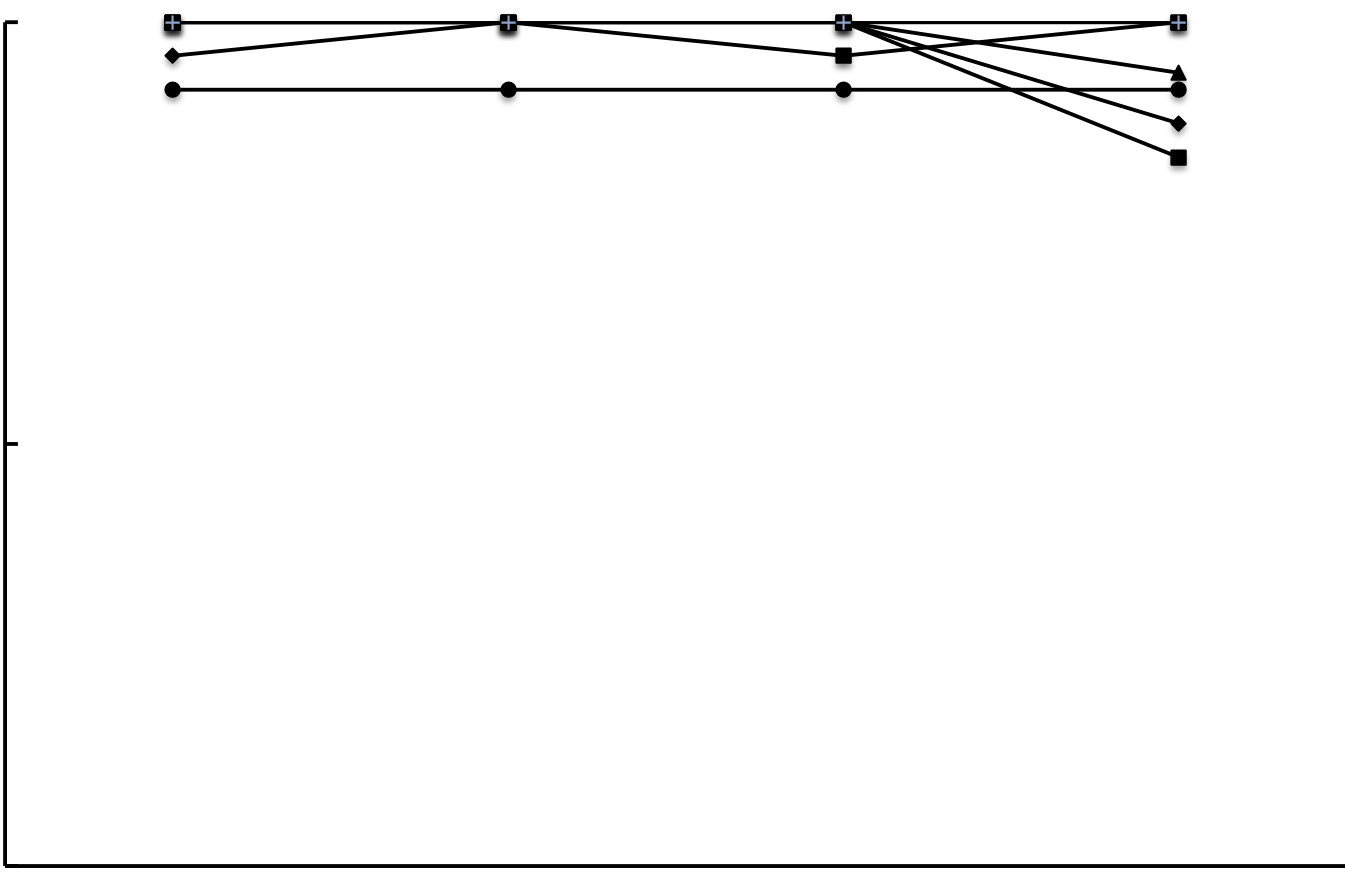
Fig.1

ASIA  
Motor  
Score

100  
75  
50

Before 1<sup>st</sup> surgery      After 1<sup>st</sup> surgery      Before 2<sup>nd</sup> surgery      After 2<sup>nd</sup> surgery

- ◆ Case1
- Case2
- ▲ Case3
- Case4
- Case5
- Case6
- ◆ Case7





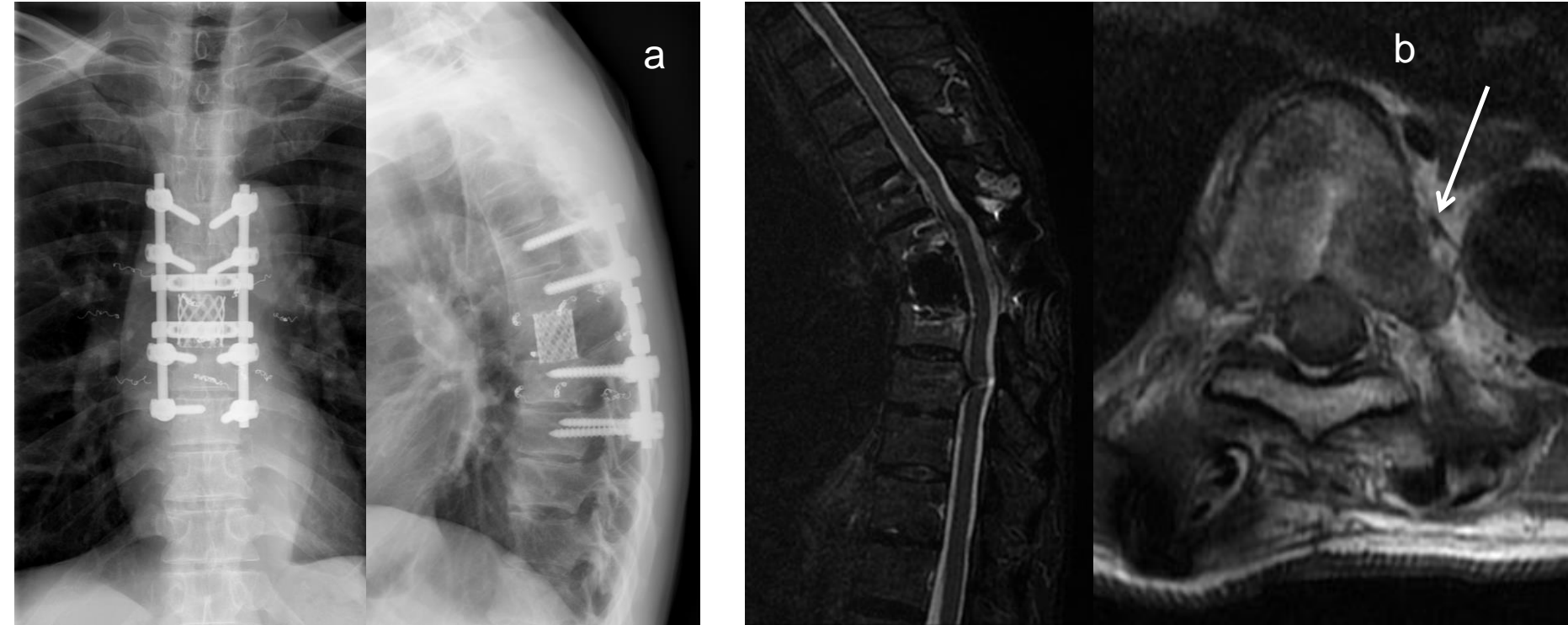


Fig.2

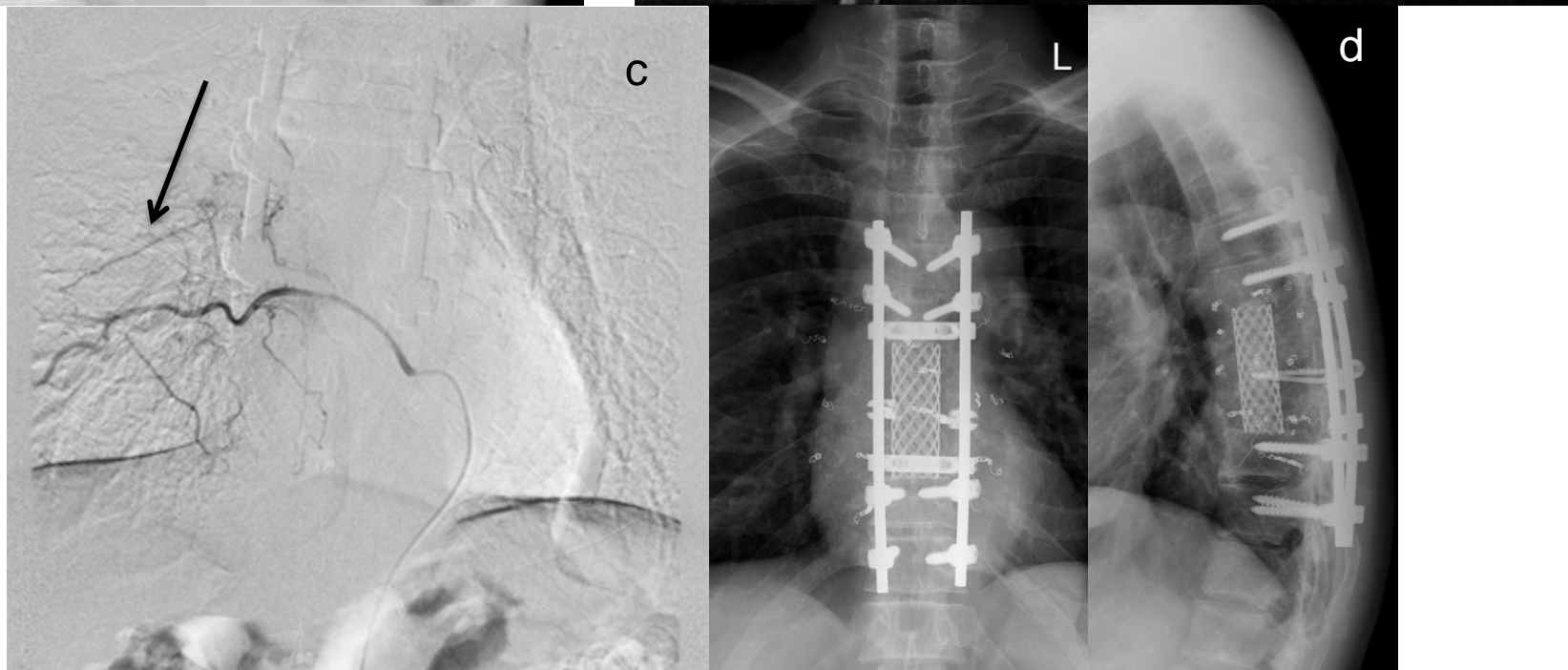


Table 1. The demographic data of the seven patients included in this study

Case	Age	Gender	Tumor
1	48	M	RCC
2	39	M	Thyroid CA.
3	57	F	Thyroid CA.
4	42	M	RCC
5	51	F	RCC
6	54	F	Chondrosarcoma
7	68	F	RCC

RCC: Renal Cell Carcinoma, Thyroid CA: Thyroid Carcinoma

Table 2. Detailed data about the embolization procedures

Case	Embolized segmental arteries (1st)	Embolized segmental arteries (2nd)	Total number of embolized arteries	Origin of Adamkiewicz artery
1	Lt T3, bil T4, 5	Bil T11,12, L1	11	Rt T3
2	Lt T3, bil T4, Lt T5	Bil L3, 4	8	Not visualized
3	Bil T4, 5, 6	Bil L1, rt L3, L4	10	Not visualized
4	Bil T7, 8, rt T9	Bil L3, 4	9	Lt T9
5	Bil T9, 10, 11	Bil L1, 3, rt L2	11	Lt L2
6	Bil T7, T8, lt T9	Bil T12, L2	9	Rt T9
7	Bil T6, 7, 8	Bil T9, rt T10	9	Lt T10

Table 3. Detailed data about surgical procedure.

Case	First operation			Second operation			Months between surgeries
	Excised vertebrae	Sacrificed roots	Blood loss (g)	Excised vertebra	Sacrificed roots	Blood loss (g)	
1	T4	Bil T4	480	T12, L1	Bil T12, L1	420	12.9
2	T4	Bil T3, T4	860	L4	none	950	1.3
3	T5, 6	Bil T5, T6	630	L1	Bil L1	280	30.0
4	T7, 8	Bil T7, T8	480	L4	none	600	5.0
5	T9, 10, 11	Bil T9, T10, T11	340	L2, 3	Bil L2	570	54.2
6	T7, 8, 9	Bil T7, T8, T9	420	L1	Bil L1	180	49.1
7	T7	Bil T7	550	T8, 9	Bil T8, T9	520	21.0