

# Outcome of posterior lumbar interbody fusion for L4-L5 degenerative spondylolisthesis

著者	Hayashi Hiroyuki, Murakami Hideki, Demura Satoru, Kato Satoshi, Kawahara Norio, Tsuchiya Hiroyuki
journal or publication title	Indian Journal of Orthopaedics
volume	49
number	3
page range	284-288
year	2015-05-01
URL	<a href="http://hdl.handle.net/2297/43122">http://hdl.handle.net/2297/43122</a>

doi: 10.4103/0019-5413.156188

# Outcome of posterior lumbar interbody fusion for L4-L5 degenerative spondylolisthesis

Hayashi, H. , Murakami, H., Demura, S., Kato, S.,

Kawahara, N., Tsuchiya, H.

## **Abstract**

### **Background**

Since the development and improvement of spinal instrumentation, PLIF has become the standard in the treatment for degenerative spondylolisthesis. However, few published studies have reported long-term outcomes of PLIF using a same surgical procedure. The purpose of this study is to evaluate a long-term outcome of PLIF using a same surgical procedure for L4-L5 degenerative spondylolisthesis.

### **Methods**

Out of 45 patients who underwent L4-L5 PLIF for degenerative spondylolisthesis between 1995 and 2003, 37 patients (16 males and 21 females) were evaluated in this study. Mean age at surgery was 61.8 years old. The average follow-up period was 121 months. We evaluated % slip, lordosis at L4/5, lumbar lordosis, JOA score, and adjacent segment degeneration.

## **Results**

% slip significantly improved from an average of 17.0% before surgery to 9.7% at the last follow-up. Lordosis at L4/5 averaged 3.6 degrees before surgery, 8.2 degrees after surgery and 6.9 degrees at the last follow-up. Although patients experienced some loss of correction at last follow-up, their lordosis at L4/5 at last follow-up still was significantly different from their lordosis at L4/5 before surgery. Lumbar lordosis did not significantly change. Mean JOA score was 13.4 before surgery and 24.5 at the last follow-up; mean recovery ratio was 71.2%. Adjacent segment degeneration occurred in 40.5% of patients, almost all of which occurred in the cranial adjacent segment. Three patients (8.1%) required reoperation due to adjacent segment degeneration, at 76 months, on average, after their initial surgery.

## **Conclusions**

With more than 10-year follow-up after L4-L5 PLIF for degenerative spondylolisthesis, the adjacent segment degeneration occurred in 40.5% and reoperation was required in 8.1%.

## **Introduction**

Significant variations exist in the surgical management of degenerative spondylolisthesis. Posterior lumbar interbody fusion (PLIF) is one of those variations. Several surgeons have modified the original PLIF technique described by Cloward.<sup>1-3</sup> However, it had been associated with a high incidence of fusion complications such as graft collapse and nonunion. As a result of this, PLIF had become not accepted as a standard surgical procedure. Since the development and improvement of spinal instrumentation, however, PLIF has become the standard treatment for progressive degenerative spondylolisthesis. While PLIF with pedicle screw fixation and interbody devices has shown satisfactory clinical results, a solid fusion using spinal instrumentation has been reported to accelerate the degenerative changes at the adjacent levels.<sup>2-7</sup> However, in almost all of them, the surgeons used several surgical procedures such as PLIF with or without cage. The purpose of this study was to evaluate the long-term outcome of PLIF using the same surgical procedure in patients with L4-L5 degenerative spondylolisthesis.

## **Materials and methods**

This study was approved by the ethics committee of Kanazawa University. Written

informed consent was obtained from all patients.

Seventy-four patients underwent PLIF at the L4-L5 level for lumbar spondylolisthesis with segmental instability at the Kanazawa University Hospital between 1995 and 2003. Among these, forty-five patients underwent a single-level PLIF at L4-L5 for degenerative spondylolisthesis using the same surgical procedure. Eight of these patients were excluded because their postoperative follow-up period was <60 months. The remaining 37 patients (16 men and 21 women) were included in the study. The follow-up rate in this study was 82.2 %. The mean age of the patients at the time of surgery was 61.8 years (range, 26–77 years) and the mean follow-up period was 121 months (range, 66–175 months).

#### *Surgical procedure*

A routine posterior approach through a midline incision was employed, thus exposing the L4 and L5 vertebrae. Laminectomy is performed for almost all of the caudal two-thirds of the L4 spinous process and lamina, including both inferior articular processes of L4. These procedures enable total resection of the ligamentum flavum and exposure of the neural elements. The pedicle screws were then inserted in L4 and L5

bilaterally. The reduction was initiated by distraction at the L4 pedicle screws using the distraction device. After the L4-L5 disc was resected as much as possible, the anterior part of the disc space was packed with cancellous iliac bone, and titanium cages (Harms cage, Depuy Spine, Raynham, MA) packed with grafted bone chips were inserted. Finally, compression was applied at the L5 pedicle screws using the compression device.

Radiologic assessment was performed using plain lateral view radiographs before surgery, immediately after surgery, and at the last follow-up examination. We evaluated the % slip, the lordosis at L4-L5, the lumbar lordosis, and the adjacent segment degeneration. The % slip was measured using the Taillard method.<sup>8</sup> The lordosis at L4-L5 was defined as the angle subtended by the superior end plate of L5 and the inferior end plate of L4. Lumbar lordosis was measured from the superior end plate of L1 to the inferior end plate of L5 using the Cobb method.<sup>9</sup> The adjacent segment degeneration was defined as imaging evidence of one or more of the following lesions adjacent to a fused segment that was not present preoperatively: 1) posterior opening  $>5^\circ$ ; 2) narrowing of the disc height  $<3$  mm; 3) progression of the slippage  $>3$  mm.

The Japanese Orthopaedic Association's evaluation system for low back pain syndrome (JOA score) was used before surgery and at the last follow-up examination, to evaluate the outcome of subjective symptoms (low back pain and leg pain), clinical signs (sensory and motor disturbance), and urinary bladder function. A normal score is 29 points and the worst score is -6 points (Table 1). The recovery rate of the JOA score that indicates the degree of normalization after surgery was calculated at the last follow-up examination using the formula described by Hirabayashi et al.<sup>10</sup>

Statistical evaluation was performed using one-way analysis of variance (ANOVA) to compare the radiologic measures before surgery, immediately after surgery, and at the last follow-up examination. Post hoc tests performed were indicated by ANOVA results using Tukey's test for multiple comparisons. Statistically significant differences were defined as  $P < 0.05$ . SPSS for Windows (19.0; SPSS Inc., Chicago, IL, USA) was used to perform the statistical analyses.

## **Results**

The % slip decreased from 17.0% before surgery to 9.7% at the last follow-up examination (Figure 1). The mean lordosis at L4-L5 was 3.6° before surgery, 8.2° after

surgery, and  $6.9^{\circ}$  at the last follow-up examination (Figure 2). The lumbar lordosis did not change significantly (Figure 3). Adjacent segment degeneration occurred at the cephalad level in 14 patients and at the caudal level in 1 patient (Table 2). No patient had pseudarthrosis at the last follow-up examination.

The mean JOA score was 13.4 points (range, 4–20 points) before surgery and 24.5 points (range, 16–29 points) at the last follow-up examination. The mean recovery rate was 71.2% (range, 44–100 %).

There were no serious systemic complications or deep surgical site infections. No immediate postoperative neurological complications were observed, although an incidental dural tear was observed in 2 patients (5.4%).

Reoperation was required in 3 patients (8.1%) due to intolerable symptoms in their lower extremities caused by adjacent segment degeneration. The mean period between the first surgery and the revision surgery was 76 months.

### **Case presentation**

A 72-year-old man underwent PLIF for L4-L5 degenerative spondylolisthesis. The preoperative JOA score was 17 points and the lordosis at L4-L5 was  $2.0^{\circ}$ . After the surgery, the lordosis at L4-L5 improved to  $9.0^{\circ}$ . However, adjacent segment



degeneration at the cephalad level occurred 8 years after surgery and an L3-L4 PLIF was performed. In addition, a third surgery due to adjacent segment degeneration at L2-L3 was required 2 years after the second surgery. At the last follow-up examination, his JOA score was 21 points (Figure 4).

## **Discussion**

Anterior column augmentation with PLIF using intervertebral spacers in addition to pedicular screw fixation was found to have superior fusion rate and improved clinical outcomes in spondylolisthesis.<sup>11-14</sup> Recently, transforaminal lumbar interbody fusion has also been reported to produce a high fusion rate and excellent clinical outcomes. However, PLIF is more advantageous in achieving solid fusion by removing intervertebral material and cartilaginous endplates through bilateral wide annulotomy and harvesting a greater amount of local autograft.<sup>15</sup> Evaluation of the long-term outcomes of PLIF is important. Previously conducted studies had limitations in terms of different diagnoses, different levels and number of fused segments, and different fusion techniques. Therefore, we evaluated the long-term outcomes of PLIF using the same procedure in patients with degenerative spondylolisthesis.

In this study, the mean recovery rate of the JOA score was 71.2%, and the clinical

result was satisfactory. However, we experienced the postoperative course seen in *Case 2* on some occasions. Degenerative changes at the levels adjacent to the lumbar spinal fusion have been well recognized.<sup>5,6</sup> The factors thought to be involved in the increase of degeneration at adjacent levels are the stiffness of the fixation, the number of fused levels, the natural course of degeneration at the adjacent level, and any postoperative lumbar sagittal malalignment. The importance of sagittal realignment and maintenance of lordosis during fixation have been documented in clinical studies,<sup>16,17</sup> and clinical experience suggests that lumbar fusion in a nonanatomic sagittal alignment can cause a deleterious effect at the adjacent level. Akamaru et al. reported the effects of fixing the L4-L5 segment in different sagittal alignments on the adjacent motion segments using human cadavers. Their study showed that sagittal malalignment fusion is considered a risk factor for adjacent segment degeneration after PLIF.<sup>18</sup> Therefore, we have always ensured adequate lordosis at the fusion site in PLIF.

In this study, the mean lordosis at L4-L5 was 3.6° before surgery, 8.2° after surgery, and 6.9° at the last follow-up examination. We thought that we achieved good local alignment at the fusion site, but adjacent segment degeneration occurred in 15 patients, and reoperation was required in 3 of the 15 patients. Similarly, Ohwada et al. performed PLIF both with and without a cage, and reported that adjacent segment degeneration

occurred in 57.5%, and reoperation was required in 27.5% after a minimum follow-up period of 10 years.<sup>19</sup> Ralph et al. reported in a study of instrumented PLIF that the reoperation rate was 12.9% for mono- or bi-segmental PLIF and 14.4% for multisegmental PLIF after a 5-year follow-up period.<sup>13</sup> From our results, the reasons for adjacent segment degeneration occurrence are not understood. Okuda et al. reported risk factors for adjacent segment degeneration after PLIF. Their study showed that coexistence of horizontalization of the lamina at L3 and facet tropism at L3-L4 may be a risk factor for neurologic deterioration resulting from accelerated L3-L4 degenerative change after L4-L5 PLIF. They used computed tomography and radiographs in their assessment.<sup>20</sup> On the other hand, we used only plain lateral view radiographs for our evaluation because our study data was >10 years old and was insufficient. We need to evaluate the risk factors for adjacent segment degeneration using computed tomography in the future.

This study has several limitations. First, we had no control group. Therefore, we could not evaluate the degenerative changes in the discs of nonsurgical patients. Van Horn and Bohnen, in a retrospective matched-pair study of 16 patients with a minimum follow-up period of 16 years after anterior spinal fusion, found radiographic degenerative changes in the adjacent discs at a rate similar to that in the corresponding levels of the control

group.<sup>21</sup> Second, this study was a small case series. However, despite these limitations, this study did reveal the long-term outcomes of PLIF using the same procedure in all the study subjects.

In conclusion, this study of 37 patients with a mean follow-up period of 10 years was performed to evaluate the long-term outcomes of PLIF using the same surgical procedure for L4-L5 degenerative spondylolisthesis. Although the clinical results were satisfactory, adjacent segment degeneration occurred in 15 patients (40.5%) and reoperation was required in 3 patients (8.1%).

## References

1. Cloward R. The treatment of ruptured lumbar intervertebral discs by vertebral body fusion. *J Neurosurg* 1953;10:154-168.
2. Steffee AD, Sitkowski DJ. Posterior lumbar interbody fusion and plates. *Clin Orthop* 1986;227:99-102.
3. Roy-Camille R, Saillant G, Mazel C. Internal fixation of the lumbar spine with pedicle screw plating. *Clin Orthop* 1986;203:7-17.
4. Cheng L, Nie L, Zhang L. Posterior lumbar interbody fusion versus posterolateral fusion in spondylolisthesis: a prospective controlled study in the Han nationality. *Int Orthop* 2009;33:1043-7.
5. Cho KS, Kang SG, Yoo DS, Huh PW, Kim DS, Lee SB. Risk factors and surgical treatment for symptomatic adjacent segment degeneration after lumbar spine fusion. *J Korean Neurosurg Soc* 2009;46:425-30.
6. Sakaura H, Yamashita T, Miwa T, Ohzono K, Ohwada T. Symptomatic adjacent segment pathology after posterior lumbar interbody fusion for adult low-grade isthmic spondylolisthesis. *Global Spine J* 2013;3:219-24.
7. Wang YT, Wu XT, Chen H, Wang C. Endoscopy-assisted posterior lumbar interbody fusion in a single segment. *J Clin Neurosci* 2014;21:287-92.

8. Taillard WF. Etiology of spondylolisthesis. *Clin Orthop Relat Res* 1976;117:30-9.
9. Cobb J. Outline for the study of scoliosis. In: Edwards JW, editor. *Instructional course lectures*. Ann Arbor, MI: The American Academy of Orthopedic Surgeons 1948:261-75.
10. Hirabayashi K, Miyakawa J, Satomi K, Maruyama T, Wakano K. Operative results and postoperative progression of ossification among patients with ossification of cervical posterior longitudinal ligament. *Spine* 1981;6:354-64.
11. Okuyama K, Kido T, Unoki E, Chiba M. PLIF with a titanium cage and excised facet joint bone for degenerative spondylolisthesis--in augmentation with a pedicle screw. *J Spinal Disord Tech* 2007;20:53-9.
12. Patil SS, Rawall S, Nagad P, Shial B, Pawar U, Nene AM. Outcome of single level instrumented posterior lumbar interbody fusion using corticocancellous laminectomy bone chips. *Indian J Orthop* 2011;45:500-3.
13. Ralph GP, Heinrich B, Yasser A, Hesham E, Joerg F. Reoperation rate after instrumented posterior interbody fusion; A report on 1680 cases. *Spine* 2004;29:2516-20.
14. Ye YP, Xu H, Chen D. Comparison between posterior lumbar interbody fusion and posterolateral fusion with transpedicular screw fixation for isthmic spondylolithesis:

- a meta-analysis. *Arch Orthop Trauma Surg* 2013;133:1649-55.
15. Miwa T, Sakaura H, Yamashita T, Suzuki S, Ohwada T. Surgical outcomes of additional posterior lumbar interbody fusion for adjacent segment disease after single-level posterior lumbar interbody fusion. *Eur Spine J* 2013;22:2864-8.
  16. Jackson RP, McManus AC. Radiographic analysis of sagittal plane alignment and balance in standing volunteers and patients with low back pain matched for age, sex, and size. *Spine* 1994;19:1611-8.
  17. Kawakami M, Tamaki T, Ando M, Yamada H, Hashizume H, Yoshida M. Lumbar sagittal balance influences the clinical outcome after decompression and posterolateral spinal fusion for degenerative lumbar spondylolisthesis. *Spine* 2002; 27:59-64.
  18. Akamaru T, Kawahara N, Yoon ST, Minamide A, Kim KS, Tomita K, et al. Adjacent segment motion after a simulated lumbar fusion in different sagittal alignment. *Spine* 2003;28:1560-6.
  19. Ohwada T, Yamashita T, Onoue K, Suzuki S, Yamamoto T, Ohkohchi T. Long-term follow-up study of posterior lumbar interbody fusion with pedicle screw and plates for degenerative spondylolisthesis. *Spine Spinal cord* 2008;21:461-9. (In Japanese)
  20. Okuda S, Iwasaki M, Miyauchi A, Aono H, Morita M, Yamamoto T. Risk factors for

adjacent segment degeneration after PLIF. *Spine* 2004;29:1535-40.

21. Van Horn JR, Bohnen LMLJ. The development of discopathy in lumbar disc adjacent to a lumbar anterior interbody spondylodesis; A retrospective matched-pair study with a post operative follow-up of 16 years. *Acta Orthop Belg* 1992;58:280-6.



## **Figure Legends**

**Figure 1.** The % slip significantly improved from 17.0% before surgery to 9.7% at the last follow-up. (\* $P < 0.05$ )

**Figure 2.** The lordosis at L4/5 significantly improved from 3.6 degrees before surgery to 8.2 degrees after surgery. At the last follow-up, the lordosis at L4/5 was restored. (\* $P < 0.05$ )

**Figure 3.** The lumbar lordosis didn't significantly change.

**Figure 4.** Lateral view radiographs of a 72-year-old male preoperatively (A), immediately after the first surgery (B), 8 years after the first surgery (C), immediately after the second surgery (D), 10 years after the first surgery (E), and at the last follow-up (F).

**Table 1.** Japanese Orthopaedic Association's evaluation system for low back pain

Symptoms and signs	Score
I Subjective symptoms (9 points)	
A. Low back pain	
a. None	3
b. Occasional mild pain	2
c. Frequent mild or occasional severe pain	1
d. Frequent or continuous severe pain	0
B. Leg pain and/or tingling	
a. None	3
b. Occasional mild pain	2
c. Frequent mild or occasional severe pain	1
d. Frequent or continuous severe pain	0
C. Gait	
a. None	3
b. Able to walk farther than 500 m, although it results in pain, tingling, and/or muscle weakness	2
c. Unable to walk farther than 500 m	1
d. Unable to walk farther than 100 m	0
II Clinical signs (6 points)	
A. Straight-leg raising test	
a. Normal	2
b. 30° - 70°	1
c. < 30°	0
B. Sensory disturbance	
a. None	2
b. Slight disturbance	1
c. Marked disturbance	0
C. Motor disturbance	
a. None	2
b. Slight weakness (MMT 4)	1
c. Marked weakness (MMT 3 to 0)	0
III Restriction of ADL (14 points)	Severe    Moderate    None
a. Turning over while lying	0            1            2
b. Standing	0            1            2
c. Washing	0            1            2
d. Leaning forwards	0            1            2
e. Sitting (about 1 hour)	0            1            2
f. Lifting or holding heavy objects	0            1            2
g. Walking	0            1            2
IV Urinary bladder function (-6 points)	
(a) Normal	0
(b) Mild dysuria	-3
(c) Severe dysuria	-6

MMT, manual muscle test.

**Table 2.** Details of adjacent segment degeneration

ASD	cases
1) . Posterior opening	4
2) . Narrowing of the disc height	4
3) . Progression of the slippage	2
1). +2).	2
1). +3).	1
1). +2). +3).	2
Total	15/37 (40.5 %)

# % slip

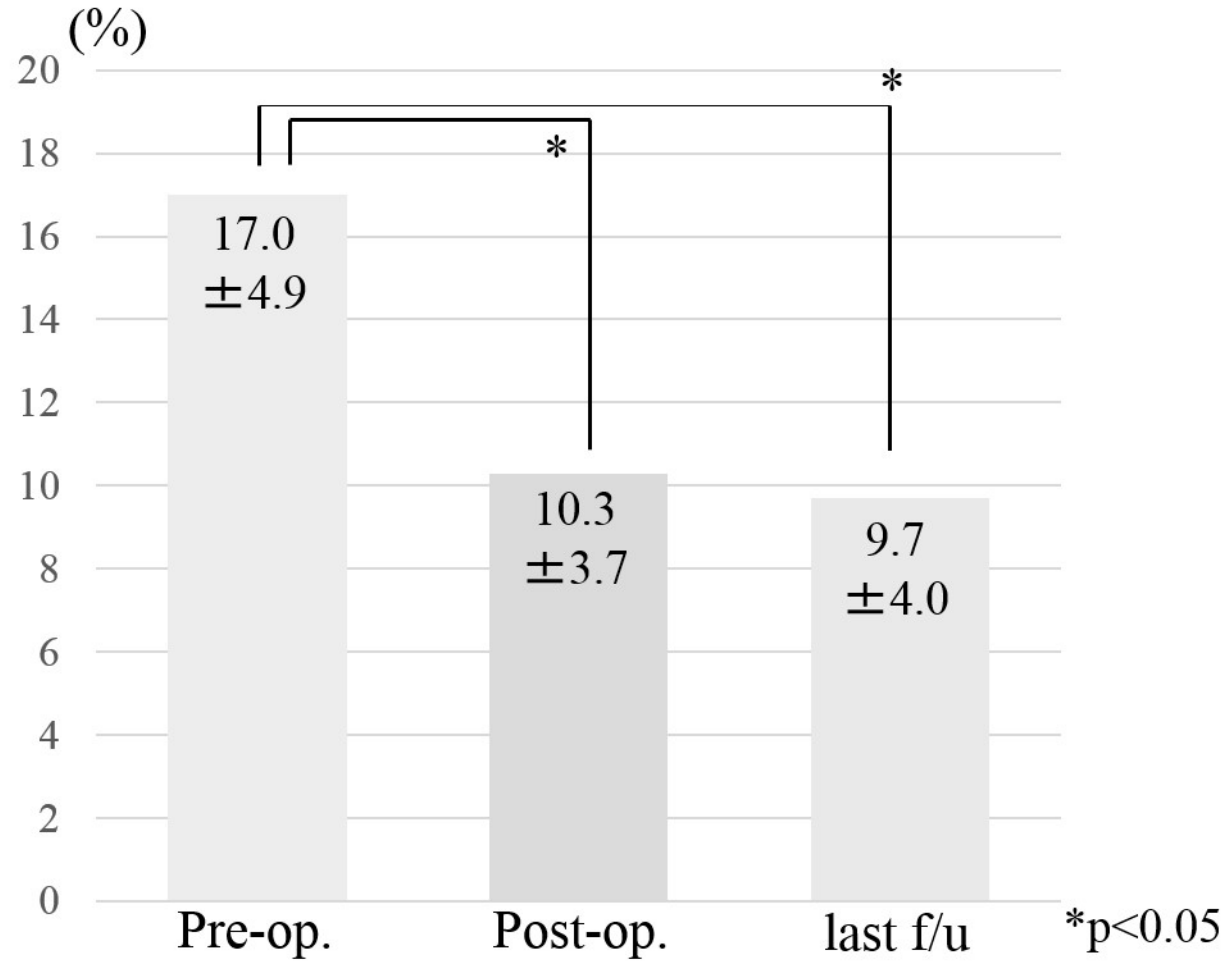


Figure. 1

# Lordosis at L4/5

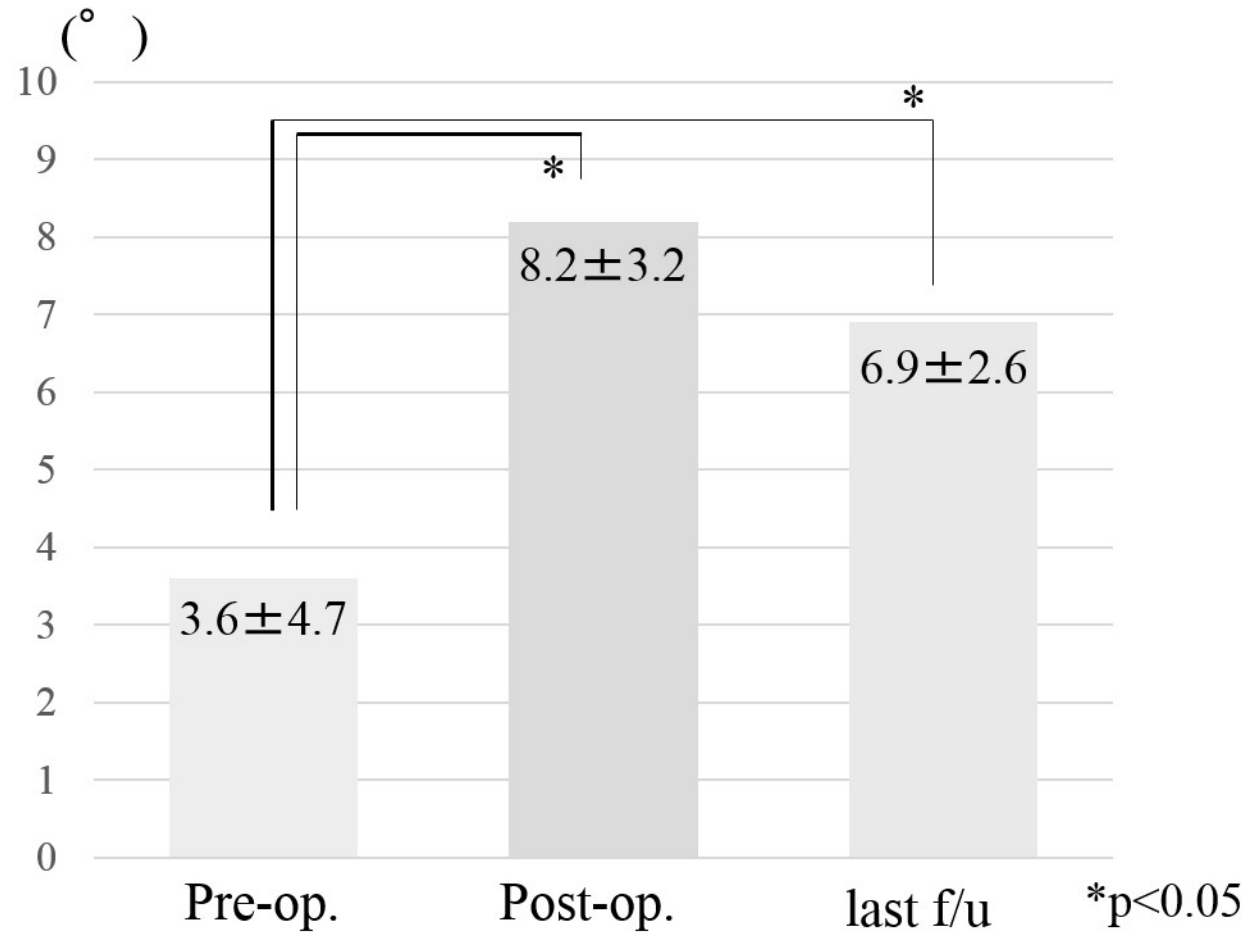


Figure. 2

# Lumbar lordosis

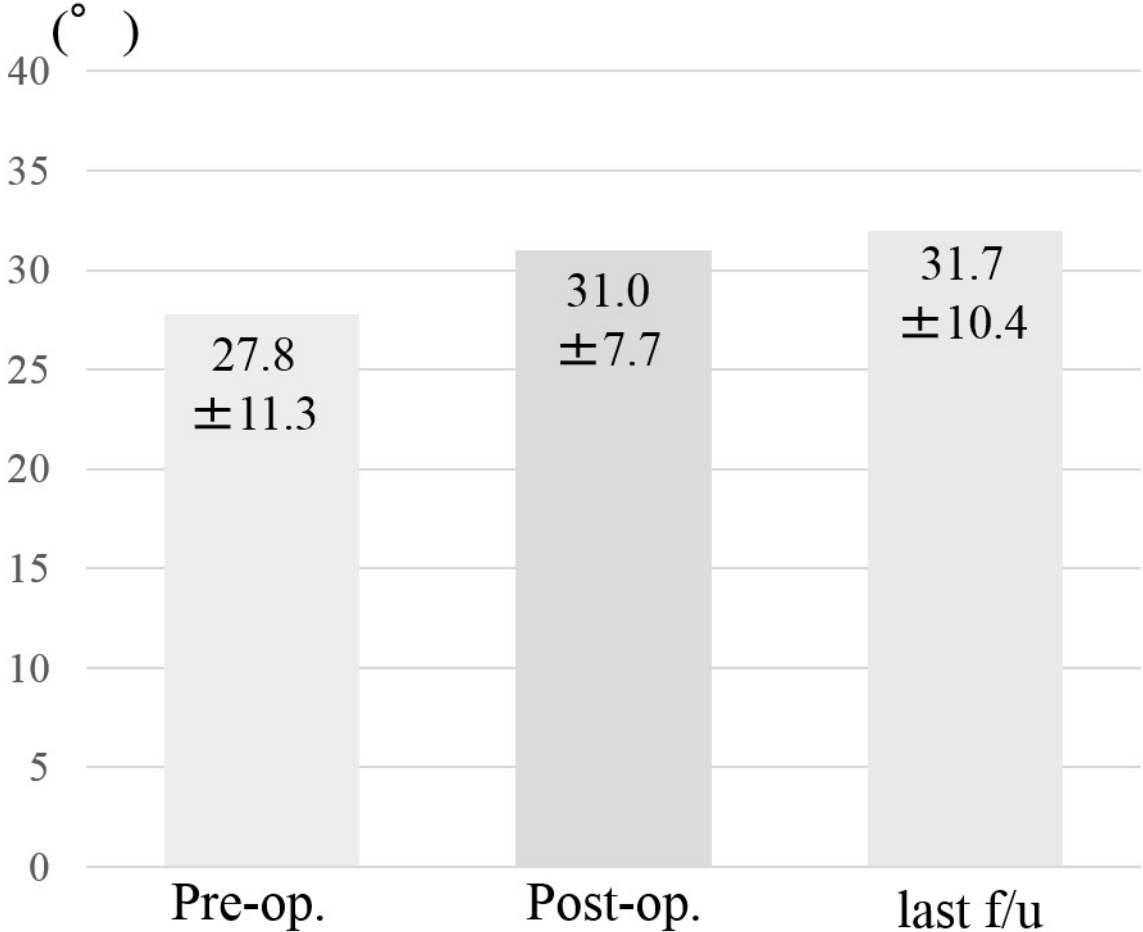


Figure. 3

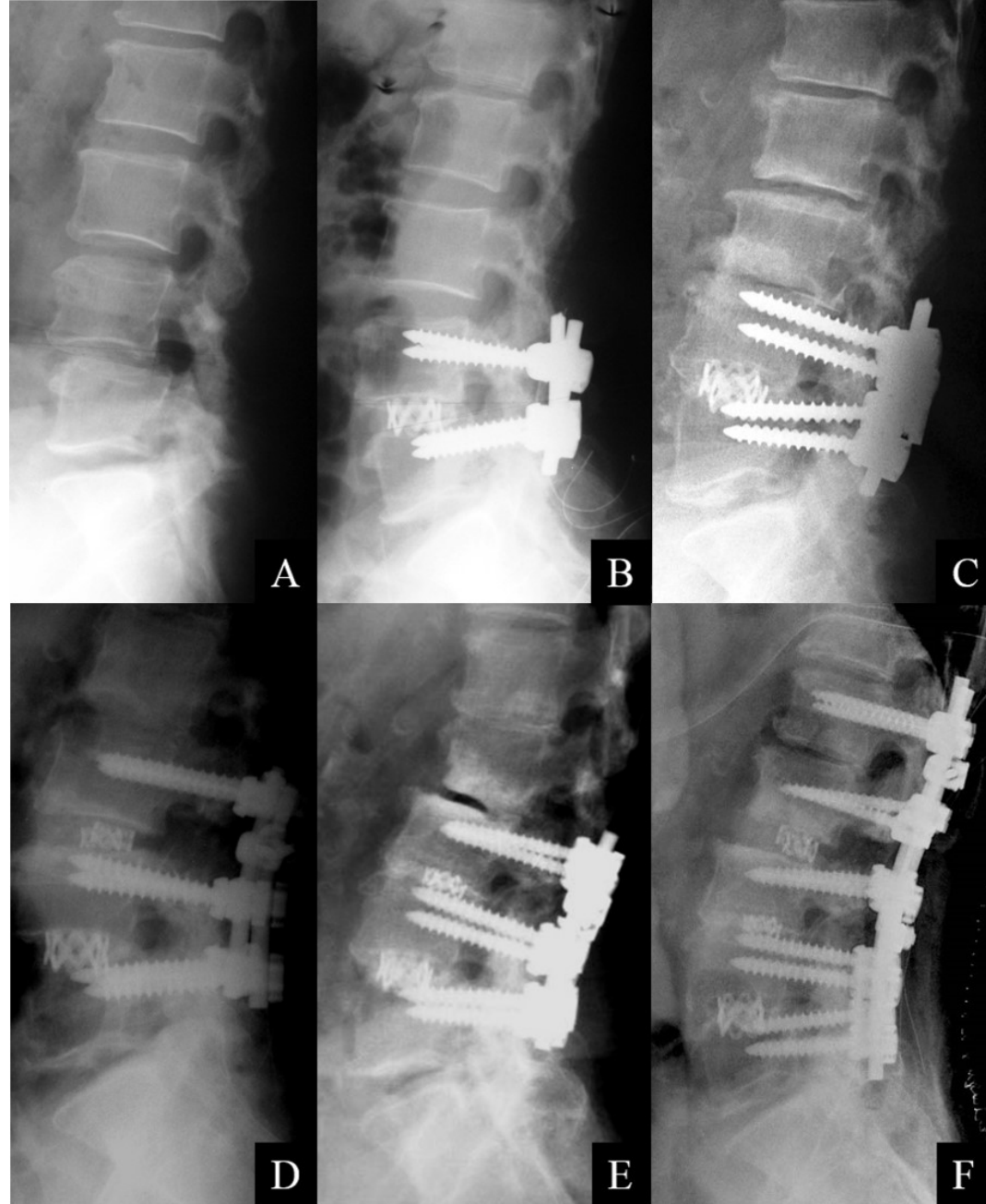


Figure. 4