

# Disappearance of lung adenocarcinoma after total en bloc spondylectomy using frozen tumor-bearing vertebra for reconstruction

著者	Sugita Shurei, Murakami Hideki, Kato Satoshi, Tanaka Sakae, Tsuchiya Hiroyuki
journal or publication title	European Spine Journal
volume	25
page range	53-57
year	2016-05-01
URL	<a href="http://hdl.handle.net/2297/43037">http://hdl.handle.net/2297/43037</a>

doi: 10.1007/s00586-015-4077-9

Title: Disappearance of lung adenocarcinoma after total *en bloc* spondylectomy using frozen tumor-bearing vertebra for reconstruction

Shurei Sugita, M.D., Ph.D.,<sup>1</sup> Hideki Murakami M.D., Ph.D.,<sup>1</sup> Satoshi Kato M.D., Ph.D.,<sup>1</sup>

Sakae Tanaka M.D., Ph.D.,<sup>2</sup> and Hiroyuki Tsuchiya M.D., Ph.D.<sup>1</sup>

1) Department of Orthopaedic Surgery, Kanazawa University, Kanazawa, Japan

2) Department of Orthopaedic Surgery, Faculty of Medicine, the University of Tokyo,

Tokyo, Japan

Correspondence should be addressed to:

Shurei Sugita, M.D., Ph.D.

13-1, Takaramachi, Kanazawa, Ishikawa, 920-8641, Japan

Tel: +81762652374 Fax: +81762344261

email: [ssugita-ky@umin.ac.jp](mailto:ssugita-ky@umin.ac.jp)

1  
2  
3  
4  
5  
6  
7  
8  
9  
10  
11  
12  
13  
14  
15  
16  
17  
18  
19  
20  
21  
22  
23  
24  
25  
26  
27  
28  
29  
30  
31  
32  
33  
34  
35  
36  
37  
38  
39  
40  
41  
42  
43  
44  
45  
46  
47  
48  
49  
50  
51  
52  
53  
54  
55  
56  
57  
58  
59  
60  
61  
62  
63  
64  
65

**Abstract**

Purpose: Total en bloc spondylectomy (TES) is a surgical procedure performed to achieve complete resection of an aggressive benign spinal tumor or a malignant spinal tumor. When reconstructing the spine after resection, we have been using liquid nitrogen-frozen resected spine bearing tumor as a bone graft, expecting an immunological response to tumor-specific antigen(s). The purpose of this article is to report a successful treatment case of lung adenocarcinoma metastasis with TES and this cryotherapy.

Methods: A 59-year-old male presented with rapid progression of neurological deterioration of the lower limbs due to a spinal metastasis from T8 to T10. The primary lung adenocarcinoma had already been excised under thoracoscopy. The patient underwent TES with reconstruction using frozen tumor-bearing vertebra for the bone graft.

Results: One month after surgery, a new nodule appeared at the right middle lobe of the lung. However, we carried out no biopsy of the newly emerged nodule and the patient received no adjuvant chemotherapy or radiotherapy. Six months after surgery, the tumor vanished. No local recurrence or metastasis of the tumor has been observed until now.

Conclusions: TES with liquid a nitrogen-frozen tumor specimen could be a promising therapeutic option for cancer patients with spine metastasis.

**Keywords:** total en bloc spondylectomy; lung cancer; frozen autograft; immunotherapy

1  
2 **Introduction**  
3

4  
5 Total en bloc spondylectomy (TES) is a surgical procedure performed to  
6  
7 achieve complete resection of an aggressive benign spinal tumor or a malignant  
8  
9 spinal tumor.[1] The outcome of this procedure has been reported to be favorable  
10  
11 with regard to the local control. [2-4] To improve the patient survival rate, a new  
12  
13 technique, which combines TES with cryosurgery, is now being used at in our  
14  
15 faculty.[5, 6] This procedure consists of the resection of the vertebral body with  
16  
17 the metastatic tumor, freezing of the tumor with liquid nitrogen then using it for  
18  
19 bone grafting.[7] This has been performed to cause tumor-induced  
20  
21 cryoimmunology.[8] This surgery was approved by the ethics committee of  
22  
23 Kanazawa University. We previously reported a case with metastatic thyroid  
24  
25 cancer at T4. After TES with cryosurgery, the serum level of thyroglobulin  
26  
27 decreased without any other adjuvant therapies, indicating activated antitumor  
28  
29 immunity.[5]  
30  
31  
32  
33  
34  
35

36 We herein present the case of a patient with a metastatic lung  
37  
38 adenocarcinoma from T8 to T10, whose newly emerged lung metastasis vanished  
39  
40 after TES with cryosurgery. Written consent was obtained from the patient for the  
41  
42 publication of this case.  
43  
44  
45  
46  
47

48 **Case report**  
49

50  
51 *History and presentation.* A 59-year-old male with rapidly worsening back pain  
52  
53 was admitted to a nearby hospital. Magnetic resonance imaging (MRI) revealed a  
54  
55 spinal tumor at T8, T9 and T10 (Fig. 1). Metastatic cancer was suspected, and he  
56  
57 underwent a detailed survey. A lung tumor at the left upper lobe was found by  
58  
59 whole body CT (Fig. 2). The patient underwent excisional biopsy with  
60  
61  
62  
63  
64  
65

1  
2 thoracoscopy for this lesion. A diagnosis of lung adenocarcinoma was confirmed  
3  
4  
5 based on the pathological findings. The patient was then referred to our hospital to  
6  
7 treat the metastatic spinal tumor. During our preoperative evaluations, rapid  
8  
9  
10 progression of the neurological deterioration of the lower limbs occurred. An  
11  
12 emergency spinal operation was performed.  
13  
14  
15  
16

17 *Operation.* *En bloc* resection of the posterior elements of T8, T9 and T10 was  
18  
19 performed by pediculotomy with a thread wire saw. Then, the anterolateral aspect  
20  
21 of the vertebral bodies was dissected, and the affected vertebral bodies (T8-10)  
22  
23 were removed after posterior fixation with instrumentation. The excised vertebral  
24  
25 bodies were frozen with liquid nitrogen for 20 minutes. These bones were crushed  
26  
27 into pieces and used as a bone graft for spinal reconstruction with local bone (Fig.  
28  
29 3). In addition, frozen tumor tissue was implanted under the skin of the axillary  
30  
31 fossa, expecting that the ground up tumor would provide tumor-specific antigens.  
32  
33  
34  
35  
36  
37  
38

39 *Postoperative course.* The patient's weakness of the lower limbs improved  
40  
41 immediately after the operation. One month after the operation, a new nodule at  
42  
43 the right middle lobe was detected by a whole body CT performed as part of the  
44  
45 routine postoperative follow-up in patients with spine metastases. We  
46  
47 retrospectively checked the lung CT, which had been taken preoperatively, and  
48  
49 found that the nodule had already existed (Fig. 4), but that the nodule had  
50  
51 gradually grown larger during observation (Fig. 4). We strongly suspected the  
52  
53 possibility of metastasis, and planned to excise the nodule. We referred the patient  
54  
55  
56 to two specialist respiratory surgeons, and a specialist radiologist. They agreed  
57  
58  
59 with us about the diagnosis of the newly-emerged nodule. We continued to  
60  
61  
62  
63  
64  
65

1  
2 perform meticulous observation of the case, and in a CT scan taken five months  
3  
4 later, the tumor had vanished (Fig. 4). No recurrence of the tumor or instrument  
5  
6 failure has been observed until one year after operation (Fig. 5).  
7  
8

9  
10 We routinely check the blood levels of interferon- $\gamma$  (IFN- $\gamma$ ) and  
11  
12 interleukin-12 (IL-12) in patients with metastatic spinal tumors as markers of  
13  
14 antitumor immunity[5]. The checks are performed right before the operation and  
15  
16 one and three months after surgery. In the present patient, the preoperative IFN-  
17  
18  $\gamma$  level was 8.4 UI/ml, and at one month after surgery, the level was 5.8 IU/ml, so  
19  
20 it was not elevated. However, three months after surgery, the level had increased  
21  
22 to 22.2 IU/ml. Similar changes were also observed in the level of IL-12. The  
23  
24 preoperative level of IL-12 was 3.6 pg/ml, which was similar to the level one  
25  
26 month after surgery (3.4 pg/ml), but the level increased up to 18.1 pg/ml three  
27  
28 months after surgery. This suggests that an antitumor immune response might be  
29  
30 activated in this case.  
31  
32  
33  
34  
35  
36  
37  
38

### 39 **Discussion**

40  
41 This is a report of a successful case whose metastatic spinal and lung metastasis  
42  
43 were treated with TES with a liquid nitrogen-frozen tumor specimen. The most  
44  
45 interesting finding of this case was that fact that a newly emerged (postoperative)  
46  
47 lung metastasis vanished without any additional adjuvant therapies.  
48  
49  
50

51 Lung cancer is the leading cause of cancer death, and the rate of lung  
52  
53 adenocarcinoma is increasing. Although the prognosis of lung adenocarcinoma  
54  
55 varies with its histological pattern, the most important factor is the tumor-nodal-  
56  
57 metastasis stage.[9] Bone metastasis is known to be a factor that negatively  
58  
59 impacts the patients' survival.[10] However, our previous study showed that there  
60  
61  
62  
63  
64  
65

1  
2 was a favorable prognosis for patients with lung carcinoma metastasis to the spine  
3  
4  
5 after the TES procedure.[11]

6  
7         At present, the immunotherapy for lung cancer mainly consists of two  
8  
9 strategies, one is which increases the tumor immunogenicity by using cancer  
10  
11 vaccines, and the other overcomes tumor-associated immunosuppression using  
12  
13 immune checkpoint inhibitors.[12] The cryotherapy was used in the present study  
14  
15 with the aim of inducing immunocompetence against the cancer cells by using the  
16  
17 frozen tumor specimen as antigens. We previously reported the successful  
18  
19 treatment of metastatic spinal thyroid cancer with multiple lung metastases using  
20  
21 a similar approach.[5] In that case, the lung metastases gradually decreased in size  
22  
23 and number after the operation. However, that case was also treated with <sup>131</sup>I  
24  
25 therapy after the operation as an adjuvant therapy. In the present case, the  
26  
27 metastatic nodule vanished without any adjuvant therapy.  
28  
29  
30  
31  
32

33  
34         Cryotherapy as systemic therapy for cancer has been gaining interest.  
35  
36 Breast cancer cells treated with cryoablation induced a tumor-specific T-cell  
37  
38 response in mice.[13] The injection of intratumoral dendritic cells following the  
39  
40 cryoablation of prostate cancer prolonged survival and reduced lung metastasis in  
41  
42 mice.[14] All of these reports were promising, but had been performed in rodents,  
43  
44 not humans. There have been few reports of the successful treatment of humans  
45  
46 with cryotherapy.[5, 15] The present report suggests that cryotherapy may  
47  
48 represent a valid systemic cancer therapy.  
49  
50  
51  
52

53  
54         The major limitation of this report is that we could not confirm the  
55  
56 pathological diagnosis of the newly emerged nodule. It is possible that it could  
57  
58 have been an inflammatory mass. However, we strongly suspected that it was a  
59  
60 metastasis, because the nodule enlarged over time. In addition, specialist  
61  
62  
63  
64  
65

1  
2 respiratory surgeons and a radiologist agreed with our assessment. And another  
3  
4  
5 major limitation of this report is that follow-up period was relatively short. The  
6  
7 follow-up period was only one and a half years, and it was not confirmed whether  
8  
9  
10 there was a complete disappearance of the newly emerged nodule.  
11  
12  
13

## 14 **Conclusions**

15  
16  
17 We herein reported the successful treatment of a metastatic spinal tumor with  
18  
19 newly emerged lung metastasis using TES and cryotherapy. TES with a liquid  
20  
21 nitrogen-frozen tumor specimen could be a promising therapeutic option for  
22  
23  
24 cancer patients with spine metastasis as both a local and systemic treatment.  
25  
26  
27  
28  
29  
30  
31  
32  
33  
34  
35  
36  
37  
38  
39  
40  
41  
42  
43  
44  
45  
46  
47  
48  
49  
50  
51  
52  
53  
54  
55  
56  
57  
58  
59  
60  
61  
62  
63  
64  
65



1  
2  
3  
4  
5  
6  
7  
8  
9  
10  
11  
12  
13  
14  
15  
16  
17  
18  
19  
20  
21  
22  
23  
24  
25  
26  
27  
28  
29  
30  
31  
32  
33  
34  
35  
36  
37  
38  
39  
40  
41  
42  
43  
44  
45  
46  
47  
48  
49  
50  
51  
52  
53  
54  
55  
56  
57  
58  
59  
60  
61  
62  
63  
64  
65

**Conflict of interest**

The authors declare no conflicts of interest concerning the materials or methods used in this study or the findings specified in this paper.

1  
2  
3  
4  
5  
6  
7  
8  
9  
10  
11  
12  
13  
14  
15  
16  
17  
18  
19  
20  
21  
22  
23  
24  
25  
26  
27  
28  
29  
30  
31  
32  
33  
34  
35  
36  
37  
38  
39  
40  
41  
42  
43  
44  
45  
46  
47  
48  
49  
50  
51  
52  
53  
54  
55  
56  
57  
58  
59  
60  
61  
62  
63  
64  
65

## References

1. Tomita K, Kawahara N, Baba H, Tsuchiya H, Nagata S, Toribatake Y (1994) Total en bloc spondylectomy for solitary spinal metastases. *Int Orthop* 18:291-298
2. Yao KC, Boriani S, Gokaslan ZL, Sundaresan N (2003) En bloc spondylectomy for spinal metastases: a review of techniques. *Neurosurg Focus* 15:E6
3. Kato S, Murakami H, Demura S, Yoshioka K, Kawahara N, Tomita K, Tsuchiya H (2014) More than 10-year follow-up after total en bloc spondylectomy for spinal tumors. *Annals of surgical oncology* 21:1330-1336. doi: 10.1245/s10434-013-3333-7
4. Yoshioka K, Murakami H, Demura S, Kato S, Kawahara N, Tomita K, Tsuchiya H (2013) Clinical outcome of spinal reconstruction after total en bloc spondylectomy at 3 or more levels. *Spine (Phila Pa 1976)* 38:E1511-1516. doi: 10.1097/BRS.0b013e3182a6427a
5. Murakami H, Kato S, Ueda Y, Fujimaki Y, Tsuchiya H (2014) Reconstruction using a frozen tumor-bearing vertebra in total en bloc spondylectomy can enhance antitumor immunity. *Eur Spine J* 23 Suppl 2:222-227. doi: 10.1007/s00586-013-3056-2
6. Murakami H, Demura S, Kato S, Yoshioka K, Hayashi H, Inoue K, Ota T, Shinmura K, Yokogawa N, Fang X, Tsuchiya H (2014) Systemic antitumor immune response following reconstruction using frozen autografts for total en bloc spondylectomy. *Spine J* 14:1567-1571. doi: 10.1016/j.spinee.2013.09.030
7. Tsuchiya H, Wan SL, Sakayama K, Yamamoto N, Nishida H, Tomita K (2005) Reconstruction using an autograft containing tumour treated by liquid nitrogen. *The Journal of bone and joint surgery British volume* 87:218-225
8. Nishida H, Tsuchiya H, Tomita K (2008) Re-implantation of tumour tissue treated by cryotreatment with liquid nitrogen induces anti-tumour activity against murine osteosarcoma. *The Journal of bone and joint surgery British volume* 90:1249-1255. doi: 10.1302/0301-620X.90B9.20671
9. Lee MC, Kadota K, Buitrago D, Jones DR, Adusumilli PS (2014) Implementing the new IASLC/ATS/ERS classification of lung adenocarcinomas: results from

1  
2 international and Chinese cohorts. *Journal of thoracic disease* 6:S568-580. doi:  
3 10.3978/j.issn.2072-1439.2014.09.13  
4  
5  
6 10. Fujimoto D, Ueda H, Shimizu R, Kato R, Otsoshi T, Kawamura T, Tamai K,  
7  
8 Shibata Y, Matsumoto T, Nagata K, Otsuka K, Nakagawa A, Otsuka K, Katakami N,  
9  
10 Tomii K (2014) Features and prognostic impact of distant metastasis in patients with  
11  
12 stage IV lung adenocarcinoma harboring EGFR mutations: importance of bone  
13  
14 metastasis. *Clinical & experimental metastasis* 31:543-551. doi: 10.1007/s10585-014-  
15  
16 9648-3  
17  
18  
19 11. Murakami H, Kawahara N, Demura S, Kato S, Yoshioka K, Tomita K (2010) Total  
20  
21 en bloc spondylectomy for lung cancer metastasis to the spine. *Journal of*  
22  
23 *neurosurgery Spine* 13:414-417. doi: 10.3171/2010.4.spine09365  
24  
25  
26 12. Mostafa AA, Morris DG (2014) Immunotherapy for Lung Cancer: Has it Finally  
27  
28 Arrived? *Frontiers in oncology* 4:288. doi: 10.3389/fonc.2014.00288  
29  
30 13. Sabel MS, Nehs MA, Su G, Lowler KP, Ferrara JL, Chang AE (2005) Immunologic  
31  
32 response to cryoablation of breast cancer. *Breast cancer research and treatment*  
33  
34 90:97-104. doi: 10.1007/s10549-004-3289-1  
35  
36 14. Machlenkin A, Goldberger O, Tirosh B, Paz A, Volovitz I, Bar-Haim E, Lee SH,  
37  
38 Vadai E, Tzehoval E, Eisenbach L (2005) Combined dendritic cell cryotherapy of  
39  
40 tumor induces systemic antimetastatic immunity. *Clinical cancer research : an*  
41  
42 *official journal of the American Association for Cancer Research* 11:4955-4961. doi:  
43  
44 10.1158/1078-0432.CCR-04-2422  
45  
46 15. Alblin RJ, Soanes WA, Gonder MJ (1971) Prospects for cryo-immunotherapy in  
47  
48 cases of metastasizing carcinoma of the prostate. *Cryobiology* 8:271-279  
49  
50  
51  
52  
53  
54  
55  
56  
57  
58  
59  
60  
61  
62  
63  
64  
65

1  
2  
3  
4  
5  
6  
7  
8  
9  
10  
11  
12  
13  
14  
15  
16  
17  
18  
19  
20  
21  
22  
23  
24  
25  
26  
27  
28  
29  
30  
31  
32  
33  
34  
35  
36  
37  
38  
39  
40  
41  
42  
43  
44  
45  
46  
47  
48  
49  
50  
51  
52  
53  
54  
55  
56  
57  
58  
59  
60  
61  
62  
63  
64  
65

Figure Legend:

Figure 1.

T2-weighted MRI of the thoracic spine. (a) Sagittal view, (b) axial view. The metastatic tumor was at T8 and T9, and partially invaded the upper corner of T10. It also protruded into the spinal canal.

Figure 2.

Lung CT showing the primary lung adenocarcinoma (arrow).

Figure 3.

A postoperative X-ray of the thoracic spine. (a) AP view (b) lateral view

Figure 4.

Pre- and postoperative CT scans showing the growth and disappearance of the lung nodule. (a) Pre-operation, (b) right after the operation, (c) one month after the operation, (d) six months after the operation.

Figure 5.

Postoperative CT scans showing the bone graft packed in the cage. (a) coronal plane (b) sagittal plane.

Figure 5

[Click here to download Figure: Figure5t.TIF](#)

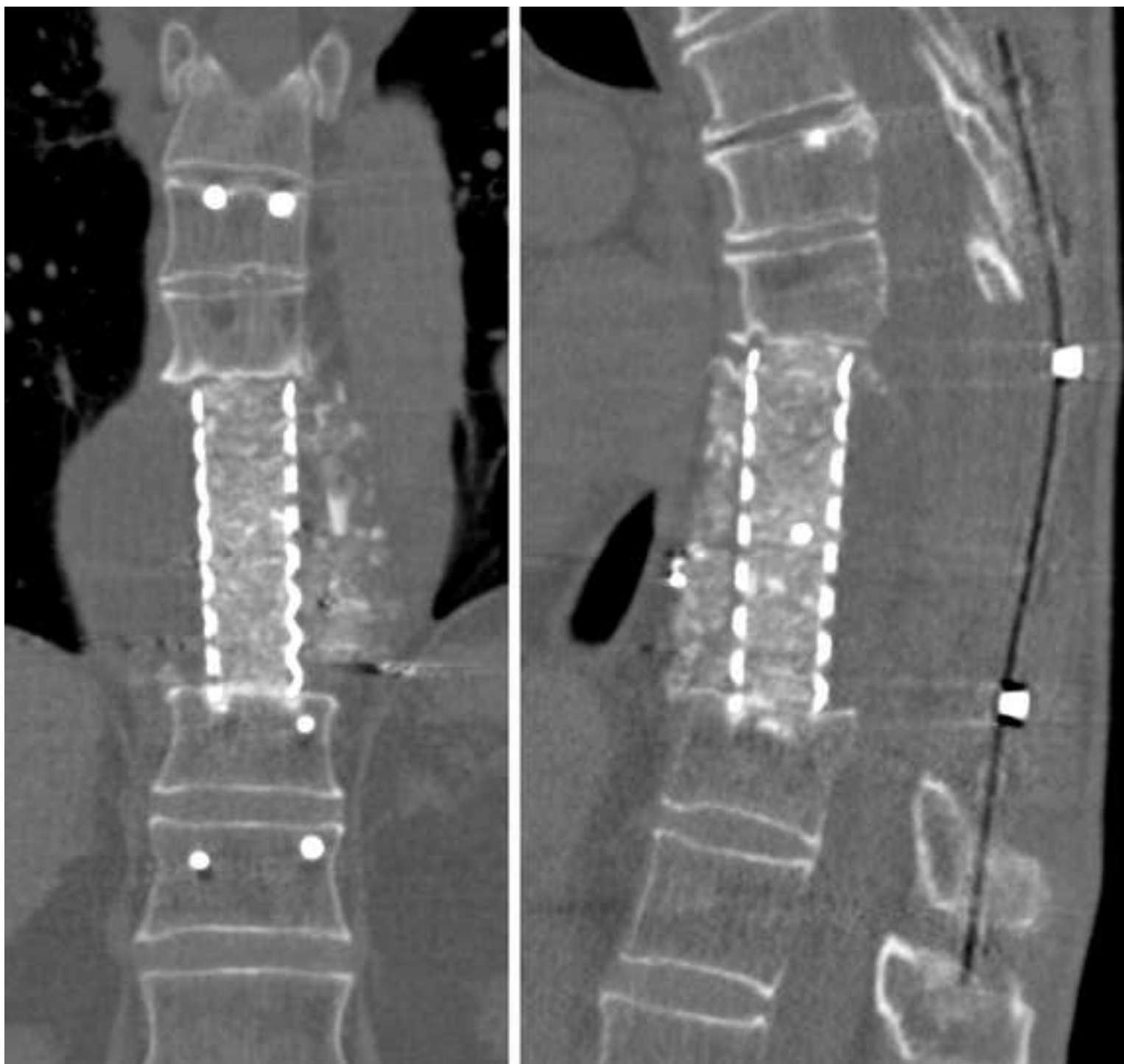

Figure 1  
[Click here to download Figure: Fig1.TIF](#)

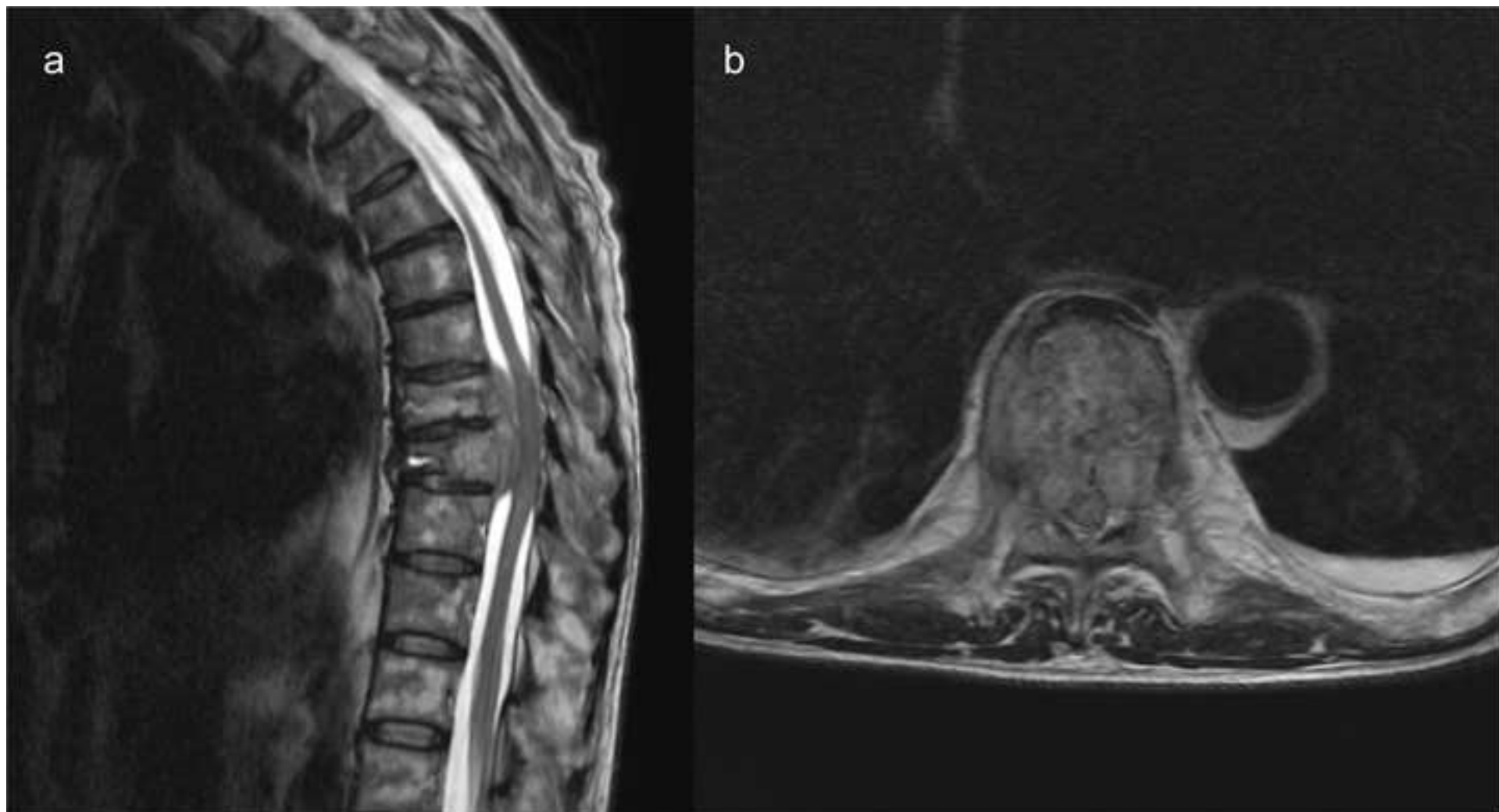


Figure 2

[Click here to download Figure: Figure2.TIF](#)

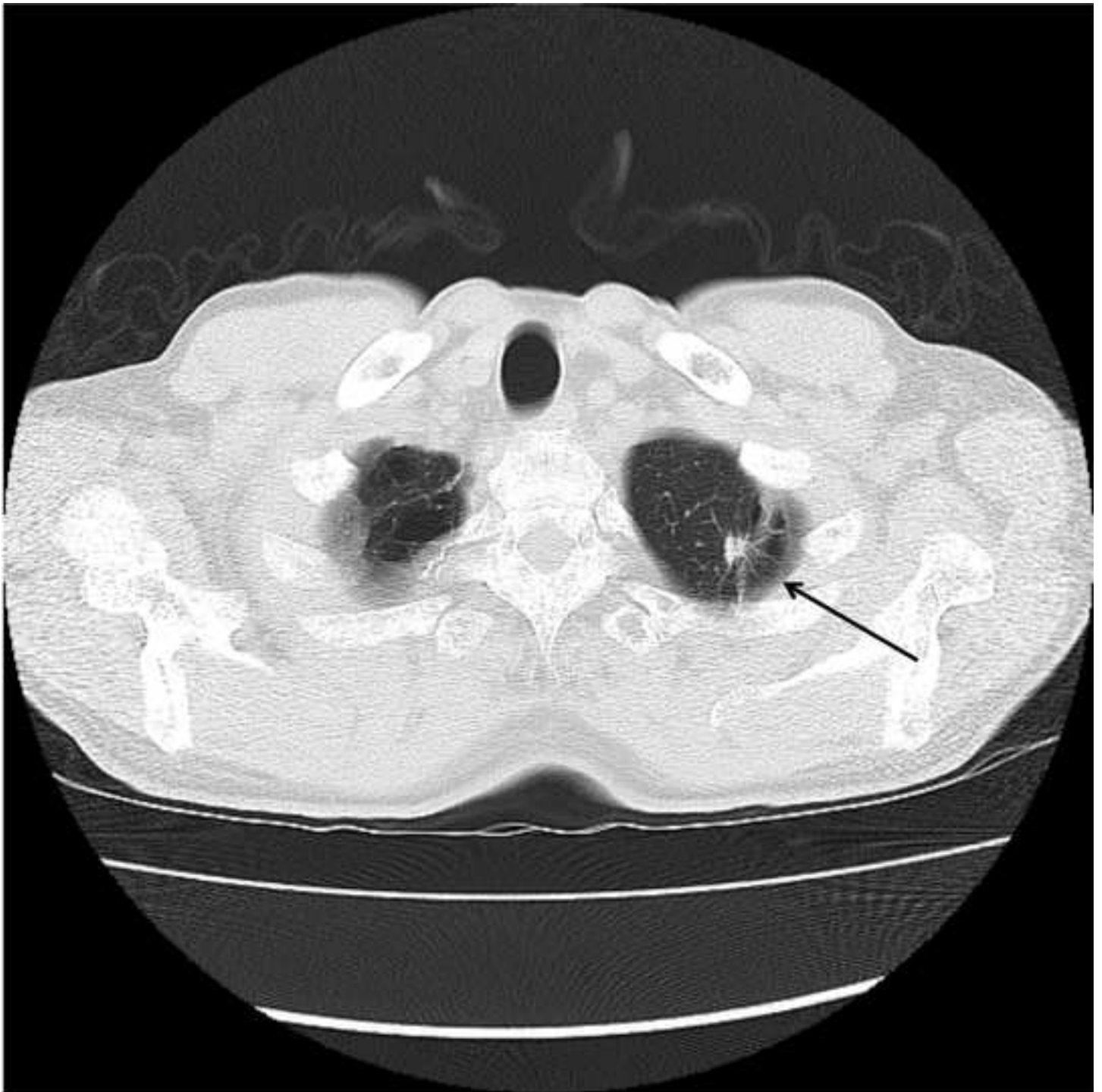


Figure 3  
[Click here to download Figure: Figure3.TIF](#)

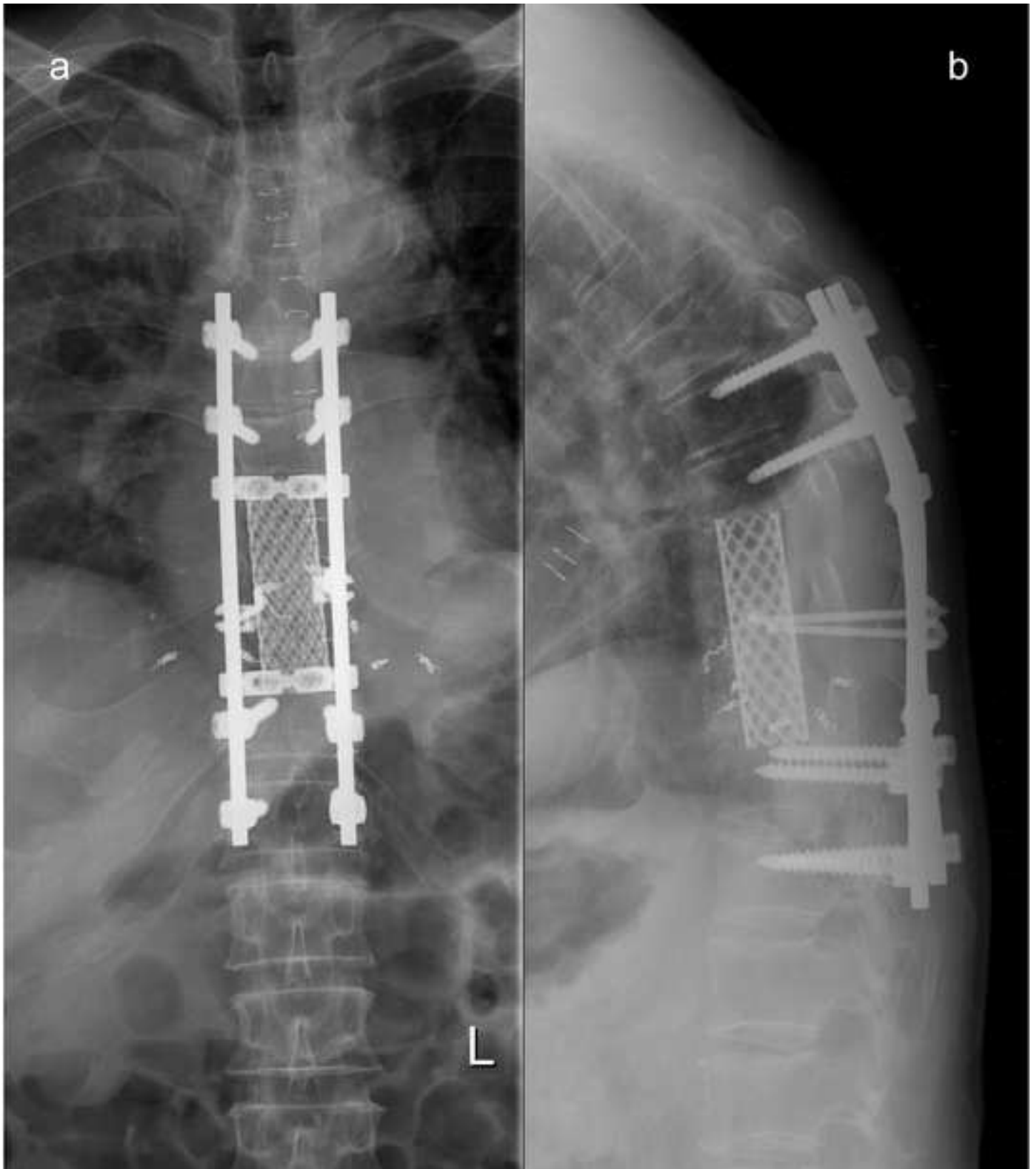




Figure 4  
[Click here to download Figure: Figure4.TIF](#)

