

## Late Onset of Cholesterol Crystal Embolism after Thrombolysis for Cerebral Infarction

Kotaro Oe<sup>1</sup>, Tsutomu Araki<sup>1</sup>, Akikatsu Nakashima<sup>1</sup>, Katsuaki Sato<sup>2</sup>,  
Tetsuo Konno<sup>3</sup> and Masakazu Yamagishi<sup>3</sup>

---

### Abstract

---

A 73-year-old man was admitted to our hospital because of bilateral foot pain. He was treated with thrombolysis for cerebral infarction about 5 months ago. Anticoagulants had not been used because of hemorrhagic infarction. The pulses of bilateral pedal arteries were palpable, but cyanosis was present in the bilateral toes. Laboratory data indicated azotemia and eosinophilia. Magnetic resonance imaging revealed multiple plaques of the thoracic and abdominal aorta, one of which was ulcerated. Skin biopsy proved the diagnosis of cholesterol crystal embolism (CCE). Because no invasive vascular procedure was performed, we assumed that CCE in this patient was related to thrombolysis. We should be cautious for late onset of CCE after thrombolysis.

**Key words:** cholesterol crystal embolism, thrombolysis, cerebral infarction

(*Inter Med* 49: 833-836, 2010)

(DOI: 10.2169/internalmedicine.49.3045)

---

### Introduction

---

Cholesterol crystal embolism (CCE) is a systemic disease resulting from the occlusion of arteries by cholesterol crystals released from atheromatous plaque of the aorta (1). Catheter or surgical manipulation of the aorta is a major cause of CCE, but it can occur spontaneously (2-4), and after thrombolysis or anticoagulants (1). Thirty cases of CCE after thrombolysis have been previously reported, and the duration from the thrombolysis to the onset of CCE ranged from a few hours to 2 months (5). Therefore, whether or not the occurrence of CCE was directly related to thrombolysis was not clear (1). We report a case of CCE which occurred about 5 months after thrombolysis for cerebral infarction.

---

### Case Report

---

A 73-year-old man was admitted to our hospital because of bilateral foot pain. He had a history of smoking two packs per day for 52 years. He had been treated for hypertension for 5 years. He had no history of diabetes mellitus or dyslipidemia. In October 2008, he was admitted to an-

other hospital because of left hemiparesis. Brain magnetic resonance imaging (MRI) revealed occlusion of the right middle cerebral artery. Laboratory data indicated mild renal dysfunction (creatinine, 1.39 mg/dL). Eosinophilia was not present (eosinophil count, 34/mm<sup>3</sup>) and C reactive protein (CRP) was not elevated. He was diagnosed as cerebral infarction and treated with intravenous thrombolysis (alteplase 34,8000 IU/kg: total 31.4 millions IU). On the following day, brain computed tomography revealed large hemorrhagic infarction in the territory of the right middle cerebral artery. Therefore, anticoagulants were not prescribed. In November 2008, he was referred to our hospital for rehabilitation. On admission, his blood pressure was 126/64 mmHg and cyanosis was not present in his toes. Laboratory data revealed that renal function was unchanged (creatinine, 1.25 mg/dL) and eosinophilia was not present (eosinophil count, 216/mm<sup>3</sup>). During hospitalization, he did not complain of foot pain and his blood pressure was stable; he was discharged in March 2009. In April 2009, he complained of bilateral foot pain and was referred to our hospital. On admission, his blood pressure was 151/104 mmHg, and heart rate was 78 beats per minute. Physical examination revealed cyanosis of bilateral toes (Fig. 1). The pulses of bilateral pedal

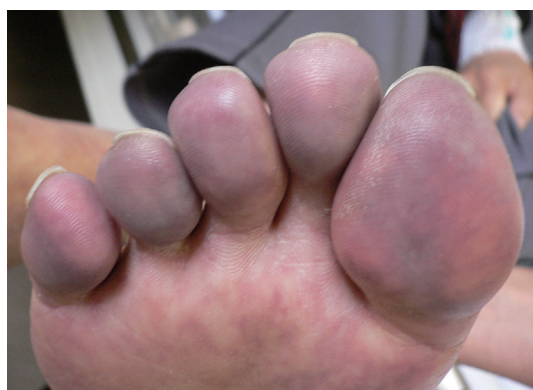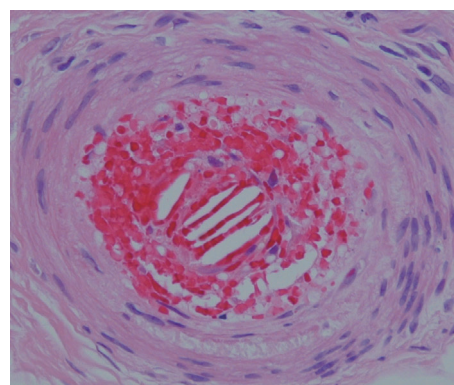
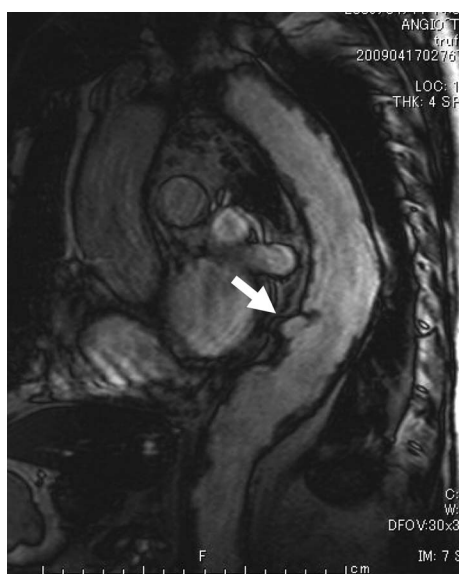---

<sup>1</sup>Division of Internal Medicine, Saiseikai Kanazawa Hospital, Kanazawa, <sup>2</sup>Department of Pathophysiological and Experimental Pathology, Kanazawa Medical University, Kahoku and <sup>3</sup>Division of Cardiovascular Medicine, Kanazawa University Graduate School of Medicine, Kanazawa  
Received for publication October 20, 2009; Accepted for publication January 14, 2010  
Correspondence to Dr. Kotaro Oe, kotaroo316@yahoo.co.jp

**Table 1. Laboratory Data on Admission**

<b>Hematological values</b>		Total cholesterol (mg/dL)	203
White blood cell count (per mm <sup>3</sup> )	7,400	Triglyceride (mg/dL)	124
Neutrophil (%)	59.0	High-density lipoprotein (mg/dL)	43
Lymphocyte (%)	15.8	Glucose (mg/dL)	112
Monocyte (%)	16.2	C reactive protein (mg/mL)	6.78
Eosinophil (%)	8.7	CH50 (U/mL)	58
Red blood cell count (per mm <sup>3</sup> )	304×10 <sup>4</sup>	C3 (mg/dL)	123
Hemoglobin (g/dL)	9.4	C4 (mg/dL)	29.6
Hematocrit (%)	27.5	<b>Coagulation values</b>	
Platelet count (per mm <sup>3</sup> )	15.5×10 <sup>4</sup>	PT (sec)	12.6
<b>Blood chemical values</b>		APTT (sec)	38.0
Creatinine (mg/dL)	5.58	FDP (μg/mL)	7
Blood urea nitrogen (mg/dL)	63.9	D-dimer (μg/mL)	3.7
Na (mEq/L)	133	<b>Urinalysis</b>	
K (mEq/L)	5.3	Protein	(+)
Cl (mEq/L)	99	Glucose	(+)
Total protein (g/dL)	7.2	Occult blood	(+)
Aspartate aminotransferase (IU/L)	85	Red blood cell	1-4/HPF
Alanine aminotransferase (IU/L)	55	White blood cell	5-9/HPF
Lactate dehydrogenase (IU/L)	370	Cast	(-)
Creatine kinase (IU/L)	360		

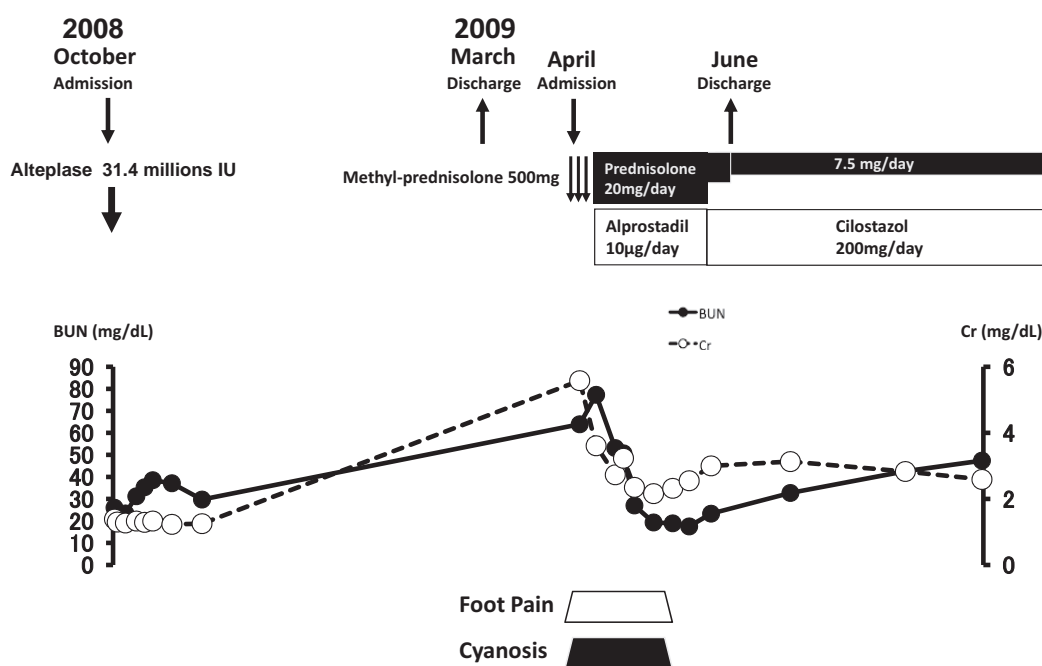
PT: Prothrombin time, APTT: activated partial thromboplastin time, FDP: fibrin and fibrinogen degradation products.

**Figure 1.** Cyanosis of the right toe.**Figure 3.** Skin biopsy of the right toe showed needle-shaped clefts in the lumen of the arteriole (Hematoxylin and Eosin staining).**Figure 2.** Magnetic resonance imaging showed multiple plaques of the thoracic and abdominal aorta, one of which was ulcerated (arrow).

arteries were palpable. Laboratory data indicated azotemia, eosinophilia, anemia and elevation of CRP (Table 1). MRI revealed multiple plaques of the thoracic and abdominal aorta, one of which was ulcerated (Fig. 2). Skin biopsy of the right toe revealed needle-shaped clefts in the lumen of arteriole which is a characteristic finding of CCE (Fig. 3). We diagnosed this case as CCE, and corticosteroid and intravenous prostaglandin E1 therapy were initiated. As no invasive vascular procedure had been performed before admission, we assumed that CCE in this patient was spontaneous or related to thrombolysis. Thereafter, cyanosis and azotemia had gradually improved, and he was discharged in June 2009 (Fig. 4).

## Discussion

CCE is a systemic disease caused by the occlusion of arteries resulting from embolization of atheromatous debris in-



**Figure 4.** Clinical course.

cluding fibrin, platelets, cholesterol crystals, and calcium fragments (1). The atheroemboli typically occlude small arteries of the extremities, brain, eye, kidney or mesentery (1). Catheter or surgical manipulation of the aorta is a major cause of CCE, and anticoagulants or thrombolysis might precipitate CCE (1). Several cases of spontaneous CCE have been reported (2-4).

Because invasive vascular procedures were not performed, CCE in this patient was spontaneous or related to thrombolysis. To our best knowledge, thirty cases of CCE after thrombolysis were reported in the past (5). The mechanism of CCE after thrombolysis is assumed to be via lysed thrombi which cover atherosclerotic plaques and release cholesterol debris into the blood stream (6). In previous reports, CCE occurred a few hours to 2 months after thrombolysis (5), but in the present patient CCE occurred about 5 months after thrombolysis. Coagulation activation was reported to be induced by thrombolysis (7, 8), and anticoagulants were recommended after thrombolysis. As anticoagulants were not used due to hemorrhagic infarction in this patient, new thrombi might have been formed on the ulcerated plaque and thereby prevented the release of cholesterol debris during the early period. Further studies are necessary to clarify whether late CCE could occur after thrombolysis.

Previously reported cases of CCE after thrombolysis were patients with acute myocardial infarction (28 cases) and deep venous thrombosis (2 cases) (5). To date, CCE after

thrombolysis for cerebral infarction has not been reported. Because emergent thrombolysis is frequently performed for fresh cerebral infarction, it is recommended to identify patients at high risk for CCE after thrombolysis. Unstable plaques, such as ulcerated, mobile or non-calcified plaques, in the thoracic aorta are known to be associated with systemic embolism (9, 10). The use of thrombolytic agent is associated with a slightly higher prevalence of ulcerated plaques in acute myocardial infarction (11). Thrombolytic agents are reported to increase the serum level of matrix metalloproteinase 9 (MMP-9) (12, 13), and MMP-9 may play a central role in plaque destabilization (14, 15). Therefore, thrombolysis might have been related to the ulcer formation of aortic plaque in this patient. As in the present case, patients with ulcerated plaques of the aorta may be at high risk for CCE after thrombolysis. Therefore, for patients with unstable plaques of the aorta, careful observation may be necessary after thrombolysis.

## Conclusion

We report a case of late onset of CCE after thrombolysis for cerebral infarction. In patients with cerebral infarction treated with thrombolysis, it is recommended to assess atherosclerosis of the aorta by MRI, and careful observation for CCE is needed in patients with unstable plaques of the aorta.

## References

- Creager MA, Libby P. Peripheral arterial diseases. In: Heart disease. 8th edition. Braunwald E, Ed. Saunders, Philadelphia, 2008: 1509-1511.
- Tan J, Afzal I, Yeadon A, Bird N, Goulesbrough D, Akbani H. Spontaneous cholesterol embolisation causing acute renal failure. *Clin Exp Nephrol* 11: 235-237, 2007.
- Enomae M, Takeda S, Yoshimoto K, Takagawa K. Chronic cholesterol crystal embolism with a spontaneous onset. *Intern Med* 46:

- 1123-1126, 2007.
4. Bradley M. Images in clinical medicine. Spontaneous atheroembolism. *N Engl J Med* **332**: 998, 1995.
  5. Hitti WA, Wali RK, Weinman EJ, Dranchenberg C, Briglia A. Cholesterol embolization syndrome induced by thrombolytic therapy. *Am J Cardiovasc Drugs* **8**: 27-34, 2008.
  6. Pochmalicki G, Feldman L, Meunier P, Rougeot C, Weschler J, Jan F. Cholesterol embolisation syndrome after thrombolytic therapy for myocardial infarction. *Lancet* **339**: 58-59, 1992.
  7. Tanne D, Macko RF, Lin Y, et al. NINDS rtPA Stroke Study Group. Hemostatic activation and outcome after recombinant tissue plasminogen activator therapy for acute ischemic stroke. *Stroke* **37**: 1798-1804, 2006.
  8. Fassbender K, Dempfle CE, Mielke O, et al. Changes in coagulation and fibrinolysis markers in acute ischemic stroke treated with recombinant tissue plasminogen activator. *Stroke* **30**: 2101-2104, 1999.
  9. Stone DA, Hawke MW, LaMonte M, et al. Ulcerated atherosclerotic plaques in the thoracic aorta are associated with cryptogenic stroke: A multiplane transesophageal echocardiographic study. *Am Heart J* **130**: 105-108, 1995.
  10. Sheikhzadeh A, Ehlermann P. Atheromatous disease of the thoracic aorta and systemic embolism. Clinical picture and therapeutic challenge. *Z Kardiol* **93**: 10-17, 2004.
  11. Belle EV, Lablanche JM, Bauters C, Renaud N, McFadden EP, Bertrand ME. Coronary angiographic findings in the infarct-related vessel within 1 month of acute myocardial infarction. Natural history and the effect of thrombolysis. *Circulation* **97**: 26-33, 1998.
  12. Tziakas DN, Chalikias GK, Hatzinikolaou EI, et al. Alteplase treatment affects circulating matrix metalloproteinase concentrations in patients with ST segment elevation acute myocardial infarction. *Thromb Res* **118**: 221-227, 2006.
  13. Horstmann S, Kalb P, Koziol J, Humphrey G, Wagner S. Profiles of matrix metalloproteinases, their inhibitors, and laminin in stroke patients: influence of different therapies. *Stroke* **34**: 2165-2172, 2003.
  14. Jones CB, Sane DC, Herrington DM. Matrix metalloproteinases: a review of their structure and role in acute coronary syndrome. *Cardiovasc Res* **59**: 812-823, 2003.
  15. Loftus IM, Naylor R, Goodall S, et al. Increased matrix metalloproteinase-9 activity in unstable carotid plaques: a potential role in acute plaque disruption. *Stroke* **31**: 40-47, 2000.