

Simple classification of carotid bifurcation: is it possible to predict twisted carotid artery during carotid endarterectomy?

著者	Kamide Tomoya, Nomura Motohiro, Tamase Akira, Mori Kentaro, Seki Shunsuke, Kitamura Yoshihisa, Nakada Mitsutoshi
journal or publication title	Acta Neurochirurgica
volume	158
number	12
page range	2393-2397
year	2016-12-01
URL	http://hdl.handle.net/2297/46185

doi: 10.1007/s00701-016-2948-4

Simple classification of carotid bifurcation: is it possible to predict twisted carotid artery during carotid endarterectomy?

Tomoya Kamide^{a,b}, Motohiro Nomura^{b,c}, Akira Tamase^b, Kentaro Mori^b, Shunsuke Seki^b, Yoshihisa Kitamura^b, Mitsutoshi Nakada^a

^aDepartment of Neurosurgery, Graduate School of Medical Sciences, Kanazawa University, Kanazawa 920-8641, Japan

^bDepartment of Neurosurgery, Yokohama Sakae Kyosai Hospital, Yokohama 247-8581, Japan

^cDepartment of Neurosurgery, Kanto Rosai Hospital, Kawasaki 211-8510, Japan

Corresponding author: Tomoya Kamide

Department of Neurosurgery, Graduate School of Medical Science, Kanazawa University, 13-1 Takara-machi, Kanazawa, Ishikawa 920-8641, Japan

Phone: +81-76-265-2384, Fax: +81-76-234-4262

e-mail: kamide@med.kanazawa-u.ac.jp

Abstract

Background: The internal carotid artery (ICA) usually runs posterolaterally to the external carotid artery (ECA), but occasionally we encounter the twisted carotid bifurcation, a variant in which the ICA courses medially to the ECA during carotid endarterectomy (CEA). Prediction of this anomaly in the preoperative evaluation is mandatory, although descriptions in the literature are limited. We reviewed the clinical features of patients underwent CEA and analyzed preoperative cerebral angiography, especially anteroposterior (AP) view to determine whether it could be a predictive modality.

Methods: In 58 consecutive CEA cases, we simply classified them into 3 groups; type 1 (the ICA runs laterally and the ECA runs medially), type 2 (the ICA and ECA run to overlap each other) and type 3 (the ICA runs medially and the ECA runs laterally), based on the findings of AP view of cerebral angiography. We compared the clinical features and intraoperative findings of those groups.

Results: Of 58 cases, type 1-3 were 24, 30 and 4 cases, respectively. Twisted carotid bifurcations were recognized in 7 cases (12.4%), including 3 cases in type 2 and 4 in type 3, and all twisted cases were found on the right side. Twisted carotids and right-sided lesion were significantly frequent in type 3, but no statistical differences of coexisting diseases were recognized among 3 groups. CEA of twisted carotid bifurcations were performed successfully with correction of the carotid position in 3 and as it was in 4 cases.

Conclusions: Twisted carotid bifurcations were observed during operation in 10% in type 2 and 100% in type 3. CEA of twisted carotid bifurcations can be performed safely with or without correction of the carotid position. AP view of cerebral angiography could be useful for preoperative evaluation.

Key words

Twisted carotid artery, Carotid bifurcation, Carotid endarterectomy, Anteroposterior view

1. Introduction

Carotid artery stenosis is a major risk factor for ischemic stroke, and randomized trials demonstrated that carotid endarterectomy (CEA) reduced the overall stroke risk for symptomatic and asymptomatic patients with severe carotid stenosis [1, 2, 11, 12]. In the procedure, minor modification is sometimes necessary when the case has a vascular anomaly. For example, we occasionally encounter the case with the internal carotid artery (ICA) running medially to the external carotid artery (ECA), in other words, the ICA running behind the ECA and the ECA branches including superior thyroid, lingual and facial arteries crossing the common carotid artery (CCA) and/or ICA in the operative field (Fig. 1). Loftus described this variant as a “side-by-side carotid artery” [7-9], and Sitzer et al reported a “dorsal/dorsomedial origin of the ICA” [14]. In addition, Katano et al reported this as a “twisted carotid bifurcation” [5], but there is only limited information about these unusual situations. Thus, we attempted to clarify the clinical features and to evaluate whether it can be predictable in the preoperative radiological assessment.

2. Patients and Methods

From January 2013 to March 2015, 55 patients underwent 58 consecutive primary CEA procedures. Cerebral angiography was performed preoperatively in all cases and anatomy of carotid bifurcations were divided into 3 groups; type 1 (the ICA runs laterally and the ECA runs medially), type 2 (the ICA and ECA run to overlap each other) and type 3 (the ICA runs medially and the ECA runs laterally) in anteroposterior (AP) view (Fig. 2).

In all cases, surgery was performed basically with rotating the neck about 30°, a short longitudinal incision along the sternocleidomastoid muscle and standard techniques using intraluminal shunts (Pruitt-Inahara, Lemaitre Vascular Inc., Burlington, MA, USA).

Twisted carotid bifurcation was defined the ECA lying posterior or posterolaterally to the ICA, with the superior thyroid artery, and lingual and facial branches were crossing and covering the CCA and/or ICA in the operative field.

The Kruskal-Wallis test was used to compare the 3 groups and Steel-Dwass test was used for comparison between each 2 groups. The Fisher exact probability test and unpaired 2-group t test (Student t test) were used to compare the data for cases with twisted and normal carotid bifurcations. P value less than 0.05 was considered to be statistically significant.

3. Results

A total of 58 consecutive CEA-treated cases (mean age, 73.5 ± 6.5 years; male-female = 47:11; symptomatic-asymptomatic = 30:28) were classified into 3 groups as follows; type 1 was 24 cases (41.4%), type 2 was 30 cases (51.7%) and type 3 was 4 cases (6.9%) (Table 1). During carotid isolation, 7 cases (12.4%) demonstrated twisted carotid bifurcations, including 3 in type 2 (10%) and 4 in type 3 (100%), and these were found on the right side in all cases (Table 2). Although twisted carotid bifurcations and right-sided lesion were significantly frequent in type 3 ($P < 0.01$, 0.015), no significant differences were observed in the other clinical features among these groups. Furthermore, comparing twisted with normal carotid cases, twisted carotid bifurcations were preferentially found on the right side ($P = 0.017$), but no other significant differences of clinical features were recognized, too.

As for twisted carotid bifurcation cases, CEA was performed with a corrected position of the ICA and ECA in 3 cases (2 in type 2 and 1 in type 3), whereas with an inverted position as it was in 4 cases (1 in type 2 and 3 in type 3). In the latter cases, relocation of the superior thyroid artery and the other crossing ECA branches were essential but ligation of those vascular branches were not necessary. Although it was slightly difficult with a technical aspect to perform endarterectomy and closure without correcting position of the ICA and ECA, no statistical differences in carotid clamping and total operative time were observed (data not shown). Surgical procedures could be successfully accomplished in all cases and postoperative courses were uneventful.

4. Discussion

Twisted carotid bifurcation has been reported to be detected by cerebral angiography, ultrasound examination and three dimensional computed tomography ranging in incidence between 4 to 12%, and reaching 16% in elderly patients [3, 10, 13, 15]. However, definitive criteria for this anomaly is absent and epidemiological features of twisted carotid bifurcation have not been understood well [4-6, 10, 14]. Thus, in this study we defined the criteria for twisted carotid bifurcation that the ECA lying posterior or posterolaterally to the ICA, with the superior thyroid artery, and lingual and facial branches were crossing and covering the CCA and/or ICA in the operative field.

All twisted cases were observed in the right carotid bifurcation with significance comparing to the non-twisted cases. Sitzer et al and Katano et al also reported that this anomaly was seen predominantly in the right side [5, 14]. Twisted carotid bifurcation is generally considered to be a result of excessive mediolateral migration of the ECA during embryogenesis, and age-related elongation and tortuosity of the carotid arteries due to atherosclerosis may be another cause [4, 10]. Indeed, Katano et al reported most twisted carotid cases had diabetes mellitus and hypertension as coexisting diseases [5], although not in our cases. In addition, structural differences such as the presence of an anomalous artery on the right side might be concerned with the imbalance in frequency of twisted carotid bifurcation [5]. The reason why the twisted carotids are mostly found in the right side needs to be clarified.

Loftus recommended radical turning of the head to contralateral side to swing the ICA out in the cases of twisted carotid bifurcations, although he named the same condition as a “side-by-side carotid artery” [7-9]. However, he himself indicated that radical rotation led to overlying the sternocleidomastoid muscle on the CCA and carotid bifurcation, which would lead to wrong orientation to the carotid sheath and require a much greater degree of retraction during carotid isolation. We performed CEA with the neck rotated about 30° in all cases not to lead disorientation. We encountered 7 cases (12.4%) demonstrating twisted carotid bifurcations in the procedure, but the frequency might be different if we changed the neck rotation at every case.

We attempted to correct the position of carotid arteries in the surgical procedure of twisted cases. However, we didn't pursue the correction of the carotid position, especially in cases of unstable plaque to prevent embolic infarction due to manipulate the carotid arteries. As a result, in 4 of 7 cases CEA was performed in an inverted position as it was and procedures were safely accomplished without ligation of all crossing vascular branches in all cases. The increase in incidence of superior laryngeal

and vagus nerve injuries in the surgical procedure of twisted carotid cases are still under debate [10], but no case had those injuries in this study.

To predict this anomaly in the preoperative evaluation, we attempted to classify the carotid bifurcation simply into 3 types using AP view of cerebral angiography. We expected type 3 cases were corresponding to twisted carotid bifurcation, but a part of type 2 (10%) cases were also demonstrated this anomaly during CEA. Thus, we have to assume that type 2 cases have the possibility to demonstrate twisted carotid bifurcation in the operative field. Regarding the technical aspects, type 3 cases were more difficult to correct the twisting arteries, although without significance due to small number of twisted cases. We think this simple classification is useful to achieve accurate preoperative planning easily. Further studies are needed to clarify whether the classification is also effective to evaluate the difficulty of correcting twisted arteries.

5. Conclusion

Twisted carotid bifurcation does not seem to be uncommon and are here found in 12.4% of all CEA-treated cases, with especially all cases in type 3 and a part of type 2 cases. Simple classification in AP view of conventional cerebral angiography could be useful to confirm the possibility of twisted carotid bifurcation, in addition, the degree of difficulty to correct the twisted arteries, in the surgical procedure.

Funding

No funding was received for this research.

Conflicts of interest

All authors certify that they have no affiliations with or involvement in any organization or entity with any financial interest (such as honoraria; educational grants; participation in speakers' bureaus; membership, employment, consultancies, stock ownership, or other equity interest; and expert testimony or patent-licensing arrangements), or non-financial interest (such as personal or professional relationships, affiliations, knowledge or beliefs) in the subject matter or materials discussed in this manuscript.

Ethical approval

All procedures performed in studies involving human participants were in accordance with the ethical standards of the institutional and/or national research committee and with the 1964 Helsinki declaration and its later amendments or comparable ethical standards. For this type of study formal consent is not required.

Informed consent

Informed consent was obtained from all individual participants included in the study.

Reference

1. European Carotid Surgery Trialists' Collaborative Group (1991) MRC European Carotid Surgery Trial: interim results for symptomatic patients with severe (70-99%) or with mild (0-29%) carotid stenosis. *The Lancet* 337:1235-1243
2. Executive Committee for the Asymptomatic Carotid Atherosclerosis Study (1995) Endarterectomy for Asymptomatic Carotid Artery Stenosis. *JAMA* 273:1421-1428
3. Hayashi N, Hori E, Ohtani Y, Ohtani O, Kuwayama N, Endo S (2005) Surgical anatomy of the cervical carotid artery for carotid endarterectomy. *Neurol. Med. Chir. (Tokyo)* 45:25-30
4. Kamenskiy AV, Pipinos, II, Carson JS, MacTaggart JN, Baxter BT (2015) Age and disease-related geometric and structural remodeling of the carotid artery. *J. Vasc. Surg.* 62:1521-1528
5. Katano H, Yamada K (2010) Carotid endarterectomy for stenoses of twisted carotid bifurcations. *World Neurosurg.* 73:147-154; discussion e121
6. Koch S, Nelson D, Rundek T, Mandrekar J, Rabinstein A (2009) Race-ethnic variation in carotid bifurcation geometry. *J. Stroke Cerebrovasc. Dis.* 18:349-353
7. Loftus C (1995) Side-by-side positioning. *Carotid endarterectomy. Principles and technique.* St. Louis: Quality Medical Publishing, pp 48-9
8. Loftus C (1995) Side-by-side. *Carotid endarterectomy. Principles and technique.* St. Louis: Quality Medical Publishing, pp 94-5
9. Loftus C (2007) Side-by-side carotid anatomy-exposure. *Carotid endarterectomy. Principles and technique,* 2nd ed. . New York: Informa Healthcare USA, pp 158-9
10. Marcucci G, Accrocca F, Gabrielli R, Antonelli R, Giordano AG, De Vivo G, Siani A (2011) Complete transposition of carotid bifurcation: can it be an additional risk factor of injury to the cranial nerves during carotid endarterectomy? *Interact. Cardiovasc. Thorac. Surg.* 13:471-474
11. MRC Asymptomatic Carotid Surgery Trial (ACST) Collaborative Group (2004) Prevention of disabling and fatal strokes by successful carotid endarterectomy in patients without recent neurological symptoms: randomised controlled trial. *The Lancet* 363:1491-1502
12. North American Symptomatic Carotid Endarterectomy Trial Collaborators (1991) Beneficial effect of carotid endarterectomy in symptomatic patients with high-grade carotid stenosis. *N. Engl. J. Med.* 15:325:445-453

13. Schulz UG, Rothwell PM (2001) Major variation in carotid bifurcation anatomy: a possible risk factor for plaque development? *Stroke* 32:2522-2529
14. Sitzer M, Puac D, Buehler A, Steckel DA, von Kegler S, Markus HS, Steinmetz H (2003) Internal carotid artery angle of origin: a novel risk factor for early carotid atherosclerosis. *Stroke* 34:950-955
15. Thomas JB, Antiga L, Che SL, Milner JS, Steinman DA, Spence JD, Rutt BK, Steinman DA (2005) Variation in the carotid bifurcation geometry of young versus older adults: implications for geometric risk of atherosclerosis. *Stroke* 36:2450-2456

Figure legends

Fig. 1. Intraoperative view of right CEA for a twisted carotid bifurcation case. The ICA runs medially and the ECA runs laterally with superior thyroid artery crossing the CCA.

Fig. 2. Anteroposterior digital subtraction angiographic views. All cases are classified into 3 groups. A (type 1) : The ICA runs laterally and the ECA runs medially. B (type 2) : The ICA and ECA run to overlap each other. C (type 3) : The ICA runs medially and the ECA runs laterally.

Table 1. Classification and characteristics of 58 cases undergoing CEA

	All	Type 1	Type 2	Type 3	P value
n	58	24	30	4	
age	73.5 ± 6.5	72.1 ± 7.6	74.3 ± 5.7	75.5 ± 6.6	.329
male-female	47:11	19:5	25:5	3:1	.883
Symptomatic-Asymptomatic	30:28	15:9	13:17	2:2	.474
Right-Left	31:27	8:16	19:11	4:0	.015
Twisted in CEA (%)	7 (12.1)	0 (0)	3 (10.0)	4 (100)	<0.01
Hypertension (%)	45 (77.6)	18 (75.0)	23 (76.7)	4 (100)	.518
Diabetes mellitus (%)	28 (48.3)	9 (37.5)	17 (56.7)	2 (50.0)	.665
Hyperlipidemia (%)	34 (58.6)	18 (75.0)	14 (46.7)	2 (50.0)	.613
Ischemic heart disease (%)	17 (29.3)	6 (25.0)	10 (33.3)	1 (25.0)	.693

Table 2. Cases with twisted carotid bifurcations

Case	Age	Sex	R/L	A/S	Coex. Dis	Type	Intraop position	Complication
1	69	M	R	S	HT, HL	3	corrected	none
2	73	M	R	A	HL, IHD	2	corrected	none
3	73	M	R	A	HT	2	corrected	none
4	71	M	R	A	HT, DM, HL	3	twisted	none
5	74	M	R	S	HT	2	twisted	none
6	79	M	R	S	HT, IHD	3	twisted	none
7	83	F	R	A	HT, DM	3	twisted	none

M, male; F, female; R, right; S, symptomatic; A, asymptomatic; Coex. Dis, coexisting disease; HT, hypertension; HL, hyperlipidemia; IHD, ischemic heart disease; DM, diabetes mellitus; Intraop, intraoperative.

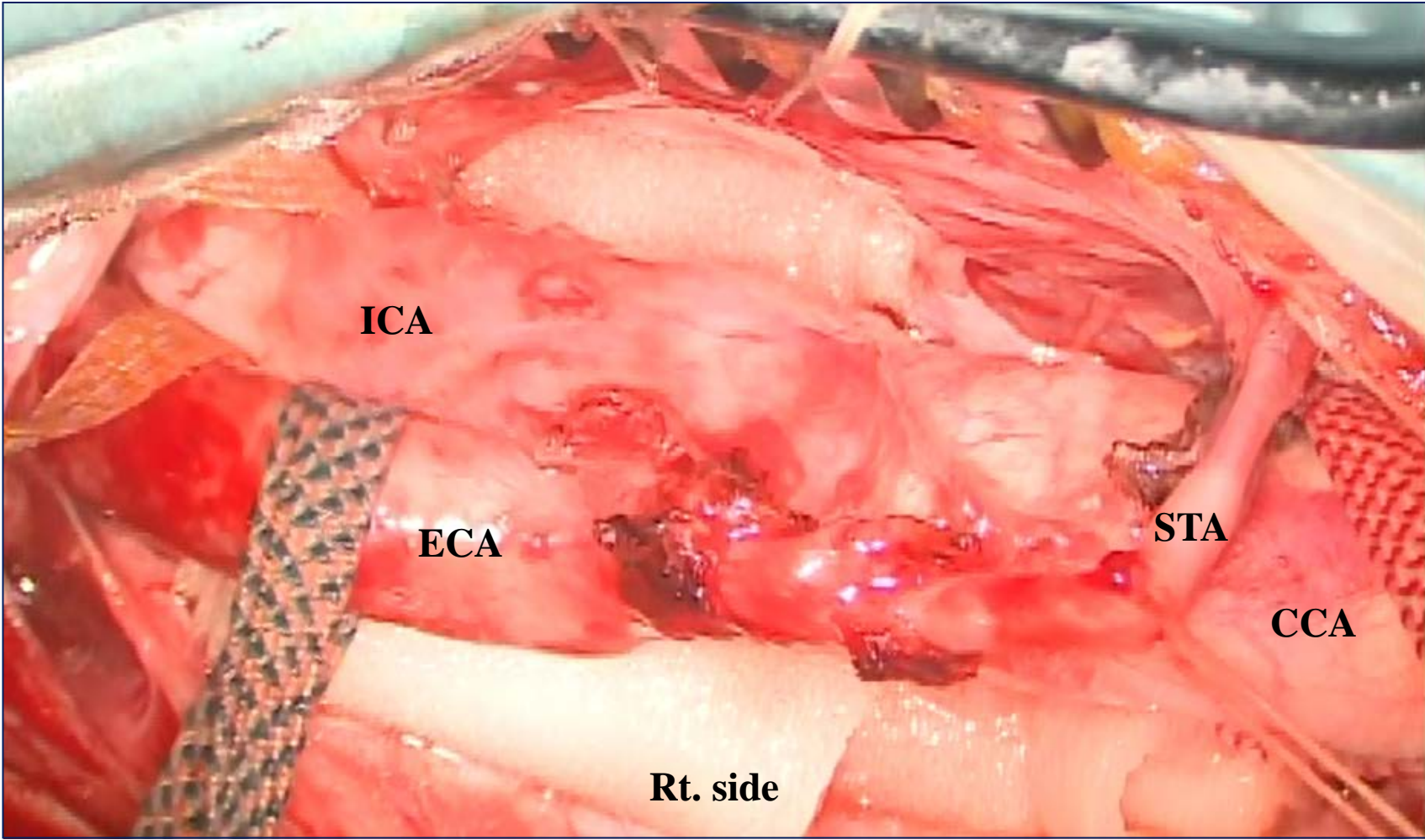


Fig. 1.

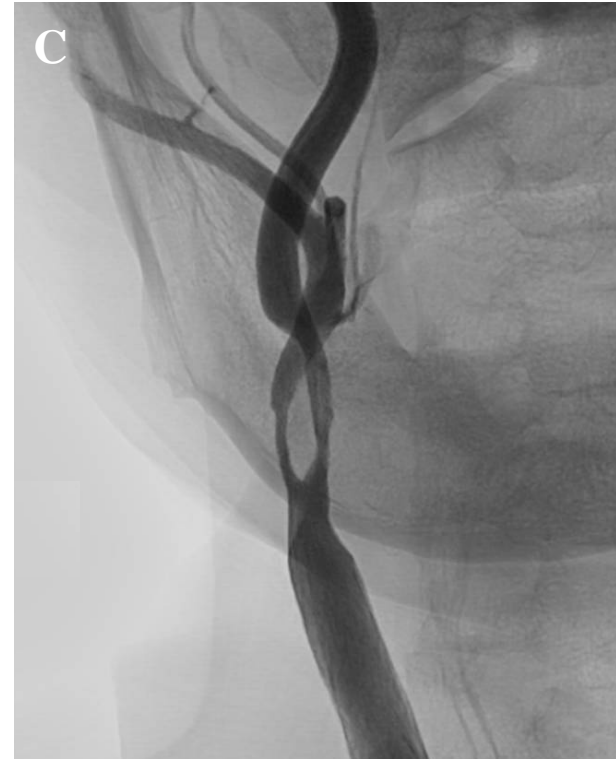
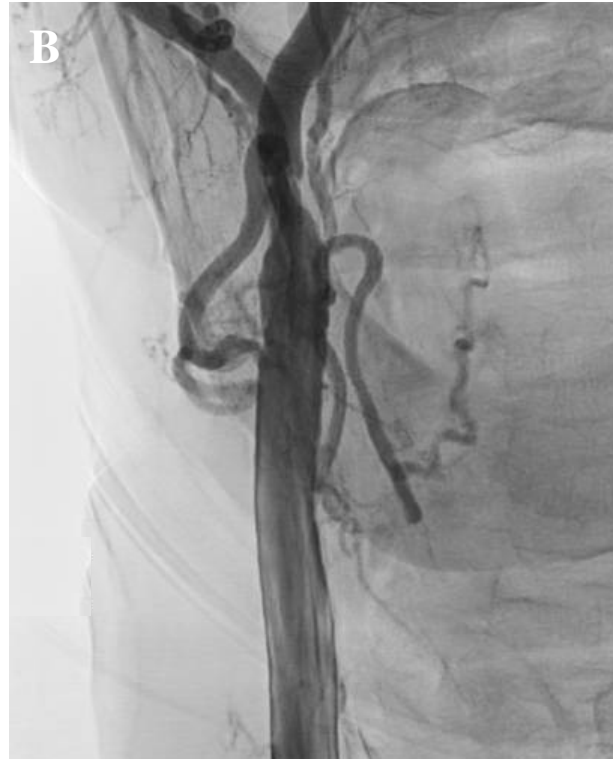
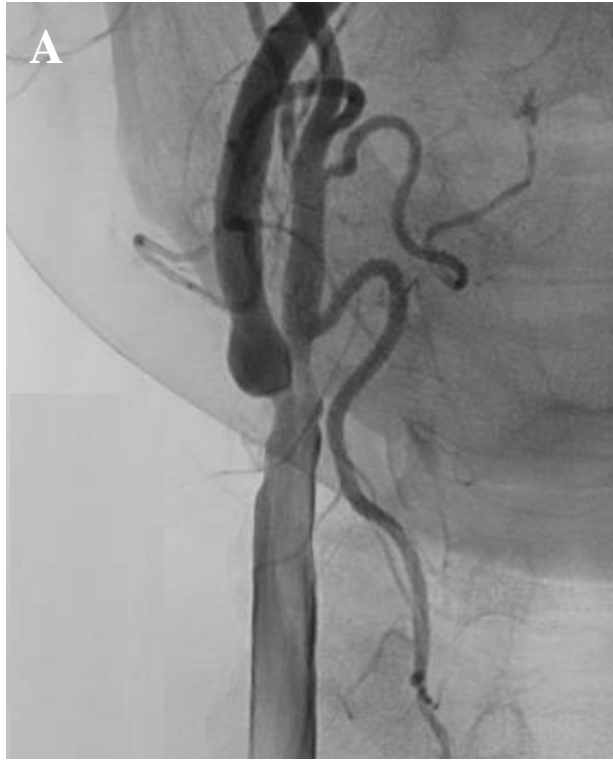Fig. 2.