

Rapid changes in plaque composition and morphology after intensive lipid lowering therapy: study with serial coronary CT angiography.

著者	Shimajima Masaya, Kawashiri Masa-aki, Nitta Yutaka, Yoshida Taiji, Katsuda Shouji, Kaku Bunji, Taguchi Tomio, Hasegawa Akira, Konno Tetsuo, Hayashi Kenshi, Yamagishi Masakazu
journal or publication title	American Journal of Cardiovascular Research
volume	2
number	2
page range	84-88
year	2012-05-15
URL	<a href="http://hdl.handle.net/2297/48420">http://hdl.handle.net/2297/48420</a>

## Original Article

# Rapid changes in plaque composition and morphology after intensive lipid lowering therapy: study with serial coronary CT angiography

Masaya Shimojima<sup>1,2</sup>, Masa-aki Kawashiri<sup>2</sup>, Yutaka Nitta<sup>1</sup>, Taiji Yoshida<sup>1</sup>, Shouji Katsuda<sup>1</sup>, Bunji Kaku<sup>1</sup>, Tomio Taguchi<sup>1</sup>, Akira Hasegawa<sup>3</sup>, Tetsuo Konno<sup>2</sup>, Kenshi Hayashi<sup>2</sup>, Masakazu Yamagishi<sup>2</sup>

<sup>1</sup>Division of Cardiology, Toyama Red Cross Hospital, Toyama, Japan; <sup>2</sup>Division of Cardiovascular Medicine, Kanazawa University Graduate School of Medicine, Kanazawa, Japan; <sup>3</sup>Division of Radiology, Toyama Red Cross Hospital, Toyama, Japan.

Received March 28, 2012; accepted April 25, 2012; Epub May 15, 2012; published June 15, 2012

**Abstract:** Although intensive lipid lowering by statins can enhance plaque stability, few data exist regarding how early statins change plaque composition and morphology in clinical setting. Therefore, to examine early changes in plaque composition and morphology by intensive lipid lowering with statins, we evaluate coronary plaques from acute coronary syndrome (ACS) before and 3 weeks after lipid lowering by coronary CT angiography. We enrolled 110 patients with suspected ACS and underwent coronary CT. We defined plaque as unstable when CT number of plaque < 50HU and remodeling index (lesion diameter/reference diameter) > 1.10. Rosuvastatin (5 mg/day) or atorvastatin (20 mg/day) were introduced to reduce low density lipoprotein cholesterol (LDL-C). Then, CT was again performed by the same condition 3 weeks after lipid lowering therapy. Total 10 patients (8 men, mean age 72.0 years), in whom informed consent regarding serial CT examination was obtained, were analyzed. Among them, 4 patients who denied to have intensive lipid lowering were served as controls. In remaining 6 patients, LDL-C reduced from 129.5±26.9 mg/dl to 68.5±11.1 mg/dl after statin treatment. Under these conditions, CT number of the targeted plaque significantly increased from 16.0±15.9 to 50.8±35.0 HU ( $p < 0.05$ ) and remodeling index decreased from 1.22±0.11 to 1.11±0.06 ( $p < 0.05$ ), although these values substantially unchanged in controls. These results demonstrate that MDCT-determined plaque composition as well as volume could be changed within 3 weeks after intensive lipid lowering. This may explain acute effects of statins in treatment of acute coronary syndrome.

**Keywords:** Computed tomography, HMG-CoA reductase inhibitor, plaques, acute coronary syndrome

## Introduction

Acute coronary syndromes (ACS) such as unstable angina and acute myocardial infarction is caused by the rupture of the atherosclerotic plaque and subsequent thrombosis [1]. Under these conditions, antiplatelet drugs, angiotensin converting enzyme inhibitor,  $\beta$ -blocker and HMG-CoA reductase inhibitors (statins) were shown to decrease the secondary cardiovascular event significantly [2-6]. Particularly statins strongly decrease low-density lipoprotein-cholesterol (LDL-C) and stabilize vulnerable plaque [6, 7]. Indeed, early use of the statin in ACS decreased the plaque volume determined by intravascular ultrasound 6 months after treatment [8]. In not only ACS but also in stable coronary syndrome,

we previously reported that statins reduced coronary plaque volume in Japanese patients [9]. However, few data exist regarding how early statins can change plaque composition and volume in clinical settings.

Recently, coronary plaque composition can be evaluated with not only invasive methods such as IVUS and optical coherence tomography but also with non-invasive one such as coronary CT angiography (CCTA) [10, 11]. Previous studies demonstrated CCTA exhibited good agreement with intravascular ultrasound in terms of evaluating plaque composition [12, 13]. In addition, repeated examination in short term could be done by CCTA except problems regarding use of contrast agent and radiation exposure. The aim

## Changes in plaque after statin

**Table 1.** Patients' characteristics before statin treatment

	Age	Sex	LDL(mg/dl)	HDL(mg/dl)	CT attenuation(HU)	Remodeling index
1	75	male	102	66	21.26	1.13
2	71	male	111	25	11.25	1.12
3	63	male	146	40	-8.43	1.36
4	76	male	113	39	17.00	1.36
5	71	male	174	43	14.25	1.20
6	79	female	131	57	40.83	1.13
	72.0±5.6		129.5±26.9	45±14.5	16.0±15.9	1.22±0.11

of this study was to evaluate changes in plaque composition and morphology in early phase such as 3 weeks after intensive lipid lowering by CCTA.

### Materials and methods

#### *Participants and study design*

We enrolled 110 patients who were suspected of ACS and were examined by 64-slice CCTA from January 2009 to March 2011. Base line characteristics included age, sex, LDL-C, high-density lipoprotein cholesterol (HDL-C) and LDL-C/HDL-C. When unstable plaque defined as described below was detected by CCTA, we administered statins such as rosuvastatin of 5mg/day or atorvastatin of 20 mg/day and re-evaluated the previously-determined coronary plaques 3 weeks later.

#### *Image acquisition*

The 64-slice CCTA scanning (Light Speed VCT, GE, USA) was performed with retrospective ECG gating.  $\beta$ -blocker such as propranolol of 20mg to 60mg was injected before scanning to decrease heart rate to 60 beats/min in average. Nitroglycerin of 0.3 mg was used for coronary artery dilatation. All image acquisitions were performed during a single breath-hold after inspiration. Scanning was performed with condition of effective tube current from 220 mA to 780 mA, effective tube voltage of 120 kV, 0.625 mm slice acquisition, and gantry rotation time of 350 ms. We performed contrast-enhanced scanning using 0.8 ml/kg contrast medium (Iopamidol 370, Bayer Healthcare, Berlin, Germany) during an inspiratory breath-hold.

#### *Image analysis*

CCTA images were analyzed using commercially

available soft ware (Advantage Workstation Volume Share 4.3). For plaque detection, both cross-sectional view, stretched view and curved multiplanar reformation images were used for analysis. Under these conditions, we chose the coronary segment with  $\geq 2$  mm in diameter. The coronary arterial remodeling was defined as a ratio of vessel diameter at the plaque site in comparison with that in the reference segment set proximal to the lesion in a normal-appearing vessel segment (reference segment). The remodeling index (lesion diameter/reference diameter) in cross-sectional view on CCTA was calculated and reported as positive remodeling when the diameter at the plaque site was at least 10% larger than the reference segment [13, 14]. We defined plaque attenuation as minimum CT density of the average of each 3 slices, and defined plaques as unstable when CT value  $\leq 50$ HU [10]. Three weeks after statin therapy, same evaluation before statin therapy was repeatedly performed for follow up patients.

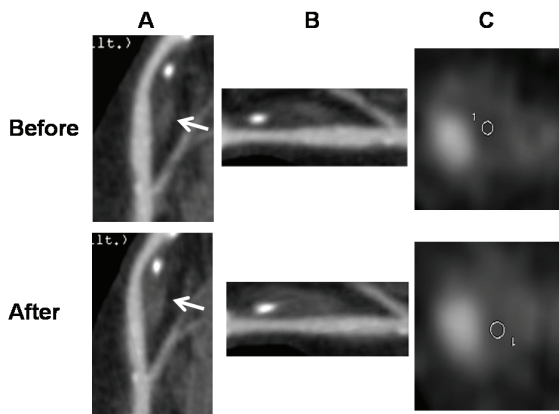
#### *Data analyses*

The quantitative variables are presented as mean  $\pm$  standard deviation and categorical data are shown as proportions. Mean values were compared using the paired t test. P-value  $< 0.05$  indicated a significant difference.

### Results

Among enrolled 110 patients, informed consent regarding the intensive statin therapy and repeated CCTA examination in 3 week was obtained in 6 patients (5 men, mean age 72.0 years, **Table 1**). The remaining 4 agreed with only repeated CT examination without intensive lipid lowering. There were 2 patients with diabetes mellitus, one patient with hypertension, 4 patients with hyperlipidemia and 2 patients with habit of smoking. There were 3 patients prescribing rosuvastatin and 3 patients prescribing

## Changes in plaque after statin

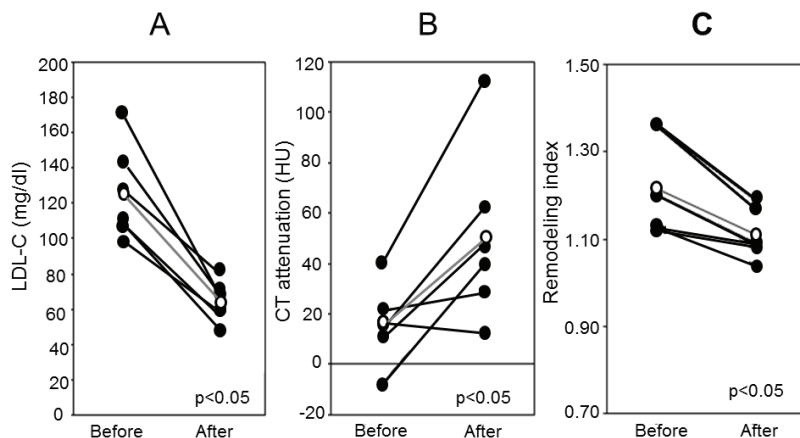


**Figure 1.** Coronary CT images of curved view (A), stretched view (B), and cross sectional view (C) before and after intensive lipid lowering therapy. Arrows indicate the target lesion and circles indicate the region of interests.

atorvastatin. Six of all had coronary plaques which were characterized by positive remodeling and low attenuation.

### Representative case

A 63 year-old Japanese male had acute myocardial infarction and performed percutaneous coronary intervention for left anterior descending coronary artery. We performed CCTA after PCI and atorvastatin of 20 mg was administered. Three weeks after statin therapy, LDL-C decreased from 146mg/dl to 71mg/dl, HDL-C increased from 33mg/dl to 40mg/dl, yielding reduced LDL-C/HDL-C from 3.86 to 2.15. Under these conditions, cross sectional view on MDCT showed the increased signal of target lesion from -8 HU to 39 HU with decreased remodeling index from 1.36 to 1.19 (Figure 1).



**Figure 2.** Changes in low density lipoprotein-cholesterol (LDL-C) (A), in CT attenuation; (B) and in remodeling index (C) before and after intensive lipid lowering therapy. Open circles indicate mean values of each data.

### Lipid profiling and plaque analysis

In all 6 patients, LDL-C decreased significantly from  $129.5 \pm 26.9$  mg/dl to  $68.5 \pm 11.1$  mg/dl, or by 47% ( $p < 0.05$ ) (Figure 2). HDL-C substantially unchanged from  $39.2 \pm 8.8$  mg/dl to  $45.0 \pm 14.5$  mg/dl. Thus, LDL-C/HDL-C decreased significantly from  $3.14 \pm 1.10$  to  $1.80 \pm 0.39$ , or by 42.6%.

CT number of the plaque increased significantly from  $16.0 \pm 15.9$  HU to  $50.8 \pm 35.0$  HU ( $p < 0.05$ ) and remodeling index decreased from  $1.22 \pm 0.11$  to  $1.11 \pm 0.06$  ( $p < 0.05$ ) (Figure 2). In controls, there were no significant changes in these values during 3 weeks. Although it is interesting to correlate changes in LDL-C levels and those in plaque composition and/or morphology, there were no correlations between changes in LDL-C and CT values in the present study.

### Discussion

The present study demonstrates that CCTA-determined plaque composition and morphology can be changed in only 3 weeks after starting intensive lipid lowering with statins. This may explain early effects of statin-induced intensive lipid lowering on prevention of cardiovascular events early after the occurrence of ACS.

Previous clinical trials showed that clinical benefit of statin therapy was observed within one month in patients with ACS [15-17]. However, few data exist demonstrating changes in plaque composition and morphology in early phase after statin therapy except findings observed by carotid ultrasound and virtual histology ultrasound [15, 16]. The present study demonstrates that intensive LDL-C reduction by 47% in average can cause changes in CCTA-determined plaque composition and morphology within only 3 weeks.

In the experimental study, high cholesterol-induced atherosclerotic endothelial dysfunction could be diminished in 2 weeks after statin treatment [18]. In the present study, there were no correlations between changes in LDL-C levels and those in plaque morphology and compositions probably due to small number of patients, although previous invasive studies demonstrated correlation between them [8, 17]. This may be explained by the period of repeated CT examination is too short to obtain the mature changes in plaque morphology and composition.

In the evaluation of plaques, we used CCTA instead of intravascular ultrasound or optical coherence tomography both of which were already established as methods for plaque evaluation. It is reasonable to consider that CCTA was apparently less invasive than intravascular imaging techniques. In addition, recent studies showed the plaque exhibiting positive remodeling and low-attenuation on CCTA was consistent with vulnerable plaque on intravascular ultrasound [12, 19, 20]. Soeda et al evaluated coronary plaque with CCTA before and after statin therapy for 24 weeks [21], and found that CT-determined plaque composition could be changed 24 weeks or 6 months after statin therapy.

### *Clinical implications and limitation*

The most important clinical implication of the present study is how rapid plaque composition and/or morphology could change after intensive lipid lowering. Although experimental studies indicated that atherosclerotic plaque composition changes quickly after discontinuation of high cholesterol diet or starting statin therapy, this should take longer time in clinical setting. Indeed, previous imaging studies were performed by evaluating plaque at least 3 months for intervals. Particularly for ACS patients, we should give statins to establish intensive lipid lowering for 3 weeks, and plaque stabilization can be obtained.

There remain, however, several limitations in the present study. First, the study size was small mainly due to difficulty to obtain the informed consent for the present study in which repeated CT examinations with radiation exposure after intensive lipid lowering therapy were performed. However, it is evident that CCTA-determined plaque composition and morphol-

ogy could be changed rapidly after intensive lipid lowering in ACS patients, although a large-scale randomized control study should be performed to confirm our result. Second, although spatial resolution of 64-slice CCTA has been improved compared to previous CT system, partial volume effect and CT attenuation of coronary lumen influence the CT attenuation of target plaque. We expect more advancement in CT technology to improve spatial resolution, which enable the evaluation of the plaque component precisely.

### **Conclusions**

In the present study, we demonstrate that CCTA-determined plaque composition as well as morphology could be immediately changed after starting intensive lipid lowering in ACS. We suggest that in ACS coronary narrowing as well as plaque composition and morphology should be evaluated by CCTA for possible indication of intensive lipid lowering therapy in these cohorts.

### **Declaration**

None

**Address correspondence to:** Dr. Masakazu Yamagishi, Kanazawa University Graduate School of Medicine, 13-1 Takara-machi, Kanazawa, Ishikawa 9208641, Japan Tel: 81-76-265-2259; Fax: 81-76-234-4210; E-mail: myamagi@med.kanazawa-u.ac.jp

### **References**

- [1] Ross R. Atherosclerosis—an inflammatory disease. *N Engl J Med* 1999; 340: 115-126.
- [2] Ueshima K, Fukami K, Hiramori K, Hosoda S, Kishida H, Kato K, Fujita T, Tsutani K and Sakuma A. Is angiotensin-converting enzyme inhibitor useful in a Japanese population for secondary prevention after acute myocardial infarction? A final report of the Japanese Acute Myocardial Infarction Prospective (JAMP) study. *Am Heart J* 2004; 148: e8.
- [3] Dargie HJ. Effect of carvedilol on outcome after myocardial infarction in patients with left-ventricular dysfunction: the CAPRICORN randomised trial. *Lancet* 2001; 357: 1385-1390.
- [4] Yasue H, Ogawa H, Tanaka H, Miyazaki S, Hattori R, Saito M, Ishikawa K, Masuda Y, Yamaguchi T, Motomiya T and Tamura Y. Effects of aspirin and trapidil on cardiovascular events after acute myocardial infarction. Japanese Antiplatelets Myocardial Infarction Study (JAMIS) Investigators. *Am J Cardiol* 1999; 83: 1308-1313.
- [5] Pfeffer MA, Braunwald E, Moyer LA, Basta L,

- Brown EJ, Jr., Cuddy TE, Davis BR, Geltman EM, Goldman S, Flaker GC and et al. Effect of captopril on mortality and morbidity in patients with left ventricular dysfunction after myocardial infarction. Results of the survival and ventricular enlargement trial. The SAVE Investigators. *N Engl J Med* 1992; 327: 669-677.
- [6] Schwartz GG, Olsson AG, Ezekowitz MD, Ganz P, Oliver MF, Waters D, Zeiher A, Chaitman BR, Leslie S and Stern T. Effects of atorvastatin on early recurrent ischemic events in acute coronary syndromes: the MIRACL study: a randomized controlled trial. *JAMA* 2001; 285: 1711-1718.
- [7] Cannon CP, Braunwald E, McCabe CH, Rader DJ, Rouleau JL, Belder R, Joyal SV, Hill KA, Pfeffer MA and Skene AM. Intensive versus moderate lipid lowering with statins after acute coronary syndromes. *N Engl J Med* 2004; 350: 1495-1504.
- [8] Okazaki S, Yokoyama T, Miyauchi K, Shimada K, Kurata T, Sato H and Daida H. Early statin treatment in patients with acute coronary syndrome: demonstration of the beneficial effect on atherosclerotic lesions by serial volumetric intravascular ultrasound analysis during half a year after coronary event: the ESTABLISH Study. *Circulation* 2004; 110: 1061-1068.
- [9] Takayama T, Hiro T, Yamagishi M, Daida H, Hirayama A, Saito S, Yamaguchi T and Matsuzaki M. Effect of rosuvastatin on coronary atheroma in stable coronary artery disease: multicenter coronary atherosclerosis study measuring effects of rosuvastatin using intravascular ultrasound in Japanese subjects (COSMOS). *Circ J* 2009; 73: 2110-2117.
- [10] Motoyama S, Kondo T, Anno H, Sugijura A, Ito Y, Mori K, Ishii J, Sato T, Inoue K, Sarai M, Hishida H and Narula J. Atherosclerotic plaque characterization by 0.5-mm-slice multislice computed tomographic imaging. *Circ J* 2007; 71: 363-366.
- [11] Sato Y, Inoue F, Yoshimura A, Fukui T, Imazeki T, Kato M, Ono H, Yoda S, Mitsui M, Matsumoto N, Furuhashi S, Takahashi M and Kanmatsuse K. Regression of an atherosclerotic coronary artery plaque demonstrated by multislice spiral computed tomography in a patient with stable angina pectoris. *Heart Vessels* 2003; 18: 224-226.
- [12] Leber AW, Becker A, Knez A, von Ziegler F, Sirol M, Nikolaou K, Ohnesorge B, Fayad ZA, Becker CR, Reiser M, Steinbeck G and Boekstegers P. Accuracy of 64-slice computed tomography to classify and quantify plaque volumes in the proximal coronary system: a comparative study using intravascular ultrasound. *J Am Coll Cardiol* 2006; 47: 672-677.
- [13] Schroeder S, Kopp AF, Baumbach A, Meisner C, Kuettner A, Georg C, Ohnesorge B, Herdeg C, Claussen CD and Karsch KR. Noninvasive detection and evaluation of atherosclerotic coronary plaques with multislice computed tomography. *J Am Coll Cardiol* 2001; 37: 1430-1435.
- [14] Motoyama S, Sarai M, Harigaya H, Anno H, Inoue K, Hara T, Naruse H, Ishii J, Hishida H, Wong ND, Virmani R, Kondo T, Ozaki Y and Narula J. Computed tomographic angiography characteristics of atherosclerotic plaques subsequently resulting in acute coronary syndrome. *J Am Coll Cardiol* 2009; 54: 49-57.
- [15] Toi T, Taguchi I, Yoneda S, Kageyama M, Kikuchi A, Tokura M, Kanaya T, Abe S, Matsuda R and Kaneko N. Early effect of lipid-lowering therapy with pitavastatin on regression of coronary atherosclerotic plaque. Comparison with atorvastatin. *Circ J* 2009; 73: 1466-1472.
- [16] Nakamura T, Obata JE, Kitta Y, Takano H, Kobayashi T, Fujioka D, Saito Y, Kodama Y, Kawabata K, Mende A, Yano T, Hirano M, Sano K, Nakamura K and Kugiyama K. Rapid stabilization of vulnerable carotid plaque within 1 month of pitavastatin treatment in patients with acute coronary syndrome. *J Cardiovasc Pharmacol* 2008; 51: 365-371.
- [17] Nissen SE, Tuzcu EM, Schoenhagen P, Brown BG, Ganz P, Vogel RA, Crowe T, Howard G, Cooper CJ, Brodie B, Grines CL and DeMaria AN. Effect of intensive compared with moderate lipid-lowering therapy on progression of coronary atherosclerosis: a randomized controlled trial. *JAMA* 2004; 291: 1071-1080.
- [18] Nachtigal P, Kopecky M, Solichova D, Zdansky P, Semecky V. The changes in the endothelial expression of cell adhesion molecules and iNOS in the vessel wall after the short-term administration of simvastatin in rabbit model of atherosclerosis. *J Pharm Pharmacol*. 2005; 57: 197-203.
- [19] Kitagawa T, Yamamoto H, Horiguchi J, Ohashi N, Kunita E, Utsunomiya H and Kihara Y. Effects of statin therapy on non-calcified coronary plaque assessed by 64-slice computed tomography. *Int J Cardiol* 2011; 150: 146-150
- [20] van Werkhoven JM, Heijenbrok MW, Schuijff JD, Jukema JW, Boogers MM, van der Wall EE, Schreur JH and Bax JJ. Diagnostic accuracy of 64-slice multislice computed tomographic coronary angiography in patients with an intermediate pretest likelihood for coronary artery disease. *Am J Cardiol* 2010; 105: 302-305.
- [21] Soeda T, Uemura S, Okayama S, Kawakami R, Sugawara Y, Nakagawa H, Matsumoto T, Sung JH, Nishida T, Senoo A, Somekawa S, Takeda Y, Ishigami K, Kawata H, Horii M and Saito Y. Intensive lipid-lowering therapy with rosuvastatin stabilizes lipid-rich coronary plaques. - Evaluation using dual-source computed tomography. *Circ J* 2011; 75: 2621-2627.