

Progression of Interstitial Lung Disease Upon Overlapping of Systemic Sclerosis with Polymyositis

Takashi Ishiguro, Masahide Yasui, Hazuki Takato, Hideharu Kimura, Nobuyuki Katayama, Kazuo Kasahara and Masaki Fujimura

Abstract

We describe a 73-year-old woman with systemic sclerosis (SSc)-polymyositis (PM) overlap syndrome, primarily SSc followed by PM. She had suffered from SSc and had interstitial pneumonia (IP), which was stable. Eight years after the initial diagnosis of SSc, proximal muscle weakness, myalgia, and dyspnea on effort developed. A chest computed tomography (CT) showed reticular shadows, and serum markers of IP such as KL-6 and surfactant protein-D were elevated at 1,170 U/mL and 176 ng/mL, respectively. Bronchoalveolar lavage fluid showed a remarkably increased number of lymphocytes. Exacerbation of SSc-IP 8 years after the initial diagnosis of SSc is not usual, and a marked increase in the number of lymphocytes in bronchoalveolar lavage fluid is also uncommon in SSc-IP, indicating overlap of another connective tissue disease. The diagnostic criteria for PM were satisfied; thus, SSc-PM overlap syndrome was diagnosed. We emphasize the need to investigate whether another connective tissue disease has developed when symptoms or laboratory findings cannot be explained by the usual clinical course of an existing connective tissue disease.

Key words: systemic sclerosis, pulmonary involvement, polymyositis, overlap syndrome

(DOI: 10.2169/internalmedicine.46.0135)

Introduction

Systemic sclerosis (SSc) is a systemic disorder characterized by inflammation, fibrosis, and vascular obliteration of the skin and visceral organs. SSc patients occasionally develop clinical or serological feature of other connective tissue diseases, such as polymyositis (PM), dermatomyositis, and systemic lupus erythematosus.

We describe a 73-year-old woman with SSc-PM overlap syndrome, primarily SSc followed by PM. SSc-PM overlap syndrome is a clinical entity with the clinical features of both SSc and PM. The patient was already suffering SSc with interstitial pneumonia (IP), and the IP had been stable. A fresh lesion developed in her lungs 8 years after the diagnosis of SSc; this is unusual for SSc-IP. Further examination revealed that the diagnostic criteria for PM were satisfied. A fresh lesion seemed to be due to the appearance of PM. This is a valuable case, in which it was observed that the pulmonary lesion due to an existing connective tissue disease was accompanied by a new pulmonary lesion due to a new over-

lapping condition, and it is therefore believed that reporting this case is worthwhile.

Case Report

A 73-year-old woman was admitted to Kanazawa University Hospital in March 2006 because of dyspnea on effort. She had been generally well until 1998, when she noticed pallor in her fingers after exposure to cold. She visited our hospital for complete examination by dermatology specialists and was admitted in January 1999. Upon physical examination, sclerodermatous skin change was found on her hands, feet, forearms, and face. A small ulceration was noted on the tip of each finger. Auscultation revealed no rales and a roentgenogram showed no abnormalities; however, a chest computed tomography (CT) revealed bilateral and slight ground-glass opacities in the subpleural region. Respiratory function tests were performed, and parameters were within normal limits (Table 1). An autoantibody against U3 ribonucleoprotein (U3-RNP), which is highly specific to SSc, was found by immunoprecipitation. Diffuse

Table 1. Results of Pulmonary Function Tests Over Time

	Nov-99	Apr-03	Feb-06	Mar-06	Jun-06
Functional residual capacity (L)	2.43	2.79	2.54	2.46	2.51
(% predicted)	129.2	129.2	116.5	115.5	117.8
Residual volume (RV) (L)	1.72	1.73	1.63	1.39	1.55
(% predicted)	121.5	119.3	110.7	95.9	106.9
Total lung capacity (TLC) (L)	4.95	4.91	3.63	3.49	3.56
(% predicted)	129.5	96.8	96	94.3	96.2
RV/TLC (%)	34.7	35.2	44.9	39.8	43.5
(% predicted)	93.7	123.1	115.4	101.5	111
Diffusing capacity of CO (ml/min/Torr)	16.75	15.11	13.06	9.99	9.98
(% predicted)	82.2	74.9	65.4	50.6	50.5
DLco/VA (ml/min/Torr/L)	4.14	3.86	3.86	3.39	3.65
(% predicted)	81.5	77.4	82.9	68.9	74.2
Vital capacity (L)	3.16	3.3	2.14	2.23	2.23
(% predicted)	137.1	146.7	97.3	102.3	102.3
FEV1 (L)	2.54	2.51	1.71	1.81	1.77
(% predicted)	151.2	158.9	114	111.1	122.9
FEV1/FVC ratio (%)	82.7	78.7	79.9	81.2	85.5

FEV1 = forced expiratory volume in 1 second

SSc was diagnosed, and prednisolone (PSL) was administered, beginning at 20 mg/day and then tapered to 5 mg/day. The patient's condition and laboratory data including KL-6 and SP-D remained stable until July 2005, when proximal muscle weakness (grade 3-4 according to Daniel's manual muscle test) and pain of the thighs and upper arms developed. Blood tests revealed an erythrocyte sedimentation rate of 58 mm. Levels of muscle-associated enzymes were extremely high, including creatine phosphokinase (CPK) at 701 U/L (normal 25 to 145 U/L), GOT (AST) at 61 IU/L (normal range below 40 IU/L), aldolase at 17 IU/L (normal <7.6 U/L); creatinuria (45.8%) was also found. Anti-Jo-1 antibody was detected by both ELISA and immunoprecipitation, although the antibody was not found in January 2000. Electromyography (EMG) showed short-duration, low amplitude potentials. On the basis of the clinical symptoms, EMG findings, and serologic findings, the presence of PM was established in accordance with the diagnostic criteria (1), SSc-PM overlap syndrome was diagnosed. PSL was increased to 25 mg/day, and this was followed by improvement in symptoms including the muscle weakness and pain. The CPK level returned to normal, and the PSL was tapered to 12.5 mg/day. In March 2006, dyspnea on effort (Fletcher Hugh Jones III) developed. Chest CT showed that the lower lobes of the lungs had shrunken. KL-6 had increased to 1,050 U/ml. A dermatology specialist consulted us, and the patient was re-admitted to our hospital in March 2006 for further evaluation and treatment.

Upon admission, physical examination revealed Raynaud's phenomenon. The patient's fingers were sclerodermic, and the skin of the trunk was thick and hard; however, changes characteristic of dermatomyositis were not seen. The cardiopulmonary system seemed normal except for fine basilar crepitations. Neurologic examination revealed no muscle weakness or atrophy. Results of urinalysis were normal. Anti-nuclear antibody was positive by immunofluorescence testing. The anti-nuclear antibody titer was high (1 :

5,120). Anti-Jo-1 and anti-U3 RNP antibodies were positive (anti-Jo-1 by ELISA and immunoprecipitation, anti-U3 RNP antibody by immunoprecipitation), although other autoantibodies such as anti-U1/U2, anti-Sm, anti-Scl 70, anti-SS-A, and anti SS-B, were not detected. KL-6 and surfactant protein-D (SP-D) were elevated to 1,170 IU/L and 176 ng/ml, respectively, although CPK and aldolase levels were within normal ranges. Electrocardiography (ECG) and echocardiography showed no abnormalities including right ventricular overload. A chest roentgenogram showed reticular shadows in the lower lung fields (Fig. 1). The minor fissure appeared lower than it had in January 1999 and December 2005, indicating volume loss of the lower lobes. Chest CT showed reticular shadows, traction bronchiectasis, and linear opacities in the lower lobes with absence of typical honeycombing (Non Specific IP pattern) (Fig. 2). Volume loss of the lower lobes had progressed in comparison to that seen in 1999, and fresh ground-glass opacities and reticular shadows were seen. Respiratory function tests were performed (Table 1), and RV, TLC, DLco had decreased, even since February 2006. These findings indicated continued deterioration of pulmonary function despite complete resolution of the muscular symptoms.

Bronchoalveolar lavage (BAL) was performed. The total cell count was 1.8×10^5 cells/ml, with 48.7 % macrophages, 1.7% neutrophils and 49.3% lymphocytes, which were atypical of SSc-IP.

On the basis of the clinical symptoms, EMG findings, and serologic findings, PM was diagnosed, pointing to SSc-PM overlap syndrome. Treatment with a combination of PSL and cyclosporine was started for IP; however, abnormal electrolysis (elevation of serum potassium to 6.0 mEq/L) occurred. We stopped the cyclosporine and used PSL alone at 40 mg/day. The PaO₂ improved to 98.7 mmHg. KL-6 and SP-D decreased to 401 U/ml and 36.8 ng/ml, respectively (Fig. 3), and the dyspnea on effort disappeared. Pulmonary function tests showed improvement of functional residual

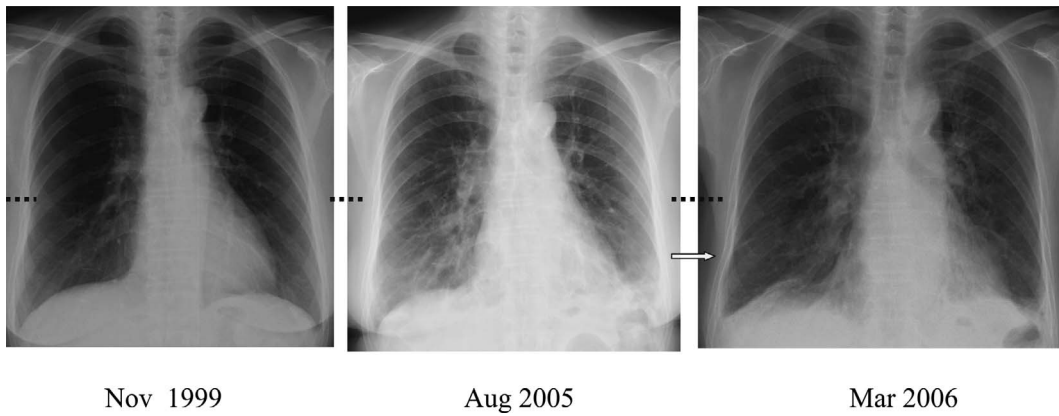


Figure 1. Chest roentgenograms obtained over the clinical course. Reticular shadows are seen in the lower lung fields. The minor fissure in March 2006 (An arrow) is lower than it was in 1999 and 2005 (dotted lines).

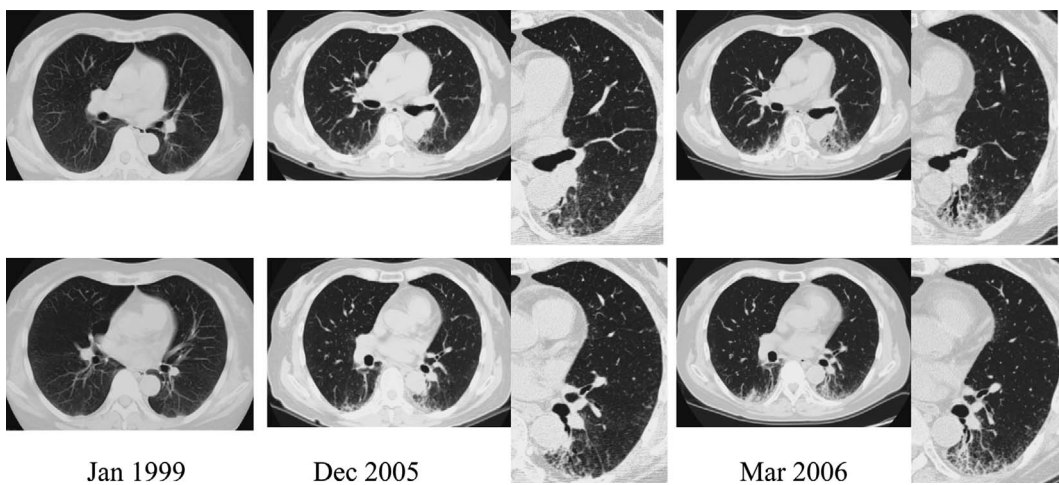


Figure 2. Chest CT scan obtained over the clinical course. Some reticular shadows were seen in the posterior the lower lobes in 1999. The lower lobes were smaller, and traction bronchiectasis and linear opacities were seen in December 2005. In March 2006, fresh ground glass opacities and reticular shadows were seen.

capacity to 2.51 L, RV to 1.55 L, TLC to 3.56 L, and DLco to 9.98 ml/min/Torr (Table 1). PSL was tapered to 20 mg at 5 mg every 2 weeks, and the patient was discharged for out-patient care.

Discussion

Systemic sclerosis is an autoimmune disease characterized by a wide spectrum of clinical, pathologic, and serologic abnormalities. Circulating antibodies against a variety of nuclear and nucleolar antigens are detected in more than 95% of patients (2). SSc patients occasionally develop clinical or serological features of other connective tissue diseases, such as PM, dermatomyositis, and systemic lupus erythematosus, resulting in an overlap syndrome. The presence of anti-Ku antibody (3), anti-PM-Scl antibody (4), or anti-U1/U2 RNP antibody has been reported in patients with an SSc overlap syndrome. Anti-Ku antibody is detected in about 50% of pa-

tients in Japan with SSc-PM overlap syndrome. Anti-PM-Scl antibody is detected specifically in North American patients with SSc-PM overlap syndrome; this antibody is seldom seen in such patients in Japan, and only 10% of Caucasians with SSc-PM overlap syndrome show detectable levels of anti-Ku antibody (5). The reason for the differences in the presence of these antibodies is not clear; genetic backgrounds and environmental factors may play a role. We did not find any of these antibodies in the present patient.

We did find autoantibody to U3 RNP (fibrillarin). Fibrillarin is an RNP particle that contains U3-RNA and is located in the fibrillar regions of nucleoli. The protein of the U3 RNP particle that contains the anti-genetic determinants is a 34-kd nucleolar protein. Anti-U3 RNP antibody is found in approximately 6% of SSc patients, and its presence in serum is highly specific to SSc (6, 7). Although Kuwana et al reported that anti-U3 RNP antibody is frequently detected in black patients with overlap syndrome (8), this antibody is

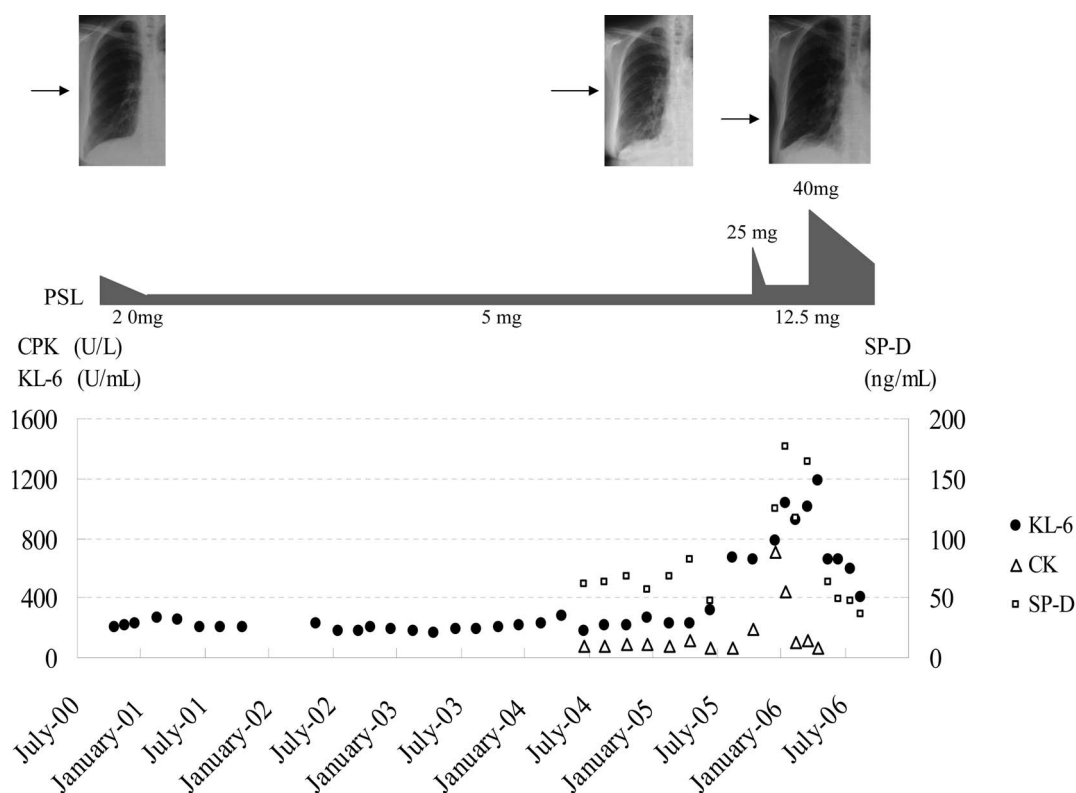


Figure 3. Laboratory values over time with findings of roentgenogram. CPK activity, KL-6, and SP-D increased in August 2005. The dosage of PSL was 5 mg/day from 1999, then increased to 25 mg/day in November, 2005, and then tapered to 12.5 mg/day in February, 2006 because muscle symptoms disappeared and CK activity decreased to normal; however, KL-6 and SP-D continued to increase. The minor fissure in March, 2006 (an arrow) became lower than it was in 1999 and 2005. The PSL was increased to 40 mg/day in May, 2006, which was followed by decreases in KL-6 and SP-D.

not generally thought to be involved in overlap syndrome in Japanese or North American Caucasians, and the meanings of its presence in patients with SSc-PM overlap syndrome is unknown. Anti-Ku and anti-PM-Scl antibodies were not detected in our case.

Loss of pulmonary function in patients with SSc is significantly greater during the first 2 years than later in the course of the disease (9). Colp concluded that lung abnormalities associated with SSc occur early and thereafter do not progress significantly (10). Therefore, it is not natural that SSc-IP would exacerbate 8 years after the initial diagnosis of SSc. In addition, a remarked increase in the number of lymphocytes in BAL fluid is not common in cases of SSc-IP (11). The atypical clinical course in the present case suggested the existence of other factors that would exacerbate the IP.

Clinical symptoms, EMG findings, and serological findings in the present case satisfied the diagnostic criteria for PM (1). Anti-Jo-1 antibody was detected in 2005 but not previously. Anti-Jo-1 (anti-histidyl-tRNP synthetase) antibody is the most common single myositis-specific autoantibody, and it is found more often in patients with PM than in patients with dermatomyositis or other myositis syndromes in adults (12). The change from negative to positive anti-

body status indicated that PM later accompanied the SSc (SSc-PM overlap syndrome) although muscle involvement in SSc has been documented by pathologic examination in 36-96% of patients with SSc (13, 14), we regarded the muscle involvement in our case to be a result of PM, according to Nishikai's criteria (15). Nishikai stated that distinction between myopathy associated with collagen disease and that associated with overlap syndrome between PM and other collagen diseases is essential from the clinical and etiological points of view. He listed the following six items for help in differentiation: (i) proximal muscle weakness continuing for more than 1 month; (ii) proximal muscle weakness below Daniel's grade 2; (iii) myalgia of more than 1 month's duration without sensory disturbance; (iv) elevated serum CPK and/or GOT level; (v) creatinuria of more than 40%; (vi) myofibril degeneration on muscle biopsy. He concluded that a condition satisfying four or more of these criteria should be classified as PM overlap syndrome. The present case satisfied four of these criteria, suggesting a PM origin rather than a simple SSc myopathy. Muscle involvement preceded the development of IP, indicating that the IP was due to the onset of PM, and the BAL yielded findings consistent with PM-IP. It has been reported for cases of anti-Jo-1-positive inflammatory myopathies that continued deteriora-

tion of pulmonary function may occur despite steroid or immunosuppressive treatment, in contrast to the good remission of muscle symptoms (16). The clinical course in our case was compatible with this report.

In the case of SSc-PM overlap syndrome, anti-Jo-1 antibody is the antibody most commonly detected (17). Patients with anti Jo-1 antibodies have a higher frequency of several connective tissue disease features, the most important of which is IP (18). IP in anti-Jo-1 antibody-positive patients can be severe and affect the prognosis (19, 20). In addition, no controlled trials of treatment have been reported, and experience is limited. Corticosteroids are the mainstay of therapy; however, their effectiveness is often poor. In the present case, treatment was started with a combination of corticosteroid (PSL 40 mg/day) and immunosuppressant cy-

closporine, the efficacy of which is suggested for PM-IP (20); however, side effects such as electrolyte abnormalities (marked elevation of the serum potassium level, and chest oppression) occurred. We abandoned the cyclosporine, and the PSL at 40 mg/day was continued, and then tapered gradually. There are reports of responses to steroid therapy, and we witnessed improvement in blood gas values, pulmonary function, and symptoms in our case.

We encountered a case in which IP progressed markedly when PM overlapped SSc. Although it is well known that connective tissue diseases including SSc occasionally overlap, we should investigate whether another collagen disease has developed when pulmonary disease cannot be explained by the usual clinical course of a connective tissue disease that has been present.

References

1. Tanimoto K, Nakano K, Kano S, et al. Classification criteria for polymyositis and dermatomyositis. *J Rheumatol* **22**: 668-674, 1995.
2. Bernstein RM, Steigerwald JC, Tan EM. Association of antinuclear and antinucleolar antibodies in progressive systemic sclerosis. *Clin Exp Immunol* **48**: 43-57, 1982.
3. Mimori T, Akizuki M, Yamagata H, et al. Characterization of a high molecular weight acidic nuclear protein recognized by autoantibodies in sera from patients with polymyositis-scleroderma overlap. *J Clin Invest* **68**: 611-620, 1981.
4. Reichlin M, Maddison PJ, Targoff I, et al. Autoantibodies to a nuclear/nucleolar antigen in patients with polymyositis overlap syndromes. *J Clin Immunol* **4**: 40-44, 1984.
5. Okano Y, Steen VD, Medsger TA Jr. Autoantibody to U3 nucleolar ribonucleoprotein (fibrillar) in patients with systemic sclerosis. *Arthritis Rheum* **35**: 95-100, 1992.
6. Mimori T. Scleroderma-polymyositis overlap syndrome. Clinical and serologic aspects. *Int J Dermatol (Suppl 1)* **26**: 419-425, 1987.
7. Reimer G, Steen VD, Penning CA, et al. Correlates between autoantibodies to nucleolar antigens and clinical features in patients with systemic sclerosis (scleroderma). *Arthritis Rheum* **31**: 525-532, 1988.
8. Kuwana M, Okano Y, Kaburaki J, et al. Racial differences in the distribution of systemic sclerosis-related serum antinuclear antibodies. *Arthritis Rheum* **37**: 902-906, 1994.
9. Steen VD, Conte C, Owens GR, Medsger TA Jr. Severe restrictive lung disease in systemic sclerosis. *Arthritis Rheum* **37**: 1283-1289, 1994.
10. Colp CR, Riker J, Williams MH Jr. Serial changes in scleroderma and idiopathic interstitial lung disease. *Arch Intern Med* **132**: 506-515, 1973.
11. Remy-Jardin M, Remy J, Wallaert B, et al. Pulmonary involvement in progressive systemic sclerosis: sequential evaluation with CT, pulmonary function tests, and bronchoalveolar lavage. *Radiology* **2**: 499-506, 1993.
12. Arnett FC, Targoff IN, Mimori T, et al. Interrelationship of major histocompatibility complex class II alleles and autoantibodies in four ethnic groups with various forms of myositis. *Arthritis Rheum* **39**: 1507-1518, 1996.
13. Medsger TA Jr, Rodnan GP, Moossby J, et al. Skeletal muscle involvement in progressive systemic sclerosis (scleroderma). *Arthritis Rheum* **2**: 554-564, 1968.
14. Clements PJ, Furst DE, Campion DS, et al. Muscle disease in progressive systemic sclerosis: Diagnostic and therapeutic conditions. *Arthritis Rheum* **21**: 62-71, 1978.
15. Nishikai M. Polymyositis and myopathies in collagen diseases. *Rhumachi* **14**: 12-21, 1974.
16. Furuya T, Hakoda M, Tsuchiya N, et al. Immunogenetic features in 120 Japanese patients with idiopathic inflammatory myopathy. *J Rheumatol* **31**: 1768-1774, 2004.
17. Spath M, Schroder M, Schlotter-Weigel B, et al. The long-term outcome of anti-Jo-1-positive inflammatory myopathies. *J Neurol* **251**: 859-864, 2004.
18. Fathi M, Lundberg IE. Interstitial lung disease in polymyositis and dermatomyositis. *Curr Opin Rheumatol* **17**: 701-706, 2005.
19. Vencovsky J, Jarosova K, Machacek S, et al. Cyclosporine A versus methotrexate in the treatment of refractory myositis: a randomized crossover study of two new cytotoxic regimens. *Scand J Rheumatol* **29**: 95-102, 2000.
20. Spath M, Schroder-Weigel B, Walter MC, et al. The long-term outcome of anti Jo-1-positive inflammatory myopathies. *J Neurol* **251**: 859-864, 2004.