

# Acute eosinophilic pneumonia following cigarette smoking: A case report including cigarette-smoking challenge test

著者	Watanabe Kazuyoshi, Fujimura Masaki, Kasahara Kazuo, Yasui Masahide, Myou Shigeharu, Kita Toshiyuki, Watanabe Akira, Nakao Shinji
journal or publication title	Internal Medicine
volume	41
number	11
page range	1016-1020
year	2002-01-01
URL	<a href="http://hdl.handle.net/2297/24303">http://hdl.handle.net/2297/24303</a>

## Acute Eosinophilic Pneumonia Following Cigarette Smoking: A Case Report Including Cigarette-Smoking Challenge Test

Kazuyoshi WATANABE, Masaki FUJIMURA\*, Kazuo KASAHARA\*, Masahide YASUI\*, Shigeharu MYOU\*, Toshiyuki KITA\*, Akira WATANABE and Sinji NAKAO\*

### Abstract

A 21-year-old woman presented with acute progressive dyspnea. Chest computed tomography (CT) revealed diffuse bilateral infiltrates. Based on the results of transbronchial lung biopsy (TBLB) and bronchoalveolar lavage fluid (BALF) and her clinical course, she was diagnosed as having acute eosinophilic pneumonia. We suspected that the disease was related to smoking because she had started smoking ten days before the onset of symptoms. Therefore, a cigarette-smoking challenge test was done with the patient's informed consent. After the challenge, eosinophilic pneumonia was documented by BALF and TBLB findings, which were similar to those detected on admission, without significant radiographic findings. (Internal Medicine 41: 1016–1020, 2002)

**Key words:** transbronchial lung biopsy, bronchoalveolar lavage fluid, CD4/CD8, tolerance

### Introduction

Acute eosinophilic pneumonia (AEP) is characterized by eosinophilic infiltration in the lungs, respiratory distress, a rapid therapeutic response to corticosteroids and the absence of relapse (1). It has been proposed that AEP is associated with cigarette smoke (2, 3). However, there has been no histological evidence after a cigarette-smoking challenge test to support that cigarette smoke causes AEP (CS-AEP). Shintani et al reported that tolerance develops to repeated resumption of smoking cigarettes in CS-AEP cases (3). But it is unclear whether eosinophils are attributed to the mechanism of tolerance. We present here a diagnostically challenged case of CS-AEP followed by bronchoalveolar lavage (BAL) and transbronchial lung biopsy (TBLB).

### Case Report

A 21-year-old woman had started smoking (20 cigarettes per day) 13 days before admission and had developed a productive cough, dyspnea and fever 3 days before admission. On admission, she was cyanotic and febrile (38.2°C). Her peripheral WBC count was 10,600/ $\mu$ l, with 76.8% neutrophils and 6.3% eosinophils. Serum C-reactive protein (CRP) was 8.4 mg/dl. Total serum IgE was 38 IU/ml, and antigen-specific IgE against *Aspergillus fumigatus* or *Candida* was negative. The results of serum *Trichosporon mucoides* and *asahii* tests and viral antibody tests were all negative. Arterial blood gas determination on room air revealed a pH of 7.42, PaO<sub>2</sub> of 51.1 mmHg, and PaCO<sub>2</sub> of 41.3 mmHg. Chest computed tomography (CT) revealed diffuse bilateral pulmonary infiltrates and mild pleural effusions (Fig. 1, Fig. 2). The BAL fluid (BALF) contained 78% eosinophils and 8% neutrophils. Immunophenotypic analysis of BALF lymphocytes revealed that the CD4/CD8 ratio was 5.1 (Table 1). Cultures of BALF proved negative for bacteria and fungi. TBLB specimen on the second day demonstrated eosinophilic pneumonia, but no granuloma or angitis (Fig. 3). She met the criteria for the diagnosis of acute eosinophilic pneumonia (AEP) proposed by Allen et al (1). She was given intravenous methylprednisolone (1,000 mg/day for three continuous days). Her condition promptly improved, showing a decrease in pulmonary infiltrates and normalization of serum CRP. However, the percentage of peripheral blood eosinophils, 6.3% on admission, increased gradually to 22.6% on the 24th hospital day, and subsequently decreased to 13.6% afterwards. A chest radiograph showed complete resolution of abnormalities and the patient was discharged on the 29th hospital day.

On Day 62, i.e., in the recovery phase, the patient had neither symptoms nor fever. The CT showed normal findings. The laboratory data, including peripheral WBC count, neutrophils, eosinophils and serum CRP, were within normal range. The results of pulmonary function tests and BALF examination were also normal (Table 1).

From the Department of Internal Medicine, Sinminato Municipal of Hospital, Sinminato and \*the Third Department of Internal Medicine, Kanazawa University School of Medicine, Kanazawa

Received for publication March 18, 2002; Accepted for publication July 19, 2002

Reprint requests should be addressed to Dr. Kazuyoshi Watanabe, the Department of Internal Medicine, Sinminato Hospital, 20 Hounoki, Shinminato 934-0053

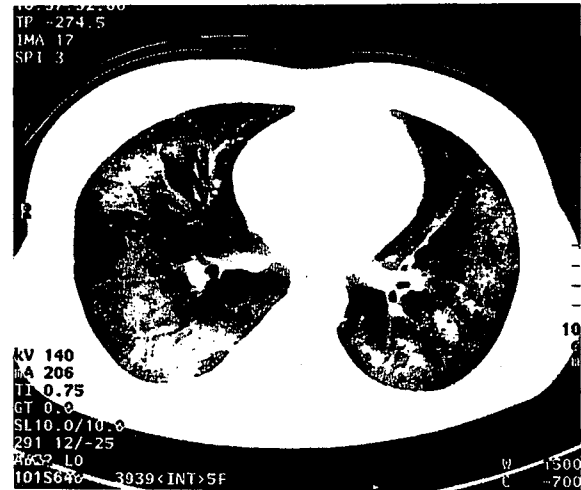
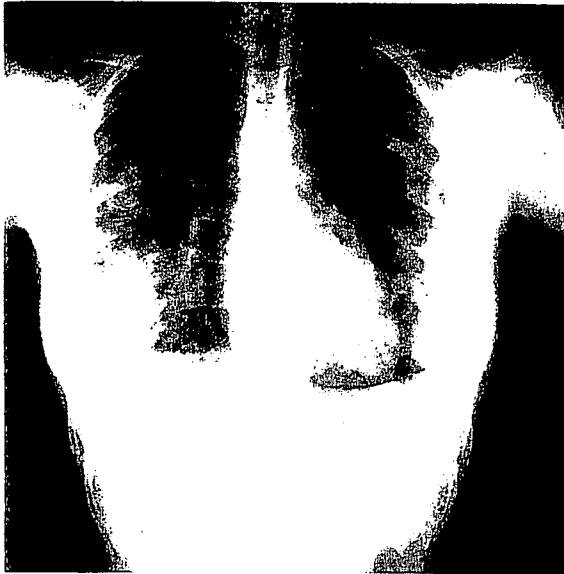

Figure 1. Chest roentgenogram on admission showing diffuse infiltrates in both lung fields.

Figure 2. Chest CT on admission showing diffuse bilateral pulmonary infiltrates and mild pleural effusions.

Table 1. Chest CT and BALF Findings at Onset, Recovery Phase and after the Cigarette-smoking Challenge Test

	Chest CT	TCC (/ml)	Neu (%)	Eo (%)	Lym (%)	Ma (%)	CD4/CD8
On Set (Day 2)	Infiltrative	35.7×10 <sup>6</sup>	8	78	6	8	5.1
Recovery Phase (Day 62)	Normal	8.8×10 <sup>6</sup>	2	0	8	90	0.5
Post Challenge (Day 92)	Normal	11.7×10 <sup>6</sup>	0	65	12	23	0.7

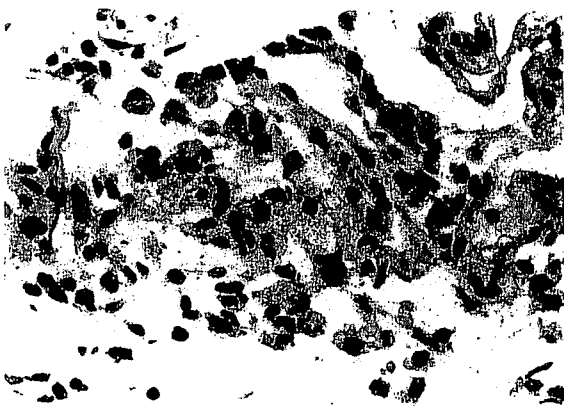


Figure 3. Photomicrograph of a transbronchial lung biopsy specimen obtained on the second day showing infiltration of eosinophils into alveolar walls and air spaces, and edematous alveolar walls (HE stain, ×400).

On Day 82, the patient still had neither symptoms nor fever. The laboratory data, CT findings and the results of pulmonary function tests were all normal. At that time she was subjected to a cigarette smoking (CS) challenge test after obtaining informed consent. For the test the patient was asked to smoke 20 cigarettes a day for 13 days. She continued cigarette smoking up to Day 91, because the percentage of peripheral eosinophils was decreasing. She hasn't developed any symptoms during the test. Her peripheral WBC count, neutrophil count, eosinophil count and CRP before the test were 4,400 /μl, 2,605 /μl, 220/μl, and 0.0 mg/dl, respectively, and they were 10,000 /μl, 8,060/μl, 270/μl and 1.0 mg/dl on Day 83, respectively (Fig. 4). The percentage of eosinophils, which was 5.0% before the test, increased gradually to 22.6% on Day 88, and subsequently decreased to 8.4% on Day 91 (Fig. 4). On Day 91, marked eosinophilia (65%) was observed in BALF, but CD4/CD8 ratio in BALF was 0.7 (Table 1). The TBLB specimen obtained on Day 91 showed the typical histology characteristics of eo-

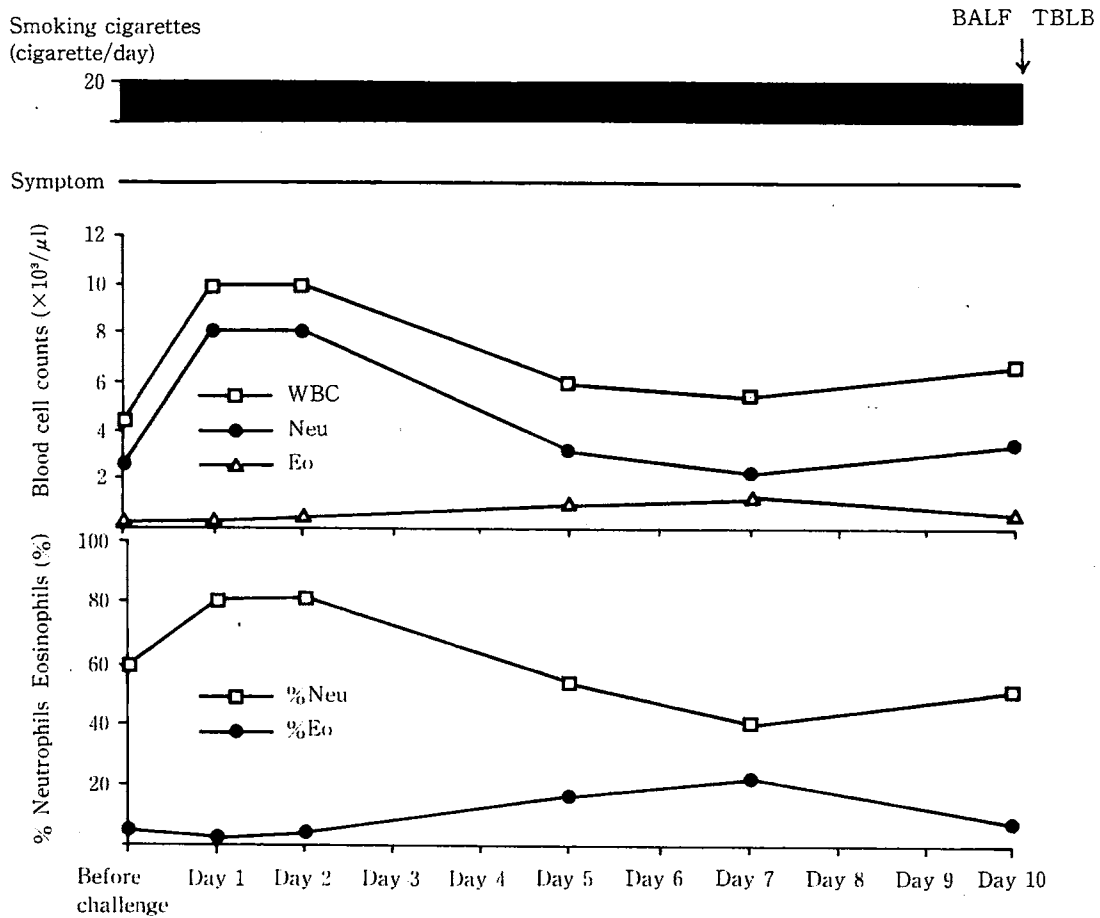


Figure 4. Results of the cigarette-smoking challenge test.

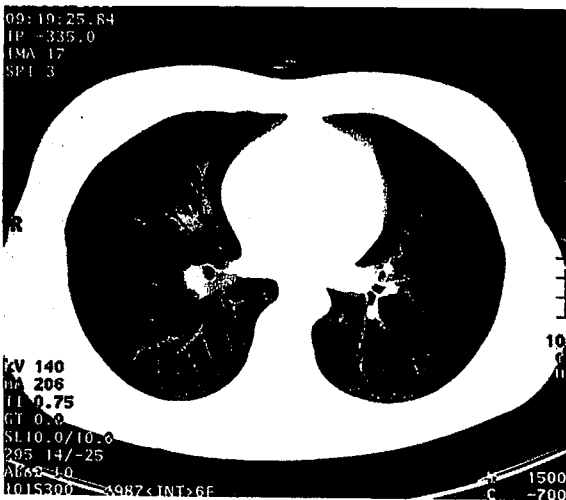


Figure 5. Chest CT on Day 91 showing normal.

sinophilic pneumonia. But CT findings (Fig. 5) and the results of pulmonary functional tests were normal after the test. Six months later, the results of pulmonary function tests including spirometry, arterial blood gases, measurement of diffusing capacity and chest radiograph were normal and she had no symptoms, although she had continued smoking 10 cigarettes a day.

### Discussion

This patient met the criteria for the diagnosis of acute eosinophilic pneumonia (AEP) proposed by Allen et al (1). It is also important to exclude infections that can present acutely with pulmonary eosinophilia, such as *Pneumocystis carinii* infection and *Aspergillus pneumonia*. No pathogenic organisms were detected in any samples obtained from our patient. Some authors (4–7) have reported AEP associated with CS. To assess the validity of this diagnosis, we reviewed 21 reported cases of CS-AEP from 1989 through 2001. Among them, 8 cases were diagnosed based on the positive challenge test (Table 2). The mean age of the patients of CS-induced AEP was 19.3 years old. The development of the symptoms was a mean 14.3 days after initiation of smoking. Serum WBC and CRP were

## Acute Eosinophilic Pneumonia Due to Smoking

**Table 2. Reported Cases of CS-AEP Diagnosed by Challenge Test**

Author	Age	Sex	S P	Fever	Symptom	PF	Chest Xp	WBC	CRP	BG	BALF	TBLB	Tolerance
Shintani (3)	19	Man	21	+	Dyspnea	+	+	+	+	+	+		+
Shintani (4)	19	Man	18	+	Chest pain	+	+		+	+			
Sasaki (8)	18	Man	3	-	Dyspnea	+	-	+		+			
Ito (9)	19	Man	14	+	Cough	+	+(HRCT)	+	+	-	+		
Matui (10)	21	Man	7	+	-		-(HRCT)	-		+	-		+
Sakamoto (11)	15	Man	17	+	Chest pain	+	-	+	+	+	+		
Kawamura (12)	19	Man	14	-	Cough	-	-	+			+		+
Nakajima (13)	23	Man	21	+	Cough	-		+	+	-			+
Present case	21	Woman	14	-	-	-	-(HRCT)	+	+	-	+	+	+
<b>Total</b>	<b>19.3</b>	<b>8/1</b>	<b>14.3</b>	<b>66.7%</b> 6/9	<b>77.8%</b> 7/9	<b>62.5%</b> 5/8	<b>37.5%</b> 3/8	<b>87.5%</b> 7/8	<b>100%</b> 6/6	<b>62.5%</b> 5/8	<b>83.3%</b> 5/6	<b>1/1</b>	<b>5/9</b>

SP: smoking period, PF: pulmonary function, WBC: white blood cell, CRP: C-reactive protein, BG: blood gases, BALF: bronchoalveolar lavage fluid, TBLB: transbronchial lung biopsy, +: positive, -: negative.

more sensitive for the diagnosis of CS-AEP by challenge test. This case would be a typical one of CS-AEP. Sasaki et al reported the case of an 18-year-old man with AEP who was challenged with CS and presented respiratory distress but no significant chest radiographic findings, but they did not perform the concurrent bronchoscopy (8). Shintani et al reported a case of CS-AEP showing tolerance (3).

As mentioned above, we supposed that eosinophils in both the lung tissue and BALF might increase, but the patient would not develop any symptoms and would present no significant chest radiographic findings after the CS challenge. We, thus, challenged our patient with CS under informed consent. The results indicated that the challenge with CS induced slightly abnormal laboratory findings and the evidence of eosinophilic pneumonia, which was documented by BALF and TBLB findings, but without symptoms, respiratory function abnormalities or remarkable chest radiographic findings. This is the first report showing direct evidence that in CS-induced AEP the increase of eosinophils in both BALF and TBLB develops without significant radiographic findings when patients start smoking cigarettes again.

Moreover, six months later, the results of pulmonary function tests and chest radiograph were normal and she had no symptoms, although she had continued smoking 10 cigarettes a day. Some authors previously reported that tolerance develops in CS-induced AEP (Table 2). This patient also showed the tolerance to repeated resumption of smoking cigarettes. The mechanism of tolerance remains unknown. Shintani et al speculated some possible mechanisms; desensitization to repeated

resumption of smoking cigarettes, and the interaction of virus infection and/or given drugs with cigarette smoke (4).

In this case the CD4/CD8 ratio of lymphocytes and the percentage of neutrophils in BALF after challenge was decreased compared with those at the onset, while the percentage of eosinophils in BALF after challenge was much the same as that at the onset. Fujimura et al showed that the CD4/CD8 ratio of lymphocytes in the BALF from patients with AEP was increased compared with those from normal subjects and patients with chronic eosinophilic pneumonia (CEP) and drug-induced eosinophilic pneumonia (drug-EP) (14). It is suspected that the increase in CD4/CD8 ratio at onset indicates induction and/or development of an allergic reaction via an activation of helper T-cells. On the other hand, the decrease in CD4/CD8 ratio after challenge may indicate an activation of suppresser T-cells by repeated resumption of smoking cigarettes. Fujimura et al showed that the number of neutrophils in BALF from patients with AEP was increased significantly compared with those from normal subjects and patients with CEP and drug-EP (14). They suspected that the inflammatory cell profile in the lungs of patients with AEP might be characterized by the intensive inflammatory cell infiltration, especially the neutrophil infiltration (14). These indicate that the eosinophils accumulated in the lungs may not be cytotoxic or pathogenic in CS-induced AEP. Ishiura et al reported that *in vivo* airway eosinophils accumulation did not worsen asthma physiology, i.e. bronchial responsiveness and allergic bronchoconstriction, in guinea pigs (15). Therefore, we speculate that eosinophil may not play a key role in the development of CS-AEP. We did not examine

the cytokine profile in BALF in this case. Further studies are needed to elucidate the role of eosinophils and lymphocyte subpopulations in the development of CS-AEP and the tolerance to repeated cigarette smoking.

### References

- 1) Allen JN, Pacht ER, Gadek JE, Davis WB. Acute eosinophilic pneumonia as a reversible cause of non-infectious respiratory failure. *N Engl J Med* **321**: 569–574, 1989.
- 2) Sakamoto Y, Kuriwaka R, Tohjima A, Miura S. Acute eosinophilic pneumonia induced by cigarette smoking. *J Thorac Dis* **38**: 466–470, 2000.
- 3) Shintani H, Fujimura M, Ishiura Y, Noto M. A case of cigarette smoking-induced acute eosinophilic pneumonia showing tolerance. *Chest* **117**: 277–279, 2000.
- 4) Shintani H, Fujimura M, Yasui M, et al. Acute eosinophilic pneumonia caused by cigarette smoking. *Intern Med* **39**: 66–68, 2000.
- 5) Shiota Y, Kawai T, Matsumoto H, et al. Acute eosinophilic pneumonia following cigarette smoking. *Intern Med* **39**: 830–833, 2000.
- 6) Nakagome K, Kato J, Kubota S, et al. Acute eosinophilic pneumonia induced by cigarette smoking. *Nihon Kogyoku Gakkai Zasshi* **38**: 113–116, 2000 (English Abstract).
- 7) Godding V, Bodart E, Delos M, et al. Mechanisms of acute eosinophilic inflammation in a case of acute eosinophilic pneumonia in a 14-year-old girl. *Clin Exp Allergy* **28**: 504–509, 1998.
- 8) Sasaki T, Nakajima M, Kawabata S, et al. Acute eosinophilic pneumonia induced by cigarette smoke. *J Thorac Dis* **35**: 89–94, 1997 (English Abstract).
- 9) Ito S, Taniguchi H, Kondo Y, et al. Positive response to smoking challenge test in a case of acute eosinophilic pneumonia. *J Thorac Dis* **37**: 424–428, 1999 (English Abstract).
- 10) Matsui S, Yamashita N, Maruyama M, et al. Acute eosinophilic pneumonia induced by cigarette smoking: positive lymphocyte stimulation test of a cigarette extract. *Nihon Kogyoku Gakkai Zasshi* **38**: 807–811, 2000 (English abstract).
- 11) Sakamoto Y, Kuriwaka R, Tohjima A, Miura S. Acute eosinophilic pneumonia induced by cigarette smoking—a challenge test utilizing another brand of cigarette. *Nihon Kogyoku Gakkai Zasshi* **38**: 466–470, 2000.
- 12) Kawamura T, Mochizuki Y, Nakahara Y, Kimoto T, Watanabe S. A clinical study of 5 cases of acute eosinophilic pneumonia—the relationship between beginning to smoke and acute eosinophilic pneumonia. *Nihon Kyobu Shikkan Gakkai Zasshi* **35**: 1252–1258, 1997.
- 13) Nakajima M, Yoshida K, Miyashita N, Niki Y, Matsushima T. Eosinophilia and cough induced by resumption of cigarette smoking in a beginning smoker recovering from acute respiratory failure. *Nihon Kogyoku Gakkai Zasshi* **37**: 543–548, 1999.
- 14) Fujimura M, Yasui M, Shinagawa S, Nomura M, Matsuda T. Bronchoalveolar lavage cell findings in three types of eosinophilic pneumonia: acute, chronic and drug-induced eosinophilic pneumonia. *Respir Med* **92**: 743–749, 1998.
- 15) Ishiura Y, Fujimura M, Myou S, Amemiya T. In vivo airway eosinophil accumulation induced by polymyxin-B reduces bronchial responsiveness in guinea pigs. *Clin Exp Allergy* **31**: 644–651, 2001.