

Differentiation of hepatic tumors by use of image contrast with T2-weighted MRI

著者	Ogura Akio, Hayakawa Katsumi, Miyati Tosiaki, Maeda Fumie, Miyai Akira, Saeki Fumito, Murata Takaharu
journal or publication title	Radiological Physics and Technology
volume	2
number	1
page range	54-57
year	2009-01-01
URL	http://hdl.handle.net/2297/17584

doi: 10.1007/s12194-008-0043-0

Differentiation of hepatic tumors by use of image contrast with T2-weighted MRI

Akio Ogura, M.S. ^{1,2)}

Katsumi Hayakawa, M.D. ¹⁾

Tosiaki Miyati, Ph.D. ²⁾

Fumie Maeda, R.T. ¹⁾

Akira Miyai, R.T. ¹⁾

Fumito Saeki, R.T. ¹⁾

Takaharu Murata, R.T. ¹⁾

1) Department of Radiology, Kyoto City Hospital

2) Graduate School of Medical Science, Kanazawa University

Corresponding Author: Akio Ogura

Department of Radiology, Kyoto City Hospital

1- 2, Higashitakada-cho, Mibu, Nakagyo-ku, Kyoto, JAPAN

TEL: +8175-311-5311(2183)

E-mail address: a-ogura@mbox.kyoto-inet.or.jp

Abbreviated Title Page

Differentiation of hepatic tumors by use of image
contrast with T2-weighted MRI

Abstract

Differentiation of hepatic tumors is often evaluated in terms of qualitative diagnostic performance. The signal intensity patterns of hepatic masses are known to differ on certain T2-weighted imaging sequences. In this study, we investigated the quantitative analysis of hepatic masses by using an index called the “T2-shine ratio”. Fast-spin-echo (FSE), Half-Fourier acquisition single-shot turbo spin echo (HASTE), and True-FISP sequences obtained with quick-imaging techniques during a single breath-hold were examined in 74 patients. T2-shine ratios were calculated by use of the signals of Region of interests (ROIs) placed on a tumor and peripheral tissue: the T2-shine ratio is defined as (tumor signal-liver signal) / liver signal. The rate of change in the T2-shine ratio was compared among three sequences of FSE, HASTE, and True-FISP. The T2-shine ratio of FSE deducted from HASTE was significantly higher for hepatic cysts than for other masses. The T2-shine ratio of HASTE deducted from True-FISP was less than zero for hemangioma. For the value that deducted the T2-shine ratio of HASTE from the T2-shine ratio of True-FISP, hemangiomas had a significantly lower value than did cysts and metastases ($P<0.05$), but there was no significant difference from hepatocellular carcinomas (HCCs). Although liver cysts, cavernous hemangiomas and other lesions could be differentiated, it was virtually impossible to distinguish HCCs from metastatic tumors. In conclusion, the quantitative analysis of hepatic tumors was able to differentiate among these lesions by use of the T2-shine ratio.

Key words: hepatic tumors, T2-shine ratio, quantitative analysis

Introduction

Magnetic resonance imaging (MRI) is frequently used for facilitating the diagnosis of hepatic masses. Techniques for distinguishing hepatic tumors in imaging studies have been proposed by several researchers [1-5]. Dynamic study after bolus injection of gadolinium chelates is a useful method for detection and characterization of hepatic masses [6,7]. Superparamagnetic iron oxide particles (SPIOs) can also contribute to distinguishing hepatic masses by use of various imaging sequences [8-13]. In addition, conventional MR images without contrast media are commonly obtained, taking advantage of the high contrast resolution of this modality. However, most radiologists prefer visual assessment for tumor characterization. For the evaluation of appearance, considerable time is required for developing the skills of experienced radiologists. In general, hepatic cysts and hemangiomas show much higher signal intensities on heavily T2-weighted images (T2WIs) because of the high fluid concentrations in these tissues. This influence is particularly great for cysts. In addition, the signal intensity of hemangiomas tends to deteriorate on True-FISP sequences in comparison to that on Half-Fourier acquisition single-shot turbo spin echo (HASTE) sequences. For metastases and hepatocellular carcinomas (HCCs), there is no typical signal difference among the three imaging sequences. Regarding the numerical value of the signal, however, the order of signal intensity depends on the signal gain in MRI, and the signal intensity difference is evaluated in relation to the organization of the circumference. Quantitative evaluation of MRI findings is difficult because the radiologists know these signal intensity patterns experimentally, but such a determination cannot avoid being a qualitative index of the radiologist's sensitivity and skill. Therefore, we developed a quantitative analysis method by the using the T2-shine ratio as the ratio of

the signal intensity of the mass and organization of the circumference (contrast). In this study, we assessed whether the quantitative diagnostic performance by use of the T2-shine ratio could discriminate among hepatic masses including hepatic cysts, cavernous hemangiomas, metastases, and HCCs.

Materials and Methods

This study was carried out retrospectively. The subjects were 74 patients. Twenty-one patients had cysts, 14 had HCCs, 22 had hemangiomas, and 17 had metastases. All of the patients in the study group had undergone previous sonography and CT examinations. The diagnoses of solid masses were established by dynamic enhanced CT and dynamic enhanced MRI studies. In some patients, pathologic confirmation was obtained by biopsy or surgical intervention. The institutional review board approved the study design and the review of patient records and images.

All patients were studied with a 1.5T MRI unit (Magnetom Symphony, Siemens, Erlangen, Germany) that used a body phased-array coil. Fast spin echo (FSE), HASTE, and True-FISP sequences were examined with breathhold in all patients. The sequence parameters are shown in Table 1. FSE was performed with an effective TE of 77 msec and echo train lengths (ETLs) of 25. HASTE was performed by one excitation with an effective TE of 88 msec and ETLs of 128. The HASTE sequence is essentially a heavily T2-weighted sequence, which may cause water-rich lesions to appear very bright. True-FISP was performed with an effective TE of 2.66 msec and TR of 5.32 msec in a steady state. Sequential slice imaging was obtained on the transverse plane with a 5 mm slice thickness.

FSE, HASTE, and True-FISP sequences using quick-imaging techniques under a single breathhold were examined in the 74 patients (liver cysts, cavernous hemangiomas, hepatocellular carcinomas, and metastatic tumors). The T2-shine ratio can be estimated by a simple calculation with

use of imaging data of each sequence from the ratios of signal intensity determined by placement of a region of interest (ROI) on the mass and the organization of the circumference. We manually designed a circular ROI with an electronic cursor to match the mass. ROIs of the organization of the circumference were in the normal liver parenchyma excluding major blood vessels.

The T2-shine ratio is defined as

$$\text{T2-shine ratio} = (\text{tumor signal} - \text{liver signal}) / \text{liver signal} \quad \dots\dots (1)$$

The rate of change in the T2-shine ratio was compared among the three sequences. The Wilcoxon signed-rank test was used for comparison of all data.

Results

The T2-shine ratios of images obtained by FSE, HASTE, and True-FISP imaging sequences for the 74 masses (cysts, HCCs, hemangiomas, and mets) are shown in Figure 1a-d. For cysts, the T2-shine ratio of HASTE was a high value in comparison with that of FSE. For hemangioma, the T2-shine ratio of True-FISP showed a tendency to deteriorate compared to that on the other sequences. Figure 2 shows the values obtained by deduction of the T2-shine ratio of FSE from the T2-shine ratio of HASTE. Cysts showed a difference in the T2-shine ratios greater than 1 in all masses and exhibited a significantly higher value than did the other masses ($P < 0.05$). Also, the T2-shine ratios of hemangiomas were greater than zero. Figure 3 indicates the value after deduction of the T2-shine ratio of HASTE from the T2-shine ratio of True-FISP. Hemangiomas showed a difference in the T2-shine ratio less than zero for all masses and showed a significantly lower value than did cysts and metastases ($P < 0.05$), but there was no significant difference from HCCs.

Discussion

An MRI can be performed with a variety of imaging sequences. The signal intensity is determined by T1-relaxation, T2-relaxation, and proton density of organization as well as the influence of susceptibility to imaging factors. Therefore, signal intensity is specific to the imaging sequence design and composition of organization. In general, radiologists know these signal intensity patterns from experiments, but the determination of diagnosis is also based on the radiologist's sensitivity and skill. The characteristics of the three image sequences used in this study were as follows.

FSE --- Fast spin echo is a general T2-weighted image with an echo train of 25.

HASTE --- A high-speed single-shot fast-spin-echo sequence that allows a heavy T2-weighted image in abdominal imaging.

True-FISP --- A T2-star weighted image with gradient echo. The signal intensity shows T2/T1 with optimal flip angle of excitation pulse.

Signal= $1/2M_0\sqrt{T_2/T_1}$ (2)

For the T2-shine ratio of the cysts, HASTE, which is a heavily T2WI, showed a higher value than did FSE (Figure 2). Moreover, cysts always showed a high value more than 1 compared to that on FSE because cysts contain abundant water. For the T2-shine ratio of hemangiomas, True-FISP was lower than HASTE (Figure 3). This is because of the influence of the susceptibility for a gradient echo of the hemosiderin and contrast of T2/T1. However, the signal intensities of True-FISP showed various patterns; there were masses that showed a high signal and the same signal for organization of the circumference. True-FISP showed a lower T2-shine ratio than did HASTE in all cases. We considered it possible to distinguish cysts and hemangioma from other lesions by using indices of the two modalities discussed above. A limitation of this study was the inability to discriminate between HCC and metastasis, which unfortunately did not allow meaningful distinctions. This is because the composition of

metastatic lesions depends on the type of primary tumor, whereas the composition of HCC changes with the degree of differentiation. Therefore, it seems that these differences cause the characteristics of these masses to be distributed more broadly. The usefulness of adding another index to the T2-shine ratio will be investigated in a future study. In this study, we were able to distinguish among cysts, hemangiomas, and other masses without using contrast media.

This index may be a useful algorithm for computer-aided diagnosis.

Conclusion

Using an index called the T2-shine ratio, we examined the usefulness of quantitative analysis of hepatic masses. For the T2-shine ratio of cysts, HASTE, which is a heavily T2WI, gave higher values than did FSE. Cysts always showed a value greater than 1 compared to that on FSE. For the T2-shine ratio of hemangiomas, True-FISP was lower than HASTE. By use of this index, it was possible to distinguish cysts and hemangiomas from other masses without the use of contrast media.

References

- 1) Ohtomo K, Itai Y, Furui S, Yashiro N, Yoshikawa K, Iio M. Hepatic tumors: differentiation by transverse relaxation time(T2) of magnetic resonance imaging. *Radiology*.1985;155:421-423.
- 2) Kim YH, Saini S, Blake MA, Harisinghani M, Chiou YY, Lee WJ, et al. Distinguishing hepatic metastases from hemangiomas. *J Comput Assist Tomogr* 2005; 29(5):571-579.
- 3) Li W, Nissenbaum MA, Stehling MK, Goldmann A, Edelman RR. Differentiation between hemangiomas and cysts of the liver with nonenhanced MR imaging: efficacy of T2 values at 1.5T. *JMRI*

- 1993;3:800-802.
- 4) McFarland EG, Mayo-Smith WW, Saini S, Hahn PF, Goldberg MA, Lee MJ. Hepatic hemangiomas and malignant tumors: improved differentiation with heavily T2-weighted conventional spin-echo MR imaging. *Radiology*.1994;193: 43-47.
 - 5) Naganawa S, Jenner G, Cooper TG, Potchen EJ, Ishigaki T. Rapid MR imaging of the liver: comparison of twelve techniques for single breath-hold whole volume acquisition. *Radiation Medicine*; 12(6): 255-261.
 - 6) Ohtomo K, Itai Y, Yoshikawa K, Kokubo T, Yashiro N, Iio M, et al. Hepatic tumors: dynamic MR imaging. *Radiology* 1987;163: 27-31.
 - 7) Mahfouz AE, Hamm B, Taupitz M, Wolf KJ. Hypervascular Liver Lesion: Differentiation of focal nodular hyperplasia from malignant tumors with dynamic gadolinium-enhanced MR imaging. *Radiology* 1993; 186: 133-138.
 - 8) Arbab AS, Ichikawa T, Sou H, Akaki T, Nakajima H, Ishigame K, et al. Ferumoxides-enhanced double echo T2-weighted MR imaging in differentiating metastases from nonsolid benign lesions of the liver. *Radiology* 2002; 225: 151-158.
 - 9) Kumano S, Murakami T, Kim T, Hori M, Okada A, Sugiura T, et al. Using superparamagnetic iron oxide-enhanced MRI to differentiate metastatic hepatic tumors and nonsolid benign lesions. *AJR* 2003; 181: 1335-1339.
 - 10) Schoenigr CP, Koepke J, Gueckel F, Sturm J, Georgi M. MRI with superparamagnetic iron oxide: efficacy in the detection and characterization of focal hepatic lesions. *Magn Reson Imaging* 1999;17(3): 383-392.
 - 11) Mori K, Yoshida H, Itai Y, Okamoto Y, Mori h, Takahashi N, et al. Arterioportal shunts in cirrhotic patients: evaluation of the difference between tumorous and nontumorous arterioportal shunts on MR imaging

with superparamagnetic iron oxide. AJR 2000; 175: 1659-1664.

12) Paley MR, Mergo PJ, Torres GM, Ros PR. Characterization of focal hepatic lesions with ferumoxides-enhanced T2-weighted MR imaging. AJR 2000; 175: 159-163.

13) Vogl TJ, Hammerstingl R, Schwarz W, Mack MG, Muller PK, Pegions W, et al. Superparamagnetic iron oxide-enhanced versus gadolinium-enhanced MR imaging. Radiology 1996; 198: 881-887.

Figure legends

Fig.1a T2-shine ratio of images by FSE, HASTE, and True-FISP imaging sequence for a cyst.

Fig.1b T2-shine ratio of images by a FSE, HASTE, and True-FISP imaging sequence for HCC.

Fig.1c T2-shine ratio of images by a FSE, HASTE, and True-FISP imaging sequence for hemangioma.

Fig.1d T2-shine ratio of images by a FSE, HASTE, and True-FISP imaging sequence for the metastases.

Fig.2 Value that deducted T2-shine ratio of FSE from T2-shine ratio of HASTE. Cysts showed a difference of T2-shine ratio more than 1 in all samples and had a significantly higher value than the other masses ($P < 0.05$). The T2-shine ratio of hemangiomas was more than zero.

Fig.3 Value that deducted T2-shine ratio of HASTE from T2-shin ratio

of True-FISP. Hemangiomas showed a difference of T2-shine ratio in a value less than zero for all samples. Hemangiomas had a significantly lower value than the cysts and metastases ($P < 0.05$), but no significant difference from HCCs.

T2 shine ratio

10

Cyst

8

6

4

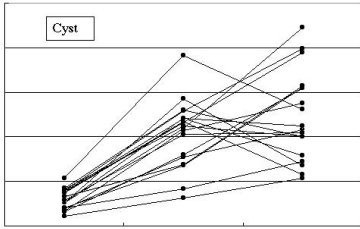
2

0

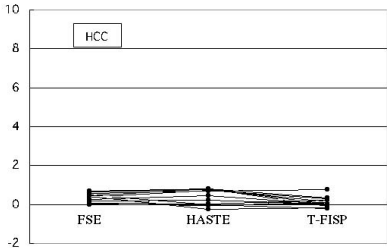
FSE

HASTE

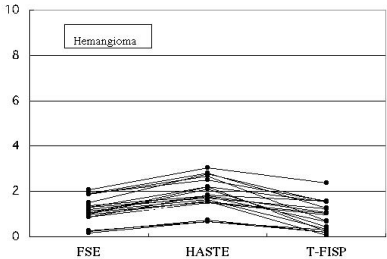
T-FISP



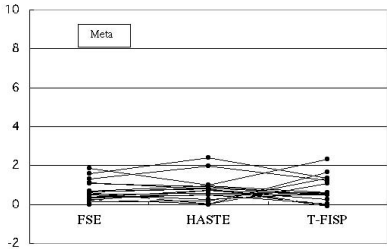
T2 shine ratio



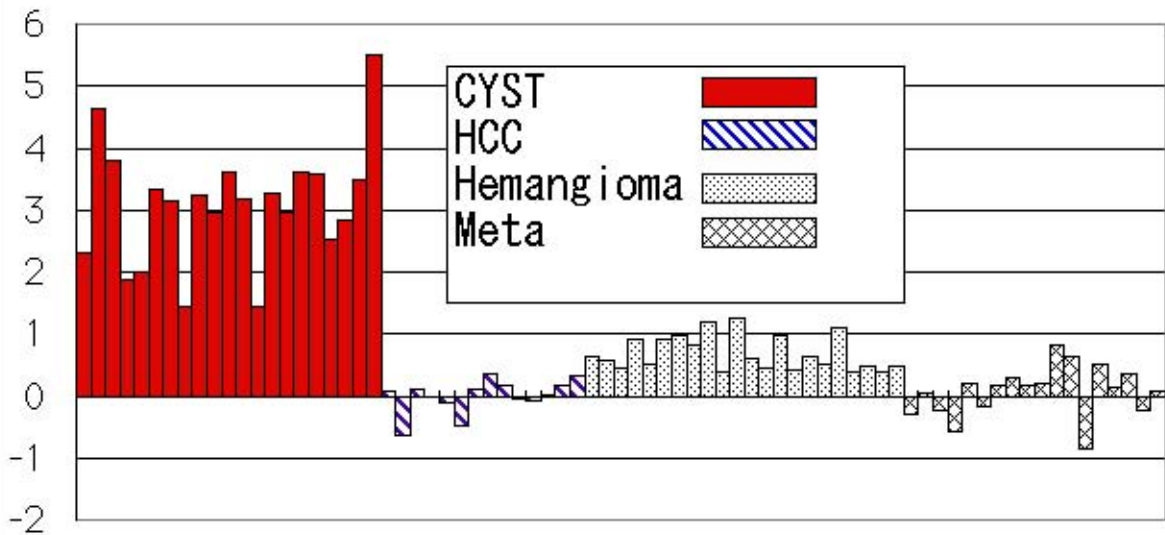
T2 shine ratio



T2 shine ratio



Increase in T2-shine ratio from FSE to HASTE



Table

Imaging sequences	TR (msec)	TE (msec)	ETL	band width(Hz/px)	thickness (mm)
FSE	3180	77	25	391	5
HASTE	(-)	88	128	651	5
True-FISP	5.32	2.66		558	5