

Acute eosinophilic pneumonia caused by cigarette smoking

著者	Shintani Hiromoto, Yasui Masahide, Ueda Kousei, Kameda Shouni, Noto Minoru, Matsuda Tamotsu, Kobayashi Masako
journal or publication title	Internal Medicine
volume	39
number	1
page range	66-68
year	2000-01-01
URL	http://hdl.handle.net/2297/24307

doi: <https://doi.org/10.2169/internalmedicine.39.66>

Acute Eosinophilic Pneumonia Caused by Cigarette Smoking

Hiromoto SHINTANI, Masaki FUJIMURA*, Masahide YASUI*, Kousei UEDA, Shouni KAMEDA, Minoru NOTO, Tamotsu MATSUDA* and Masako KOBAYASHI**

Abstract

It has been suggested that acute eosinophilic pneumonia (AEP) is associated with cigarette smoking because in Japan, the patients with AEP are young and have a high incidence of short-term smoking history. However, there has been no direct evidence to support that cigarette smoke causes AEP. Herein is reported the first case showing the direct evidence and a long-term clinical course of cigarette smoking-induced AEP, in which tolerance to repeated resumption of smoking cigarettes might have occurred. We should pay attention to the history of cigarette smoking in seeing patients with AEP, especially in young patients. (Internal Medicine 39: 66-68, 2000)

Key words: smoking, challenge test, tolerance

Introduction

Acute eosinophilic pneumonia (AEP) was first described in 1989 (1, 2), and the causes of AEP remain unknown. It is suggested that AEP may be related to a hypersensitivity phenomenon to an inhaled antigen (2). It has been proposed that AEP is associated with cigarette smoke (3, 4), because the patients with AEP are young and have a high incidence of short-term smoking history. However, there has been no direct evidence to support that cigarette smoke causes AEP.

We present here a diagnostically challenged case of AEP that recurred when the patient resumed smoking cigarettes.

Case Report

In January 1994, a previously healthy 19-year-old Japanese man started smoking several cigarettes per day, gradually increasing to 20 cigarettes per day within a week. Eighteen days after starting smoking, he experienced pleuritic chest pain, and two days after the onset of the symptom, he developed a non-

productive cough, dyspnea, and fever (39.0°C). Then he was seen by a physician at his office, and given PL granule® which is usually administered in treatment of the common cold. Four days after the onset, one of his colleagues found him unconscious in his dormitory room, and he was admitted to our hospital with acute respiratory distress by ambulance.

At the time of admission, he was drowsy, his blood pressure was 120/62 mmHg, pulse rate was 148 beats/min, temperature was 39.4°C, and his respiration rate was 40 breaths/min. There was severe central and peripheral cyanosis without signs of anemia or jaundice. The cardiac examination was normal, and auscultation of the lungs showed decreased breath sound and crackles in late inspiratory phase bilaterally. The abdomen appeared normal with no organomegaly. Arterial blood gas determination on room air revealed a pH of 7.50, PaO₂ of 17.0 mmHg, and PaCO₂ of 31.8 mmHg. His peripheral white blood cell count was 23,900/μl, with 95% neutrophils, 3% lymphocytes, 1% monocytes, and 1% eosinophils. Total serum IgE was 250 IU/ml, and antigen-specific IgE against *Aspergillus fumigatus* was negative. A chest X-ray revealed diffuse bilateral pulmonary infiltrates and pleural effusions (Fig. 1). His trachea was intubated and he was mechanically ventilated, and at the same time, fiberoptic bronchoscopy was performed above ventilator settings. Bronchoalveolar lavage (BAL) yielded a cell count of 10.4×10⁵/ml, with 47% eosinophils, 20% macrophages, 17% lymphocytes, and 16% neutrophils. Cultures of BAL fluid for common bacteria and fungi proved negative. Transbronchial lung biopsy specimens are shown in Fig. 2. He was given intravenous methylprednisolone (1,000 mg/day for three continuous days). He was extubated on the third hospital day. On the fourth day the shadows on the chest X-ray film improved remarkably and corticosteroid administration was tapered to oral prednisolone 40 mg/day, gradually tapering to a stop on his twentieth hospital day. Pleural effusion on the eighth day of hospitalization showed a cell count of 1.7×10⁵/ml, with 58.5% lymphocytes, 34% eosinophils, 4.0% macrophages, and 3.5% neutrophils. Pleural biopsy specimen obtained using the Cope needle revealed infiltration of lymphocytes and eosinophils in the pleura.

From the Department of Internal Medicine, Komatsu Municipal Hospital, Komatsu, *the Third Department of Internal Medicine, Kanazawa University School of Medicine, Kanazawa and **the First Department of Pathology, Kanazawa University School of Medicine, Kanazawa

Received for publication January 21, 1999; Accepted for publication August 7, 1999

Reprint requests should be addressed to Dr. Hiromoto Shintani, the Department of Internal Medicine, Komatsu Municipal Hospital, Ho 60 Mukaimotoori-machi, Komatsu 923-8560

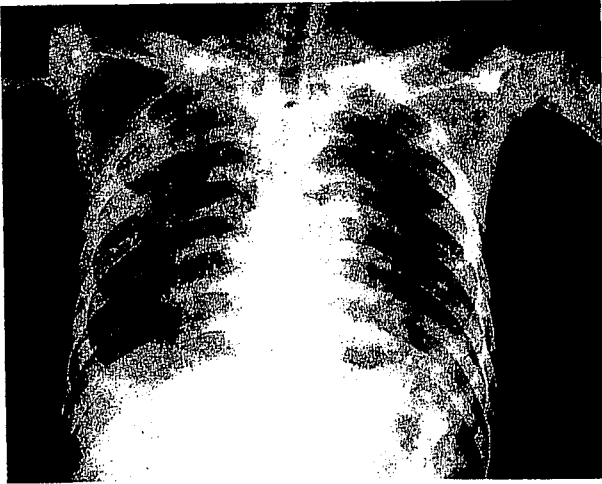



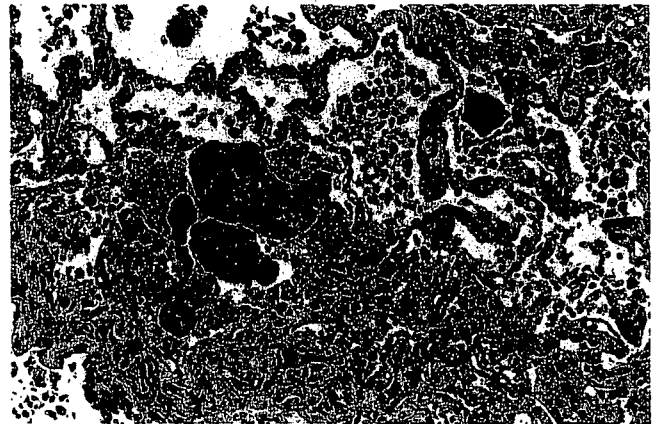
Figure 1. Chest X-ray on admission showed diffuse bilateral alveolar infiltration predominantly in the right hilar portion and the right upper lung field and blurred bilateral costophrenic angles, suspicious of pleural effusions.

On day 22 PaO₂ was 99.0 mmHg and PaCO₂ was 40.3 mmHg. Vital capacity (VC) was 4,580 ml (103.6% of the predicted value). Forced expiratory volume in one second (FEV₁) was 4,260 ml (93.4% of the predicted value). At that time, the patient was challenged with smoking 10 cigarettes (Marlboro®) per day, under informed consent. He developed pleuritic chest pain, headache, and nausea 24 hours after starting smoking. Forty hours later his body temperature rose from 36.7 to 37.5°C, and the PaO₂, VC and FEV₁ decreased to 86.1 mmHg, 3,970 ml, and 3,520 ml, respectively. The CRP, fibrinogen, and alveolar-arterial oxygen pressure difference (A-aDO₂) before the challenge were below 0.3 mg/dl, 256 mg/dl, and 2.4 mmHg, and rose to 2.5 mg/dl, 402 mg/dl, and 15.1 mmHg after the challenge (40 hours after starting smoking), respectively. Consequently, cigarette smoking was discontinued, and then his symptoms subsided and laboratory findings returned to normal. The patient was also challenged with PL granule®, but no symptoms or signs were induced.

After the challenge test, the patient was discharged on his thirty-third hospital day. After about a one-month cessation of cigarette smoking, he resumed smoking several cigarettes per day. Although he experienced intermittent pleuritic chest pain, he continued smoking, gradually increasing to 20 cigarettes per day. Then his chest pain became worse and he visited our hospital. A chest X-ray revealed mild bilateral pleural effusions but no pulmonary infiltrates. Although we advised him to stop smoking cigarettes, he continued smoking. Unexpectedly, his chest pain and pleural effusions gradually subsided with no specific therapy. As we took into account the severity of his initial symptoms of AEP, we continued checking his condition very carefully for about four years. In January 1998, the results of pulmonary function tests (spirometry, arterial blood gases, measurement of diffusing capacity) were normal while



A



B

Figure 2. Transbronchial lung biopsy specimen on the fourth day demonstrated marked bleeding in the alveoli, with infiltration of prominent macrophages, neutrophils, and eosinophils in thickened alveolar walls and air spaces. There was no granuloma or vasculitis. No organisms were detected (A: HE stain, ×70). The specimen on the eighth day demonstrated marked fibrin formation in the alveoli, with infiltration of marked eosinophils and mononuclear cells in alveolar walls and spaces (B: HE stain, ×70).

he continued smoking 20 cigarettes per day.

Discussion

It has been proposed that AEP is associated with cigarette smoking (3, 4), but there has been no direct evidence supporting it. As the present young patient had started cigarette smoking within three weeks before the onset of symptoms and considering that even environmental smoke has been shown to induce wheezing and asthma in young people (5), we suspected that cigarette smoking might be the cause of his illness. So we tried a cigarette smoking challenge under informed consent. As a result, the challenge with cigarette smoke induced the

symptoms and abnormal laboratory data in the patient. Previously, Sasaki et al reported that an 18-year-old man with AEP was challenged by smoking cigarettes (6), and he developed a nonproductive cough and respiratory distress, but without fever, significant X-ray findings or abnormal inflammatory data as CRP and fibrinogen. The present case presented pleuritic chest pain, fever and elevation of CRP and fibrinogen after the challenge. Eosinophilic pleurisy without evidence of an infectious cause was reported to be one of the most important symptoms of AEP (7). It is also important to exclude infections that can present acutely with pulmonary eosinophilia, such as *Pneumocystis carinii* infection (8), and *Aspergillus* pneumonia (9). No pathogenic organisms were detected in any samples obtained from our patient. Furthermore, the present case had a recurrence of pleurisy when he restarted cigarette smoking after a one-month period of smoking cessation. The relapsed symptoms gradually disappeared without any treatment and no recurrence has occurred during the four-year follow-up period. This is probably due to tolerance to repeated resumption of smoking cigarettes in cigarette smoking-induced AEP. The mechanism of tolerance remains unknown. We speculate some possible mechanisms as follows: 1) Repeated exposure to an antigen induces hyposensitization in sensitized guinea pigs (10). A similar phenomenon may be induced in the alveolar region as well as in airways in cigarette smoking-induced AEP. 2) Initial symptoms of AEP such as fever and cough are similar to those of respiratory viral infection. If patients with cigarette smoking-induced AEP initially had suffered from respiratory viral infection which was not accidentally detected in any samples obtained from the patients, the degree of their susceptibility of not only airways (11) but also alveolar region to cigarette smoke might have been increased, resulting in the onset of AEP. Discontinuation of viral infection may induce the tolerance. 3) Several of the patients with cigarette smoking-induced AEP were given drugs such as antibiotics and NSAIDs before the definitive diagnosis of AEP. Such drugs might act as an enhancer in the initial phase of cigarette smoking-induced AEP. In the present case, PL granule[®] alone did not induce any

symptoms or signs by the provocation test, but might have acted as an enhancer in the initial phase of cigarette smoking-induced AEP. AEP usually has an excellent prognosis without relapse (1, 2). This issue may be explained by the tolerance developed by repeated exposure to causative agents.

This is the first report showing direct evidence and a long-term clinical course of cigarette smoking-induced AEP in which tolerance to repeated resumption of smoking cigarettes seems to have developed. We should pay attention to the history of cigarette smoking in seeing patients with AEP, especially in young patients.

References

- 1) Allen JN, Pacht ER, Gadek JE, Davis WB. Acute eosinophilic pneumonia as a reversible cause of noninfectious respiratory failure. *N Engl J Med* **321**: 569–574, 1989.
- 2) Badesch DB, King TE Jr, Schwarz MI. Acute eosinophilic pneumonia: a hypersensitivity phenomenon? *Am Rev Respir Dis* **139**: 249–252, 1989.
- 3) Nakamura H, Kashiwabara K, Yagyu K, et al. Clinical evaluation of three cases of acute eosinophilic pneumonia. *Jpn J Soc Bronchology* **17**: 432–437, 1995 (Abstract in English).
- 4) Hashimoto S, Fukahori T, Ueda M, et al. A case of acute eosinophilic pneumonia. *Respir Res* **12**: 502, 1993 (Abstract in English).
- 5) Cunningham J, O'Connor GT, Dockery DW, Speizer FE. Environmental tobacco smoke, wheezing, and asthma in children in 24 communities. *Am J Respir Crit Care Med* **153**: 218–214, 1996.
- 6) Sasaki T, Nakajima M, Kawabata S, et al. Acute eosinophilic pneumonia induced by cigarette smoke. *J Thoracic Dis* **35**: 89–94, 1997 (Abstract in English).
- 7) Greenburg M, Schiffman RL, Geha DG. *N Engl J Med* **322**: 635, 1990.
- 8) Fleury-Feith J, Van Nhieu JT, Picard C, Escudier E, Bernaudin JF. Bronchoalveolar lavage eosinophilia associated with *Pneumocystis carinii* pneumonia in AIDS patients. *Chest* **95**: 1198–1201, 1989.
- 9) Ricker DH, Taylor SR, Gartner JC Jr, Kurland G. Fatal pulmonary aspergillosis presenting as acute eosinophilic pneumonia in a previously healthy child. *Chest* **100**: 875–877, 1991.
- 10) Lundberg L. Guinea pigs inbred for studies of respiratory anaphylaxis. *Acta Pathol Microbiol Scand [C]* **87C**: 55–66, 1979.
- 11) Empey DW, Laitinen LA, Jacobs L, Gold WM, Nadel JA. Mechanisms of bronchial hyperreactivity in normal subjects after upper respiratory tract infection. *Am Rev Respir Dis* **113**: 131–139, 1976.