

# Phenotypic heterogeneity in a family with FAP due to a TTR Leu58Arg mutation: A clinicopathologic study

著者	Motozaki Yuko, Sugiyama Yu, Ishida Chiho, Komai Kiyonobu, Matsubara Shiro, Yamada Masahito
journal or publication title	Journal of the Neurological Sciences
volume	260
number	1-2
page range	236-239
year	2007-09-15
URL	<a href="http://hdl.handle.net/2297/7021">http://hdl.handle.net/2297/7021</a>

doi: 10.1016/j.jns.2007.03.021

Short communication

**Phenotypic heterogeneity in a family with FAP due to a TTR Leu58Arg mutation: a clinicopathologic study**

Yuko Motozaki<sup>a\*</sup>, Yu Sugiyama<sup>b</sup>, Chiho Ishida<sup>a</sup>, Kiyonobu Komai<sup>a</sup>, Shiro Matsubara<sup>c</sup>,

Masahito Yamada<sup>a</sup>

<sup>a</sup>Department of Neurology and Neurobiology of Aging, Kanazawa University Graduate

School of Medical Science, 13-1 Takara-machi, Kanazawa 920-8641, Japan

<sup>b</sup>Department of Neurology, Kanazawa Municipal Hospital, 3-7-3 Heiwa-machi, Kanazawa

921-8105, Japan

<sup>c</sup>Department of Neurology, Tokyo Metropolitan Neurological Hospital, 261 Musashidai,

Huchu, Tokyo 183-0042, Japan

Disclosure: The authors have no conflicts of interest related to the publication of this article.

\* Corresponding author. Tel.; +81 76 265 2292; fax: +81 76 234 4253.

*E-mail address:* yukokato@med.kanazawa-u.ac.jp (Y. Motozaki).

Characters in the title: 88

Words: 1,098

Key words: familial amyloid polyneuropathy; transthyretin; mutation; carpal tunnel

syndrome; vitreous opacity

## **Abstract**

A family with familial amyloid polyneuropathy (FAP) due to a transthyretin (TTR) Leu58Arg mutation was investigated clinicopathologically. The proband presented with sensori-motor-autonomic polyneuropathy, and autopsy demonstrated massive amyloid deposition in the peripheral nerves and heart. However, the mother was characterized by carpal tunnel syndrome and ocular vitreous opacities. Thus, there was considerable phenotypic heterogeneity among family members despite the identical TTR genotype.

## 1. Introduction

Familial amyloid polyneuropathy (FAP) is a disorder with autosomal dominant inheritance caused by a mutant transthyretin. The clinical features include neurologic and non-neurologic manifestations such as sensorimotor polyneuropathy, autonomic dysfunction, carpal tunnel syndrome (CTS), cardiomyopathy, renal dysfunction, gastrointestinal dysfunction, endocrine dysfunction, vitreous opacity, and glaucoma.

Major foci of FAP are located in Japan, Portugal, and Sweden [1]. In those areas, a TTR Val30Met mutation is most common cause [1]; patients with the Val30Met mutation usually present with sensory dominant polyneuropathy, autonomic failure, rhythm and conduction disturbances of heart, and renal failure. Recently, more than 100 single or double mutations and a deletion in the TTR gene have been reported to be associated with FAP [1].

In 1991, a new mutation causing TTR, Leu58Arg, was reported in a family in Kanazawa, Japan [2]. However, clinical and pathologic features associated with this mutation have not been studied. There have not been any reports of other FAP families with the Leu58Arg mutation. We here describe, for the first time, clinicopathologic

features of the Japanese FAP kindred with a Leu58Arg TTR mutation.

## 2. Case reports

*Patient 1 (V-I).* A 35-year-old man developed left leg weakness without sensory disturbance, and muscle weakness of the both legs slowly progressed. He originated from Kanazawa, Ishikawa prefecture, Japan. His family history through six generations demonstrated two affected and four presumably affected members with autosomal dominant inheritance (Fig. 1). At age 37, neurologic examination demonstrated muscular atrophy and weakness in the distal extremities, dysesthesia in a glove and stocking distribution, and reduced deep tendon reflexes. He also had orthostatic hypotension and impotence. He had no symptom related to the central nervous system. Urine analysis was normal, and echocardiogram showed mild thickening of the ventricular wall with normal wall motion. Nerve conduction studies demonstrated a decrease in the amplitude of complex motor action potentials (CMAP) with decreased motor conduction velocities in the median and ulnar nerves. Furthermore, CMAP was not evoked in the tibial or peroneal nerves. Sensory nerve action potentials could not be elicited in the median,

ulnar or sural nerves. EMG showed chronic denervation in the flexor carpi ulnaris and active denervation in the rectus femoris. Sural nerve biopsy demonstrated marked loss of myelinated and unmyelinated fibers with slight amyloid deposition. Sequencing analysis of the TTR gene following the single-strand conformation polymorphism (SSCP) analysis [2] disclosed a point mutation (CTC→CGC) at codon 58 changing leucine to arginine (Leu58Arg).

Thereafter, both the polyneuropathic and autonomic symptoms slowly progressed. He developed orthostatic syncope at age 42. At age 43, the patient suddenly developed cardiopulmonary arrest, and died of pneumonia three weeks after. The total duration of his illness was 9 years. Autopsy was performed 2.5 hours after death.

Histopathological and immunohistochemical studies of the autopsied tissues demonstrated deposition of TTR-positive amyloid in systemic organs and tissues in various degrees (Table 1, Fig. 2). The heart weighed 550 g, showing cardiomegaly with massive amyloid deposition in the endo- and myocardium (Fig. 2A).

Prominent amyloid deposition was found in the peripheral nervous system including the sciatic nerves (Fig. 2B). In the central nervous system, massive amyloid deposition

was observed in the dura mater (Fig. 2F), in addition to mild amyloid deposition in the leptomeningeal vessels, subpial brain parenchyma (Fig. 2G), and choroid plexus.

Besides the amyloid deposition, acute ischemic changes in the brain and purulent bronchopneumonia were observed.

*Patient 2 (IV-2).* The patient was the mother of Patient 1. She complained of muscle weakness and dysesthesia in the right thumb at age 47. Two month later, she also developed muscle weakness and dysesthesia in the left thumb. She was diagnosed as having bilateral CTS. She received local injection of corticosteroid and surgical treatment for the CTS. Thereafter, however, her symptoms gradually progressed. At age 53, she developed visual disturbance due to the vitreous opacities. Neurological examination at age 62 demonstrated complete blindness in the right eye, blurred vision in the left eye, and reduced sense of touch, pain, and temperature and weakness of the hands due to the CTS. The TTR Leu58Arg mutation was also detected [2].

### **3. Discussion**



Our clinicopathologic investigation of a family with a TTR Leu58Arg mutation demonstrated considerable phenotypic difference between the two affected family members despite the identical TTR genotype. Patient 1 was characterized by sensori-motor and autonomic polyneuropathy with motor involvement as an initial symptom and cardiac amyloidosis in the late stage, whereas Patient 2, the mother of Patient 1, presented with later onset and slower progression of CTS and vitreous opacities.

A variety of clinicopathologic phenotypes have been reported in association with a variety of TTR mutations. CTS is the main feature of the disorder that was formerly called FAP type II, Rukavina [3] or Maryland type [4]. Maryland type FAP was reported to be related to a TTR Leu58His mutation [5-7]. Interestingly, this mutation is at the same site as the mutation found in our patients, but differed in the substituted amino acid. In addition to CTS, the clinical features of FAP with the TTR Leu58His mutation include progressive sensori-motor polyneuropathy, and cardiomyopathy or nephropathy in the advanced stage of the disease or at autopsy [4]. Onset with CTS and slowly progressive course in our Patient 2 with the Leu58Arg mutation resembled the features of FAP with the Leu58His mutation. However, vitreous opacities as found in our Patient 2 are rare, and

polyneuropathy with initial motor involvement as found in our Patient 1 has not been previously reported in FAP with the Leu58His mutation [4-8]. It is reported that different TTR mutants are associated with differences in the efficiency of the endoplasmic machinery that targets destabilized mutant proteins for degradation and the enhanced tendency of these variants to aggregate if secreted, which may lead to different tissue selective amyloid diseases [9]. The phenotypic difference of FAP between the Leu58His and Leu58Arg mutations suggest differences in the secretion efficiency or aggregation characteristics of the TTR variants, despite the same mutation site, as the difference is found between TTR Val30Met and Val30Gly mutations [9].

Different phenotypes between the affected family members despite the identical TTR genotype in this family would indicate that factors other than the mutant TTR influence the pathogenesis of FAP due to the Leu58Arg mutation, as suggested in FAP due to other mutations [10]. These factors would include environmental as well as the other genetic components, requiring further study.

Acknowledgments

The authors thank Ms. Y. Kakuda and Y. Yamaguchi for excellent technical assistance.

This study was supported in part by a grant from the Amyloidosis Research Committee from the Ministry of Health, Labor, and Welfare, Japan.

## References

1. Ando Y, Nakamura M, Araki S. Transthyretin-related familial amyloidotic polyneuropathy. *Arch Neurol* 2005;62:1057-1062.
2. Saeki Y, Ueno S, Yorihuji S, Sugiyama Y, Ide Y, Matsuzawa Y. New mutant gene (transthyretin Arg58) in cases with hereditary polyneuropathy detected by non-isotope method of single-strand conformation polymorphism analysis. *Biochem Biophys Res Commun* 1991;180:380-385.
3. Rukavina JG, Block WD, Jackson CE, Falls HF, Carey JH, Curtis AC, et al. Primary systemic amyloidosis: A review and an experimental, genetic, and clinical study of 29 cases with particular emphasis on the familial form. *Medicine (Baltimore)* 1956;35:239-334.
4. Mahloudji M, Teasdall RD, Adamkiewicz JJ, Hartmann WH, Lambird PA, McKusick VA. The genetic amyloidosis with particular reference to hereditary neuropathic amyloidosis type II (Indiana or Rukavina type). *Medicine (Baltimore)* 1969;48:1-37.
5. Nichols WC, Lieoniaks JJ, McKusick VA, Benson MD. Direct sequencing of the gene for Maryland/German familial amyloidotic polyneuropathy type II and genotyping by

- allele-specific enzymatic amplification. *Genomics* 1989;5:535-540.
6. Goebel HH, Seddigh S, Hopf HC, Uemichi T, Benson MD, McKusick VA. A European family with histidine 58 transthyretin mutation in familial amyloid polyneuropathy. *Neuromuscul Disord* 1997;7:229-230.
7. Mendell JR, Jiang XS, Warmolts JR, Nichols WC, Benson MD. Diagnosis of Maryland/German familial amyloidotic polyneuropathy using allele-specific, enzymatically amplified, genomic DNA. *Ann Neurol* 1990;27:553-557.
8. Jacobson DR, Gorevic PD, Sack GH, Malamet RL. Homozygous transthyretin His 58 associated with unusually aggressive familial amyloidotic polyneuropathy. *J Rheumatol* 1993;20:178.
9. Sekijima Y, Wiseman RL, Matteson J, Hammarstöm P, Miller SR, Sawkar AR, et al. The biological and chemical basis for tissue-selective amyloid disease. *Cell* 2005;121:73-85.
10. Planté-Bordeneuve V, Said G. Transthyretin related familial amyloid polyneuropathy. *Curr Opin Neurol* 2000;13:569-573.

Table 1. Distribution and degree of amyloid deposition in Patient 1

Visceral organs			
Heart	endocardium		+++
	myocardium		+++
Lung	(vascular wall)		+
Liver	(vascular wall)		+
kidney	(glomeruli and vascular wall)		+
Stomach	(mucosa and submucosa)		++
Small intestine	(mucosa and submucosa)		+
Colon	(mucosa and submucosa)		+
Rectum	(mucosa and submucosa)		++
Peripheral nervous system			
	Sciatic nerve		+++
Central nervous system			
	Dura mater		+++
	Leptomeningeal vessel		+
	Subpial brain parenchyma		+
	Choroid plexus		+

-, absent; +, slight deposition; ++, moderate deposition; +++, marked deposition

Figure legends

Figure 1. The pedigree of the family. An arrow (V-I) indicates the proband (Patient 1).

Filled symbols indicate examined FAP patients, and crosshatched symbols indicate unexamined patients suspected of FAP.

Figure 2. Pathologic findings in Patient 1. Amyloid deposits, positive for Congo red (A, B, F, G) with green birefringence under polarized light (C, H), were seen in the myocardium (A), sciatic nerve (B-E), dura mater of the sagittal sinus (F), and subpial region of the brain (arrow heads) (G, H). The amyloid deposits are immunostained with an antibody to TTR (D), but not with an antibody to AA protein (E) or immunoglobulin light chains. (Bar = 100 $\mu$ m )

Figure 1

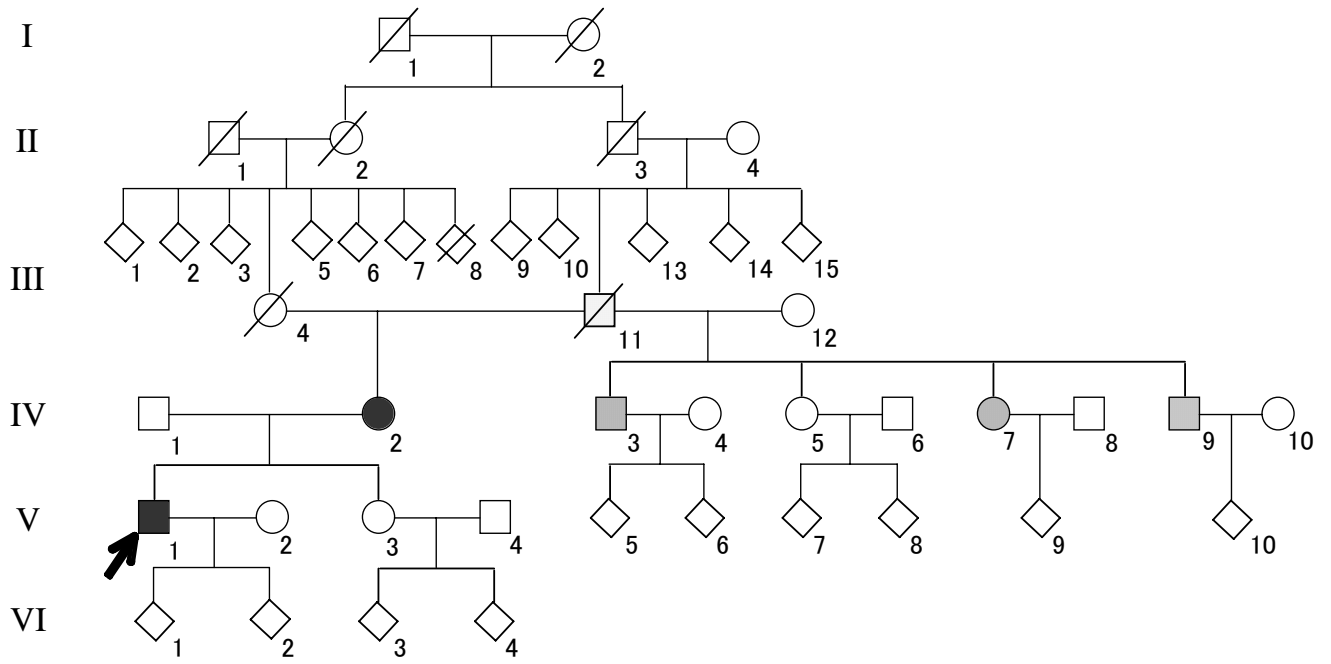




Figure 2

