

The Use of an Intermaxillary Fixation Screw for Mandibular Setback Surgery

著者	Ueki Koichiro, Marukawa Kohei, Shimada Mayumi, Nakagawa Kiyomasa, Yamamoto Etsuhide
journal or publication title	Journal of Oral and Maxillofacial Surgery
volume	65
number	8
page range	1562-1568
year	2007-08-01
URL	http://hdl.handle.net/2297/6929

doi: 10.1016/j.joms.2006.10.071

The use of inter-maxillary fixation (IMF) screw for mandibular setback surgery

KOICHIRO UEKI¹, KOHEI MARUKAWA¹, MAYUMI SHIMADA¹, KIYOMASA
NAKAGAWA¹, ETSUHIDE YAMAMOTO¹

1) Department of Oral and Maxillofacial Surgery, Graduate School of Medicine,
Kanazawa University, 13-1 Takaramachi, Kanazawa 920-8641, Japan.

Address correspondence to: Koichiro Ueki, DDS, PhD

Department of Oral and Maxillofacial Surgery, Graduate School of Medicine,
Kanazawa University, 13-1 Takaramachi, Kanazawa 920-8641, Japan.

Tel: +81-76-265-2444; Fax: +81-76-234-4268

E-mail: kueki@med.kanazawa-u.ac.jp

Key words: IMF (inter-maxillary fixation) screw, sagittal split ramus osteotomy,
cephalogram

Abstract

Purpose: The purpose of this study was to assess skeletal stability after mandibular setback surgery with and without an inter-maxillary fixation (IMF) screw.

Subjects and Methods: The subjects consisted of 40 patients with mandibular prognathism. The subjects underwent sagittal split ramus osteotomy (SSRO) with titanium plate fixation and were divided into two groups, one with and one without an IMF screw. A lateral cephalogram was done preoperatively, immediately after surgery, and 1 month, 3 months and 6 months postoperatively. The two groups were then compared statistically.

Results: In the comparison of the time-course change between the two groups with repeated measure ANOVA, there were significant differences in occlusal plane (between subjects, $F=2.517$; $df=4$; $P=0.0437$) and convexity (between subjects, $F=4.048$; $df=4$; $P=0.0038$). However, there was no significant difference in the other measurements.

Conclusion: This study suggested that in most measurements, there was no significant difference between two groups with and without IMF screw in time-course skeletal change. However, use of IMF screw was helpful for orthognathic surgery as a rigid anchor of IMF.

Traditionally, inter-maxillary fixation (IMF) has been achieved with arch bars or interdental eyelet wiring. These techniques have some intrinsic disadvantages, so a unit for temporary IMF has been developed. IMF with bone screws was described as a technique in 1989 when it was proposed as the sole means of fracture treatment.¹ Use of intraoral cortical bone screws for intermaxillary fixation is a valid alternative to arch bars in the treatment of mandibular fractures. Iatrogenic injury to dental roots is the most important problem of this procedure, but this can be minimized by an experienced surgeon.²

Recently, mini-implants, which are small screws typically used for craniofacial surgery applications have been used to enhance anchorage. Clinical reports demonstrate the viability of using mini-screws for skeletal anchorage to support a variety of orthodontic tooth movement.³⁻⁷

Sagittal split ramus osteotomy (SSRO) or intraoral vertical ramus osteotomy (IVRO) are frequently used for the treatment of mandibular prognathism. In these procedures, IMF or elastic traction is used immediately after surgery to establish ideal occlusion and skeletal morphology. Conventionally, surgical hooks attached to the orthodontic wire have been used for IMF or traction. However, in cases in which the setback amount or counterclockwise rotation is large, a significant extrusive load at the anterior teeth can occur immediately after surgery until muscle function adapts to postoperative mandibular morphology and occlusion. Therefore, we recently used the IMF screw implanted at the anterior teeth region to reduce the extrusive load of anterior teeth.

The purpose of this study was to compare skeletal stability after mandibular

setback surgery with and without inter-maxillary fixation (IMF) screw.

Patients and Methods

Patients

The 40 Japanese adults in this study presented with jaw deformities diagnosed as mandibular prognathism. At the time of orthognathic surgery, the patients ranged in age from 15 to 45 years, with a mean age of 21.6, standard deviation 6.0 years.

Surgery

The groups were randomized to show similar distribution in preoperative SNB. Of the 40 patients in this study, 20 underwent bilateral SSRO for correction of their mandibular deformities. Other procedures were not performed. A total of 4 IMF screws® (2×8 mm) (Stryker Leibinger, Freiburg, Germany) were implanted between lateral incisors and canines at the region of anterior alveolar bone in the maxilla and mandible (Fig. 1). IMF screws and the main orthodontic wires were connected with 0.4 mm wire when the IMF screw was covered by oral mucosa. After osteotomy, rigid fixation for the bony segments was achieved with titanium mini-plates and monocortical screws (4 holes/bur 8 mm interval length 0.55 mm thickness) and 4 screws (2×7 mm) (Würzburg titanium miniplate system, Leibinger Co., Freiburg, Germany). IMF using IMF screws and wire was performed from postoperative day 1 to approximately 1 week postoperatively. IMF immediately after the operation was removed to avoid the risk of airway and obstruction and aspiration by vomiting. After this IMF period, elastic

traction with hooks attached to the orthodontic main wire was combined with IMF screws to maintain the ideal occlusion. The patients ranged in age from 15 to 35 years, with a mean age of 21.7 (standard deviation 5.6) years.

The other 20 patients underwent bilateral SSRO with rigid fixation with a titanium mini-plate and monocortical screws used in the same manner. Other procedures were not performed. However, the IMF screw was not implanted and IMF was not performed. Elastic traction with hooks attached to the orthodontic main wire was done to maintain the ideal occlusion from postoperative 1 day. The patients ranged in age from 15 to 45 years, with a mean age of 21.5 (standard deviation 6.6) years.

All 40 patients received orthodontic treatment before and after surgery.

Cephalogram assessment Lateral cephalogram were done to assess the skeletal changes before operation, immediately after surgery, and 1 month, 3 months and 6 months after surgery. Lateral cephalograms were analyzed preoperatively and postoperatively with the use of computer software (Cephalometric A to Z, Yasunaga Labo., Fukui, Japan). Measurements were shown in Fig. 2. One skilled observer performed all digitization so that the cephalometric method errors were small and acceptable in this study. Error analysis by digitization and remeasuring 10 randomly selected cases generated an average error less than 0.4 mm for the linear measurements and 0.5 degree for the angle measurements.

Statistical analysis: Data were statistically analyzed with Stat View 4.5 (ABACUS Concepts, Inc., Berkeley, CA, USA) and Dr. SPSSII (SPSS Japan Inc., Tokyo, Japan)

Time-dependent changes (times×group) in cephalometric measurements were examined by repeated measure analysis of variance (repeated measure ANOVA). Comparisons between IMF group and non-IMF group in each period were performed and adjusted using Bonferroni correction. Differences were considered significant at $P<0.05$.

Results

After surgery, no patient had wound infection or dehiscence, bone instability or non-union or long-term malocclusion. Mean setback was 6.7 ± 3.2 mm on the right side and 6.4 ± 3.2 mm on the left side in the IMF screw group, and 6.1 ± 2.9 mm on the right side and 6.5 ± 4.1 mm on the left side in the group without the screw. In the IMF screw group, there was no breakage or loss of the screw and iatrogenic dental injuries were not found. However, in 3 cases, screws implanted at maxillary alveolar bone were covered by oral mucosa at the time of removal (6 screws total). The period of use of IMF screws was mean 13.9 days, standard deviation 5.1 days.

In the comparison of the time-course change between two groups using repeated ANOVA measure, there were significant differences between the two groups in occlusal plane (between subjects, $F=2.517$; $df=4$; $P=0.0437$) and convexity (between subjects, $F=4.048$; $df=4$; $P=0.0038$). However, there was no significant difference in the other measurements (Figs. 3 and 4, Table.1).

In the comparison between groups in each period with t-test, there were significant differences after 1 month ($P=0.0419$) and 3 months ($P=0.0469$), and there were no significant differences in mandibular length pre-operatively, immediately after operation

and after 6 months. In ANS-Me, there were significant differences immediately after operation ($P=0.0321$) and at 6 months ($P=0.0491$), but there were no significant differences pre-operatively, or after 1 month and 3 months (Figs. 5 and 6, Table.1). There were no significant differences in the other measurements.

Discussion

The use of the bone screw for temporary intermaxillary fixation provides many benefits to patients and surgeons. These benefits are: quick, easy and safe insertion; compatibility with any plating system; no discomfort to the patient; reduced trauma to the buccal mucosa; ideal for use when teeth have been heavily restored; ease of maintaining gingival health compared to h arch bars and eyelet wires; and easy, painless removal without anesthesia in the outpatient department.⁸ The screws can also be used as anchors for elastic traction.

There are some reports that the use of intraoral cortical bone screws for intermaxillary fixation is a valid alternative to arch bars in the treatment of mandibular fractures, but objective data was not presented.^{1,2,4,8,9} There are also some clinical reports that demonstrated the viability of using a mini-screw for skeletal anchorage to support a variety of orthodontic tooth movements.^{5-8,10} However, these reports did not describe the usefulness of an IMF screw in orthognathic surgery.

In the previous studies regarding mandibular fracture, Coburn et al.⁴ reported that one hundred and twenty-two patients with mandibular fractures had IMF screws. Five patients (4%) developed complications including fracture of the screws on insertion, iatrogenic damage to teeth causing tooth loss and bony sequestra around the area of

screw placement. Roccia et al.² noted that 4.9% of the screws were covered by oral mucosa, 1.9% were lost, and none were broken. He stated that the most important complication was iatrogenic damage to dental roots (1.5%). Malocclusion was observed in one patient (1.6%) and lack of consolidation of a displaced fracture of the mandibular bony.

In this study, breakage, loss of the screw and iatrogenic dental injuries were not found. However, screws were covered by oral mucosa at the time of removal in 3 cases (6 screws) implanted at maxillary alveolar bone. We wanted to use the IMF screws as rigid anchors so we used 0.4 mm wire to connect the IMF screw to the main orthodontic wire. We then used the surgical hook attached to the main orthodontic wire with the IMF screws indirectly in the maxilla and the mandible. Even if the IMF screw was covered by mucosa, the anchorage function of IMF could be used significantly.

Screws placed in an interradicular location should not impinge on adjacent root structures. Published studies about mini-screws described the site of insertion as mid-root or at/beyond the root apex.^{3,5-7,10} However, regarding root injury, Asscherickx et al.¹¹ stated that histological examination of three teeth damaged by mini-implants demonstrated an almost complete repair of the periodontal structure (e.g. cementum, periodontal ligament and bone). In this study, IMF screws were implanted between a lateral incisor and a canine at the region of anterior alveolar bone. IMF or elastic traction was performed starting one day after the operation. Postoperative facial swelling and a decrease in mouth opening distance occurred in all patients postoperatively, so it was easier to treat the screws at the anterior region rather than those at the posterior region. Furthermore, when the anatomical structure of the s

maxillary sinus and mental foramen in the mandible was considered, these regions were considered to be valid sites to rigidly fix the screws. The IMF screw was needed for immediate loading after implantation, and it could receive the horizontal force of the persistent opening tendency of the anterior teeth. Therefore, the region with rigid bicortical bone region was selected.

Some investigators currently use a period of IMF in order to minimize relapse.^{12,13} Krekmanov et al.¹⁴ reported that bicortical screw fixation without IMF is sufficient to counteract any relapse. However, on the basis of our previous report,¹⁵ we used semi-rigid fixation with a titanium plate in this study. We also agree that the IMF period should be shortened or omitted, but elastic traction was necessary to establish the ideal occlusion. Therefore, the IMF screw was used to prevent the anterior teeth from erupting as a skeletal anchor. In fact, it was difficult to detect and compare the difference in the degree of eruption of anterior teeth.

From the results of this study, it was not found that there was significant differences between non-IMF screw group and the IMF screw group in most measurements. In mandibular length, non-IMF screw group had a change after 1 and 3 months. This cannot be attributable to the lack of IMF screws because they were removed at a mean of 14 days after surgery. However, the difference in ANS-Me immediately after surgery suggested that anterior vertical height in the IMF screw group became shorter than the non- IMF screw group. The difference in the time-course change in occlusal plane suggested that mandibular clockwise rotation after operation could be achieved in IMF screw group. At least immediately after surgery, use of IMF might have an effect. However, it could not be found the difference clearly between two

groups after more than 1 month. Although, in Convexity, there was significant difference in time-course change, the change after 3 and 6 months seemed to be pronounced. This might not be the effect of IMF screw, because of after removal of IMF screws.

In conclusion, this study suggested that in most measurements, there was no significant difference between two groups with and without IMF screw in time-course skeletal change. However, use of IMF screw was helpful for orthognathic surgery as a rigid anchor of IMF.

References

- 1) Arthur G., Bernando N. Simplified method of maxillo-mandibular fixation. *J Oral Maxillofac Surg* 47: 1234, 1989.
- 2) Roccia F., Tavolaccini A., Dell'acqua A., Fasolis M. An audit of mandibular fractures treated by intermaxillary fixation using intraoral cortical bone screws. *J Cranio-maxillofac Surg* 33: 251, 2005.
- 3) Kanomi R. Mini-implant for orthodontic anchorage. *J Clin Orthod* 31: 763, 1997.
- 4) Coburn DG., Kennedy DWG., Hodder SC. Complications with intermaxillary fixation screws in the management of fractured mandibles. *Br J Oral Maxillofac Surg* 40: 241, 2002.
- 5) Lee JS, Park HS, Kyung HM, Sung JH. Micro-implant anchorage for lingual treatment of a skeletal class II malocclusion. *J Clin Orthod* 35: 643, 2001.
- 6) Park HS, Bae SM, Kyung HM, Sung JH. Micro-implant anchorage for treatment of skeletal class I bialveolar protrusion. *J Clin Orthod* 35: 417, 2001.
- 7) Park YC, Lee SY, Kim DH, Jee SH. Intrusion of posterior teeth using mini-screw implants. *Am J Orthod Dentofacial Orthop* 123: 690, 2003.
- 8) Jones DC. The intermaxillary screws: a dedicated bicortical bone screw for temporary intermaxillary fixation. *Br J Oral Maxillofac Surg* 37: 115, 1999.
- 9) Gordon KF, Read JM, Anand VK. Results of intraoral cortical bone screw fixation technique for mandibular fractures. *Otolaryngol Head Neck Surg* 113: 248, 1995.
- 10) Costa A, Raffaini M, Melsen B. Miniscrews as orthodontic anchorage: a preliminary report. *Int J Adult Orthod Orthognath Surg* 13: 201, 1998.

- 11) Asscherickx K, Vannet BV, Wehrbein H, Sabzevar MM. Root repair after injury mini-screw. *Clin Oral Impl Res* 16: 575, 2005.
- 12) Franco JE, Van Sickels JE, Thrash WJ. Factors contributing to relapse in rigidly fixed mandibular setback. *J Oral Maxillofac Surg* 47: 451, 1989.
- 13) Perrot DH, Lu YF, Pogrel MA, Kaban LB. Stability of sagittal split osteotomies: a comparison of three stabilization techniques. *Oral Surg Oral Med Oral Pathol Oral Radiol Endod* 78: 696, 1994.
- 14) Krekmanov V, Lilja J, Ringqvist M. Sagittal split osteotomy of the mandible without postoperative intermaxillary fixation. *Scand J Plast Reconstr Surg* 23: 115, 1989.
- 15) Ueki K, Nakagawa K, Takatsuka S, Yamamoto E. Plate fixation after mandibular osteotomy. *Int J Oral Maxillofac Surg* 30: 490, 2001.

Legends

Figure 1. Method of IMF screw implantation. A)IMF screw, B) intra-oral photograph, C) lateral cephalogram. Arrows show IMF screws.

Figure 2. Lateral cephalometric analysis. 1)Occlusal angle to SN, 2)Convexity, 3)Mandibular length, 4)ANS-Me.

Figure 3. Change in occlusal plane to SN. There was a significant difference in the time-course change between the two groups with ANOVA.

Figure 4. Change in the convexity. There was a significant difference in the time-course change between the two groups with ANOVA.

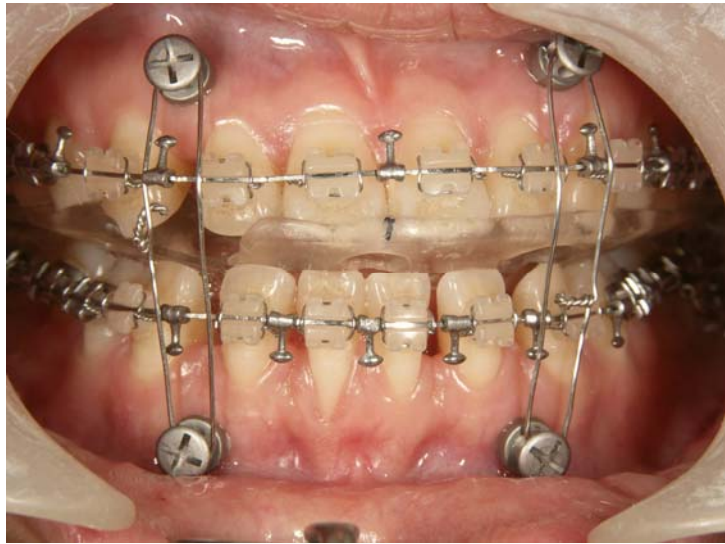Figure 5. Change in mandibular length. * indicates a significant difference at $P<0.05$ with t-test.

Figure 6. Change in ANS-Me. * indicates a significant difference at $P<0.05$ with t-test.

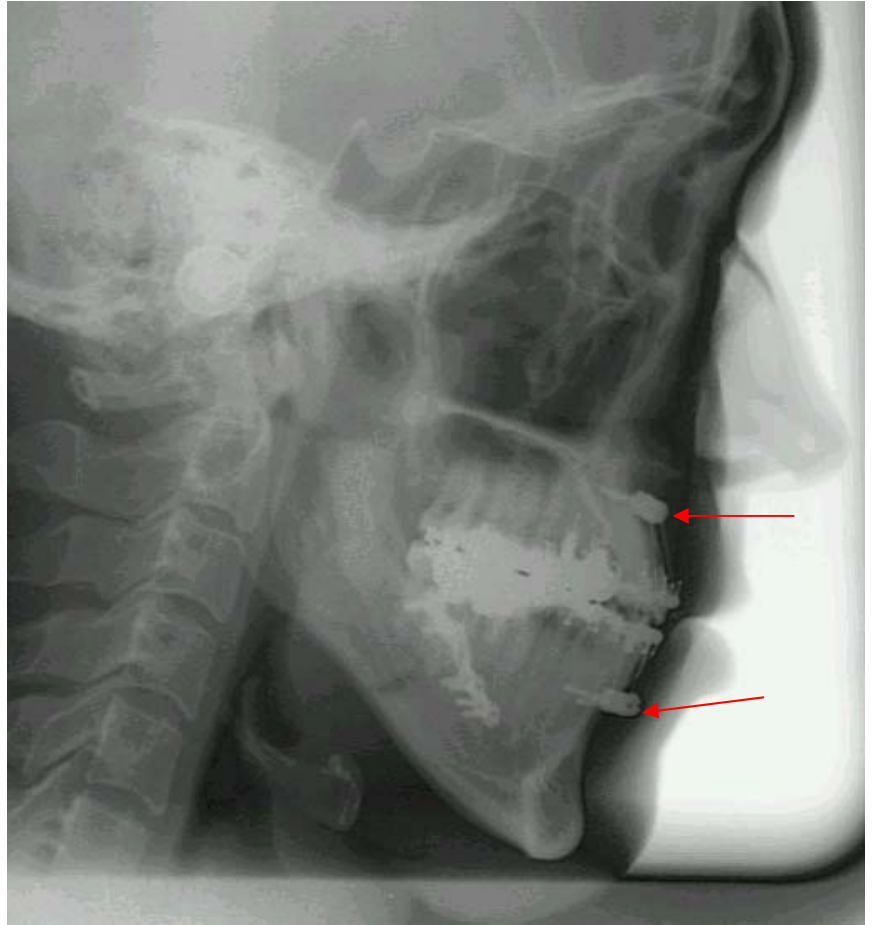Table 1. Cephalometric analysis results. SD indicates standard deviation.



A



B



C

Fig. 1

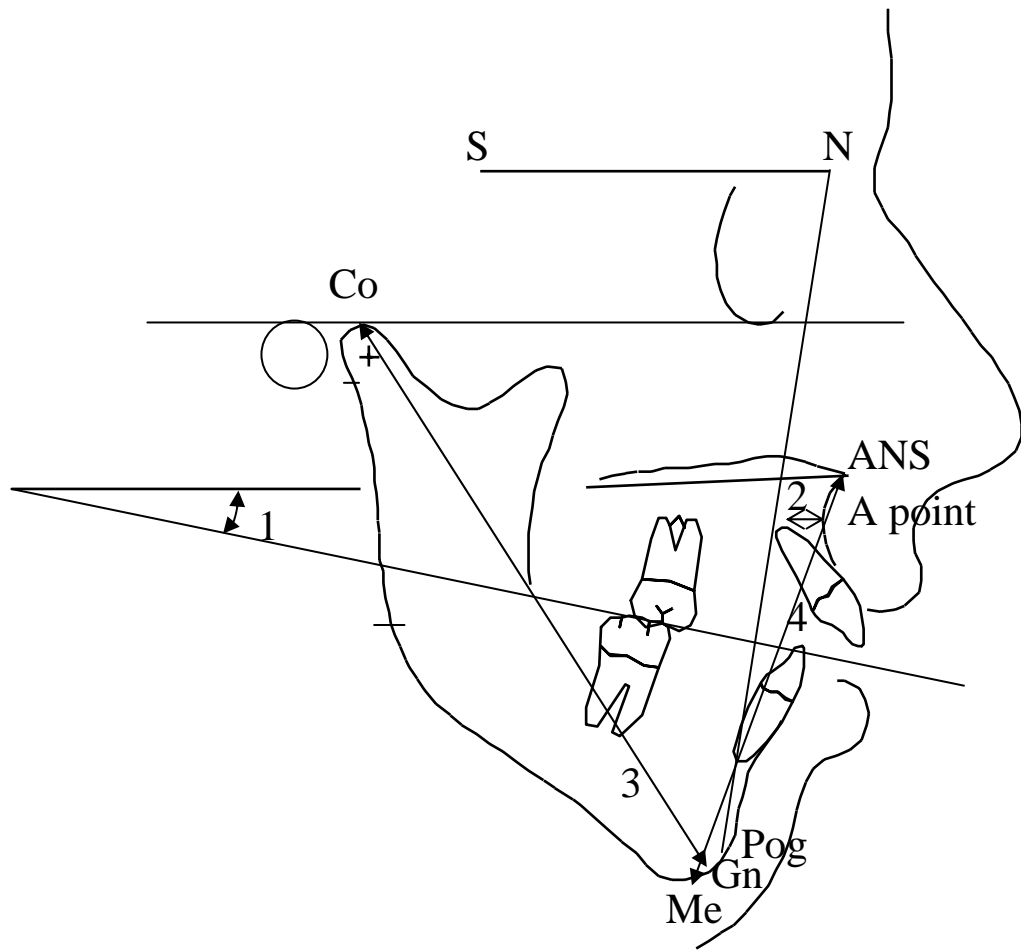


Fig. 2

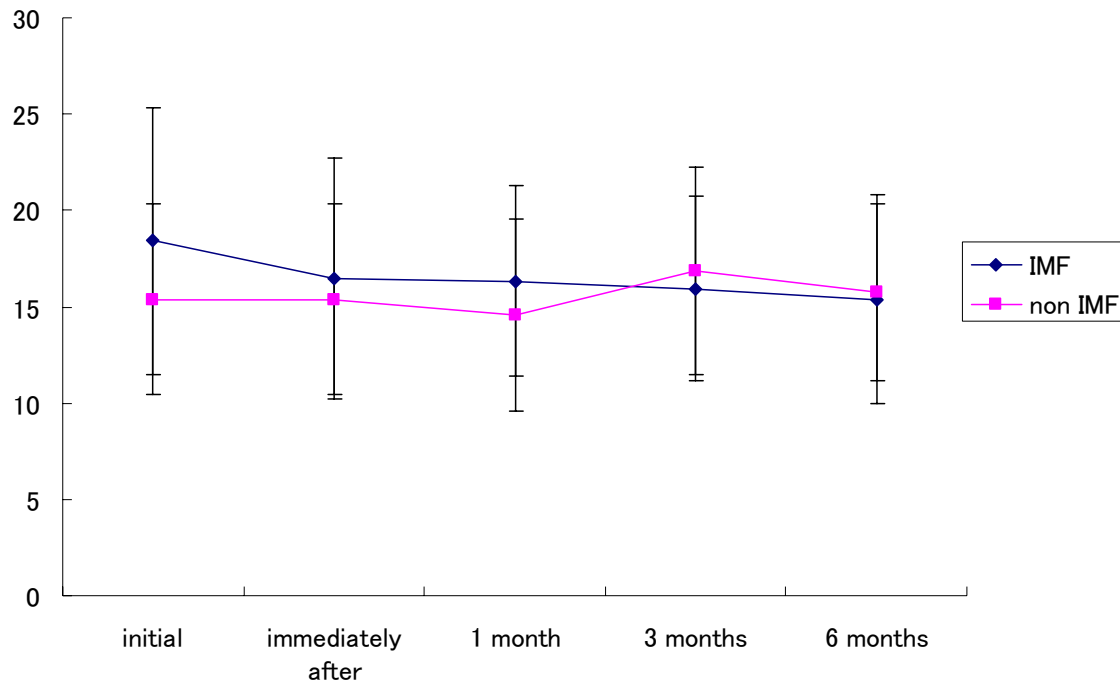


Fig. 3

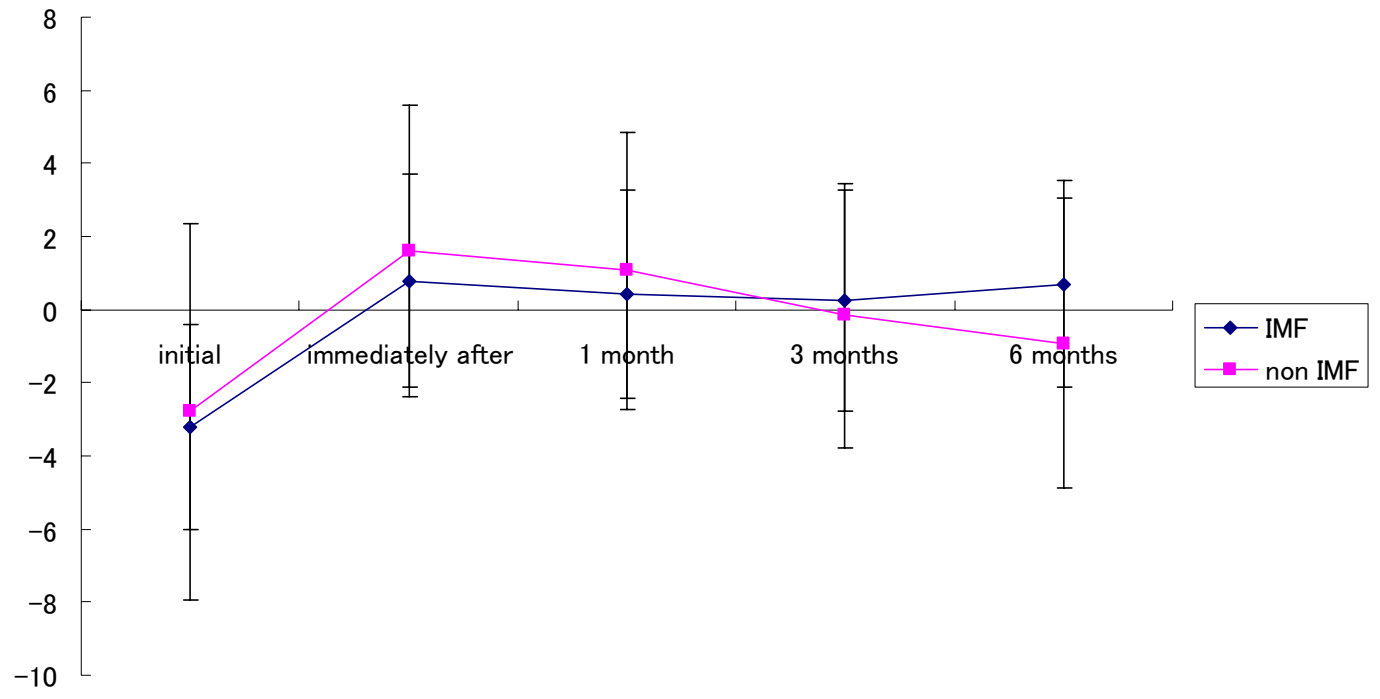


Fig.4

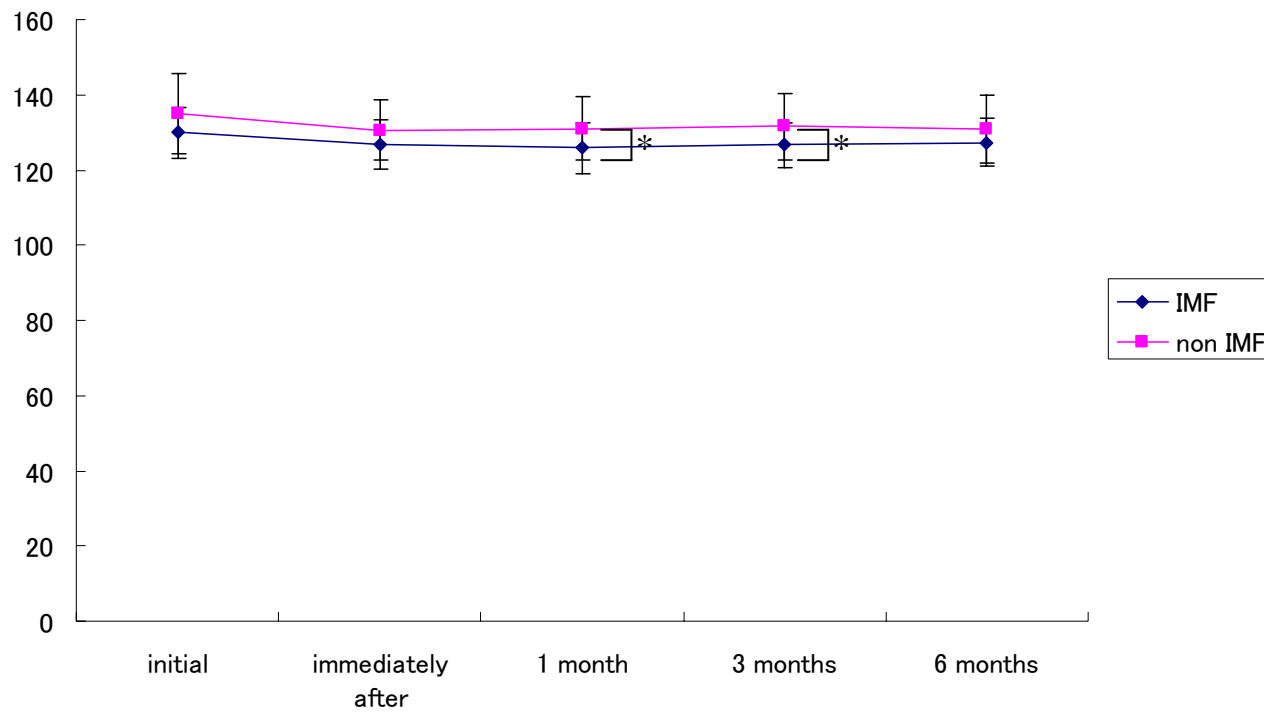


Fig. 5

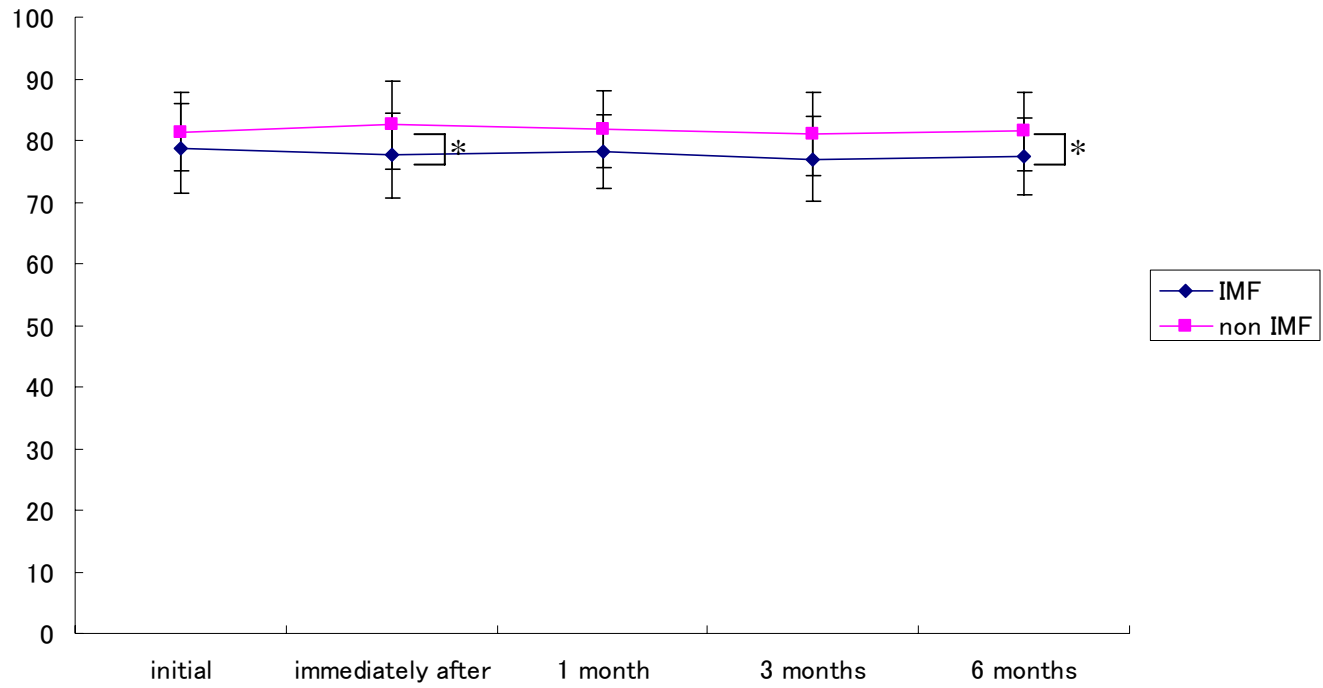


Fig. 6

IMF screw group	Initial		Immediately after		1 month		3 months		6 months	
	Average	SD	Average	SD	Average	SD	Average	SD	Average	SD
SNB	83.1	4.9	80.7	4.4	80.2	3.7	80.6	4.2	80.7	3.7
Occlusal Plane - SN	18.4	6.9	16.5	6.2	16.3	4.9	15.9	4.8	15.4	5.4
Mandibular Length(Co-Gn)	129.9	6.8	126.8	6.4	125.9	6.8	126.7	5.9	127.4	6.5
Gonial angle	133.0	7.5	129.6	7.6	130.6	6.7	132.3	8.1	132.7	7.4
Convexity	-3.2	2.8	0.8	2.9	0.4	2.9	0.3	3.0	0.7	2.8
ANS-Menton	78.7	7.4	77.6	7.0	78.2	6.0	77.0	6.9	77.5	6.2
Interincisal Angle	124.2	10.0	131.7	8.7	126.9	7.2	125.7	7.7	126.5	7.7
Incisor Overjet	-4.1	2.5	2.9	0.9	3.3	0.9	3.3	0.8	3.2	0.8
Incisor Overbite	-0.4	2.4	0.4	0.8	0.6	0.9	0.9	0.8	0.7	1.0

Non IMF screw group	Initial		Immediately after		1 month		3 months		6 months	
	Average	SD	Average	SD	Average	SD	Average	SD	Average	SD
SNB	83.8	5.6	80.7	4.5	81.4	3.9	81.8	4.3	81.7	4.4
Occlusal Plane - SN	15.4	4.9	15.4	5.0	14.6	5.0	16.9	5.4	15.7	4.6
Mandibular Length(Co-Gn)	135.0	10.5	130.6	7.9	131.0	8.5	131.6	8.8	130.8	9.0
Gonial angle	133.3	5.9	131.9	7.1	132.7	8.3	133.9	7.7	134.6	8.3
Convexity	-2.8	5.2	1.6	4.0	1.1	3.8	-0.2	3.6	-0.9	4.0
ANS-Menton	81.4	6.4	82.5	7.1	81.9	6.2	81.0	6.8	81.5	6.4
Interincisal Angle	127.7	10.0	130.2	9.9	130.8	10.4	129.0	10.1	129.4	8.3
Incisor Overjet	-3.0	4.4	3.1	1.4	3.4	1.5	3.6	0.9	3.3	1.4
Incisor Overbite	0.2	4.0	1.2	1.9	1.5	1.4	1.2	2.0	1.9	1.6

Table 1.