

Comparison of maxillary stability after Le Fort I osteotomy for occlusal cant correction surgery and maxillary advanced surgery

著者	Ueki Koichiro, Hashiba Yukari, Marukawa Kohei, Yoshida Kan, Shimizu Chika, Nakagawa Kiyomasa, Yamamoto Etsuhide
journal or publication title	Oral Surgery, Oral Medicine, Oral Pathology, Oral Radiology, and Endodontics
volume	104
number	1
page range	38-43
year	2007-07-01
URL	http://hdl.handle.net/2297/6699

doi: <https://doi.org/10.1016/j.tripleo.2006.11.018>

Comparison of maxillary stability after Le Fort I osteotomy for occlusal cant correction surgery and maxillary advanced surgery

KOICHIRO UEKI, YUKARI HASHIBA, KOHEI MARUKAWA, KAN YOSHIDA,
CHIKA SHIMIZU, KIYOMASA NAKAGAWA and ETSUHIDE YAMAMOTO¹

Department of Oral and Maxillofacial Surgery (Chief: Prof. E. Yamamoto, DDS, PhD),
Graduate School of Medicine, Kanazawa University, Kanazawa, Japan.

Key words: maxillary stability, Le Fort I osteotomy, bimaxillary, asymmetry

Address correspondences to: Koichiro Ueki, DDS, PhD

Department of Oral and Maxillofacial Surgery, Graduate School of Medicine,
Kanazawa University, 13-1 Takaramachi, Kanazawa 920-8641, Japan.

Tel: +81-76-265-2444; Fax: +81-76-234-4268

E-mail: kueki@med.kanazawa-u.ac.jp

Comparison of maxillary stability after Le Fort I osteotomy for occlusal cant correction surgery and maxillary advanced surgery

Abstract

Purpose: This study was designed to compare postoperative maxillary stability following Le Fort I osteotomy for the correction of occlusal cant as compared with conventional Le Fort I osteotomy for maxillary advancement.

Subjects and Methods: The subjects were 40 Japanese adults with jaw deformities. Of these, 20 underwent a Le Fort I osteotomy and intraoral vertical ramus osteotomy (IVRO) to correct asymmetric skeletal morphology and inclined occlusal cant. The other 20 patients underwent a Le Fort I osteotomy and sagittal split-ramus osteotomy (SSRO) to advance the maxilla. Lateral and posteroanterior cephalograms were taken postoperatively and assessed statistically. Thereafter, the two groups were followed for time-course changes.

Results: There was no significant difference between the two groups with regard to time-course changes during the immediate postoperative period.

Conclusion: This suggests that maxillary stability after Le Fort I osteotomy for cant correction does not differ from that after Le Fort I osteotomy for maxillary advancement.

Introduction

The Le Fort I osteotomy is frequently used for the correction and treatment of dentofacial deformities, particularly in maxillary advancement. The development of surgical procedures to reposition the maxilla superiorly has made it possible to treat many dentofacial deformities successfully.¹ Moreover, greater confidence in the adequacy of the blood supply has led to the downfracture technique for total maxillary osteotomy.^{2,3} This technique reportedly frees the palate and dentoalveolar portion of the maxilla so that superior repositioning posteriorly or anteriorly is feasible with or without the creation of multiple dentoalveolar segments. However, it is sometimes difficult to move the maxilla superiorly and posteriorly by the conventional method, excising only the posterior maxillary tuberosity with preservation of the descending palatine vessel. In cases that are unsuitable for maxillary advancement, especially in patients with maxillary asymmetry or protrusion, it is necessary to mobilize the pterygoid process in order to achieve ideal maxillary movement. Therefore we herewith report the modified Le Fort I technique with artificial fracture of the pterygoid process using an ultrasonic bone curette.⁴

In previous studies, superior surgical repositioning has been shown to result in excellent skeletal stability on lateral cephalogram.^{1,5-11}, although data of frontal cephalogram has not been evaluated. Symmetrical facial apparatus and symmetrical smile line are essential to get the esthetical improvement. Moreover, in our previous study, the incidence of disc displacement in temporomandibular joint was 18.2% in the class III symmetry group and 56.8% in the class III asymmetry group¹². These results suggest that asymmetry increases the occurrence of TMJ dysfunction. In short, skeletal

and occlusal symmetry was also very important functionally. However, there has been no report regarding maxillary repositioning in patients with bimaxillary asymmetry. Furthermore, there has been no report comparing surgery for maxillary advancement with that for occlusal cant correction.

This study was designed to compare postoperative maxillary stability between Le Fort I osteotomy for the correction of occlusal cant and conventional Le Fort I osteotomy for maxillary advancement.

Patients and Methods

Patients

The subjects were 40 Japanese adults with jaw deformities. Of these, 20 presented with jaw deformities diagnosed as bimaxillary asymmetry. The other 20 were diagnosed with mandibular prognathism with maxillary retrognathism requiring maxillary advancement. At the time of orthognathic surgery, the patients ranged in age from 17 to 34 years (mean, 24.1 years). All received orthodontic treatment both before and after surgery.

Surgery

Twenty patients underwent a Le Fort I osteotomy and bilateral intraoral vertical ramus osteotomy (IVRO) to alter occlusal cant, predominantly for the correction of asymmetry ("cant" group) (Fig. 1). In this group, Le Fort I osteotomy was performed as reported previously.⁴ Two PLLA L-type miniplates (10 × 22 × 1.5 mm) with four (2 × 8 mm) screws (Fixorb-MX; Takiron Co., Osaka, Japan) and two straight PLLA

plates ($28 \times 4.5 \times 1.5$ mm) with four (2×8 mm) screws (Fixorb-MX; Takiron Co.) were used to fix the maxilla. Segmental fixation was not performed after IVRO. After several days of maxillomandibular fixation (MMF) with wire, guiding elastic bands were placed to maintain ideal occlusion. The mean age of these patients was 25.6 years (range, 17 to 32 years; SD, 5.1 years).

The remaining 20 patients underwent Le Fort I osteotomy and bilateral SSRO (by the Obwegeser method) to advance the maxilla and set back the mandible, predominantly for the correction of mandibular prognathism (“advance” group). PLLA plates were used to fix the advanced maxilla in position, as in the cant group, and two PLLA miniplates ($28 \times 4.5 \times 1.5$ mm) with four (2×8 mm) screws (Fixorb-MX; Takiron Co.) were used for bilateral internal fixation of the mandible. After several days of maxillomandibular fixation (MMF) with wire, guiding elastic bands were placed to maintain ideal occlusion. The mean age of these patients was 22.1 years (range, 16 to 34 years; SD, 5.4 years).

Cephalographic assessment

All patients underwent lateral and posteroanterior cephalography to assess skeletal changes preoperatively, immediately after surgery, and 1, 3, 6, and 12 months postoperatively (Fig. 2). To assess maxillary stability, arbitrary points for the anterior nasal spine (ANS), posterior nasal spine (PNS), A point, and incisor edge were defined and measured from preoperative images and subsequently transferred to all remaining radiographs. One skilled observer performed all digitization so that errors in

cephalometric method were small and acceptable for the purposes of this study. Error analysis by digitization and the remeasuring of 10 randomly selected cases generated an average error less than 0.4 mm for the linear measurements and 0.5 degree for the angular measurements.

Lateral cephalometric analysis

SNA: angle between the sella- nasion plane and the nasion–A point plane

S-A parallel to SN: distance between the A point and the sella parallel to the SN plane

S-A perpendicular to SN: distance between the A point and the sella perpendicular to the SN plane

S-PNS parallel to SN: distance between the arbitrary PNS and the sella parallel to the SN plane

S-PNS perpendicular to SN: distance between the arbitrary PNS and the sella perpendicular to the SN plane

mx1-S parallel to SN: distance between the incisor edge and the sella parallel to the SN plane

mx1-S perpendicular to SN: distance between the incisor edge and the sella perpendicular to the SN plane

S-ANS parallel to SN: distance between the arbitrary ANS and the sella parallel to the SN plane

S-ANS perpendicular to SN: distance between the arbitrary ANS and the sella perpendicular to the SN plane

Posteroanterior cephalometric analysis

Mx-Md midline: angle between the ANS-Menton line and the line perpendicular to the bilateral zygomatic frontal suture line

Deviation side mx6 to Zy-Zy: distance between the most buccal point at the first molar crown on the deviation side and the line connecting the most lateral points of the bilateral zygomatic arches (Zy-Zy)

Nondeviation side mx6 to Zy-Zy: distance between the most buccal point of the left molar crown on the nondeviation side and Zy-Zy

Ratio: ratio of the deviation side mx6 to Zy-Zy to the nondeviation side mx6 to Zy-Zy

Occlusal cant: angle between Zy-Zy and the line from the most buccal point at the right first molar crown to the most buccal point of the left molar crown

A positive Mx-Md midline angle represents mandibular deviation to the left and a negative angle indicates mandibular deviation to the right. A positive occlusal cant represents right elevation of the occlusal plane and a negative cant shows left elevation of the occlusal plane. The Mx-Md midline angles of all cases were then given positive values, so that all consecutive measurements could be attributed to either the deviated or nondeviated side before statistical analysis was performed.

Statistical analysis

Data were statistically analyzed with StatView software, version 4.5 (ABACUS Concepts, Inc., Berkeley, CA, USA). Time-dependent changes after surgery in cephalometric measurements were examined using analysis of variance (ANOVA). Each serial period was defined and the differences between measurements were

calculated as follows.

T1: (immediately after surgery versus preoperative)

T2: (after 1 month versus immediately after surgery)

T3: (after 3 months versus after 1 month)

T4: (after 6 months versus after 3 months)

T5: (after 1 year versus after 6 months)

Then the data between groups were compared by paired comparison using Student's t-test. Differences were considered significant at $p < 0.05$.

Results

In the cant group, the Le Fort I osteotomy was safely achieved with minimal bleeding (mean, 275.0 mL; SD, 144.2 mL) and no notable complications. In the advance group, mean bleeding was 221.1 mL; SD, 122.3 mL. There were no notable complications. There was no significant difference between the two groups in the amount of bleeding.

There were significant differences between two groups in preoperative measurements of Mx-Md midline ($p = 0.0001$), ratio ($p = 0.005$), and occlusal cant ($p = 0.0132$), so that division of this study could be considered valid.

There was no significant differences between the two groups in all measurements by repeated-measure ANOVA (Bonferroni correction was also performed) in time-dependent change after surgery (excluding preoperative data) (Tables I and II).

There were significant difference between the groups in S-PNS perpendicular to SN ($p = 0.0205$), mx1-S parallel to SN ($p = 0.0012$), mx1-S perpendicular to SN ($p =$

0.00272), S-ANS parallel to SN ($p = 0.0015$), Mx-Md midline ($p = 0.0005$), and ratio ($p = 0.0362$) of T1, meaning changes due to surgery. However, there were no significant differences in measurements of T2 to T5 (Tables III and IV).

Discussion

There have been several reports regarding the skeletal stability of maxilla in class III patients.¹³⁻¹⁷ Skeletal stability following orthognathic surgery is generally better horizontally than vertically. Simultaneous superior repositioning of the maxilla and advancement of the mandible is commonly employed to correct excessive anterior face height combined with mandibular deficiency.¹⁸ In class III patients, although superior repositioning of the maxilla that significantly rotates the mandible in the closing direction should be done with caution, clockwise rotation of the palatal plane, which moves the anterior maxillary structures down, is an effective way to produce a reasonably stable correction of the anterior open bite.¹⁹ In this study, a satisfactory result was obtained in terms of stability following maxillary advanced surgery.

However, there has been no report regarding maxillary superior repositioning in patients with bimaxillary asymmetry. In the present study, lateral impaction on one side and slight lateral elongation on the other was used in most cases. Thus bony contact was kept on the impaction side, but it was difficult to keep such contact area on the elongation side. Therefore a curved osteotomy line was applied on the elongation side to obtain a larger area of bony contact. In fact, asymmetric movements of the maxilla were measured using Deviation side mx1 to Zy-Zy and Non-deviation side mx1 to Zy-Zy. However, elongation on the deviation side was not shown statistically

and decrease tendency was shown in both sides in both groups postoperatively. Elongation in one side might not keep postoperatively.

On the other hand, regarding mandibular osteotomy, IVRO is frequently selected in combination with Le Fort I osteotomy. After the maxilla is fixed in its new position, the mandibular osteotomies are performed. IVROs are preferred to SSROs because damage to the mandibular nerves is less frequent and there is less interference with the proximal segment when the mandible is rotated.²⁰

When the maxillary segment is moved and positioned after fracture, interference between the maxilla and the pterygoid process may occur in the pterygomaxillary region. The palatine artery also runs in the medial wall of the sinus, so that it may be difficult to trim the posterior part of the maxillary segment, including the medial wall of the sinus. Therefore artificial fracture of the pterygoid process is occasionally necessary, especially in the correction of the maxillary occlusal cant on frontal image.

A complete or partial maxillary setback can frequently induce an ideal profile, especially in cases of maxillary protrusion, retrognathism, or bimaxillary asymmetry. Furthermore, Japanese patients with prognathism or asymmetry tend to have comparatively lower noses than similar Caucasian patients. For example, in a case of asymmetry with an anteroposteriorly normal maxillary position, maxillary advancement may change the shape of the nose, so that it is not aesthetically acceptable. To avoid this, a Le Fort I osteotomy is used to change only the maxillary occlusal plane in the lateral or frontal view without maxillary advancement.

On the other hand, stability following occlusal cant correction, especially in patients with bimaxillary asymmetry, was unknown. From our results, the exact A

point, ANS, and PNS in the maxillary segment were moved superiorly immediately after surgery. Time-course changes after surgery were so small that occlusion could be regarded as remaining stable.

Analysis of posteroanterior cephalography can be used to measure dentofacial asymmetry and determine occlusal cant. A line was drawn connecting the most buccal points of the left and right maxillary first molars in this study. Standard posteroanterior cephalometric analyses do not include evaluation of the relationships of the occlusal plane to the horizontal. This represents an important deficiency, because leveling of the occlusal plane, when necessary, should be a goal of surgical and orthodontic therapy. However, occlusal cant alone is insufficient to evaluate asymmetry, so values of the Mx-Md midline and the ratio of mx1 to Zy-Zy were added for more accurate evaluation. In fact, in posteroanterior cephalometric analysis, there were no significant changes except for the intended change between preoperative and immediate postoperative values. However, the lack of differences may also be attributable to the fact that measurements on posteroanterior cephalography are more sensitive to minor differences in head position and are thus not as precise as measurements on lateral cephalography.

Our previous study has already proved that a slight tendency for vertical impaction after Le Fort I osteotomy both in combination with SSRO and IVRO with PLLA plates in the comparison between titanium group and PLLA group, although differences in time-course changes were not clinically apparent, and normal occlusion was established in all patients.²¹ PLLA plates were used in both groups in this study, so that this study could not be affected by fixation material. The comparison between

SSRO and IVRO was not performed in this study, because we wanted to know the maxillary change on frontal view following Le Fort I osteotomy. However, in the comparison in skeletal stability between SSRO alone and IVRO alone, IVRO group showed slight vertical decrease at the pogonion point, although SSRO group showed gradual increase in lateral cephalogram. Furthermore, no significant differences were identified in measurements on PA cephalography.²² These results suggested that the maxillary stability could not be affected by mandibular ramus osteotomy.

Conclusion

Our study suggests that maxillary stability after Le Fort I osteotomy for the correction of cant does not differ from that after Le Fort I osteotomy for maxillary advancement.

References

1. Proffit WR, Phillips C, Turvey TA. Stability following superior repositioning of the maxilla by Le Fort I osteotomy. *Am J Orthod Dentfac Orthop* 1987; 92: 151-161.
2. Bell WH. Le Fort I osteotomy for correction of maxillary deformities. *J Oral Surg* 1975; 33: 412-426.
3. Epker BN, Wolford LM. Middle third facial osteotomies. *J Oral Surg* 1975; 33: 491-514.
4. Ueki K, Nakagawa K, Marukawa K, Yamamoto E. Le Fort I osteotomy using ultrasonic bone curette to fracture the pterygoid plates. *J Cranio Maxillofac Surg* 2004; 32: 381-382.
5. Epker BN. Superior surgical repositioning of the maxilla: long term results. *J Maxillofac Surg* 1981; 9: 237-246.
6. Greebe RB, Tuinzing DB. Superior repositioning of the maxilla by a Le Fort I osteotomy: a review of 26 patients. *Oral Surg Oral Med Oral Pathol* 1987; 63: 158-161, 1987.
7. Hall HD, Roddy SC Jr. Treatment of maxillary alveolar hyperplasia by total maxillary alveolar osteotomy. *J Oral Surg* 1975; 33: 180-188.
8. Proffit WR, Turvey TA, Phillips C. Orthognathic surgery: a hierarchy of stability. *Int J Adult Orthod Orthognath Surg* 1996; 11: 191-204.
9. Schendel SA, Eisenfeld JH, Bell WH, Epker BN. Superior repositioning of the maxilla: stability and soft tissue osseous relations. *Am J Orthod* 1976; 70: 663-674.

10. West RA, McNeill RW. Maxillary alveolar hyperplasia diagnosis and treatment planning. *J Maxillofac Surg* 1975; 3: 239-250.
11. Wolford LM, Epker BN. The combined anterior and posterior maxillary osteotomy: a new technique. *J Oral Surg* 1975; 33: 842-851.
12. Ueki K, Nakagawa K, Takatsuka S, Shimada M, Marukawa K, Takazakura D, Yamamoto E. Temporomandibular joint morphology and disc position in skeletal class III patients. *J Cranio Maxillofac Surg* 2000; 28:362-8.
13. Franco JE, Van Sickels JE, Thrash WJ: Factors contributing to relapse in rigidly fixed mandibular setbacks. *J Oral Maxillofac Surg* 1989; 47:451-456.
14. Law JH, Rotskoff KS, Smith RJ: Stability following combined maxillary and mandibular osteotomies treated with rigid internal fixation. *J Oral Maxillofac Surg* 1989; 47: 128-136.
15. Proffit WR, Phillips C, Turvey TA: Stability after surgical-orthodontic corrective of skeletal Class III malocclusion. 3: Combined maxillary and mandibular procedures. *Int J Adult Orthod Orthognath Surg* 1991; 6: 211-215.
16. Costa F, Robiony M, Sembronio S, Polini F, Politi M: Stability of skeletal class III malocclusion after combined maxillary and mandibular procedures. *Int J Adult Orthod Orthognath Surg* 2001; 16: 179-192.
17. Kwon TG, Mori Y, Minami K, Lee SH, Sakuda M: Stability of simultaneous maxillary and mandibular osteotomy for treatment of class III malocclusion: An analysis of three-dimensional cephalograms. *J Craiomaxillofac Surg* 2000; 28:272-277.

18. Proffit WR. Treatment planning: the search for wisdom. In: Proffit WR, White RP Jr., eds. Surgical-orthodontic treatment. St. Louis: CV Mosby, 1990; 142-191.
19. Moldez MA, Sugawara J, Umemori M, Mitani H, Kawamura H. Long-term dentofacial stability after bimaxillary surgery in skeletal Class III open bite patients. *Oral Surg Oral Med Oral Pathol Oral Radiol Endod* 2000; 15: 309-319,.
20. Bell WH. Mandibular excess with vertical maxillary excess or deficiency. In: Bell WH, ed. Surgical correction of dentofacial deformities, New concepts Vol. III. Philadelphia: WB Saunders Company, 1985; 107-152.
21. Ueki K, Marukawa K, Shimada M, Nakagawa K, Alam S, Yamamoto E. Maxillary stability following Le Fort I osteotomy in combination with sagittal split ramus osteotomy and intraoral vertical ramus osteotomy: a comparative study between titanium miniplate and poly-L-lactic acid plate. *J Oral Maxillofac Surg* 2006 ;64:74-80.
22. Ueki K, Marukawa K, Shimada M, Nakagawa K, Yamamoto E. Change in condylar long axis and skeletal stability following sagittal split ramus osteotomy and intraoral vertical ramus osteotomy for mandibular prognathia. *J Oral Maxillofac Surg* 2005;63:1494-9.

Figure Legends

FIGURE 1. Coronal rotation. Maxillary height of the right side needed for impaction and that of the left side needed for elongation. At the same time, an intraoral vertical ramus osteotomy is performed to establish the ideal occlusion.

FIGURE 2. Measurements in the posteroanterior and lateral cephalograms.

TABLE 1. Results of cephalometric analysis in the Cant group. SD indicates standard deviation.

TABLE 2. Results of the cephalometric analysis in the Advance group. SD indicates standard deviation.

TABLE 3. Results of changes in each period in the Cant group. SD indicates standard deviation.

TABLE 4. Results of changes in each period in the Advance group. SD indicates standard deviation.

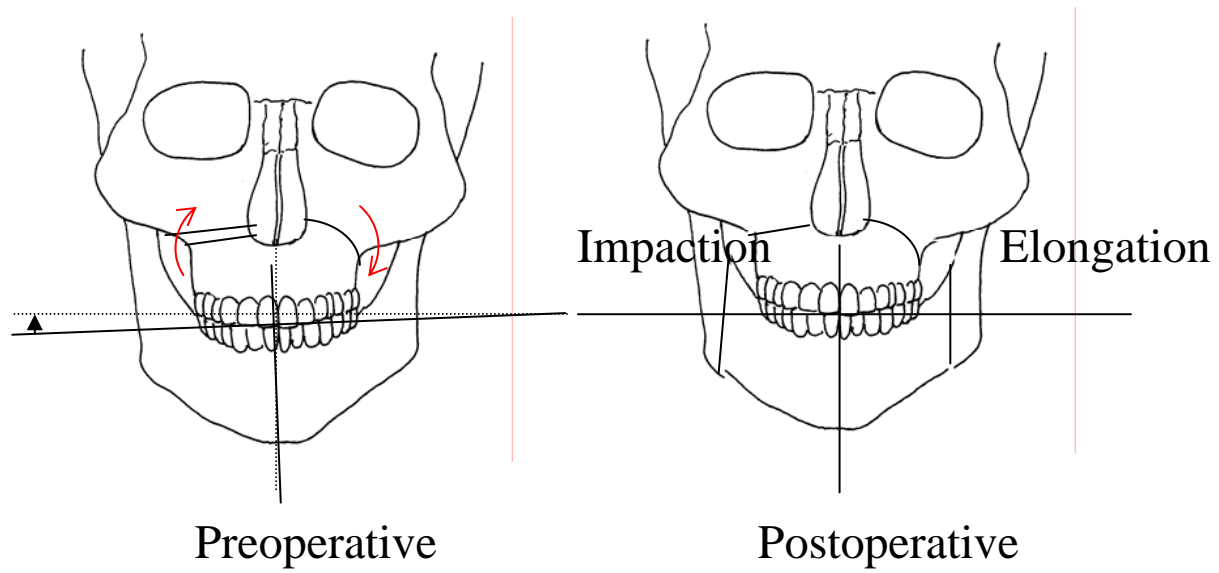


Fig. 1

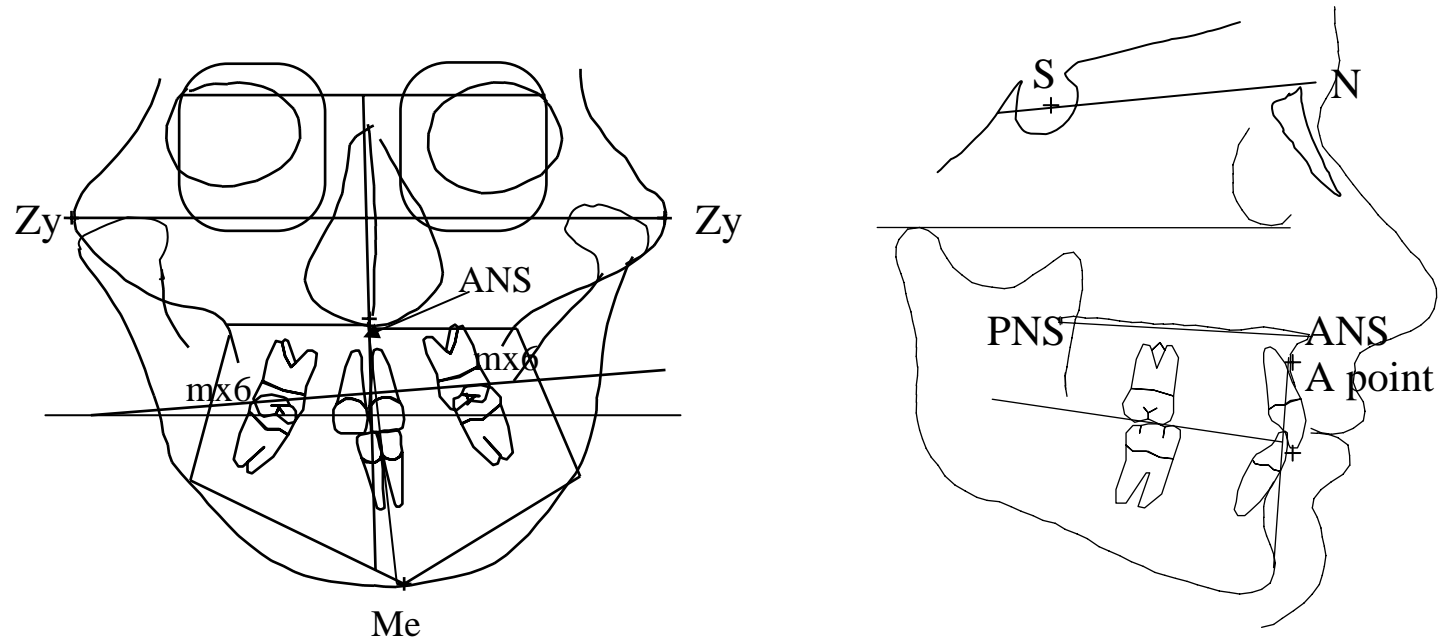


Fig.2

		initial	immediately after		1 month		3 months		6 months		1 year		
		Mean	SD	Mean	SD	Mean	SD	Mean	SD	Mean	SD	Mean	SD
Lateral													
SNA	(dg)	80.8	5.2	82.7	4.6	81.2	3.1	81.4	3.3	81.7	3.1	82.7	3.9
S-A parallel to SN	(mm)	55.7	6.1	56.8	5.6	55.8	4.1	56.0	4.7	55.6	4.7	56.0	4.7
S-A perpend SN	(mm)	61.0	3.7	58.3	4.2	58.0	4.0	57.2	4.6	56.6	4.0	55.6	4.3
S-PNS parallel to SN	(mm)	12.5	4.7	13.8	4.3	13.8	3.1	13.9	3.4	13.5	3.8	13.8	3.8
S-PNS perpend to SN	(mm)	47.6	2.6	44.0	3.2	44.2	2.3	44.5	3.0	43.8	2.4	43.0	2.8
mx1-S parallel to SN	(mm)	57.8	6.3	58.6	6.4	57.9	5.4	58.4	6.9	58.5	6.9	58.1	6.9
mx1-S perpend to SN	(mm)	65.2	2.8	64.1	2.5	64.6	3.4	63.8	4.1	63.2	3.3	62.3	3.3
S-ANS parallel to SN	(mm)	61.1	5.5	59.6	5.0	58.1	3.7	58.9	3.6	59.0	3.7	59.1	3.9
S-ANS perpend to SN	(mm)	54.8	3.5	52.2	3.9	51.9	3.6	52.1	4.1	51.3	4.0	50.2	4.0
Frontal													
Mx-Md Midline	(dg)	5.6	3.9	1.1	2.2	1.5	2.3	1.4	2.4	0.9	2.0	0.9	2.4
Deviation side mx6 to Zy-Zy	(mm)	49.6	5.8	45.4	5.3	44.7	5.1	43.9	5.0	42.1	5.7	42.9	6.5
Non-deviation side mx6 to Zy-Zy	(mm)	47.4	6.3	45.9	4.3	45.4	4.1	45.0	4.4	42.9	5.5	43.6	5.6
Ratio		0.96	0.04	1.02	0.06	1.02	0.07	1.03	0.07	1.02	0.06	1.02	0.05
Occlusal cant	(dg)	-2.3	2.1	0.7	2.4	0.9	3.7	1.4	3.2	1.2	2.8	0.9	2.7

Table 1.

		initial Mean	SD	immediately after Mean	SD	1 month Mean	SD	3 months Mean	SD	6 months Mean	SD	1 year Mean	SD
Lateral													
SNA	(dg)	79.9	3.8	83.1	4.0	82.3	3.4	83.3	3.8	82.7	3.9	82.6	4.0
S-A parallel to SN	(mm)	54.0	5.9	57.3	6.4	56.6	5.7	57.4	5.9	56.2	6.4	56.4	6.0
S-A perpend SN	(mm)	59.4	5.7	58.3	6.1	57.3	5.1	57.4	5.3	56.4	5.6	57.0	5.4
S-PNS parallel to SN	(mm)	13.4	3.9	16.0	3.6	16.4	4.4	15.9	4.4	15.4	3.9	15.7	3.6
S-PNS perpend to SN	(mm)	45.8	4.9	44.9	5.6	44.3	4.9	44.2	4.8	43.7	5.0	43.7	4.9
mx1-S parallel to SN	(mm)	56.2	7.8	60.2	8.0	60.2	7.0	60.7	7.7	59.6	8.1	59.5	7.7
mx1-S perpend to SN	(mm)	65.8	11.2	66.1	12.2	65.5	9.4	65.4	9.5	64.0	9.6	64.2	9.6
S-ANS parallel to SN	(mm)	58.4	6.0	61.2	7.2	60.0	5.5	60.5	6.0	59.7	6.3	59.7	5.8
S-ANS perpend to SN	(mm)	53.7	4.6	52.4	5.3	51.1	5.0	51.6	5.2	50.7	5.1	50.9	5.0
Frontal													
Mx-Md Midline	(dg)	2.0	2.3	0.7	1.8	0.6	1.5	1.0	1.7	1.2	1.9	1.2	1.9
Deviation side mx6 to Zy-Zy	(mm)	46.6	5.5	45.8	5.9	44.8	5.1	45.0	5.4	43.3	5.2	42.8	6.1
Non-deviation side mx6 to Zy-Zy	(mm)	46.9	6.0	46.6	6.0	45.5	6.2	45.4	5.5	44.3	5.5	43.9	6.1
Ratio		1.00	0.05	1.02	0.05	1.01	0.06	1.01	0.04	1.02	0.05	1.03	0.04
Occlusal cant	(dg)	-0.6	2.2	1.2	2.2	0.7	2.3	1.0	2.7	0.6	2.2	1.0	2.2

Table 2.

		T1 Mean	SD	T2 Mean	SD	T3 Mean	SD	T4 Mean	SD	T5 Mean	SD
Lateral											
SNA	(dg)	1.9	4.2	-1.5	4.3	0.2	3.6	0.4	1.5	1.0	1.7
S-A parallel to SN	(mm)	1.0	4.7	-1.0	4.4	0.2	3.9	-0.3	1.5	0.3	1.4
S-A perpend SN	(mm)	-2.7	4.6	-0.3	3.9	-0.7	2.9	-0.7	3.2	-1.0	2.3
S-PNS parallel to SN	(mm)	1.3	3.3	0.0	3.1	0.1	2.7	-0.3	2.0	0.3	1.0
S-PNS perpend to SN	(mm)	-3.5	3.8	0.2	2.0	0.3	1.4	-0.8	1.7	-0.8	1.5
mx1-S parallel to SN	(mm)	0.7	2.8	-0.6	3.3	0.5	4.1	0.1	2.1	-0.4	2.1
mx1-S perpend to SN	(mm)	-1.1	2.1	0.5	2.4	-0.8	2.4	-0.7	2.6	-0.9	1.4
S-ANS parallel to SN	(mm)	-1.5	4.3	-1.5	3.7	0.7	3.5	0.2	2.2	0.1	1.8
S-ANS perpend to SN	(mm)	-2.5	4.2	-0.3	3.3	0.1	2.7	-0.7	3.1	-1.2	2.2
Frontal											
Mx-Md Midline	(dg)	-4.5	3.2	0.4	1.7	-0.1	1.6	-0.5	1.9	0.1	1.9
Deviation side mx6 to Zy-Zy	(mm)	-4.2	7.9	-0.7	4.6	-0.8	3.5	-1.8	5.4	0.9	6.4
Non-deviation side mx6 to Zy-Zy	(mm)	-1.4	7.5	-0.5	4.9	-0.4	4.2	-2.1	5.1	0.7	5.4
Ratio		0.06	0.07	0.00	0.05	0.01	0.05	-0.01	0.05	0.00	0.04
Occlusal cant	(dg)	3.0	3.0	0.2	2.6	0.5	2.4	-0.1	2.7	-0.3	1.2

Table 3.

		T1 Mean	SD	T2 Mean	SD	T3 Mean	SD	T4 Mean	SD	T5 Mean	SD
Lateral											
SNA	(dg)	3.2	2.9	-0.8	2.5	1.0	2.0	-0.6	1.5	-0.1	1.8
S-A parallel to SN	(mm)	3.3	2.8	-0.8	2.1	0.8	2.1	-1.2	1.4	0.2	1.1
S-A perpend SN	(mm)	-1.0	3.8	-1.0	2.8	0.1	2.2	-0.9	2.6	0.5	3.3
S-PNS parallel to SN	(mm)	2.6	2.5	0.5	2.4	-0.6	2.4	-0.5	2.9	0.3	1.5
S-PNS perpend to SN	(mm)	-1.0	2.8	-0.6	2.0	-0.1	1.4	-0.5	1.3	0.0	1.7
mx1-S parallel to SN	(mm)	3.9	3.0	0.0	2.8	0.6	2.3	-1.2	2.4	-0.1	1.5
mx1-S perpend to SN	(mm)	0.3	1.9	-0.6	3.3	-0.1	1.7	-1.4	1.9	0.2	2.2
S-ANS parallel to SN	(mm)	2.8	3.7	-1.2	3.6	0.6	2.2	-0.8	2.1	-0.1	2.3
S-ANS perpend to SN	(mm)	-1.3	3.1	-1.3	2.9	0.4	2.6	-0.9	3.1	0.2	3.3
Frontal											
Mx-Md Midline	(dg)	-1.3	2.0	-0.1	1.7	0.4	1.6	0.3	1.8	0.0	0.4
Deviation side mx6 to Zy-Zy	(mm)	-0.9	5.2	-1.0	4.1	0.2	1.4	-1.6	2.8	-0.6	4.0
Non-deviation side mx6 to Zy-Zy	(mm)	-0.2	4.4	-1.2	4.7	-0.1	2.7	-1.1	2.4	-0.4	3.9
Ratio		0.02	0.07	-0.01	0.05	0.00	0.04	0.01	0.04	0.01	0.04
Occlusal cant	(dg)	1.8	2.8	-0.6	2.0	0.4	2.7	-0.4	1.6	0.4	1.1

Table 4.