

Alu-mediated large deletion of the CDSN gene as a cause of peeling skin disease

著者	Wada Taizo, Matsuda Yusuke, Muraoka Masahiro, Toma Tomoko, Takehara Kazuhiko, Fujimoto Manabu, Yachie Akihiro
journal or publication title	Clinical Genetics
volume	xx
number	xx
page range	xxxx-xxxx
year	2014-01-01
URL	http://hdl.handle.net/2297/36276

doi: 10.1111/cge.12294

Alu-mediated large deletion of the CDSN gene as a cause of peeling skin disease

Taizo Wada,^a Yusuke Matsuda,^a Masahiro Muraoka,^a Tomoko Toma,^a Kazuhiko Takehara,^b Manabu Fujimoto,^b and Akihiro Yachie^a

Institutional affiliations:

^aDepartment of Pediatrics and ^bDepartment of Dermatology, School of Medicine, Institute of Medical, Pharmaceutical and Health Sciences, Kanazawa University, Kanazawa, Japan.

Correspondence to: Taizo Wada, MD, PhD

Department of Pediatrics, School of Medicine,
Institute of Medical, Pharmaceutical and Health Sciences,
Kanazawa University
13-1 Takaramachi, Kanazawa 920-8641, Japan
Phone: +81-76-265-2313
Fax: +81-76-262-1866
E-mail: taizo@staff.kanazawa-u.ac.jp

Conflict of interest statement:

None of the authors has any potential financial conflict of interest.

Acknowledgments:

We thank Dr. Tsutomu Oh-ishi for array CGH analysis, Ms. Harumi Matsukawa and Ms. Shizu Kouraba for their excellent technical assistance. This work was supported by a Grant-in-Aid for Scientific Research from the Ministry of Education, Culture, Sports, Science and Technology of Japan; and a grant from the Ministry of Health, Labour, and Welfare of Japan, Tokyo.

Abstract

Peeling skin disease (PSD) is an autosomal recessive skin disorder caused by mutations in *CDSN* and is characterized by superficial peeling of the upper epidermis. Corneodesmosin (CDSN) is a major component of corneodesmosomes that plays an important role in maintaining epidermis integrity. Herein, we report a patient with PSD caused by a novel homozygous large deletion in the 6p21.3 region encompassing the *CDSN* gene, which abrogates CDSN expression. Several genes including *C6orf15*, *PSORS1C1*, *PSORS1C2*, *CCHCR1*, and *TCF19* were also deleted, however, the patient showed only clinical features typical of PSD. The deletion size was 59.1 kb. Analysis of the sequence surrounding the breakpoint showed that both of the telomeric and centromeric breakpoints existed within Alu-S sequences that were oriented in opposite directions. These results suggest an Alu-mediated recombination event as the mechanism underlying the deletion in our patient.

Keywords: Alu, CDSN, deletion, peeling skin disease, recombination.

Introduction

Peeling skin disease (PSD), a generalized inflammatory form of peeling skin syndrome, is an autosomal recessive skin disorder caused by mutations in *CDSN* and is

characterized by superficial peeling of the upper epidermis (1, 2). Patients with PDS have been reported to carry nonsense or frameshift mutations resulting in complete loss of expression of corneodesmosin (CDSN), a major component of corneodesmosomes that plays an important role in maintaining epidermis integrity. Herein, we report a patient with PDS caused by a novel homozygous large deletion in the 6p21.3 region encompassing *CDSN*.

Material and methods

Patient report

A 3-week-old Japanese girl from non-consanguineous parents was hospitalized for severe skin anomalies, hypereosinophilia (6,075/ μ L), and hypoproteinemia (Fig. 1A-C). Serum IgE levels were slightly elevated at 51 IU/L, and allergen-specific IgE were all negative. Thereafter the patient developed IgE-mediated fish allergy. She is now 16 years of age and has suffered from frequent episodes of widespread patchy peeling and erythema (Fig. 1D). Serum IgE levels were significantly elevated (14,940 IU/L) with high allergen-specific IgE against multiple inhalant and food allergens with age: class 5 for house dust mite; class 4 for kiwi fruit; class 3 for cow's milk, egg white, shrimp, oyster, codfish and flounder; and class 2 for crab.

Mutation, array comparative genomic hybridization (CGH) and breakpoint analysis

DNA was extracted from blood samples using a standard method. The *CDSN* gene was amplified from genomic DNA using specific primers (2). Array CGH and breakpoint analysis were performed as described previously (3).

Results

The lack of expression of *CDSN* protein in her skin biopsy (Fig. 1E, F) and amplification of any *CDSN* sequences from her DNA prompted us to perform array comparative genomic hybridization (CGH) analysis (Fig. 2A). We were able to clearly demonstrate a region of continuously reduced copy number around 6p21.3, in which *CDSN* was located. There were no significant copy number alterations in other parts of the patient's genome. Direct sequencing analysis of the breakpoint PCR products demonstrated that the breakpoints were chr6:31,069,672 and chr6:31,128,857. The deletion size was 59.1 kb. The centromeric breakpoint was located within intron 2 of *TCF19*. More importantly, Alu sequences were found to be involved in the deletion (Fig. 2B, C).

Discussion

Repetitive Alu sequences are widely distributed and important for insertional mutagenesis and recombination events in a variety of human genetic disorders (4).

Unequal homologous recombination may occur between two Alu sequences oriented in the same direction, resulting in duplications, deletions and translocations. In fact, around 0.3% of all human genomic diseases have been reported to likely result from Alu-mediated unequal homologous recombination. However, in our patient, the two Alu sequences responsible for the deletion were oriented in opposite directions (Fig. 2B, C). Although Alu sequences inserted in the opposite directions have been found to be more prone to illegitimate recombination when they are less than 20 bp apart from each other (5), there have been rare reports of observations similar to ours. In addition, studies of comparative analysis of the chimpanzee and human genomes have demonstrated the uncommonness of this type of Alu-mediated deletion (6). Analysis of the junction sequence allowed us to postulate that non-homologous end joining (NHEJ) is the most likely mechanism responsible for the deletion. Further investigations are necessary to assess how Alu sequences oriented opposite directions would contribute to recombination-mediated damage to the human genome.

Mutations in the *CDSN* gene in humans have been originally identified in patients with autosomal dominant hypotrichosis simplex of the scalp (HSS) (7). To date, all mutations responsible for HSS have been reported to be heterozygous nonsense mutations, namely p.Gln200X, p.Gln209X, p.Gln215X and p.Tyr239X, all of which lead to truncated CDSN proteins. Aggregates formed by the dominant negative effect of mutated CDSN may be toxic to the hair follicle cells resulting in HSS (7-10). In contrast, genetic defects in patients with PDS have been shown to be homozygous nonsense (p.Lys59X) or frameshift mutations leading to complete loss of CDSN expression (2, 11-13). Consistent with these findings, our patient carrying the homozygous deletion mutation exhibited no

protein expression of *CDSN*, and the parents and brother, who were heterozygous carrier (Fig. 2D), did not show any abnormalities in the hair and skin. No products were amplified by the breakpoint PCR from 130 alleles of ethnically-matched healthy controls. However, because of the non-consanguinity in the parents, genotyping studies using larger number of samples will be required to assess whether the deletion allele could have a significant frequency in the Japanese population.

In addition to *CDSN*, there were several other genes involved in the deletion in our patient: *C6orf15*, *PSORS1C1*, *PSORS1C2*, *CCHCR1*, and *TCF19*. Most of them have been reported to be associated with increased risk of psoriasis. However, the precise roles of these genes in psoriasis susceptibility, as well as their physiological roles, remain to be determined. It is also known that genetic variations of *CCHCR1* are likely related to cervical epithelial cell transformation and nevirapine-induced rash in addition to psoriasis, none of which has been observed in our patient. On the other hand, no human disease has been reported to be associated with defective expression of these genes. Accordingly, our patient showed clinical features typical of PDS but no unexplained symptoms that could be related to other deleted genes.

Absence of *CDSN* protein leads to defects in the epidermal barrier, resulting in predisposition towards atopic dermatitis. Netherton syndrome is a rare dermatosis caused by mutations in *SPINK5*, encoding LEKTI, which is involved in the degradation of *CDSN*. Therefore, PDS, Netherton syndrome and atopic dermatitis may show clinical overlap between each other, especially in childhood. In fact, our patient was initially diagnosed with Netherton syndrome-like condition. Interestingly, marked eosinophilia was demonstrated at the onset in the patient, which probably resulted from the presence

of intense systemic allergic inflammation, i.e., severe atopic dermatitis. Serum IgE levels and allergen-specific IgE against multiple allergens increased dramatically with age. These results further suggest the importance of maintaining skin barrier function in the environment to prevent the subsequent development of allergic diseases after birth.

In summary, our studies identified the novel homozygous large deletion encompassing *CDSN* as an additional type of mutation in PDS, and demonstrated its genomic mechanism to be Alu-mediated recombination.

References

1. Jonca N, Leclerc EA, Caubet C et al. Corneodesmosomes and corneodesmosin: from the stratum corneum cohesion to the pathophysiology of genodermatoses. *Eur J Dermatol* 2011; 21 Suppl 2: 35-42.
2. Oji V, Eckl KM, Aufenvenne K et al. Loss of corneodesmosin leads to severe skin barrier defect, pruritus, and atopy: unraveling the peeling skin disease. *Am J Hum Genet* 2010; 87: 274-281.
3. Yamada M, Arai T, Oishi T et al. Determination of the deletion breakpoints in two patients with contiguous gene syndrome encompassing *CYBB* gene. *Eur J Med Genet* 2010; 53: 383-388.
4. Batzer MA, Deininger PL. Alu repeats and human genomic diversity. *Nat Rev Genet* 2002; 3: 370-379.

5. Lobachev KS, Stenger JE, Kozyreva OG et al. Inverted Alu repeats unstable in yeast are excluded from the human genome. *Embo J* 2000; 19: 3822-3830.
6. Han K, Lee J, Meyer TJ et al. Alu recombination-mediated structural deletions in the chimpanzee genome. *PLoS Genet* 2007; 3: 1939-1949.
7. Levy-Nissenbaum E, Betz RC, Frydman M et al. Hypotrichosis simplex of the scalp is associated with nonsense mutations in CDSN encoding corneodesmosin. *Nat Genet* 2003; 34: 151-153.
8. Davalos NO, Garcia-Vargas A, Pforr J et al. A non-sense mutation in the corneodesmosin gene in a Mexican family with hypotrichosis simplex of the scalp. *Br J Dermatol* 2005; 153: 1216-1219.
9. Caubet C, Bousset L, Clemmensen O et al. A new amyloidosis caused by fibrillar aggregates of mutated corneodesmosin. *Faseb J* 2010; 24: 3416-3426.
10. Yang SX, Yin JH, Lin ZM et al. A novel nonsense mutation in the CDSN gene underlying hypotrichosis simplex of the scalp in a Chinese family. *Clin Exp Dermatol* 2013.
11. Mazereeuw-Hautier J, Leclerc EA, Simon M et al. A novel mutation in CDSN causes peeling skin disease in a patient from Morocco. *Br J Dermatol* 2011; 165: 1152-1155.
12. Israeli S, Zamir H, Sarig O et al. Inflammatory peeling skin syndrome caused by a mutation in CDSN encoding corneodesmosin. *J Invest Dermatol* 2011; 131: 779-781.
13. Telem DF, Israeli S, Sarig O et al. Inflammatory peeling skin syndrome caused a novel mutation in CDSN. *Arch Dermatol Res* 2012; 304: 251-255.

Figure Legends

Fig. 1. Characterization of the skin lesions.

(A) Superficial peeling and ichthyosiform erythroderma at 1 month of age. (B, C) Hematoxylin and eosin staining of the skin biopsy specimen, original magnification x40 and x100. Extensive detachment of the stratum corneum, hyperkeratosis, parakeratosis, and eosinophilic infiltration were shown in the epidermis. (D) Extensive peeling of the skin and erythema over the forearms at 16 years of age. (E, F) Immunohistochemistry. The skin biopsy specimens were stained with anti-corneodesmosin antibody (Atlas antibodies, Stockholm, Sweden). A specimen from a normal control showed positive staining in the granular layers (E), whereas corneodesmosin was not detectable in the patient's specimen (F). Bars indicate 100 μm for B and 50 μm for C, E and F.

Fig. 2. Characterization of the deletion mutation and the breakpoint.

(A) Analysis of the array comparative genomic hybridization. The red band indicates the region of continuously reduced copy number in the 6p21.3 region. (B) Schematic representation of the deletion and the Alu sequences involved in the recombination. The telomeric breakpoint was intergenic between *MUC22* and *C6orf15* loci, and the centromeric breakpoint was located within intron of *TCF19*. Both breakpoints existed within Alu sequences, which were oriented in opposite directions. Arrows indicate Alu sequences. Boxes represent exons of the *TCF19* gene, and shaded areas represent the coding regions. Numbering according to NC_000006.11. (C) Sequences surrounding the junction alongside the reference sequences of Alu-Sc and Alu-Sg. All sequences are

shown in 5' to 3' direction. Microhomologies are underlined. (D) Carrier status of the family members. PCR amplification for *CDSN* and the breakpoint were shown.

Amplified products were obtained from both PCR reactions for each DNA sample from the patient's father, mother and younger brother, indicating that they were heterozygous carriers. No amplified products were obtained from control DNA due to the absence of the deletion. Marker lanes contain 100-bp (top) and 1-kb (bottom) molecular size markers.

Fig. 1

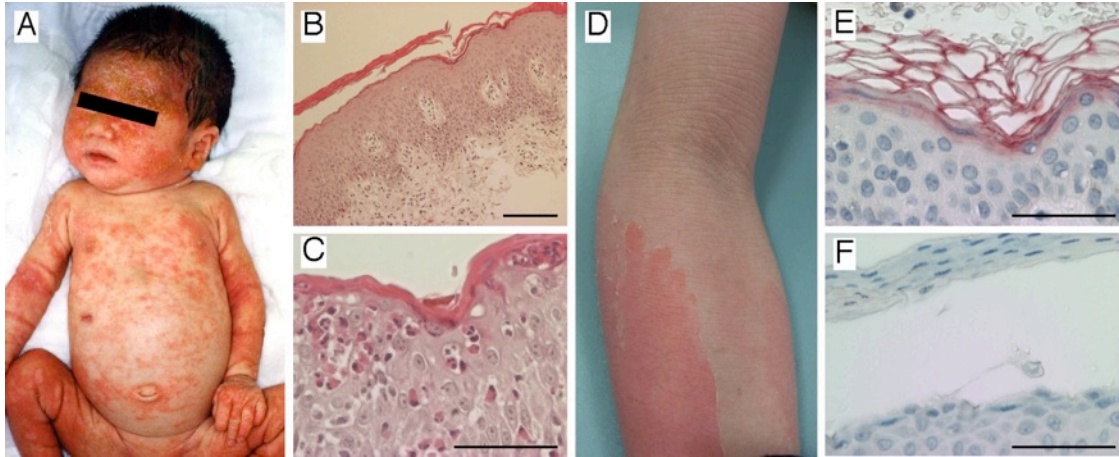


Fig.2

