

# Endoscopic removal of subgaleal hematoma in a 7-year-old patient treated with anticoagulant and antiplatelet agents

著者	Hayashi Yasuhiko, Kita Daisuke, Furuta Takuya, Oishi Masahiro, Hamada Jun-ichiro
journal or publication title	Surgical Neurology International
volume	5
page range	134911
year	2014-01-01
URL	<a href="http://hdl.handle.net/2297/40600">http://hdl.handle.net/2297/40600</a>

doi: 10.4103/2152-7806.134911

## Case Report

# Endoscopic removal of subgaleal hematoma in a 7-year-old patient treated with anticoagulant and antiplatelet agents

Yasuhiko Hayashi, Daisuke Kita, Takuya Furuta, Masahiro Oishi, Jun-ichiro Hamada

Department of Neurosurgery, Kanazawa University, Ishikawa, 13-1, Takara-machi, Kanazawa, 920-8641, Japan

E-mail: \*Yasuhiko Hayashi - [yahayashi@med.kanazawa-u.ac.jp](mailto:yahayashi@med.kanazawa-u.ac.jp); Daisuke Kita - [kitad@med.kanazawa-u.ac.jp](mailto:kitad@med.kanazawa-u.ac.jp); Takuya Furuta - [tfuruta@med.kanazawa-u.ac.jp](mailto:tfuruta@med.kanazawa-u.ac.jp); Masahiro Oishi - [ma-oishi@med.kanazawa-u.ac.jp](mailto:ma-oishi@med.kanazawa-u.ac.jp); Jun-ichiro Hamada - [jhamada@med.kanazawa-u.ac.jp](mailto:jhamada@med.kanazawa-u.ac.jp)

\*Corresponding author

Received: 16 January 14 Accepted: 16 April 14 Published: 20 June 14

**This article may be cited as:**Hayashi Y, Kita D, Furuta T, Oishi M, Hamada J. Endoscopic removal of subgaleal hematoma in a 7-year-old patient treated with anticoagulant and antiplatelet agents. *Surg Neurol Int* 2014;5:98.Available FREE in open access from: <http://www.surgicalneurologyint.com/text.asp?2014/5/1/98/134911>

Copyright: © 2014 Hayashi Y. This is an open-access article distributed under the terms of the Creative Commons Attribution License, which permits unrestricted use, distribution, and reproduction in any medium, provided the original author and source are credited.

## Abstract

**Background:** Subgaleal hematomas frequently occur in children after head trauma and extend over the cranial sutures. Although conservative treatment suffices in most cases, surgical removal of a subgaleal hematoma is indicated when the patient presents with anemia and headache associated with its progressive enlargement.

**Case Description:** We present the case of a 7-year-old boy who was medicated with warfarin and aspirin due to a hypoplastic left ventricle and fell from a rock wherein he hit his head in the frontal region. Although a computed tomography scan of the head revealed no intracranial lesion, an extracranial hematoma was found to extend over the cranial sutures, leading to the diagnosis of subgaleal hematoma. The hematoma continued to grow gradually despite the cessation of warfarin and aspirin therapy immediately after the head trauma. Since the patient's headache and anemia were progressing as the hematoma enlarged, removal of the hematoma was performed 3 days after admission. Endoscopic hematoma removal was planned to enable accurate coagulation of the sites of bleeding and removal of the maximal amount of hematoma through minimal incision. The hematoma was completely removed, and the patient's postoperative course was excellent with alleviation of both the anemia and the headache. No sign of hematoma recurrence could be detected during 2 years follow-up.

**Conclusion:** An angled endoscope can allow visualization of the deep subgaleal space, and this technique enabled direct visualization of the bleeding sites and accurate coagulation to prevent recurrence of hematoma. Endoscopic techniques, such as minimally invasive techniques, can allow sufficient removal of subgaleal hematoma with minimal morbidity, especially in patients such as ours.

**Key Words:** Anticoagulant agent, endoscope, removal, subgaleal hematoma

**Access this article online****Website:**[www.surgicalneurologyint.com](http://www.surgicalneurologyint.com)**DOI:**

10.4103/2152-7806.134911

**Quick Response Code:**

## INTRODUCTION

Subgaleal hematomas, defined as hematomas extending over the cranial sutures, frequently arise in children after head trauma. In most cases, conservative treatment is the preferred option because adhesion between the galea

aponeurotica and the periosteum restricts the extent of the hematoma. In special cases, however, the hematoma enlarges extraordinarily past these adhesions, and the patients thus affected suffer from progressive anemia followed by the lethargy and headache resulting from the excessive distension of the skin and the subcutaneous

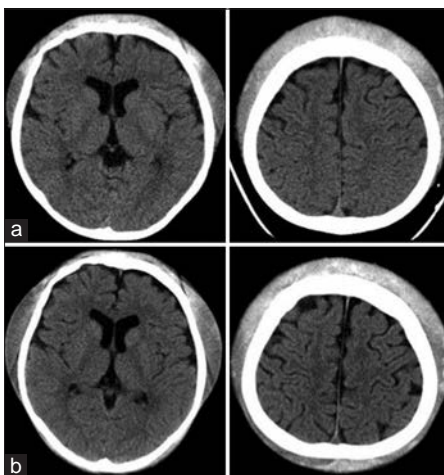
tissue. In such cases, hematoma removal is performed in order to relieve the symptoms.<sup>[1]</sup>

In our case, a 7-year-old boy medicated with warfarin and aspirin suffered from a giant and growing subgaleal hematoma, and endoscopic removal of the hematoma was performed with an excellent clinical outcome. The possibility of adequately removing such giant subgaleal hematomas via endoscope is discussed.

## CASE REPORT

A 7-year-old boy who was medicated with warfarin and aspirin due to a hypoplastic left ventricle fell from a rock with a height of 3 m and hit his head in the frontal region. He became stuporous and was transferred to a local hospital. Neurological examination revealed mild disturbance of consciousness without any focal deficits. Physical examination demonstrated the frontal region to be remarkably swollen. The swelling was soft and extremely tender. Computed tomography (CT) scan showed an extensive subcutaneous hematoma over the cranial sutures, indicating subgaleal hematoma without intracranial lesions. Conservative treatment including cessation of the warfarin and aspirin therapy was instituted. Rapid neutralization with a vitamin K2 agent was not performed because the patient's prothrombin time-international normalized ratio (PT-INR) of 1.44 and 5-min bleeding time at admission were not remarkably outside the normal range.

However, the subgaleal hematoma gradually grew to surround the anterior part of the cranial vault in spite of compression with bandage to the head [Figure 1]. The patient's head circumference and anemia also progressed leading to worsening of his headache and lethargy [Table 1]. The headache was attributed to



**Figure 1:** (a) Computed tomography (CT) scan showing the presence of a subgaleal hematoma in the frontal region upon admission. (b) The subgaleal hematoma gradually enlarged in the posterior direction and the patient's symptoms worsened in tandem

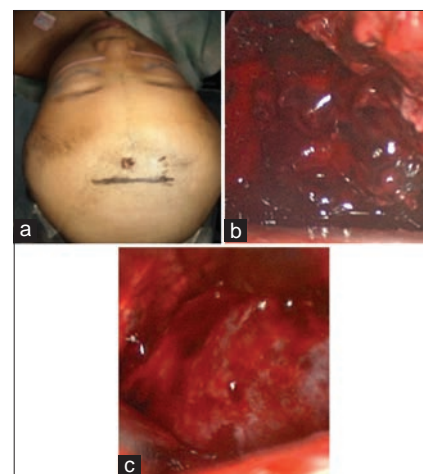
the stretching of the cutaneous and subcutaneous tissue. Therefore, surgical removal of the hematoma was planned. An endoscope was used to avoid a long skin incision and to allow efficient removal of the hematoma under direct visualization. The bleeding time before surgery was 4 min, which was not dangerously prolonged.

The patient was placed in a supine position under general anesthesia. A local anesthetic agent was infiltrated at the midline of the planned entry site to reach the subgaleal hematoma. A skin incision approximately 2 cm long was made along the hairline and used to introduce the endoscope and the surgical instruments [Figure 2a]. The subgaleal hematoma around the entry site was removed with aspiration and a spatula to allow advancement of a 30° angled rigid endoscope (Karl Storz, Germany) in the working space left by hematoma removal [Figure 2b]. Several sites of bleeding in the subgaleal space could be found and coagulated during the procedure, and the oozing from the surrounding subcutaneous tissue was controlled without difficulty to allow the almost complete removal of the hematoma [Figure 3].

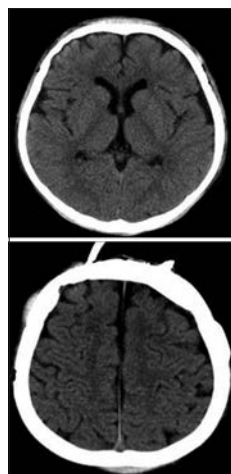
The patient's postoperative course was uneventful. His headache diminished immediately and the anemia also began to resolve within a week. No sign of recurrence could be found during 2 years follow-up after the resumption of warfarin and aspirin therapy.

## DISCUSSION

Subgaleal hematomas frequently occur in children after head trauma and extend over the cranial sutures. Although conservative treatment suffices in most cases,



**Figure 2:** (a) Preoperative photograph of the skin incision for the removal of the subgaleal hematoma, located just behind the hairline. (b) Intraoperative photograph showing the endoscopic view of the hematoma removal. (c) After removal of the hematoma, the galea was exposed above the periosteum



**Figure 3: Postoperative CT scan revealing the complete absence of the subgaleal hematoma**

surgical removal can be considered, if the growth of the hematoma causes symptoms such as headache and anemia. In our case, the hematoma gradually grew and led to progress symptoms in spite of less invasive compression with bandages for 2 days, therefore, removal of hematoma was performed. Some authors have reported that although subgaleal hematomas in patients with coagulopathy tend to be as large as intracerebral hematomas, surgical removal of the hematoma results in an excellent outcome.<sup>[1]</sup> However, when an extensive skin incision is made to allow sufficient removal of the hematoma, it can be difficult to coagulate the multiple sources of bleeding and oozing. Although the patient had previously been treated with warfarin and aspirin for his cardiac disease, his PT-INR and bleeding time were not far outside the normal range; therefore, neutralization with vitamin K2 agent was not performed preoperatively. Another problem in the treatment of subgaleal hematomas is postoperative recurrence in patients with coagulopathy.

In our case, we planned surgical removal of the subgaleal hematoma with a rigid endoscope. The advantages of the endoscope were considered to be as follows: First, it did not require an extensive skin incision. Second, removal of the part of the hematoma near the incision created the working space for the endoscope, which could then be advanced deeper into the subcutaneous space. The rigid endoscope was also used as a retractor to pull up the skin stretched by the subgaleal hematoma. Third, an angled endoscope can allow clear visualization of the deep subgaleal space. Fourth, this technique enabled direct visualization of the sites of bleeding and accurate coagulation thereof to prevent recurrence of hematoma in the subgaleal space.

Chater-Cure and colleagues have described the endoscopy-assisted removal of periorbital inclusion cysts in children. They also used a small incision behind the hairline in the child's forehead and advanced the rigid endoscope through the subgaleal plane.<sup>[2]</sup> In our case, the subgaleal hematoma had already dissected the subgaleal

**Table 1: Daily changes in the perioperative patient's hemoglobin, hematocrit, prothrombin time-international normalized ration, fibrinogen level, and head circumference**

	Pre-ope	Day 0	Day 2	Day 3	Day 10
Hb	13	11.7	8.6	10.2	11.1
Ht	38.6	34.8	25.3	29.6	35.5
PT-INR	1.5	1.44	1.42	1.32	1.57
HC		56	57.4	54.2	54
Fibrinogen	192		176		275
			OPE		
			Transfusion		

HC: Head circumference, PT-INR: Prothrombin time-international normalized ration, OPE: Operation

plane. Therefore, the working space for the endoscope was created as the hematoma was removed. Postoperative CT revealed complete removal of the hematoma, surpassing our preoperative expectations. Other authors have also reported endoscopy-assisted techniques for removing subperiosteal dermoid cysts in the periorbital area via a skin incision behind the hairline.<sup>[3-6]</sup> However, the use of this technique for the removal of large or giant subgaleal hematomas has not been previously reported.

The limitations of this procedure are the techniques available to control the bleeding and the possibility that the consistency of the hematoma will preclude aspiration in the deeper subgaleal space. If the bleeding appears to come from many sites that are difficult to coagulate, conversion from endoscopic to open surgery should be considered.<sup>[2,3,6]</sup>

## CONCLUSION

Endoscopic techniques have been advanced along with the recent trend toward invasive neurosurgery. These minimally invasive techniques can allow sufficient removal of subgaleal hematoma with minimal morbidity, especially in patients such as ours. In addition, the utility of endoscopic techniques for the removal of subgaleal hematoma should be confirmed after long-term follow-up.

## REFERENCES

1. Amar AP, Aryan HE, Meltzer HS, Levy ML. Neonatal subgaleal hematoma causing brain compression: Report of two cases and review of the literature. *Neurosurgery* 2003;52:1470-4.
2. Chater-Cure G, Hoffman C, Knopman J, Rhee S, Souweidane MM. Endoscopy-assisted removal of periorbital inclusion cysts in children. *J Neurosurg Pediatr* 2011;7:161-4.
3. Guerrissi JO. Endoscopic excision of frontozygomatic dermoid cysts. *J Craniofac Surg* 2004;15:618-22.
4. Papay FA, Stein JM, Dietz JR, Luciano M, Morales L Jr, Zins J. Endoscopic approach for benign tumors in the forehead and brow. *J Craniofac Surg* 1997;8:176-80.
5. Rosati M. Endoscopic treatment of dermoid cyst. *Ann N Y Acad Sci* 1994;734:455-9.
6. Senchenkov A, Clay RP. Endoscopic removal of the dermoid cysts of the eyebrow in pediatric patients. *Ann Plast Surg* 2005;55:595-8.