

The culdotomy two U procedure for vaginal ovarian cystectomy

著者	Tanaka Masaaki, Sagawa Tetsuya, Hashimoto Manabu, Mizumoto Yasunari, Yamazaki Rena, Myojo Subaru, Inoue Masaki
journal or publication title	Surgical Innovation
volume	18
number	2
page range	114-118
year	2011-06-01
URL	http://hdl.handle.net/2297/28501

doi: 10.1177/1553350610397213

M Tanaka Culdotomy with ultrasound and umbrella page 1

1 The Culdotomy Two U Procedure for Vaginal Ovarian Cystectomy

2

3

4 Masaaki Tanaka^a, MD, PhD, Tetsuya Sagawa^b, MD, Manabu Hashimoto^a, MD, PhD,

5 Yasunari Mizumoto^a, MD, PhD, Rena Yamazaki^a, MD, Subaru Myojo^a MD, PhD, and

6 Masaki Inoue^a, MD, PhD

7

8

9 ^aDepartment of Obstetrics and Gynecology, Kanazawa University,

10 School of Medicine, 13-1, Takaramachi, Kanazawa, Ishikawa 920-8641, Japan

11 ^bSagawa Clinic, 1-308, Kamiaraya, Kanazawa, Ishikawa 920-8065, Japan

12

13

14 Correspondence to: Masaaki Tanaka, MD, PhD

15 Department of Obstetrics and Gynecology, Kanazawa University,

16 School of Medicine, 13-1, Takaramachi, Kanazawa, Ishikawa 920-8641, Japan

17 E-mail: masaaki@med.kanazawa-u.ac.jp

18 Tel: +81-76-265-2425, Fax: +81-76-234-4266

19

20

M Tanaka Culdotomy with ultrasound and umbrella page 2

21 **Abstract**

22 When transvaginal removal of ovarian cysts is performed successfully, the procedure
23 compares favorably with laparoscopy in terms of invasiveness. However, the approach
24 into peritoneal cavity has been laborious. The objective was to evaluate feasibility of
25 an ultrasound-guided culdotomy using a newly-developed umbrella needle. New
26 culdotomy was performed on 36 patients with ovarian cysts. Each cyst was directly
27 punctured by the needle from vagina under ultrasound guidance. The vaginal walls on
28 both sides of the needle were incised with an electric scalpel. Through wound, cyst
29 was exteriorized and enucleated. Preoperative characteristics of patients, outcome,
30 operating time, blood loss, complications, and cyst histology were analyzed.
31 Culdotomy was performed successfully in all cases. Operating time was less than 10
32 minutes and blood loss was less than 10 ml. There were no culdotomy-associated
33 complications. Culdotomy assisted by ultrasound imaging and an umbrella needle is a
34 simple, safe, and reliable method for vaginal ovarian cystectomy.

M Tanaka Culdotomy with ultrasound and umbrella page 3

35 **Introduction**

36 Since the establishment of minimally invasive surgery with the introduction of
37 laparoscopy, new procedures following this concept have been developed. Natural
38 orifice transluminal endoscopic surgery (NOTES) has become an area of great
39 interest.^{1,2} In NOTES, natural orifices such as the mouth, anus, urethra, and vagina are
40 used as ports of entry into the peritoneal cavity through which the flexible endoscopic
41 devices are passed. Although NOTES currently has unresolved issues, the elimination
42 of an abdominal incision is expected to result in the less invasive surgery. Among
43 natural orifices, the transvaginal route is considered to be the most promising for the
44 peritoneal cavity access.³

45 In the gynecological arena, the use of the vaginal route for the removal of ovarian
46 cysts is currently being reevaluated.⁴⁻⁷ In laparoscopically assisted vaginal ovarian
47 cystectomy, following laparoscopic inspection, the ovarian cyst is enucleated via the
48 vaginal route. Alternatively, the enucleation is done laparoscopically and the excised
49 mass extracted vaginally. The merits of this procedure compared to a laparoscopic
50 cystectomy are that it permits removal of larger ovarian cysts, has a shorter operating
51 time, and results in less cyst spillage. In laparoscopically supported vaginal ovarian

M Tanaka Culdotomy with ultrasound and umbrella page 4

52 cystectomy, the cystectomy is initially approached transvaginally, and in the cases in
53 which a transvaginal extraction is impossible, laparoscopy is used to complete the
54 operation.⁸ The merits of this system are that an abdominal incision can be avoided in
55 most patients treated and the remaining patients can be salvaged by laparoscopy; thus, a
56 laparotomy is avoided in all cases. In both NOTES and an ovarian cystectomy, the use
57 of a vaginal route may greatly contribute to the progress in the minimally invasive
58 surgery.

59 In an ovarian cystectomy using a transvaginal route, a culdotomy is one of the most
60 important steps.⁹⁻¹⁰ Especially in the laparoscopically supported system beginning
61 with a vaginal approach, a successful culdotomy is an essential step.¹¹ The peritoneal
62 cavity cannot be entered without an accurate vaginal wall incision, and a blind incision
63 may occasionally injure the rectum.¹² We previously presented the new culdotomy
64 technique using an ultrasonographic guidance and a renal balloon dilator catheter; this
65 procedure facilitates the flawless performance of a culdotomy.¹¹ Visualization by
66 ultrasound ensured safe entry into the cul-de-sac without complications. The
67 drawback of this method, however, was that this multi-step procedure using a balloon
68 dilator, took longer to perform than a traditional culdotomy; therefore, it was not

M Tanaka Culdotomy with ultrasound and umbrella page 5

69 practical. Simplification of the technique was our next objective.

70 In this report, we present a novel, simplified culdotomy technique using a newly

71 developed needle. The purpose of the present study was to evaluate the feasibility and

72 effectiveness of this method, which we termed “Culdotomy Two U.”

For Peer Review

73 **Materials and Methods**

74 We performed vaginal ovarian cystectomies via ultrasound-guided culdotomy with
75 an umbrella Hakko needle on 35 patients with presumed benign unilateral ovarian cysts
76 and one with bilateral cysts; the procedures were performed between June 2006 and
77 March 2010 at Kanazawa University Hospital or Sagawa Clinic.

78 The patients were required to be non-virginal for employment of the transvaginal
79 route. The inclusion criteria for patients with an ovarian cyst were: presumed to be
80 benign; located in the cul-de-sac; and presumed absence of extensive adhesions. The
81 presence of one or more of the following sonographic criteria was considered to
82 increase the index of suspicion for a malignancy: multilocular appearance; irregular
83 border; intracystic papillary vegetation; or the presence of ascites.¹³⁻¹⁵ In some cases
84 magnetic resonance imaging (MRI) was used to distinguish mature cystic teratomas or
85 endometriomas from other ovarian tumors (including malignancies). Teratomas with
86 serum squamous cell carcinoma antigen (SCC) levels outside of the normal range (> 1.5
87 ng/ml) were excluded, because of the possibility that teratomas with a SCC beyond the
88 normal value may have a malignant transformation.¹⁶⁻¹⁸ Teratomas with
89 alpha-fetoprotein levels outside of the normal range were also excluded because of the

M Tanaka Culdotomy with ultrasound and umbrella page 7

90 possibility of an immature cystic teratoma.¹⁹ Cyst location was determined by
91 preoperative transvaginal sonography and patients with at least one ovarian cyst located
92 in the cul-de-sac were included. The adhesion is examined on bimanual examination
93 or pre-operative ultrasound examination. The cases of endometriomas in which the
94 women without infertility and dysmenorrhea desires no scar and the cyst is deemed not
95 to be adherent, were included.

96 For each patient, the following parameters were included in the analysis: age, body
97 mass index, parity, the diameters of ovarian cysts, outcome of culdotomy, operating
98 time for culdotomy, blood loss during culdotomy, complications of culdotomy,
99 C-reactive protein (CRP) level on postoperative day 3, and histology. Some data were
100 reported as mean \pm standard deviation or n (%).

101 The following procedure was used for each culdotomy. Patients were administered
102 enemas on both the day prior to and the day of surgery. The culdotomy was performed
103 with the patient in the dorsal lithotomy position on the operating table, under general or
104 spinal anesthesia. A speculum was placed in the vagina and the cervix was visualized
105 and grasped with forceps. A vaginal ultrasound probe with a needle guide was then
106 inserted into the vagina. The ovarian cyst was directly punctured under ultrasound

M Tanaka Culdotomy with ultrasound and umbrella page 8

107 guidance with an umbrella Hakko needle via the center of the posterior vaginal fornix.

108 Following ultrasonographic confirmation of the placement of the top of the umbrella

109 needle into the cyst, the umbrella portion of the needle was opened and stabilized by

110 forceps and an inner needle was inserted. Following the extraction of the ultrasound

111 probe with a needle guide from the vagina, the needle remained, penetrating the center

112 of the posterior vaginal fornix. While the needle was gently retracted towards the

113 operator's side, the vaginal walls on both sides of the needle were incised with an

114 electric scalpel. Following an adequate incision of the vaginal wall, the ovarian cyst

115 wall was visible in the cul-de-sac through the vaginal defect. By bluntly enlarging the

116 defect in the vaginal wall with forceps, the culdotomy was completed.

117 The ovarian cyst was then partially exteriorized through the vaginal wall defect with

118 gentle traction on the umbrella Hakko needle towards the operator's side. The cyst

119 contents were aspirated with another needle to reduce its volume and permit complete

120 exteriorization. After the descent of the cyst into the vagina, a transvaginal ovarian

121 cystectomy was performed in a manner similar to that of a laparotomy. The culdotomy

122 was then closed with a suture.

123 The umbrella Hakko needle consists of a 19-gauge, 30-cm-long, metal needle with

M Tanaka Culdotomy with ultrasound and umbrella page 9

124 an overcoat. The metal needle and the overcoat are fixed at the top of the needle.

125 The needle has four 10-mm, longitudinal slits beginning 2 mm below the overcoat tip.

126 By moving the overcoat, these slits enable this portion of the needle to open in an

127 umbrella-like fashion. The umbrella can then be held open by stabilizing the needle

128 and the overcoat with forceps. This needle has two attachments. One is an inner

129 needle and the other is a screw. The tip of the inner needle is dull to prevent injury to

130 the bowel or other tissues in the cul-de-sac when it is inserted into the metal needle.

131 The screw is used to fix the metal needle to the overcoat prior to removal of the forceps.

132 The umbrella Hakko needle is a newly-developed device that is not yet approved for

133 medical use. The Kanazawa University Hospital ethics committee authorized the

134 experimental use of this device in our patients. A full explanation of the device was

135 provided to the patients and all gave informed consent prior to participating in the study.

136 **Results**

137 The mean age was 32.3 years with a standard deviation of 5.7 years. The mean
138 body mass index was 20.7 with a standard deviation of 3.1. Twenty-three patients
139 (64%) were nulliparas. The mean maximum cyst diameter was 6.9 cm with a standard
140 deviation of 2.1 cm.

141 In all cases, culdotomy was successfully performed; the operating time was less than
142 10 minutes and the blood loss was less than 10 ml. There were no
143 culdotomy-associated complications, including rectal injury. The mean CRP value on
144 postoperative day 3 was 1.47 mg/dl with a standard deviation of 1.25 mg/dl.

145 Histological examination of the resected specimens demonstrated eighteen teratomas,
146 eleven serous cystadenomas, three endometriomas, and four mucinous cystadenoma.

147 There were no cases of malignancy.

M Tanaka Culdotomy with ultrasound and umbrella page 11

148 **Discussion**

149 Culdotomy for transvaginal removal of ovarian cysts is sometimes laborious. In a
150 vaginal hysterectomy, the other operative steps can replace the unsuccessful culdotomy,
151 and culdotomy can be re-challenged after several successful steps. Unlike a
152 culdotomy for a vaginal hysterectomy, that step for an ovarian cystectomy must be
153 successfully accomplished at the beginning of the operation; this is because the other
154 operative steps cannot be started without the entering the cul-de-sac. A
155 poorly-executed culdotomy should be avoided because the cicatrices in the cul-de-sac
156 may cause subsequent dyspareunia. Needless to say, rectal injury must be avoided.
157 A reliable and safe culdotomy technique is needed for a vaginal ovarian cystectomy.

158 Direct centesis of the ovarian cyst under ultrasound guidance is a marked
159 characteristic of our culdotomy technique. We positively utilize the fact that most
160 ovarian cysts are located in the cul-de-sac. In such cases, transvaginal ultrasound can
161 easily visualize the safe vaginal area for the entry into the cul-de-sac; this area is
162 between the cyst and the ultrasound probe. The needle penetrating from the vaginal
163 side toward the cyst is a useful guide for the accurate incision of the vaginal wall.

164 Visualization by ultrasound and direct centesis prevent intestinal and rectal injuries and

M Tanaka Culdotomy with ultrasound and umbrella page 12

165 always lead to successful culdotomy.

166 The culdotomy technique described in this report employed a newly-developed
167 device, the umbrella Hakko needle. This method simplifies our previously-developed
168 method that uses a balloon dilator.¹¹ The mean operating time was shortened from 23
169 minutes to less than 10 minutes. This is because culdotomy with the umbrella Hakko
170 needle eliminates several steps required when the balloon dilator is used. Ultrasound
171 guidance and centesis using the umbrella needle are key to this practical culdotomy
172 procedure. Thus, we named this procedure “Culdotomy Two U,” for ultrasound and
173 umbrella.

174 The umbrella Hakko needle has some noteworthy features. The most important
175 feature is the guidance for cul-de-sac entry. If only we incise the vaginal wall on both
176 sides of the needle, the intraperitoneal cavity can be opened without exception. In this
177 technique, we do not have to possess any excellent skills in regard to experience and
178 intuition. After the centesis of the cyst, the needle is fixed in an umbrella-like fashion
179 and the top of the needle is maintained within the cyst. This prevents the cyst from
180 withdrawing into the pelvic cavity and eliminates the difficulty of locating the cyst after
181 culdotomy. The needle is gently pulled towards the operator’s side to incise the

M Tanaka Culdotomy with ultrasound and umbrella page 13

182 vaginal wall. The opened umbrella is useful to prevent the needle from escaping.

183 Moreover, the traction of the opened needle is expected to fill in a tiny hole caused by

184 the centesis and to diminish the spillage of the cyst contents.

185 We must take into consideration the influences of intraperitoneal spillage of cyst

186 contents. When we perform an ovarian cystectomy, either laparoscopically or

187 transvaginally, it is theoretically impossible to avoid intraperitoneal spillage in all

188 cases.²⁰ Thus, it is imperative to preoperatively minimize the possibility of an ovarian

189 malignancy. Meticulous preoperative studies, including ultrasound, MRI, and tumor

190 markers are essential; all cases of possible malignancy should be excluded.¹³⁻¹⁹ In

191 some cases in which preoperative examinations don't perfectly deny the possibility of

192 malignancy, laparoscopy should be selected because laparoscopic inspection may be

193 useful to find ovarian malignancy. Chemical inflammation after intraperitoneal

194 spillage also must be avoided. The mean CRP value on postoperative day 3 was 1.47

195 mg/dl and statistically equal to that of laparoscopic ovarian cystectomy cases (data not

196 shown). These results suggest that intraperitoneal spillage is minimal and chemical

197 inflammation does not occur. However, the degree of intraperitoneal spillage should

198 be estimated using a different method. Currently, in some cases, we perform the

M Tanaka Culdotomy with ultrasound and umbrella page 14

199 intraperitoneal observation with a flexible culdoendoscope during a vaginal ovarian
200 cystectomy. Using this scope, it is possible not only to observe but also to irrigate the
201 pelvic cavity; thus, this method may become useful as a routine procedure for vaginal
202 ovarian cystectomy.

203 We cannot adopt the Culdotomy Two U procedure in all benign ovarian cysts. In
204 cases in which the ovarian cyst is out of cul-de-sac, we adopt either of the following two
205 methods. When the cyst is only a short distance from the cul-de-sac, the Culdotomy
206 FourS Two U procedure is selected; in this procedure, an artificially-developed, saline
207 solution space in the cul-de-sac is punctured by the umbrella needle.³ When the cyst is
208 located on the anterior surface of the uterus, we employ an anterior colpotomy, using the
209 traditional method of incising the anterior vaginal fornix.⁸

210 When an ovarian cystectomy is successfully completed vaginally, it compares
211 favorably to laparoscopic surgery in terms of its invasiveness. Vaginal surgery has the
212 additional benefit of no visible scarring. The culdotomy is one of the most important
213 steps in completing the transvaginal removal of ovarian cysts; thus, we focused on
214 optimizing the culdotomy procedure. The Culdotomy Two U procedure provides a
215 simple, safe, and reliable method and we expect that a vaginal ovarian cystectomy will

M Tanaka Culdotomy with ultrasound and umbrella page 15

216 become more accessible to both patients and gynecologists desiring minimally invasive
217 surgery.

For Peer Review

218 **References**

- 219 1. Voermans RP, Van Berge Henegouwen MI, Fockens P. Natural orifice
220 transluminalendoscopic surgery (NOTES). *Endoscopy* 2007;39:1013–17
221 (review).
- 222 2. Rattner D, Kalloo A. SAGE/ASGES Working Group on Natural Orifice
223 Translumenal Endoscopic Surgery. October 2005. *Surg Endosc* 2006;20:329–33.
- 224 3. Tanaka M, Sagawa T, Hashimoto M, Mizumoto Y, Yoshimoto H, Yamazaki R, et
225 al. The Culdotomy FourS Two U procedure for transvaginal access to the
226 peritoneal cavity. *Endoscopy* 2009;41:472–4.
- 227 4. Tsin DA, Colombero LT, Lambeck J, Manolas P. Minilaparoscopy-assisted
228 natural orifice surgery. *JSLS* 2007;11:24–9.
- 229 5. Ghezzi F, Raio L, Mueller MD, Gyr T, Buttarelli M, Franchi M. Vaginal
230 extraction of pelvic masses following operative laparoscopy. *Surg Endosc*
231 2002;16:1691–96.
- 232 6. Teng FY, Muzsnai D, Perez R, Mazdisnian F, Ross A, Sayre JW. A comparative
233 study of laparoscopy and colpotomy for the removal of ovarian dermoid cysts.
234 *Obstet Gynecol* 1996;87:1009–13.

M Tanaka Culdotomy with ultrasound and umbrella page 17

- 235 7. Pardi G, Carminati R, Ferrari MM, Ferrazzi E, Bulfoni G, Marcozzi S.
236 Laparoscopically assisted vaginal removal of ovarian dermoid cysts. *Obstet*
237 *Gynecol* 1995;85:129–32.
- 238 8. Tanaka M, Sagawa T, Mizumoto Y, Hashimoto M, Yoshimoto H, Yamazaki R, et
239 al. Use of laparoscopic support to avoid laparotomy in vaginal ovarian
240 cystectomy. *J Minim Invasive Gynecol* 2008;15:350–4.
- 241 9. Lee RA, Welch JS, Spraitz AF Jr. Use of posterior culdotomy in pelvic operation.
242 *Am J Obstet Gynecol* 1966 Jul 15;95:777–80.
- 243 10. Massi GB, Savino L, Lena A, Susini T. Management of benign adnexal masses
244 by vaginal route. *Front Biosci* 1996;1:8–11.
- 245 11. Tanaka M, Sagawa T, Hashimoto M, Mizumoto Y, Yoshimoto H, Yamazaki R, et
246 al. Ultrasound-guided culdotomy for vaginal ovarian cystectomy using a renal
247 balloon dilator catheter. *Ultrasound Obstet Gynecol* 2008;31:342–5.
- 248 12. Hoffman MS, Lynch C, Lockhart J, Knapp R. Injury of the rectum during
249 vaginal surgery. *Am J Obstet Gynecol* 1999;181:274–7.
- 250 13. Vergote I, De Brabanter J, Fyles A, Bertelsen K, Einhorn N, Sevelde P, et al.
251 Prognostic importance of degree of differentiation and cyst rupture in stage I

- 252 invasive epithelial ovarian carcinoma. *Lancet* 2001;357:176–82.
- 253 14. Patel MD, Feldstein VA, Lipson SD, Chen DC, Filly RA. Cystic teratomas of the
254 ovary: diagnostic value of sonography. *AJR Am J Roentgenol* 1998;171:1061–5.
- 255 15. Cohen L, Sabbagha R. Echo patterns of benign cystic teratomas by transvaginal
256 ultrasound. *Ultrasound Obstet Gynecol* 1993;3:120–3.
- 257 16. Bal A, Mohan H, Singh SB, Sehgal A. Malignant transformation in mature
258 cystic teratoma of the ovary: report of five cases and review of the literature.
259 *Arch Gynecol Obstet* 2007;275:179–82.
- 260 17. Yamanaka Y, Tateiwa Y, Miyamoto H, Umemoto Y, Takeuchi Y, Katayama K, et
261 al. Preoperative diagnosis of malignant transformation in mature cystic teratoma
262 of the ovary. *Eur J Gynaecol Oncol* 2005;26:391–2.
- 263 18. Mori Y, Nishii H, Takabe K, Shinozaki H, Matsumoto N, Suzuki K, et al.
264 Preoperative diagnosis of malignant transformation arising from mature cystic
265 teratoma of the ovary. *Gynecol Oncol* 2003;90:338–41.
- 266 19. Kawai M, Furuhashi Y, Kano T, Misawa T, Nakashima N, Hattori S, et al.
267 Alpha-fetoprotein in malignant germ cell tumors of the ovary. *Gynecol Oncol*
268 1990;39:160–6.

M Tanaka Culdotomy with ultrasound and umbrella page 19

- 269 20. Smorgick N, Barel O, Halperin R, Schneider D, Pansky M. Laparoscopic
270 removal of adnexal cysts: is it possible to decrease inadvertent intraoperative
271 rupture rate? Am J Obstet Gynecol 2009;200:237 e1–3.

For Peer Review

272 **Figure Legends**

273

274 **Figure 1.** Sagittal view of the pelvis illustrating the Culdotomy Two U procedure.

275 The ovarian cyst is directly punctured transvaginally with an umbrella Hakko needle

276 under ultrasound guidance and the umbrella portion of the needle is opened.

277 c: ovarian cyst; us: ultrasound probe; um: umbrella Hakko needle

278

279 **Figure 2.** The Culdotomy Two U procedure.

280 A. With the patient in the dorsal lithotomy position, the ovarian cyst is punctured under

281 ultrasound guidance through a needle guide; an umbrella Hakko needle is inserted at

282 the center of the posterior vaginal fornix.

283 B. The ovarian cyst is punctured transvaginally under ultrasound guidance with an

284 umbrella Hakko needle and the umbrella portion of the needle is opened within the

285 cyst.

286 C. The umbrella Hakko needle penetrates the center of the posterior vaginal fornix.

287 D. With gentle traction on the needle towards the operator's side, the vaginal walls on

288 both sides of the needle are incised with an electric scalpel.

M Tanaka Culdotomy with ultrasound and umbrella page 21

289 E. Following an adequate incision, the ovarian cyst wall is visible, punctured by an
290 umbrella needle.

291 F. The cyst wall is enucleated transvaginally.

292

293 **Figure 3.** The umbrella Hakko needle.

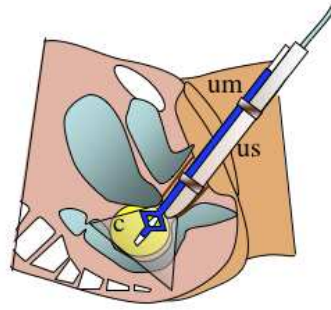
294 A. The body and attachments; an inner needle with a screw.

295 B. The umbrella portion is closed.

296 C. The umbrella portion is opened.

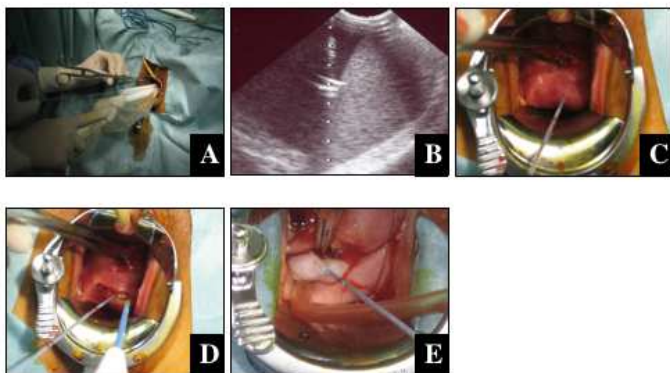
297 D. An inner needle is inserted into the opened umbrella needle.

Fig.1




Review

Fig.2




Review

Fig3



A



B

C

D

Review