

# Multifocal human papillomavirus detection in palatine and pharyngeal tonsils

著者	Murono Shigeyuki, Yoshida Hiroshi, Kobayashi Tetsuro, Kawase Tomotaka, Kikuchi Daisuke, Suzuki Toshihiko, Nakanishi Yosuke, Endo Kazuhira, Kimura Hiroaki, Wakisaka Naohiro, Yoshizaki Tomokazu
著者別表示	室野 重之, 中西 庸介, 遠藤 一平, 脇坂 尚宏, 吉崎 智一
journal or publication title	Acta Oto-Laryngologica
volume	138
number	5
page range	483-486
year	2018-05-04
URL	<a href="http://doi.org/10.24517/00050456">http://doi.org/10.24517/00050456</a>

doi: 10.1080/00016489.2017.1408143



**Multifocal human papillomavirus detection in palatine and pharyngeal tonsils**

Running title: HPV in palatine and pharyngeal tonsils

Shigeyuki Muro<sup>a,b</sup>, Hiroshi Yoshida<sup>b</sup>, Tetsuro Kobayashi<sup>a</sup>, Tomotaka

Kawase<sup>a</sup>, Daisuke Kikuchi<sup>a</sup>, Toshihiko Suzuki<sup>a</sup>, Yosuke Nakanishi<sup>b</sup>,

Kazuhira Endo<sup>b</sup>, Satoru Kondo<sup>b</sup>, Naohiro Wakisaka<sup>b</sup>, Tomokazu Yoshizaki<sup>b</sup>

<sup>a</sup>Department of Otolaryngology, Fukushima Medical University, Fukushima, Japan

<sup>b</sup>Department of Otolaryngology-Head and Neck Surgery, Kanazawa University, Kanazawa, Japan

Conflicts of interest: None

Financial disclosure: This study was supported in part by JSPS KAKENHI

Grant Numbers JP26462598 and JP17K11394 and research grants from the

Daiwa Securities Health Foundation (42-17) and the Support Unit for

Conducting Clinically Essential Studies in St. Luke's International

University.

Corresponding author

Shigeyuki Murono

Department of Otolaryngology, Fukushima Medical University

1 Hikarigaoka, Fukushima 960-1295, Japan

Phone: 81-24-547-1321

Fax: 81-24-548-3011

Email: [murono@fmu.ac.jp](mailto:murono@fmu.ac.jp)

## **ABSTRACT**

**Conclusion:** HPV DNA detection in both the palatine and pharyngeal tonsils in the same individual, especially in HPV-OPC, suggested the ability of HPV to infect tonsillar tissues of Waldeyer's ring multifocally.

**Background:** Multifocal human papillomavirus (HPV) infection into the palatine and pharyngeal tonsils, which might be linked to a second primary tumor of HPV-positive oropharyngeal cancer (OPC), was investigated.

**Patients and methods:** One hundred and five patients with various head and neck diseases including 14 patients with OPC were enrolled in this study.

Swabs from the palatine and pharyngeal tonsils were collected in each individual, and auto-nested GP5+/GP6+ PCR for HPV DNA was performed.

**Results:** HPV DNA was detected in the palatine tonsil or the pharyngeal tonsil in a small subset of upper respiratory tract cancer other than OPC (URTC) and non-cancer diseases. Furthermore, HPV DNA was detected in both the palatine and pharyngeal tonsils in the same individual in 2 of 48 (4%) URTC cases, and 1 of 43 (2%) non-cancer cases. On the other hand, p16-positive OPC cases demonstrated a higher HPV DNA detection rate (4 of 9, 44.4%) compared with other disease groups.

**Key Words:** Human papillomavirus, palatine tonsil, pharyngeal tonsil, oropharyngeal cancer, auto-nested PCR

## **Introduction**

Human papillomavirus (HPV) infection is a principal cause of a distinct form of oropharyngeal cancer (OPC) [1]. The incidence of HPV-positive OPC (HPV-OPC) has been increasing, and it accounted for 72% of all OPCs in the early 2000s in the United States [2]. Interestingly, the clinical characteristics of HPV-OPC are quite different from classic HPV-negative OPC [1]. Some major interesting characteristics of HPV-OPC include the predominant occurrence in the palatine tonsil followed by the lingual tonsil, and a reduced risk of developing second primary cancer compared with classic OPC [3].

On the other hand, there are interesting case reports showing synchronous HPV-related bilateral tonsillar cancers [4,5]. Furthermore, McGovern et al. demonstrated a case with three synchronous HPV-positive cancers of the bilateral tonsils as well as the nasopharynx [6]. Therefore, multifocal HPV infection into Waldeyer's ring including the palatine tonsils, pharyngeal tonsil, and lingual tonsil may be possible. However, there have been few reports from this perspective [7]. In the present study, we compared the incidence of HPV infection between the palatine and pharyngeal tonsils in the same individuals in a group of patients with various head and neck

diseases including OPC.

## **Patients and methods**

### ***Patients***

One hundred and five patients with various head and neck diseases including 14 OPCs were enrolled in this study. They were divided into three groups: OPC, upper respiratory tract cancer other than OPC (URTC), and non-cancer. The clinical characteristics of the patients are shown in Table 1. URTC included 15 laryngeal cancers, 13 hypopharyngeal cancers, 9 oral cancers, 8 nasopharyngeal cancers, and 3 others. Non-cancer included 15 sinonasal diseases except for papilloma, 8 benign thyroid tumors, 7 benign laryngeal diseases except for papilloma, 7 ear diseases, 3 benign salivary gland tumors, and 3 others. This study was approved by the Ethics Committee of Kanazawa University School of Medicine (2014-054), and Fukushima Medical University (2996), and written consent was obtained from all enrolled patients.

Actually, enrolled patients in this study also comprised the majority of subjects in a previous study simultaneously performed [8]. Some data in the

previous study, namely, patient characteristics, HPV detection and genotyping in the palatine tonsil, and p16 immunostaining, were utilized in the present study [8]. However, as described above, the present study focused on comparing HPV infection between the palatine and pharyngeal tonsils, contrasting with the previous report focusing on HPV detection in oral rinse as a biomarker of OPC [8].

### ***Sample collection***

With respect to the sample from the palatine tonsil, brushing of the palatine tonsil using a swab for uterine cervix cytodiagnosis was performed [8]. Brushing was basically performed on the surface of the palatine tonsil while it was performed on the tumor-harboring palatine tonsil in cases with tonsillar cancer. With respect to the sample from the pharyngeal tonsil, brushing was endonasally performed using a swab with a movable cover allowing exposure only in the nasopharynx to prevent endonasal contamination. Samples were stored at 4 degrees Celsius until use after being suspended in a preservative solution for liquid-based cytology (Medical & Biological Laboratories, Nagoya, Japan).

### ***HPV DNA detection***



DNA extraction and HPV DNA detection were performed as reported previously [8]. Briefly, after DNA extraction,  $\beta$ -Globin was first amplified by the polymerase chain reaction (PCR) to confirm the adequacy of the extracted DNA in all samples. In  $\beta$ -globin-positive samples, auto-nested PCR consisting of the first amplification with 36 cycles and the second with 20 cycles using the same set of GP5+/GP6+ primers to increase sensitivity was performed to detect a broad spectrum of mucosotropic HPV [8-12]. This generates an approximately 140-bp-long fragment from the HPV L1 structural gene. The amplified DNA was visualized by ultraviolet illumination using ethidium bromide after electrophoresis on 2% agarose gel. The p1203 PML2d HPV-16 plasmid, which was a gift from Peter Howley (Addgene plasmid # 10869), was used as a positive control, while the negative control included all reagents except for DNA.

### ***HPV genotyping***

HPV genotyping, which could detect 37 HPV genotypes including 15 high-risk types (16, 18, 31, 33, 35, 39, 45, 51, 52, 53, 56, 58, 59, 66, and 68), 6 low-risk types (6, 11, 42, 43, 44, and CP8304), and 16 probably low-risk types (26, 34, 40, 54, 55, 57, 61, 67, 69, 70, 71, 72, 73, 82, 83, and 84) was performed

for HPV DNA-positive samples as previously described [8].

### ***Immunohistochemistry***

In 14 OPC cases, previously reported data on immunostaining for p16 was also utilized in this study [8].

### ***Statistical analysis***

The distribution of HPV DNA between the palatine and pharyngeal tonsils was analyzed using the two-tailed Fisher's exact test. All analyses were carried out using SPSS19.0 software (SPSS Inc., Chicago, IL, USA). In all tests,  $p < 0.05$  was considered significant.

## **Results**

### ***HPV DNA detection in the palatine and pharyngeal tonsils***

$\beta$ -Globin was detected in all samples. In 14 cases with OPC, HPV DNA was detected in 3 cases (21%) in only the palatine tonsil, 1 case (7%) in only the pharyngeal tonsil, 4 cases (29%) in both the palatine and pharyngeal tonsils, and 6 cases (43%) in neither the palatine nor pharyngeal tonsil (Table 2, Figure). In 9 cases with p16-positive OPC, HPV DNA was detected in 3 cases (33%), none (0%), 4 cases (44%), and 2 cases (22%), respectively. In 5 cases

with p16-negative OPC, HPV DNA was detected in none (0%), 1 case (20%), none (0%), and 4 cases (80%), respectively.

In 48 cases with URTC, HPV DNA was detected in 2 cases (4%) in only the palatine tonsil, 2 cases (4%) in only the pharyngeal tonsil, 2 cases (4%) in both the palatine and pharyngeal tonsils, and 42 cases (88%) in neither the palatine nor pharyngeal tonsil (Table 2, Figure). All these 6 cases with HPV detection, including one nasopharyngeal cancer, two hypopharyngeal cancers, two oral cancers, and one cervical node cancer of unknown primary, were negative for p16 immunostaining. Similarly, in 43 cases with non-cancer, HPV DNA was detected in 3 cases (7%), 4 cases (9%), 1 case (2%), and 35 cases (81%), respectively (Table 2, Figure).

### ***HPV genotyping***

HPV genotyping was further performed in 29 samples with HPV DNA detection. In p16-positive OPC, HPV58 was detected in one case positive for only the palatine tonsil. Two cases positive for both the palatine and pharyngeal tonsils demonstrated HPV16 in each sample. In URTC, one of two cases positive for only the pharyngeal tonsil showed HPV16. This was a case with oral cancer. Another case positive for both tonsils showed HPV16

in the pharyngeal tonsil while no genotype was detectable in the palatine tonsil. This was a case with hypopharyngeal cancer. In non-cancer cases, two of three cases positive for only the palatine tonsil demonstrated HPV16. No types of HPV were detected in the remaining samples of each disease group.

## **Discussion**

In the present study, HPV DNA was detected in 4 of 48 cases (8.3%) in the palatine tonsil and also 4 of 48 cases (8.3%) in the pharyngeal tonsil in patients with URTC. Similarly, HPV DNA was detected in 4 of 43 cases (9.3%) in the palatine tonsil and 5 of 43 cases (11.6%) in the pharyngeal tonsil in patients with non-cancer. A few reports comparing HPV detection in those two tissues are currently available [13,14]. Although these reports analyzed HPV DNA using GP5+/GP6+ primers or MY09/MY11 primers in paraffin-embedded tonsillar and adenoid tissues of children, the results were conflicting [13,14]. The former demonstrated HPV detection in 9.4% in the palatine tonsil and in 7.1% in the pharyngeal tonsil, while the latter showed HPV detection in neither the palatine nor pharyngeal tonsil [13,14].

Although it is possible that the quantity of DNA obtained from a swab is less

than from paraffin-embedded tissue, an HPV detection rate in the present study equivalent to that in the report by Mammas et al. in both tissues may be due to using auto-nested GP5+/GP6+ PCR like our previous report in oral rinse [8]. Of course, the fact that subjects in the present study were adult may also affect it.

The present study demonstrated that HPV infection is possible solely in either the palatine tonsil or pharyngeal tonsil as well as multifocally in both tonsils. It remains unknown whether HPV infection of those tissues is passive or oncogenic. Although several reports demonstrated HPV detection in a small subset of nasopharyngeal cancer (NPC), most HPV-related head and neck cancers belong to OPC [1,15,16]. Therefore, the greater predominance of OPC than NPC in the association with HPV, despite the similar HPV detectability between both tonsils in the present study, suggests that HPV infection could be rarely oncogenic in the pharyngeal tonsil, but be possibly oncogenic in the palatine tonsil. Structural differences between both tonsils may be one of the reasons for such a predominance [17]. HPV-OPC generally arises from deep crypts of the palatine tonsil. Interestingly, palatine tonsillar crypts, blind tubules from the epithelium on the surface of

the tonsil, extend deeply into this tissue [17]. On the other hand, unlike the palatine and lingual tonsils, the pharyngeal tonsils have no epithelial crypts extending into them [17].

Multifocal HPV infection into both the palatine and pharyngeal tonsils was observed in the present study, especially in p16-positive OPC rather than URTC and non-cancer. This is an interesting finding because an HPV-associated second primary tumor of HPV-OPC may present synchronously and/or metachronously outside the oropharynx [6,18].

Virus-induced field cancerization and/or multifocal oncogenic HPV infection of the pharynx is considered uncommon in OPC because both HPV-positive and HPV-negative tonsil cancers similarly harbor HPV infection at other pharyngeal sites [7]. However, in the report by Thavaraj et al., three of 12 other pharyngeal sites with HPV infection, which accounted for 3 of 59 cases as a result, demonstrated p16 positivity as well as a histology of severe dysplasia in HPV-positive tonsillar cancer, while none of such sites showed them in HPV-negative tonsillar cancer [7]. This suggests that multifocal HPV infection in tonsils of Waldeyer's ring could be oncogenic, at least in part. In accordance with this, Joseph et al. reported that all 4 synchronous or

metachronous bilateral HPV-associated tonsillar cancers demonstrated 100% concordance of the HPV DNA sequence in each pair of the index tumor and corresponding second primary tumor [19]. Therefore, we believe that the importance of multifocal infection of HPV from the perspective of multicentric cancerization in HPV-OPC should be emphasized.

There are several limitations in the present study. Firstly, the number of cases with OPC was small. However, the high HPV DNA detection rate in the cancer-harboring palatine tonsil suggested that our procedure was adequate. Therefore, we could at least demonstrate a trend toward a higher rate of HPV infection into the pharyngeal tonsil in HPV-OPC (44.3%) compared with URTC (8.3%) and non-cancer (11.6%). Secondly, the contralateral normal-appearing tonsil should have been investigated in addition to the index cancer-harboring tonsil in cases of OPC. This would have provided us with further information with respect to multifocal HPV infection into Waldeyer's ring. Thirdly, although we made up for the disadvantage of the small quantity of each sample with the use of auto-nested PCR, as previously shown, we could not evaluate the histology including presence of cancer or dysplasia nor p16 immunoreactivity in cases

with HPV DNA detection [8]. Prospective observation including histology if necessarily will be helpful to confirm an oncogenic role of HPV infection for the second primary tumor in OPC. Fourthly, the HPV genotyping rate was low. We considered the procedural difference between genotyping, which consisted of one round of PCR, and auto-nested PCR was a major reason for the low rate [8]. However, at least a trend of HPV16 predominance was confirmed. Further study is planned to overcome these limitations.

## **Conclusion**

In conclusion, HPV DNA detection in both the palatine and pharyngeal tonsils in the same individual, especially in those with HPV-OPC, suggested the ability of HPV to infect tonsillar tissues of Waldeyer's ring multifocally. This will be focused on from the perspective of a second primary tumor of HPV-OPC.

## **Acknowledgement**

We thank Dr. P. Howley for providing p1203 PML2d HPV16. This study was supported in part by JSPS KAKENHI Grant Numbers JP26462598 and



JP17K11394 and research grants from the Daiwa Securities Health Foundation (42-17) and the Support Unit for Conducting Clinically Essential Studies in St. Luke's International University.

**Disclosure statement**

The authors reported no conflicts of interest. The authors alone are responsible for the content and writing the paper.

## References

1. Marur S, D'Souza G, Westra WH, et al. HPV-associated head and neck cancer: a virus-related epidemic. *Lancet Oncol* 2010;11:781-789.
2. Chaturvedi AK, Engels EA, Pfeiffer RM, et al. Human papillomavirus and rising oropharyngeal cancer incidence in the United States. *J Clin Oncol* 2011;29:4294-4301.
3. Xu CC, Biron VL, Puttagunta L, et al. HPV status and secondary primary tumours in oropharyngeal squamous cell carcinoma. *J Otolaryngol Head Neck Surg* 2013;42:36.
4. Nakahara S, Yasui T, Takenaka Y, et al. Synchronous bilateral tonsillar carcinomas associated with human papillomavirus. *Auris Nasus Larynx* 2014;41:109-112.
5. Theodoraki MN, Veit JA, Hoffmann TK, et al. Synchronous bilateral tonsil carcinoma: case presentation and review of the literature. *Infect Agent Cancer* 2017;12:38.
6. McGovern SL, Williams MD, Weber RS, et al. Three synchronous HPV-associated squamous cell carcinomas of Waldeyer's ring: case report and comparison with Slaughter's model of field cancerization. *Head Neck*

2010;32:1118-1124.

7. Thavaraj S, Stokes A, Mazuno K, et al. Patients with HPV-related tonsil squamous cell carcinoma rarely harbor oncogenic HPV infection at other pharyngeal sites. *Oral Oncol* 2014;50:241-246.

8. Yoshida H, Muro S, Ueno T, et al. Usefulness of human papillomavirus detection in oral rinse as a biomarker of oropharyngeal cancer. *Acta Otolaryngol* 2017;137:773-777.

9. Jacobs MV, de Roda Husman AM, van den Brule AJ, et al. Group-specific differentiation between high- and low-risk human papillomavirus genotypes by general primer-mediated PCR and two cocktails of oligonucleotide probes. *J Clin Microbiol* 1995;33:901-905.

10. Harwood CA, Spink PJ, Suretheran T, et al. Degenerate and nested PCR: a highly sensitive and specific method for detection of human papillomavirus infection in cutaneous warts. *J Clin Microbiol* 1999;37:3545-3555.

11. Remmerbach TW, Brinckmann UG, Hemprich A, et al. PCR detection of human papillomavirus of the mucosa: comparison between MY09/11 and GP5+/6+ primer sets. *J Clin Virol* 2004;30:302-308.

12. Souto Damin AP, Guedes Frazzon AP, de Carvalho Damin D, et al. Detection of human papillomavirus DNA in squamous cell carcinoma of the esophagus by auto-nested PCR. *Dis Esophagus* 2006;19:64-68.
13. Mammas IN, Sourvinos G, Michael C, et al. Human papilloma virus in hyperplastic tonsillar and adenoid tissues in children. *Pediatr Infect Dis J* 2006;25:1158-1162.
14. Xue XC, Chen XP, Yao WH, et al. Prevalence of human papillomavirus and Epstein-Barr virus DNA in Chinese children with tonsillar and/or adenoidal hypertrophy. *J Med Virol* 2014;86:963-967.
15. Dogan S, Hedberg ML, Ferris RL, et al. Human papillomavirus and Epstein-Barr virus in nasopharyngeal carcinoma in a low-incidence population. *Head Neck* 2014;36:511-516.
16. Kano M, Kondo S, Wakisaka N, et al. The influence of human papillomavirus on nasopharyngeal carcinoma in Japan. *Auris Nasus Larynx* 2017;44:327-332.
17. Hollinshead WH. *Anatomy for surgeons: The head and neck*, third edition. Philadelphia: J. B. Lippincott Company; 1982. pp.389-411.
18. Caley A, Evans M, Powell N, et al. Multicentric human

papillomavirus-associated head and neck squamous cell carcinoma. *Head Neck* 2015;37:202-208.

19. Joseph AW, Ogawa T, Bishop JA, et al. Molecular etiology of second primary tumors in contralateral tonsils of human papillomavirus-associated index tonsillar carcinomas. *Oral Oncol* 2013;49:244-248.

## Figure Legends

Representative images of HPV DNA detection. HPV DNA was detected in both the palatine tonsil (Pal) and pharyngeal tonsil (Pha) in a p16-positive oropharyngeal cancer (OPC) case (1st panel), and in only Pha in a p16-negative OPC case (6th panel). HPV DNA was detected in both Pal and Pha in an upper respiratory tract cancer other than OPC (URTC) case (2nd panel), and in only Pha in another URTC case (3rd panel). HPV DNA was detected in both Pal and Pha in a non-cancer case (4th panel), and in only Pha in another non-cancer case (5th panel). Six lanes belonging to another disease group in each gel were removed from the original image in each panel. PC, positive control; NC, negative control; OR, oral rinse. \* means a blank lane.

Table 1 Patient characteristics

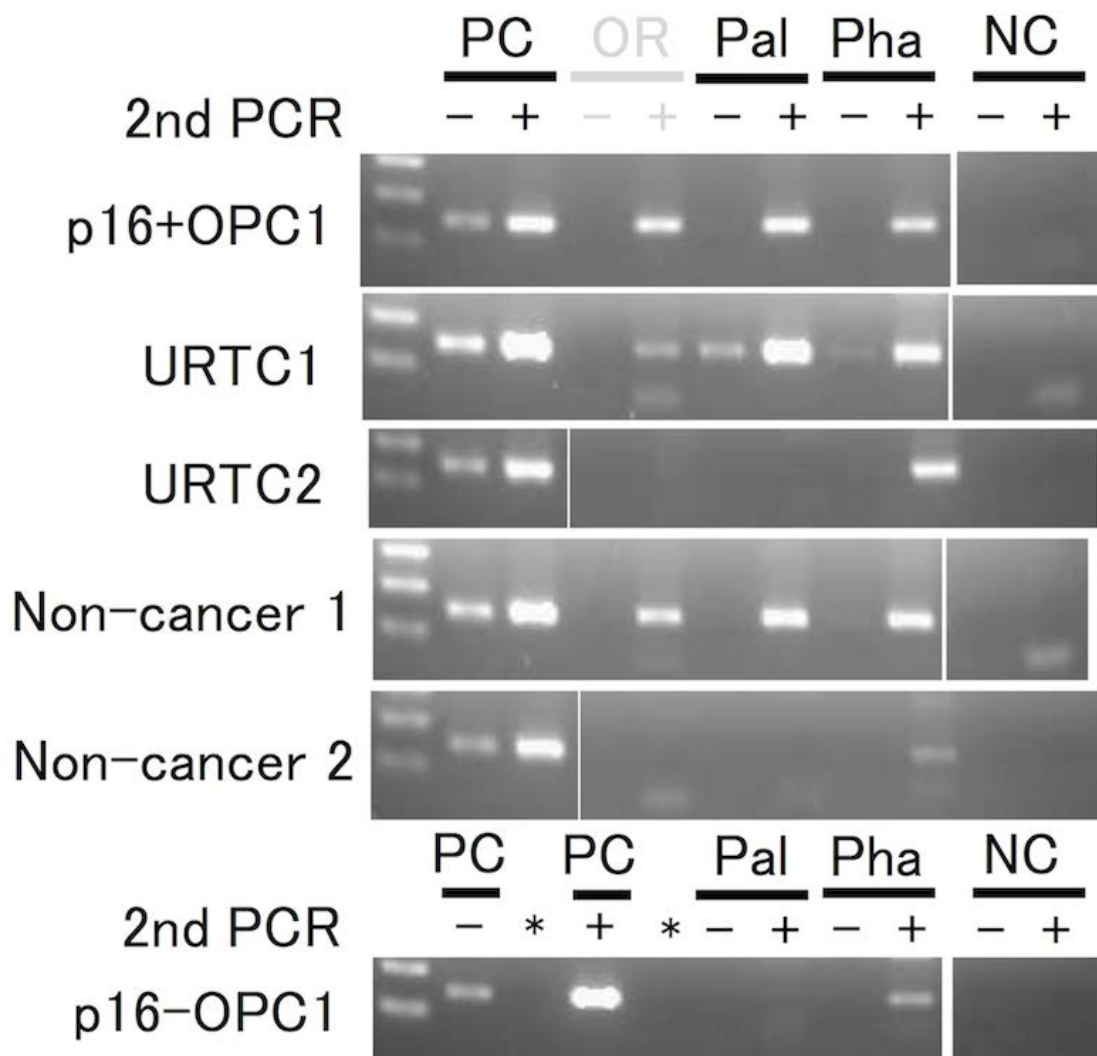
	Number of patients	Sex		Mean age (years)
		Male	Female	
Oropharyngeal cancer	14	10	4	66.3
Upper respiratory tract cancer other than oropharyngeal cancer	48	42	6	65.3
Non-cancer	43	17	26	55.1

Table 2 HPV DNA detection in the palatine and pharyngeal tonsils

	N	Pal* only	Pha** only	Both Pal and Pha	Neither Pal nor Pha	p-value	Summary	
							Pal*	Pha**
OPC	14	3	1	4	6	0.266	7	5
p16-positive OPC	9	3	0	4	2	0.444	7	4
p16-negative OPC	5	0	1	0	4	1.000	0	1
URTC	48	2	2	2	42	0.030	4	4
Non-cancer	43	3	4	1	35	0.402	4	5

\*Palatine tonsil, \*\*Pharyngeal tonsil; OPC, oropharyngeal cancer; URTC, upper respiratory tract cancer other than OPC





Figure