

Skeletal Stability After Mandibular Setback Surgery: Bicortical Fixation Using a 2.0-mm Locking Plate System Versus Monocortical Fixation Using a Nonlocking Plate System

メタデータ	言語: eng 出版者: 公開日: 2017-10-03 キーワード (Ja): キーワード (En): 作成者: メールアドレス: 所属:
URL	http://hdl.handle.net/2297/9783

Skeletal stability after mandibular setback surgery: bicortical fixation using a 2.0-mm locking plate system versus monocortical fixation using a nonlocking plate system

KOICHIRO UEKI, DDS, PhD,† YUKARI HASHIBA DDS, * KOHEI MARUKAWA,
DDS, PhD, † SHAMIUL ALAM BDS, PhD, † KIYOMASA NAKAGAWA, DDS, PhD,
‡ ETSUHIDE YAMAMOTO, DDS, PhD, §

Department of Oral and Maxillofacial Surgery, Graduate School of Medicine, Kanazawa University, 13-1 Takaramachi, Kanazawa 920-8641, Japan.

†Clinical fellow.

* Graduate student.

† Postdoctoral fellow.

‡Associate Professor.

§ Chief Professor.

Address correspondence to: Koichiro Ueki, DDS, PhD.

Department of Oral and Maxillofacial Surgery, Graduate School of Medicine, Kanazawa University, 13-1 Takaramachi, Kanazawa 920-8641, Japan.

Tel: +81-76-265-2444; Fax: +81-76-234-4268

E-mail: kueki@med.kanazawa-u.ac.jp

Abstract

Purpose:

The purpose of this study is to compare the time-course changes in condylar long axis and skeletal stability after sagittal split ramus osteotomy (SSRO) with bicortical plate fixation versus monocortical plate fixation.

Patients and Methods:

Of 40 Japanese patients diagnosed of mandibular prognathism, 20 underwent SSRO with bicortical plate fixation using a locking plate system, while the other 20 underwent SSRO with monocortical plate fixation using a conventional plate system. The time-course changes in condylar long axis and skeletal stability were assessed by axial, frontal, and lateral cephalograms.

Results:

There were significant differences between the two groups in the change of left condyle angle between initial and 1 month ($P=0.0454$) and ANB between 1 and 3 months ($P=0.0206$); however, there were no significant differences between the two groups in the other measurements in each time interval.

Conclusion:

This study suggested that there were no significant differences in postoperative time-course changes between bicortical plate fixation using a locking plate system and monocortical plate fixation using a conventional plate system.

The use of rigid fixation of bony segments in orthognathic surgery has become the standard of care. There are several reasons for this change, including shorter hospital stays and patient convenience.¹

Regarding the comparison between plates and positional screws, several authors have suggested that plates used to stabilize the fragments may have an advantage over bicortical screws because they may minimize rotation of mandibular condyles.^{2,3} Blomqvist and Isaksson⁴ compared short-term stability in two groups of patients who underwent mandibular advancement using either three bicortical positional screws or monocortical screws and plates. They noted that there was no difference in the stability between the two groups. Both showed instability the further the mandible was advanced. Choi, et al.,⁵ reported that there was no significant difference between miniplate fixation and bicortical screw fixation in setback surgery.

On the other hand, one significant development that has taken place recently is the locking screw plate, which has taken various forms over the last few years.⁶⁻⁹ The locking design in the plate prevents screw migration out of the bone by maintaining screw-plate integrity, creating a more rigid system and potentially improved plate performance. Even if some bone resorbs from the undersurface of the plate, the fixation should remain intact. The locking screw plate system reduces compressive forces between the undersurface of the plate and lateral bony cortex better than a conventional mandibular plate. However, there are no reports regarding the use of the locking screw plate system for orthognathic surgery.

The purpose of this study is to compare the time-course changes in condylar long axis and skeletal stability after sagittal split ramus osteotomy (SSRO) with bicortical plate fixation using a locking screw plate system versus monocortical plate fixation using a conventional plate system.

Patients and Methods

Patients

Forty Japanese adults (13 men and 27 women) randomly selected in this study presenting with jaw deformities were diagnosed as mandibular prognathism. At the time of orthognathic surgery, the patients ranged in age from 15 to 39 years, with a mean age and standard deviation of 22.2 ± 5.9 years.

Surgery

Of the 40 patients, 20 (men: 3, women: 17) underwent bilateral SSRO for correction of their mandibular deformities. Monocortical rigid fixation was achieved with miniplates and screws (long miniplate: 4 holes/burr 8mm thickness 1.0 mm and 4 screws (2×7 mm) Würzburg titanium miniplate system, Leibinger Co., Freiburg, Germany). The patients in the monocortical group ranged in age from 17 to 39 years, with a mean age and standard deviation of 21.7 ± 5.6 years. The other 20 patients (men: 10, women: 10) underwent bilateral SSRO with bicortical rigid fixation (long miniplate: 4 holes burr 8mm thickness 1.0mm and 4 screws (2×14 mm and 2×5 mm) Universal Mandible fixation module, Stryker Leibinger Co., Freiburg, Germany). Two screws on distal segment were monocortical fixation, and two screws on proximal segment were used bicortically as positional screws. Bicortical screws were placed at the posterior region to the second molar in the anterior ramus, so that the roots of teeth in the distal segment could be protected (Fig. 1). The patients in the bicortical group ranged in age from 15 to 35 years, with a mean age and standard deviation of 22.8 ± 5.9 years. At the site of fixation, an osseous step was formed, depending on the amount of setback. Bent plates were used to maintain the condyle in its original position in both groups, so that a small gap remained between the bone fragments at the anterior part of the juncture site space in both fixation methods (Fig. 1).¹⁰ After several days of MMF, elastic was placed to maintain an ideal occlusion in the same manner in both groups.

Cephalogram assessment

All patients underwent lateral, frontal and axial cephalograms to assess the skeletal

changes before operation and at 1 month, 3 months, 6 months and 1 year postsurgery. (Figs. 2 and 3).

One skilled observer performed all digitization so that errors in the cephalometric method were small and acceptable for the purposes of this study. Error analysis by digitization and remeasurement of 10 randomly selected cases generated an average error of less than 0.4 mm for the linear measurements and 0.5 degree for the angular measurements.

Statistical analysis

Data were statistically analyzed with StatView software, version 4.5 (ABACUS Concepts, Inc., Berkeley, CA, USA) Each serial period was defined, and the differences between measurements were calculated as follows.

T1: (Initial to 1 month)

T2: (1 month to 3 months)

T3: (3 months to 1 year)

The data between the groups were then compared by a paired comparison method using Student's t-test. Differences were considered significant at $p < 0.05$.

Result

After surgery no patient experienced any wound infection or severe temporomandibular joint symptoms. The mean setback amount was 6.7 ± 3.2 mm on the right side and 6.4 ± 3.2 mm on the left side in the monocortical group and 7.7 ± 4.6 mm on the right side and 8.3 ± 3.5 mm on the left side in the bicortical group. Setback amount in the bicortical group tended to be larger than that in the monocortical group, although there was no significant difference.

There were significant differences between the two groups in left condyle angle in T1 ($P=0.0454$) and ANB in T2 ($P=0.0206$); however, there were no significant differences between the two groups in the other measurements in T1, T2 and T3 (Tables. 1).

Discussion

Many different fixation techniques are commonly used in the clinical setting to stabilize osteotomies after bilateral SSRO. Generally, the use of plate and screw is considered as rigid fixation. However, Hammer, et al.,¹¹ mentioned that monocortical osteosynthesis is not as rigid as bicortical osteosynthesis, and the excessive shear force stress, produced by compressive action of the masseter muscle to the osteotomy line, may transform the mandibular shape postoperatively.¹² Fujioka, et al.,¹³ reported two unusual cases of complete breakage of the miniplates after sagittal split osteotomies; they also reported that postoperative mandibular shape tends to be more changeable in monocortical osteosynthesis. In the short postoperative period, it is understandable that monocortical miniplate fixation provides less stability than that with lag screw. Choung, et al.,¹⁴ compared the mechanical characteristics of the mandible after SSRO through the use of two different techniques to stabilize osteotomy, using finite element computer model simulation. The results showed that 3 bicortical screws forming an inverted-L configuration offer more effective load transmission in the mandibular constrict than a curved titanium plate and 4 monocortical screws.

On the other hand, comparing the locking plate system and the conventional plate system, the theory of the locking screw plate system is that the integration of screw and plate will allow for more rigidity in the plating system, hence decreased fixation failure.^{15,16} In addition, the design of the system allows for less critical adaptation of the plate to the bone surface, and the clinician is not dependent on the bone surface to completely stabilize the plate. Although this represents an advantage in fracture fixation, routine complications

such as infection, plate or screw fracture, and nonunion can still occur.¹⁷⁻¹⁹ Both laboratory and animal models have shown the locking-type system to function just as well or better than the conventional plates with less critical plate adaptation or when bridging continuity defects.²⁰⁻²³ However, Chiodo, et al.,⁹ mentioned that no significant differences were found between the two types of mandibular plates in the laboratory model and that the type and degree of failure are more likely related to bone quality and surgical technique when using 2-mm mandibular plate.

In an FE computer model reported by Choung, et al.,¹⁴ stress concentrations were found after simulated SSRO using a curved titanium plate and 4 monocortical screws. The highest level of stress concentration was found at proximal sites. In the bicortical group in the present study, we used two long screws at proximal sites bicortically. This was considered to be reasonable on the basis of the previous FE model simulation.

When rigid fixation is used, changes in intercondylar angle and width after BSSO advancement or setback may influence TMJ function.²⁴⁻²⁹ Intercondylar width tends to decrease after mandibular setback and to increase after mandibular advancement. This trend becomes clearer with rigid fixation. A change in axial inclination involving either a medial or lateral rotation of the axis was found, with inward rotation more frequently occurring on mandibular retropositioning and with rigid-screw fixation. Consequently, mandibular advancement usually produces greater condylar displacement than mandibular setback. Furthermore, the technique used to promote osteosynthesis and the anteroposterior direction of movement of the distal (tooth bearing) segments seem to influence the direction and magnitude of condylar displacement.

A step frequently develops at the cortical bone between the anterior aspect of the proximal segment and distal segment. Such a step was also noted in the present study. The use of a bent plate can correct this problem. An advantage to the locking screw plate system is that the amount of stability provided across the osteotomy gap is greater than when standard nonlocking screws are used.¹⁵ Therefore, the locking plate system might be adequate for our plate bending technique. Moreover, the change from initial assessment to 1 month after surgery in condylar long axis in the bicortical group was smaller than that of

the monocortical group. This might be caused by our awareness that internal rotation of the condylar long axis in the bicortical group should be prevented more than in the monocortical group. This might result in a significant difference in left condyle angle in T1.

There were no significant differences between the two groups in other measurements in T2 and T3, except for ANB in T3. It was unclear why a significant difference was found only in ANB in T3. However, we should interpret that as indicating no significant differences between the two groups in each serial period, although we expected that bicortical group using locking plate system was more rigid. This result might be affected by postoperative orthodontic treatment.

In conclusion, the results of this study demonstrated that there was no significant difference in postoperative time-course changes between bicortical plate fixation using a locking plate system and monocortical plate fixation using a conventional plate system.

References

- 1) Tucker MR: Orthognathic Surgery versus orthodontic camouflage in the treatment of mandibular deficiency. *J Oral Maxillofac Surg* 53: 572, 1995.
- 2) Scheerlinck JPO, Stoelinga PJW, Blijdorp PA, et al.: Sagittal split advancement osteotomies stabilized with miniplates. A 2-5 year follow-up. *Int J Oral Maxillofac Surg* 23: 127, 1994.
- 3) Tulasne JF, Schendel SA: Transoral placement of rigid fixation following sagittal ramus split osteotomy. *J Oral Maxillofac Surg* 47: 651, 1989.
- 4) Blomqvist JE, Isaksson S: Skeletal stability after mandibular advancement: A comparison of two rigid internal fixation techniques. *J Oral Maxillofac Surg* 52: 1133, 1994.
- 5) Choi BH, Min YS, Yi CK, et al.: A comparison the stability of miniplate with bicortical screw fixation after sagittal split setback. *Oral Surg Oral Med Oral Pathol Oral Radiol Endod* 90: 416, 2000.
- 6) Haug RH, Street CC, Goltz M: Does plate adaptation affect stability? A biomechanical comparison of locking and nonlocking plates. *J Oral Maxillofac Surg* 60: 1321, 2002.
- 7) Ellis E III, Graham J: Use of a 2.0mm locking plate/screw system for mandibular fracture surgery. *J Oral Maxillofac Surg* 60: 642, 2002.
- 8) Lazow SK, Berger JR: Transoral 2.0-mm locking miniplate fixation of mandibular fractures plus 1 week of maxillomandibular fixation: A prospective study. *J Oral Maxillofac Surg* 63: 1737, 2005.
- 9) Chiodo TA, Ziccardi VB, Janal M, et al.: Failure strength of 2.0 locking versus 2.0 conventional synthesis mandibular plates: A laboratory model. *J Oral Maxillofac Surg* 64: 1475, 2006.
- 10) Ueki K, Nakagawa K, Takatsuka S, et al.: Plate fixation after mandibular osteotomy. *Int J Oral Maxillofac Surg* 30:490, 2001.
- 11) Hammer B, Ettl D, Rahn B, et al.: Stabilization of the short sagittal split osteotomy: In vitro testing of different plate and screw configurations. *J Cranio-maxillifac Surg* 23: 321, 1995.

- 12) Righi E, Carta M, Bruzzone AA, et al.: Experimental analysis of internal rigid fixation osteosynthesis performed with titanium bone screw and plate systems. *J Cranio-maxillofac Surg* 24: 53, 1996.
- 13) Fujioka M, Hirano A, Fujii T: Complete breakage of miniplates: two unusual complication cases after sagittal split osteotomies. *J Jpn Craniomaxillofac Surg* 14: 79, 1998.
- 14) Chuong CJ, Borotikar B, Schwartz-Dabney C, et al.: Mechanical characteristics of the mandible after bilateral sagittal split ramus osteotomy: Comparing 2 different fixation techniques. *J Oral Maxillofac Surg* 63: 68, 2005.
- 15) Gutwald R, Alpert B, Schmelzeisen R: Principle and stability of locking plate. *Keio J Med* 52: 21, 2003.
- 16) Herford AS, Ellis E 3rd: Use of a locking reconstruction bone plate/screw system for mandibular surgery. *J Oral Maxillofac Surg* 56: 1261, 1998.
- 17) Klotch DW, Gal TJ, Gal RL: Assessment of plate use for mandibular reconstruction: has changing technology made a difference? *Otolaryngo Head Neck Surg* 121: 388, 1999.
- 18) Lindquist C, Soderholm AL, Salo A, et al: A comparative study on four screw-plate locking systems in sheep: A clinical and radiological study. *Int J Oral Maxillofac Surg* 30: 160, 2001.
- 19) Kirkpatrick D, Gandhi R, Van Sickels JE: Infection associated with locking reconstruction plates: A retrospective review. *J Oral Maxillofac Surg* 61: 462, 2003.
- 20) Soderholm AL, Rahn BA, Skutnabb K, et al: Fixation with reconstruction plates under critical conditions: The role of screw characteristics. *Int J Oral Maxillofac Surg* 25: 469, 1996.
- 21) Sikes JW Jr, Smith BR, Mukherjee DP, et al: Comparison of fixation strengths of locking head and conventional screws, in fracture and reconstruction models. *J Oral Maxillofac Surg* 56: 468, 1998.
- 22) Soderholm AL, Lindquist C, Skutnabb K, et al: Bridging of mandibular defects with two different reconstruction systems: An experimental study. *J Oral Maxillofac Surg* 49: 1098, 1991.

- 23) Engroff SL, Blanchaert RH Jr, Von Fraunhofer JA: Mandibulotomy fixation: A laboratory analysis. *J Oral Maxillofac Surg* 61: 1297, 2003.
- 24) Alder ME, Deahl T, Matteson SR, et al: Short-term change of condylar position after sagittal split osteotomy for mandibular advancement. *Oral Surg Oral Med Oral Pathol Oral Radiol Endod* 87: 159, 1999.
- 25) Kawamata A, Fujishita M, Nagahara K, et al: Three-dimensional computed tomography evaluation of postsurgical condylar displacement after mandibular osteotomy. *Oral Surg Oral Med Oral Pathol Oral Radiol Endod* 85: 371, 1998.
- 26) Nishimura A, Sakurada S, Iwase M, et al.: Position change in the mandibular condyle and amount of mouth opening after sagittal split ramus osteotomy with rigid or nonrigid osteosynthesis. *J Oral Maxillofac Surg* 55: 672, 1997.
- 27) Oichs MW, LaBanc JP, Dolwick MF: The diagnosis and management of concomitant dentofacial deformity and temporomandibular disorder. *Oral and Maxillofacial Surgery Clinics of North America* 2:669, 1990.
- 28) Schultes G, Gagol A, Kärcher H: Change in the dimensions of milled mandibular model after mandibular sagittal split osteotomies. *Br J Oral Maxillofac Surg* 36: 196, 1998.
- 29) Stroster TG, Pangrazio-Kulbersh V: Assessment of condylar position following bilateral sagittal split ramus osteotomy with wire fixation or rigid fixation. *Int J Adult Orthod Orthognath Surg* 9:55, 1994.

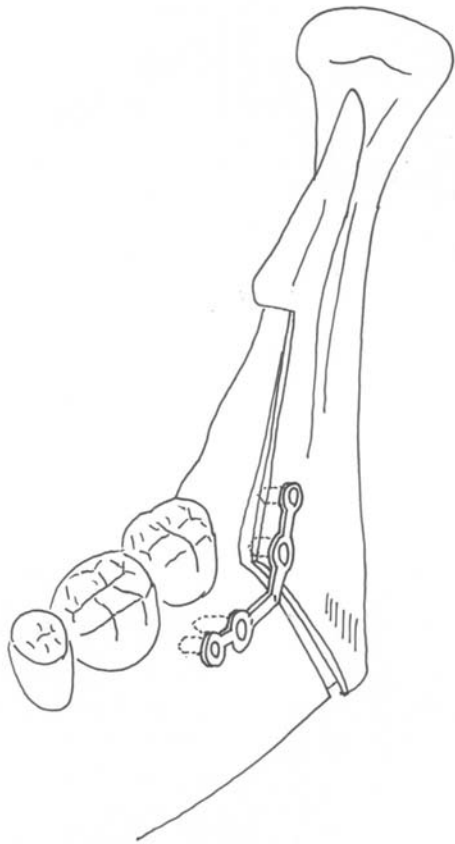
Legends

Fig. 1. Schematic drawing of the procedure and fixation in the monocortical group.
A) Monocortical group, B) Bicortical group.

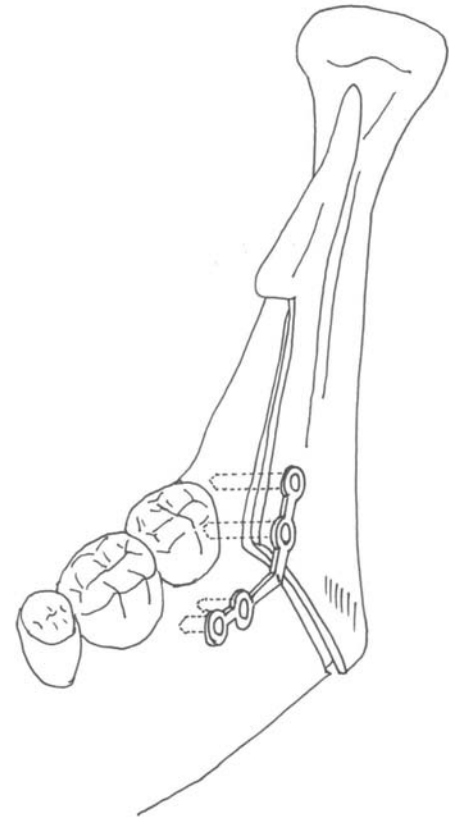
Fig. 2. Measurements in lateral cephalogram. 1: Pog-N parallel to SN, 2: Pog-N perpendicular to SN, 3: Gonial angle, 4: Ramus inclination.

Fig. 3. A) Measurements in frontal cephalogram. B) Measurements in axial cephalogram.

Table 1. Results of changes in each period. SD indicates standard deviation.

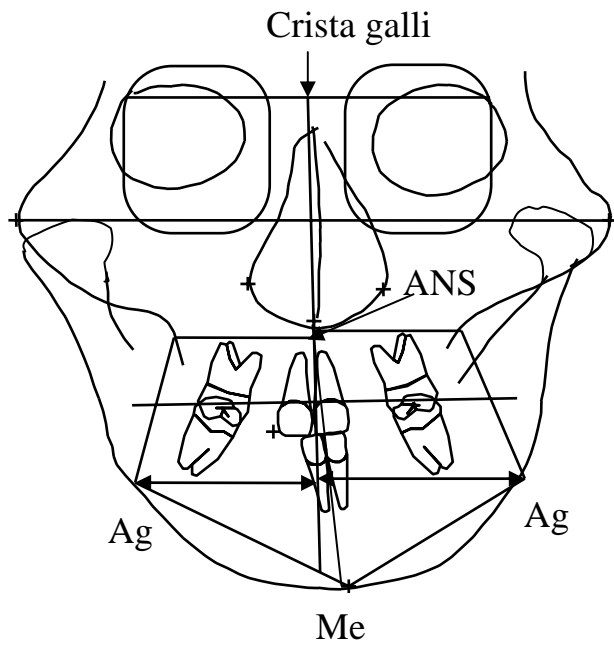


A

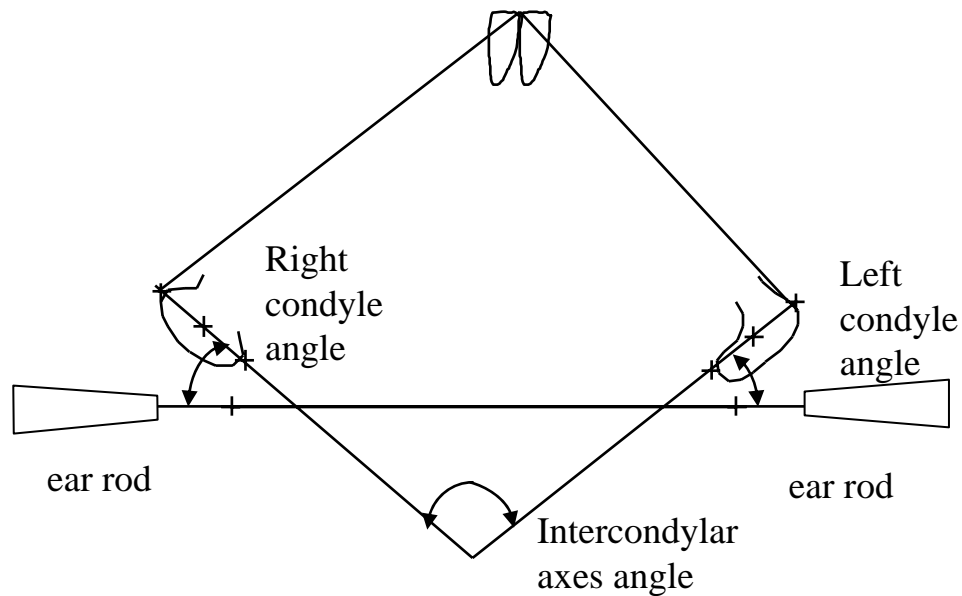


B

Fig. 1



A



B

Fig. 3

Bicortical group		T1		T2		T3	
		Mean	SD	Mean	SD	Mean	SD
Right condyle angle	(dg)	0.0	-0.6	-0.2	5.0	-0.3	-1.0
Left condyle angle	(dg)	-0.4	-1.8	-0.4	3.6	-0.2	0.3
Intercondylar axes angle	(dg)	0.5	-1.4	0.6	6.2	0.5	0.2
SNB	(dg)	-3.1	-1.3	0.5	2.3	0.0	-0.1
ANB	(dg)	2.8	-0.6	0.0	2.1	-0.3	-0.7
Gonial angle	(dg)	-3.5	0.1	-0.1	3.3	0.0	0.6
Ramus inclination(FH)	(dg)	4.1	-0.2	0.7	4.1	-1.2	-0.2
Interincisal Angle	(dg)	-0.1	8.0	-1.0	3.8	2.2	2.2
Pog-N Parallel to SN	(mm)	-1.2	-3.4	-0.7	4.2	-0.6	-0.6
Pog-N Perpend to SN	(mm)	-3.3	-0.5	-0.4	5.0	-0.5	-0.9
Occlusal Plane - SN	(dg)	0.6	-0.7	0.2	2.8	-0.5	0.4
Convexity	(mm)	2.4	-0.9	0.1	1.9	-0.5	-0.5
Me-Ag Right	(mm)	-0.8	-1.5	-1.1	4.2	0.6	1.0
Me-Ag Left	(mm)	0.7	-3.6	0.5	3.5	-1.5	-1.1

Monocortical group		T1		T2		T3	
		Mean	SD	Mean	SD	Mean	SD
Right condyle angle	(dg)	3.1	0.6	-0.5	4.5	-0.7	0.6
Left condyle angle	(dg)	3.0	1.8	1.1	5.8	0.9	1.0
Intercondylar axes angle	(dg)	-6.1	1.5	-0.6	7.3	-1.5	2.7
SNB	(dg)	-2.9	-1.3	0.4	2.2	-0.1	-0.7
ANB	(dg)	4.2	-0.8	-0.4	1.4	0.0	0.3
Gonial angle	(dg)	-2.4	-0.8	1.8	3.5	-0.1	-1.0
Ramus inclination(FH)	(dg)	3.5	0.1	-1.5	2.7	0.2	-1.0
Interincisal Angle	(dg)	2.7	7.6	-1.2	3.8	1.6	-0.3
Pog-N Parallel to SN	(mm)	-1.9	-1.8	-0.4	2.3	-0.9	0.4
Pog-N Perpend to SN	(mm)	-3.4	-0.8	0.4	2.5	1.3	-1.3
Occlusal Plane - SN	(dg)	-2.1	-2.0	-0.4	2.5	-1.0	0.5
Convexity	(mm)	3.8	-0.1	-0.2	1.7	-0.1	-0.4
Me-Ag Right	(mm)	-0.9	1.2	1.7	4.4	0.6	-0.5
Me-Ag Left	(mm)	-1.1	-1.2	1.8	5.1	0.1	0.1

Table 2.