

Prediction of myocutaneous adverse side effect
due to intra-arterial chemotherapy by
intra-arterial 99mTc-macroaggregated albumin
administration in patients with bone and
soft-tissue tumors

メタデータ	言語: eng 出版者: 公開日: 2017-10-03 キーワード (Ja): キーワード (En): 作成者: メールアドレス: 所属:
URL	http://hdl.handle.net/2297/2795

Prediction of Myocutaneous Adverse Side Effect Due to Intra-Arterial Chemotherapy by Intra-Arterial ^{99m}Tc -Macroaggregated Albumin Administration in Patients with Bone and Soft-Tissue Tumors

Junichi Taki, MD, PhD¹; Hisashi Sumiya, MD, PhD¹; Takahiro Higuchi, MD¹; Hiroyuki Tsuchiya, MD, PhD²; Koutaro Takazawa, MD²; Katsuro Tomita, MD, PhD²; and Norihisa Tonami, MD, PhD¹

¹Department of Biotracer Medicine, Kanazawa University Graduate School of Medical Sciences, Kanazawa, Japan; and

²Department of Orthopedic Surgery, Kanazawa University Graduate School of Medical Sciences, Kanazawa, Japan

In malignant bone and soft-tissue tumors, intra-arterial chemotherapy and limb-saving surgery have become popular. Myocutaneous inflammatory change and necrosis are the major local side effects of intra-arterial chemotherapy. ^{99m}Tc -macroaggregated albumin (MAA) imaging with intra-arterial tracer administration was performed to evaluate drug distribution, and the ability of ^{99m}Tc -MAA imaging to predict local side effects was assessed. **Methods:** In 24 patients, 42 ^{99m}Tc -MAA images were obtained with tracer injection through an intra-arterial catheter that was inserted into the proximal portion of the tumor-feeding artery. Abnormal uptake other than by tumor was assessed visually and quantitatively. **Results:** In visual analysis, abnormal ^{99m}Tc -MAA accumulation was observed in 21 of 42 images. In the first consecutive 13 of these 21 images, intra-arterial chemotherapy with cisplatin, doxorubicin, and caffeine was administered, and myocutaneous inflammation or necrosis in the area corresponding to the abnormal ^{99m}Tc -MAA uptake was observed in 11. In contrast, none of the 21 images without abnormal ^{99m}Tc -MAA uptake demonstrated any local adverse effect from intra-arterial chemotherapy. In the last consecutive 8 images with abnormal ^{99m}Tc -MAA uptake, intra-arterial chemotherapy was initiated with only cisplatin, and doxorubicin and caffeine administration was changed to the intravenous route. In all 8 of these images, no local adverse effects from chemotherapy were observed. Overall, the sensitivity, specificity, and accuracy of ^{99m}Tc -MAA imaging for the detection of myocutaneous damage were 100% (11/11), 91% (21/23), and 94% (32/34), respectively, and positive and negative predictive values were 85% (11/13) and 100% (21/21), respectively. In quantitative analysis, when the diagnostic threshold of the uptake ratio was set at 2.5, sensitivity, specificity, and accuracy for the detection of myocutaneous complications were 91% (10/11), 96% (22/23), and 94% (32/34), respectively, and positive and negative

predictive values were 91% (10/11) and 96% (22/23), respectively. **Conclusion:** ^{99m}Tc -MAA imaging with intra-arterial infusion before intra-arterial chemotherapy for bone and soft-tissue tumors can facilitate prediction of local myocutaneous adverse effects due to chemotherapy.

Key Words: ^{99m}Tc -macroaggregated albumin; intra-arterial chemotherapy; myocutaneous inflammatory change; drug distribution

J Nucl Med 2002; 43:1452-1456

The prognosis and quality of life of patients with malignant bone and soft-tissue tumors have improved dramatically because of advances in chemotherapy with or without radiation and limb-saving surgery (1-5). The success of preoperative chemotherapy is a key issue for the achievement of limb-saving surgery. Intra-arterial chemotherapy has therefore become popular because it can induce a favorable degree of tumor necrosis due to its pharmacokinetic advantages (1,3-7). Human studies have demonstrated that ^{195}mPt -labeled cisplatin accumulates in tumors significantly more by intra-arterial infusion than by intravenous administration, although no such differences have been observed in the pharmacokinetic profiles of the blood fractions between intravenous and intra-arterial drug administration (8).

In addition to the several side effects observed with intravenous chemotherapy, local myocutaneous inflammatory changes or necrosis or osteonecrosis can occur as complications of intra-arterial chemotherapy. Significant myocutaneous necrosis requires surgical resection, resulting in muscle weakness and limitation of the range of motion in the adjacent joint. One major cause of these complications is inappropriate drug distribution. For assessment of the distribution of an intra-arterially administered drug, intra-arterial ^{99m}Tc -macroaggregated albumin (MAA) infusion and imaging have been performed successfully in hepatic tumors (9-11).

Received Mar. 7, 2002; revision accepted Jul. 9, 2002.

For correspondence or reprints contact: Junichi Taki, MD, PhD, Department of Biotracer Medicine, Kanazawa University Graduate School of Medical Sciences, 13-1 Takara-machi, Kanazawa, 920-8640, Japan.

E-mail: taki@med.kanazawa-u.ac.jp

TABLE 1
Clinical and Scintigraphic Findings

Patient no.	Age (y)	Sex	Diagnosis	Tumor location	Extratumoral tracer uptake		Local side effect
					Visual uptake score	Uptake ratio	
1	29	M	Ewing's sarcoma	L iliac bone	No	1.00	—
2	17	M	Osteosarcoma	L distal femur	No	1.00	—
3	65	F	MFH	R distal femur	Moderate	1.84	+
4	51	M	Metastasis from lung cancer	L thigh	High	4.48	+
5	67	F	Leiomyosarcoma	R forearm	No	1.00	—
					No	1.00	—
6	62	F	MFH	R thigh	Mild	1.33	—
7	14	F	Osteosarcoma	L pelvis	No	1.00	—
					No	1.00	—
8	35	F	Osteosarcoma	R humerus	No	1.00	—
					No	1.00	—
					Mild	1.13	—
					No	1.00	—
9	36	M	Liposarcoma	L thigh	Mild	2.13	—
10	66	F	Osteosarcoma	R pelvis	High	2.91	+
11	9	M	Osteosarcoma	L femur	Moderate	2.36	—
					High	4.50	+
					No	1.00	—
12	8	M	Osteosarcoma	R femur	High	9.70	+
13	69	M	Osteosarcoma	R ilium	No	1.00	—
14	14	F	Rhabdomyosarcoma	R forearm	No	1.00	—
15	11	M	Ewing's sarcoma	L femur	Mild	2.31	—
16	52	M	MFH	L femur	High	7.37	+
					Moderate	3.40	—
					No	1.00	—
17	15	M	Eosinophilic granuloma	L acetabulum	Mild	1.41	—
18	27	M	Rhabdomyosarcoma	L first metatarsus	High	5.81	+
19	50	F	Clear cell sarcoma	R foot	Moderate	3.31	+
					Moderate	4.14	+
20	27	F	Ewing's sarcoma	R tibia	High	7.37	+
					Moderate	3.43	—*
					Moderate	2.40	—*
					High	4.34	—*
21	18	M	Osteosarcoma	R humerus	Moderate	3.64	+
22	38	M	Osteosarcoma	L distal femur	Moderate	2.73	—*
					Moderate	3.00	—*
23	49	M	Leiomyosarcoma	Sacrum	High	5.00	—*
					No	1.00	—
					No	1.00	—
24	24	F	Myxoid liposarcoma	L ankle	Moderate	2.48	—*
					Moderate	2.26	—*
					No	1.00	—

*Doxorubicin and caffeine administration were changed to intravenous route.
MFH = malignant fibrous histiocytoma.

The aim of this study was to evaluate, first, the feasibility of ^{99m}Tc -MAA imaging for the assessment of drug distribution by intra-arterial infusion of the radiopharmaceutical through the same route as intra-arterial chemotherapy and, second, the ability of ^{99m}Tc -MAA imaging to predict myo-cutaneous local complications associated with intra-arterial chemotherapy in patients with malignant bone and soft-tissue tumors.

MATERIALS AND METHODS

Twenty-four patients (14 male, 10 female; age range, 8–69 y, average age \pm SD, 36 ± 21 y) who had confirmed or suspected malignant bone and soft-tissue tumors and were scheduled for 3–5 preoperative courses of intra-arterial chemotherapy were enrolled in this study (Table 1). A total of 42 ^{99m}Tc -MAA imaging studies after intra-arterial radiopharmaceutical administration were performed.

Fifty to 100 MBq of ^{99m}Tc -MAA (0.5–1 mL) were injected slowly during 30 s to 1 min through an intra-arterial catheter that was inserted, under fluoroscopic guidance, into the proximal portion of the tumor-feeding artery for intra-arterial chemotherapy. Within 5 min of ^{99m}Tc -MAA injection, whole-body imaging was started using dual-head large-field-of-view gamma cameras equipped with low-energy, high-resolution parallel-hole collimators with a scan speed of 15 cm/min. Then, SPECT was performed to include tumor in case tracer distribution was inhomogeneous in tumor.

After the ^{99m}Tc -MAA imaging, cisplatin (120 mg/m^2) was continuously infused through the catheter for 1–2 h followed by a 48-h continuous infusion of doxorubicin (60 mg/m^2) and a 72-h infusion of caffeine (12,13).

Data Analysis

Tracer distribution distal to the ^{99m}Tc -MAA injection site was analyzed. If localized high uptake other than by tumor was observed, the uptake was assessed visually and quantitatively. In the visual analysis, uptake was graded as mild, moderate, or high. Moderate or high uptake was defined as abnormal. In the quantitative analysis, a region of interest was set manually on the area with increased tracer uptake. A background region of interest was set adjacent to the area. The uptake ratio in the area of increased uptake was calculated by dividing the count density of the area by that of the background. When no visually detectable abnormal uptake was observed, the uptake ratio was defined to be 1.0.

Statistical Analysis

Values are expressed as the mean \pm SD. Differences in uptake ratios were analyzed by an unpaired Student *t* test or ANOVA with adjustment by the Scheffé method for multiple comparisons when appropriate. *P* < 0.05 was considered statistically significant.

RESULTS

All clinical and scintigraphic findings are presented in Table 1.

In the visual analysis, abnormal ^{99m}Tc -MAA accumulation was observed in 21 of 42 images. Almost all cases of abnormal uptake (19/21) were observed proximal to the tumor. In the first consecutive 13 of these 21 cases intra-arterial chemotherapy was started without a change in the position of the catheter tip. In 11 of these 13 cases, myocutaneous inflammation or necrosis in the area corresponding to the abnormal ^{99m}Tc -MAA uptake was observed. In contrast, none of the 21 cases without abnormal ^{99m}Tc -MAA uptake demonstrated any local adverse effect of intra-arterial chemotherapy. In the last consecutive 8 cases with abnormal ^{99m}Tc -MAA uptake, intra-arterial chemotherapy was initiated with only cisplatin, and doxorubicin and caffeine administration was changed to the intravenous route to avoid local complications. In all 8 of these cases, no local adverse effects of chemotherapy were observed. Overall, after the last 8 consecutive cases with abnormal ^{99m}Tc -MAA uptake were excluded from the analysis because intra-arterial administration of doxorubicin and caffeine was changed to the intravenous route, the sensitivity, specificity, and accu-

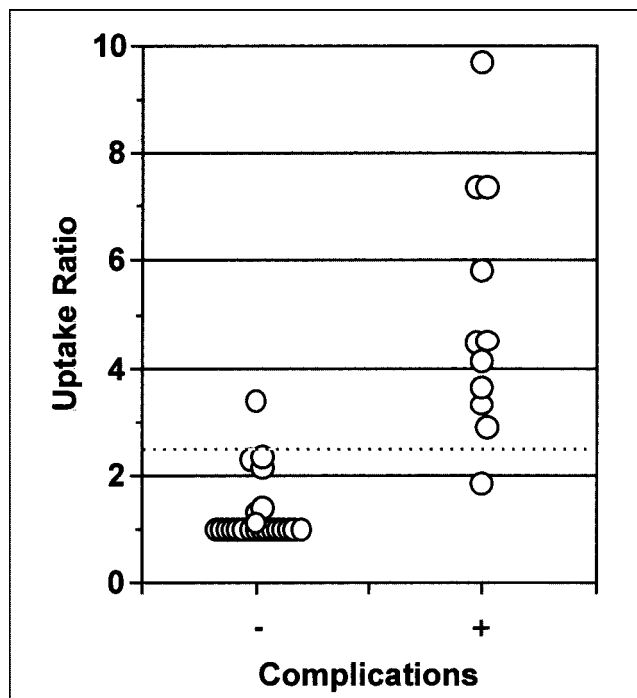


FIGURE 1. ^{99m}Tc -MAA uptake ratios were plotted for cases with and cases without myocutaneous complications. Dotted line indicates uptake ratio of 2.5.

racy of ^{99m}Tc -MAA imaging for the detection of myocutaneous damage were 100% (11/11), 91% (21/23), and 94% (32/34), respectively, and positive and negative predictive values were 85% (11/13) and 100% (21/21), respectively.

In quantitative analysis, uptake ratios in areas of mild, moderate, and high uptake were 1.66 ± 0.52 , 2.96 ± 0.66 , and 5.72 ± 2.08 , respectively. The ratios in high-uptake areas were significantly higher than the ratios in mild- ($P < 0.0001$) and moderate-uptake areas ($P < 0.005$). In Figure 1, uptake ratios were plotted in cases with and without myocutaneous complications. Uptake ratios were significantly lower in cases without complications than in cases with complications (1.31 ± 0.63 vs. 5.00 ± 2.33 , $P < 0.0001$). When the diagnostic threshold of the uptake ratio was set at 2.5, sensitivity, specificity, and accuracy for the detection of myocutaneous complications were 91% (10/11), 96% (22/23), and 94% (32/34), and positive and negative predictive values were 91% (10/11) and 96% (22/23), respectively.

^{99m}Tc -MAA, ^{201}Tl , and MR images of a 65-y-old woman with malignant fibrous histiocytoma in the right distal femur are presented in Figure 2. Abnormal local ^{99m}Tc -MAA accumulation was observed proximal to the tumor. High tumor uptake of ^{99m}Tc -MAA, indicating hypervascularity of the tumor, was also observed. Corresponding to the local ^{99m}Tc -MAA uptake, local painful redness with severe tenderness developed.

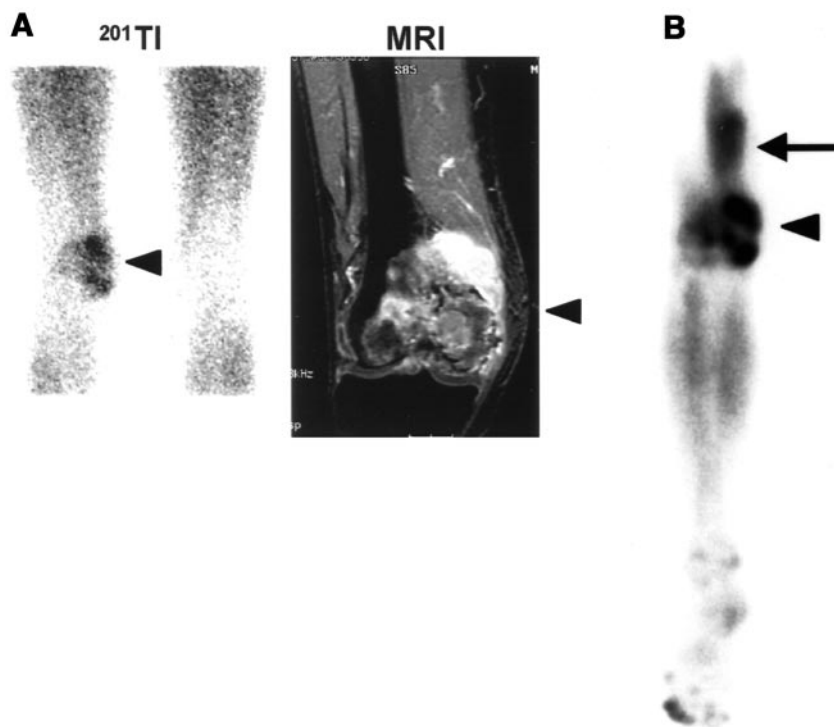


FIGURE 2. A 65-y-old woman with malignant fibrous histiocytoma in right distal femur. (A) Anterior ^{201}Tl image and coronal MR image with gadolinium enhancement demonstrate inhomogeneous ^{201}Tl uptake in tumor and inhomogeneous tumor enhancement, respectively (arrowheads). (B) Abnormal local $^{99\text{m}}\text{Tc}$ -MAA accumulation (arrow) is seen proximal to tumor. Inhomogeneous high tumor uptake of $^{99\text{m}}\text{Tc}$ -MAA, indicating heterogeneous hypervascularity of tumor, is also observed (arrowhead). Corresponding to local $^{99\text{m}}\text{Tc}$ -MAA uptake, local painful redness with severe tenderness developed after intra-arterial chemotherapy.

DISCUSSION

The present study demonstrated that abnormal uptake of $^{99\text{m}}\text{Tc}$ -MAA in normal tissue after an intra-arterial infusion predicted the local adverse effect of intra-arterial chemotherapy. Accordingly, prechemotherapeutic imaging with an intra-arterial infusion of $^{99\text{m}}\text{Tc}$ -MAA was considered to be a useful method for preventing myocutaneous inflammatory change or necrosis due to intra-arterial chemotherapy.

In this study, we hypothesized that the local myocutaneous adverse effect should occur because of the abnormally high delivery of the drugs to a particular normal tissue, resulting in exposure of the normal tissue to an excessive dose of anticancer drugs and consequent injury. Because adverse effects were observed exclusively in the particular areas with intense $^{99\text{m}}\text{Tc}$ -MAA accumulation, tissue damage was considered to be produced by an excessive concentration of the anticancer drugs. The precise mechanisms of localized high delivery or heterogeneous distribution of intra-arterial infused drug are not completely clear, although intra-arterial laminar flow of the drug due to continuous slow infusion may be responsible for the phenomenon (14). Homogeneous mixing of infused aqueous solutions injected into the artery may require some flow turbulence. If no such homogenous mixing of the drug is obtained, streaming of the drug may occur, and the drug may flow into the side branches that perfuse skin or muscles and cause undue toxicity in nontarget tissues as well as suboptimal tumor response. In some cases, before mixing of the drug in the artery, the solution with a high drug concentration may flow

into side branches that perfuse nontarget tissues. In almost all cases, abnormally high delivery of $^{99\text{m}}\text{Tc}$ -MAA was observed proximal to the tumor. It seems likely that turbulent flow distal to the tumor would counteract such streaming effects.

Our study demonstrated that if abnormally high uptake of $^{99\text{m}}\text{Tc}$ -MAA in normal tissues was observed, myocutaneous adverse effects would be prevented by changing the route of doxorubicin administration to intravenous while continuing with intra-arterial cisplatin administration. This contention is supported by evidence of the extreme toxicity of doxorubicin to soft tissues when it is administered intra-arterially. To avoid local side effects, repositioning of the catheter by withdrawing it several centimeters may be effective when extratumoral abnormally high uptake is observed. In this situation, whether additional $^{99\text{m}}\text{Tc}$ -MAA imaging with a larger dose offers reliable diagnostic information in spite of the previously administered tracer activity remains to be elucidated.

CONCLUSION

$^{99\text{m}}\text{Tc}$ -MAA imaging with an intra-arterial infusion before intra-arterial chemotherapy for bone and soft-tissue tumors can facilitate prediction of local myocutaneous adverse effects due to chemotherapy. When extratumoral abnormally high uptake of $^{99\text{m}}\text{Tc}$ -MAA is observed, modification of doxorubicin administration from the intra-arterial to the intravenous route is recommended to avoid local side effects.

REFERENCES

1. Jaffe N, Knapp J, Chuang VP, et al. Osteosarcoma: intra-arterial treatment of the primary tumor with cis-diammine-dichloroplatinum II (CDP)—angiographic, pathologic, and pharmacologic studies. *Cancer*. 1983;51:402–407.
2. Eilber FR, Eckhardt J, Morton DL. Advances in the treatment of sarcomas of the extremity: current status of limb salvage. *Cancer*. 1984;54:2695–2701.
3. Kempf RA, Irwin LE, Menendez L, et al. Limb salvage surgery for bone and soft tissue sarcoma: a phase II pathologic study of preoperative intraarterial cisplatin. *Cancer*. 1991;68:738–743.
4. Petrilli AS, Gentil FC, Epelman S, et al. Increased survival, limb preservation, and prognostic factors for osteosarcoma. *Cancer*. 1991;68:733–737.
5. Tsuchiya H, Tomita K, Mori Y, et al. Caffeine-assisted chemotherapy and minimized tumor excision for nonmetastatic osteosarcoma. *Anticancer Res*. 1998;18:657–666.
6. Bacci G, Picci P, Ruggieri P, et al. Primary chemotherapy and delayed surgery (neoadjuvant chemotherapy) for osteosarcoma of the extremities: the Istituto Rizzoli Experience in 127 patients treated preoperatively with intravenous methotrexate (high versus moderate doses) and intraarterial cisplatin. *Cancer*. 1990;65:2539–2553.
7. Kashdan BJ, Sullivan KL, Lackman RD, et al. Extremity osteosarcomas: intraarterial chemotherapy and limb-sparing resection with 2-year follow-up. *Radiology*. 1990;177:95–99.
8. Shani J, Bertram J, Russell C, et al. Noninvasive monitoring of drug biodistribution and metabolism: studies with intraarterial Pt-195m-cisplatin in humans. *Cancer Res*. 1989;49:1877–1881.
9. Miller DL, Schneider PD, Gianola FJ, Willis M, Vermess M, Doppman JL. Assessment of perfusion patterns during hepatic artery infusion chemotherapy: EOE-13 CT and ^{99m}Tc-MAA scintigraphy. *AJR*. 1984;143:827–831.
10. Ziessman HA, Thrall JH, Yang PJ, et al. Hepatic arterial perfusion scintigraphy with Tc-99m-MAA: use of a totally implanted drug delivery system. *Radiology*. 1984;152:167–172.
11. Ziessman HA, Wahl RL, Juni JE, et al. The utility of SPECT for ^{99m}Tc-MAA hepatic arterial perfusion scintigraphy. *AJR*. 1985;145:747–751.
12. Tsuchiya H, Tomita K, Mori Y, Asada N, Yamamoto N. Marginal excision for osteosarcoma with caffeine assisted chemotherapy. *Clin Orthop*. 1999;358:27–35.
13. Tsuchiya H, Morinaga T, Taki J, Sumiya H, Matsui O, Tomita K. Effect of myocutaneous inflammatory changes caused by intra-arterial chemotherapy on the outcome of patients who undergo limb-saving surgery. *Cancer*. 2001;91:2447–2453.
14. Blacklock JB, Wright DC, Dedrick RL, et al. Drug streaming during intra-arterial chemotherapy. *J Neurosurg*. 1986;64:284–291.

