

Prognostic factors for squamous cell carcinoma of the temporal bone: Extensive bone involvement or extensive soft tissue involvement?

メタデータ	言語: eng 出版者: 公開日: 2017-10-03 キーワード (Ja): キーワード (En): 作成者: メールアドレス: 所属:
URL	http://hdl.handle.net/2297/19813

2008/ 11/ 16

Prognostic Factors for Squamous Cell Carcinoma of the Temporal Bone:

Extensive Bone Involvement or Extensive soft tissue involvement?

By

Makoto Ito, MD, PhD*, Miyako Hatano, MD, PhD and Tomokazu Yoshizaki, MD, PhD

Department of Otolaryngology-Head and Neck Surgery, Division of
Neuroscience, Kanazawa University Graduate School of Medical Science,
Kanazawa, Japan

Text pages: 13

Figures: 6

Tables: 2

Running Head: Prognostic Factors of Temporal Bone SCC

*Address correspondence and reprint requests to: Dr. Makoto Ito, MD, PhD.

Department of Otolaryngology Head and Neck Surgery, Division of
Neuroscience, Kanazawa University Graduate School of Medical Science,

13-1 Takaramachi, Kanazawa, Ishikawa 920-8640, JAPAN

Telephone: 76-265-2413, FAX: 76-234-4265

E-mail: makoto@med.kanazawa-u.ac.jp

Acknowledgements

This study was supported by a Grant-in-Aid for Scientific Research from the Ministry of Education, Science, Sports and Culture of Japan (#19591961)

Word count: 2482

Key words: external auditory canal; middle ear; squamous cell carcinoma; prognostic factor; bone involvement; soft tissue involvement; surgical resection; facial paralysis

This study was presented at the 8th International Conference on Cholesteatoma and Ear Surgery (Turkey, 2008).

ABSTRACT

Conclusion: Extensive bone erosion correlated with a worse prognosis of the squamous cell carcinoma (SCC) of the temporal bone but extensive soft tissue involvement did not correlate with prognosis in this study. Resectability of the tumor seems to be major prognostic factors of temporal bone SCC.

Objective: Prognostic factors for SCC of the temporal bone were evaluated regarding initial clinical symptoms and radiographic imaging.

Methods: Clinical symptoms of the patients with primary SCC of the external auditory canal (EAC) or middle ear (ME) were reviewed based on medical records. Correlation of clinical symptoms and cancer severity staging using the modified Pittsburgh classification was analyzed, along with disease-specific survival (DSS).

Results: Sixteen patients with primary SCC of the EAC (n=13) or ME (n=3) were included in the study population. Disease-specific survival was not influenced by whether a hearing disturbance or otalgia was noted at the first medical examination. Extended bone involvement identified with imaging studies significantly correlated with worse prognosis ($p < 0.05$). Prognoses of patients without extensive bone erosion were

well and extensive (≥ 0.5 cm) soft tissue involvement did not correlate with prognosis in this study. Prognoses of patients with insufficient bone resection or no surgery were significantly poor ($p < 0.01$).

Key words: external auditory canal; middle ear; squamous cell carcinoma; prognostic factor; bone involvement; surgical resection

LIST OF ABBREVIATIONS

squamous cell carcinoma (SCC), disease-specific survival (DSS), local canal resection (LCR), lateral temporal bone resection (LTBR), subtotal temporal bone resection (STBR), external auditory canal (EAC), middle ear (ME), hearing disturbance (HD), computed tomography (CT), magnetic resonance imaging (MRI), positron emission tomography (PET)

MANUSCRIPT TEXT

INTRODUCTION

Squamous cell carcinoma (SCC) is the most frequent primary malignant tumor of the temporal bone, but the incidence is as rare as <0.2% of all tumors of the head and neck.[1] It is a rare, but threateningly aggressive, tumor with poor prognosis. Many publications have tried to evaluate survival in this aggressive disease, but patient numbers are limited (ranging from 10 to 39 patients, with most <30 patients), and surveillance periods are too long (ranging from 10 to 37 years, with most >15 years), possibly due to the rarity of this disease.[1-9] The quality of imaging studies (Computed tomography (CT) and magnetic resonance imaging (MRI)) has improved dramatically over time, and the accuracy of diagnosis of this disease is influenced by the quality of imaging. Similar reports contain many patients, but they are multi-institutional retrospective studies, with the surgical procedure and the surgeon different at each institution and surveillance periods are too long (>20 years).[10, 11] By chance, we had experience with 16 cases of primary SCC of the temporal bone over 6 years (from 2001 to 2006). Because it was a brief surveillance period, the qualities of the imaging studies

were similar and the same surgeon performed all surgical procedures. The University of Pittsburgh staging system[12] is most common classification tool for temporal bone SCC, and we followed the modified version of this classification for these patients[1]. Although many previous reports conclude that long-term prognosis of temporal bone SCC depends mainly on staging and primary treatment[1, 4, 5], there is no universally accepted staging system for temporal bone SCC. Due to the limited database for this tumor type, it has been difficult to determine any correlation between the clinical conditions, clinical symptoms and the extent of the lesion, and prognosis. In the present study, we try to evaluate the prognostic factors associated with the survival rate for SCC of the temporal bone.

MATERIALS AND METHODS

A retrospective case review was performed on all patients receiving treatment of SCC of the external auditory canal or middle ear at Kanazawa University Hospital (Kanazawa, Japan) from 2001 to 2006. The observation duration for survival was defined as ≥ 30 months after diagnosis. Clinical symptoms before treatment were identified based on patient medical records. The extent of the lesion was estimated for all patients through

imaging study and physical examination findings. Computed tomography and MRI were routinely conducted and positron emission tomography (PET) was carried out in some cases. Bone invasion and soft tissue involvement were determined by CT scan and MRI, respectively. Regional lymph node swelling and distant metastases were distinguished by PET scan. Tumors of the external auditory canal (EAC) and middle ear (ME) were staged according to the University of Pittsburgh staging system (Moody's modified) for malignancies of the EAC (for definitions, see Table 1).[1, 12] All tumors of the ME were classified into T4 stage because tumors were eroding deep parts of the temporal bone.

The surgical resection we performed most often was lateral temporal bone resection (LTBR) (n=10). In cases of LTBR, the bony and cartilaginous portions of the EAC, including the anterior bony EAC, were removed *en bloc*. All surgical procedures were performed by the same surgeon (Ito.M). Lateral temporal bone resection was performed combined with radiation therapy for the tumors that remained lateral to the tympanic membrane. All patients with T2 and T3 diseases received LTBR. Lateral temporal bone resection was also performed for some patients with T1 and T4 disease;

one T1 case (No.2) had tumor located in the deep part of EAC, two T4 cases (No.10 and 11) had limited external auditory canal bony erosion but had extensive (≥ 0.5 cm) soft tissue involvement, and other two T4 cases (No.12 and 13) required extensive gross tumor removal.

CT, MRI, and/or PET were routinely carried out every 6 months for up to 3 years after treatment. Because scar tissue after surgery or irradiation was often hard to differentiate from recurrent SCC, we distinguished them by using size enlargement of a space-occupying lesion. Clinical outcomes included the occurrence and timing of any recurrence (local, regional lymph node, or distant metastasis), the last follow-up date, and death. Disease-specific survival (DSS) rates were determined using the Kaplan-Meier method and the log-rank test was applied to compare survival outcomes. The correlation of clinical symptoms before treatment and T staging in the Pittsburgh classification with DSS was analyzed statistically. P-values < 0.05 were considered statistically significant.

RESULTS

The medical records for a total of 16 patients with the primary SCC of the EAC (n=13)

and ME (n=3) were reviewed retrospectively (Table 2). There were 7 males and 9 females, ranging in age from 41 to 83 years, and the mean age at first visit for the population was 64 ± 13.8 years. The distribution of T stages for primary tumors was T1: 3, T2: 2, T3: 3, and T4: 8. All ME diseases (Nos.9, 14, 15) were classified into T4 stage in the present study. One patient (No.12) in the T4 group had regional lymph node involvement. The most common presenting symptoms were otorrhea (15 patients: 93.7%), otalgia (12 patients: 75.0%), and hearing disturbance (10 patients: 62.5%). Disease-specific survival was not influenced by whether otalgia or hearing disturbance (HD) were present at the time of the diagnosis (Figures 1 and 2).

One patients with T1 tumors received LTBR alone because the tumor was located in the deep part of the EAC. Two other T1 patients received local canal wall resection (LCR). Ten patients (one T1, all T2 and T3, and four T4) received LTBR. Three patients with T4 disease received chemo-radiation therapy alone because tumors showed extensive dura matter and major vessels invasions. Eleven patients received radiation therapy combined with surgery. One patient (No.5, T2) received subtotal temporal bone resection (STBR) after postoperative radiotherapy because of local tumor

recurrence. Another one patient (No.9, T4) received STBR. Six patients in the T4 group and all patients in the T3 group showed extensive bone involvement, including T4 with bone erosion of the deep temporal bone and T3 with apparent bone erosion of the external auditory canal and/or tumor involving the middle ear cavity. Extensive bone involvement significantly correlated with a worse prognosis (Figure 3, $p < 0.05$). There were three patients (Nos.14 to 16) with dural involvement and four patients (Nos.13 to 16) with major vessels invasion. The prognoses of all these patients with erosion of the deep temporal bone were quite poor. On the other hand, other two patients in the T4 group (No.10 and 11) showed extensive (≥ 0.5 cm) soft tissue involvement but limited bone erosion and the prognoses of these two T4 cases (No.10 and 11) were quite well. Extensive (≥ 0.5 cm) soft tissue involvement (four T4 cases) did not correlate with a worse prognosis in this study (Figure 4). Disease-specific survival comparing patients in the early stage group (T1-T2) with the advanced stage group (T3-T4) are shown in Figure 5. Kaplan-Meier analysis demonstrated that there was no statistically significant difference in DSS for patients with early stage versus advanced stage diagnoses.

Facial nerve paralysis was found in 3 patients (Nos.14, 15 and 16) and these

three patients were classified into T4 because of extensive bone involvement with Pittsburgh staging system; i.e. dural involvement and major vessels invasion, and their prognoses were quite poor, with survival times not longer than 12 months. In addition to the facial nerve paralysis, bone destruction of the fallopian canal was detected in three patients who did not show facial paralysis (No. 8 in T3 and Nos. 12 and 13 in T4). We performed LTBR for these three patients, one male patient (No.8) received additional facial nerve resection and other two female patients (No.12 and 13) refused resection of the facial nerve, and surgical margins of these three patients were positive. Then these patients received post-operative radiation therapy. They showed facial paralysis at the time of local recurrences and their survival times were not longer than 28 months. Within these three patients, one patient (No. 8 in T3) represented tumor eroding the osseous external auditory canal (full-thickness) and the fallopian canal then we performed LTBR. Unfortunately the pathological diagnosis after surgery showed tumor invasion into the mastoid and the deep temporal bone. One patient (No. 12 in T4) represented tumor eroding the jugular foramen and we recommended STBR but she refused resection of the facial nerve and STBR. It might be better to choose STBR

instead of LTBR for these two patients. Another one patient (No. 13) showed carotid canal bone involvement so that we did not recommend surgery but patient asked us gross tumor removal before radiotherapy.

In contrast, there were other four advanced stage patients (Nos. 6, 7 in T3 and Nos. 10, 11 in T4) without extensive bone destruction of the deep temporal bone. They received complete LTBR and surgical margins were negative. The prognoses of these four patients were quite well, no disease over 32 months. Another one patient in ME tumor (No. 9 in T4) received STBR and her prognosis was well. Among the total 16 patients, 7 patients died of disease. Six patients underwent insufficient / no surgery and all of them died of disease. On the other hand, only one patient died of disease among 10 patients who underwent total tumor removal (Figure 6, $p < 0.01$). Resectability of the tumor was strongly related to the prognosis in this study.

DISCUSSION

Management of SCC of the temporal bone remains challenging for ear and skull base surgeons due to the proximity of the dura mater and the nearby neural and vascular structures. These rare malignant tumors involve the anatomically complicated temporal

bone and the lack of universally accepted cancer staging system makes treatment planning challenging. Clearly, surgery combined with or without radiotherapy is widely accepted as the standard of treatment and previous reports found that radiotherapy alone or salvage surgery after radiotherapy had depressingly poor prognoses.[1, 4, 5] However, the results of these previous studies are limited by the small number of patients involved and too long periods of time required to collect these cases. Long periods of surveillance resulted in different qualities in imaging studies used for staging and different surgical techniques. Many factors make it difficult to get clear information from the literature regarding prognosis and optional treatment of temporal bone SCC. We report here 16 cases of primary SCC of the temporal bone within a brief surveillance period (6-years). The quality of the imaging studies was similar and the same surgeon performed all surgical procedures in this study.

The University of Pittsburgh staging system for primary SCC of the external auditory canal was proposed in 1990 as a straightforward and precise system for classifying disease before treatment.[12] It is now the most common classification system and endorsed by many reports in the literature.[1-8, 10] Although extensive

(≥ 0.5 cm) soft tissue involvement was considered as T4 disease in Pittsburgh staging system, one of the main findings in the present study was that extensive bone involvement significantly correlated with a worse prognosis but extensive (≥ 0.5 cm) soft tissue involvement did not correlate with prognosis. Radiotherapy combined with surgery may be effective in cases with such soft tissue diseases. We decide the surgical procedure according to the expansion of bone involvement. Our treatment strategy of the surgical procedure for the temporal bone SCC is followings; LCR for T1 disease except tumor located in the deep part of the EAC, LTBR for T1 with tumor located in the deep part of the EAC, all T2 diseases and T3 with tumor eroding the osseous external auditory canal, STBR for T3 disease with tumor involving middle ear and/or mastoid and a part of T4 disease such as restricted bone involvement of medial wall of middle ear or jugular foramen. T4 disease with extensive soft tissue involvement but limited bone erosion is treated as same as above treatment strategy according to the bone involvement.

Although many of the previous reports concluded that early stage group (T1-2) had better survival and recurrence outcome compare to advanced stage group

(T3-4), some reports failed to find statistically significant differences between these two groups.[6] In the present study, there was no statistically significant difference between these two groups. The lack of significant differences in our population was probably due to the small number of patients in the early stage group (n=5), but another possibility was due to the good prognoses of two T4 cases (No.10 and 11) with extensive (≥ 0.5 cm) soft tissue involvement but limited external auditory canal bony erosion, they were alive without disease. Moore et al also failed to find significant difference between early stage group (T1-2) and advanced stage group (T3-4), with the majority of their T4 cases being classified as such because of extensive soft tissue involvement.[6] Because extensive bone erosion, but not extensive soft tissue involvement, significantly correlated with a worse prognosis in this study, further investigations to elucidate a universal staging system must be continued.

The University of Pittsburgh staging system was modified in 2000 to reflect the opinion that facial nerve paralysis indicated a prognosis comparable to that of T4 disease.[1] Although this modification has not been evaluated in some other studies[2, 8], our data confirm its utility in the present study. The prognoses of the three patients

(No.14, 15 and 16) who presented with facial nerve paralysis before treatment were quite poor, and their survival times were no longer than 12 months. Our results support the accuracy of the Moody's modification[1] of the University Pittsburgh staging system for SCC of the temporal bone. In addition to the facial nerve paralysis, other three patients (No.8, 12 and 13) with bone destruction of the fallopian canal in the imaging studies before treatment also showed poor prognosis, their survival times were no longer than 28 months. These three patients underwent insufficient bone resections. Within these three patients, two patients (Nos. 8 and 12) might have had better prognosis if they received STBR instead of LTBR. Six in the 7 patients who died of disease underwent insufficient / no surgery. On the other hand, only one patient died of disease among 10 patients who underwent total tumor removal. Complete resection of the tumor might be most important prognostic factor for the treatment of the temporal bone SCC.

CONCLUSIONS

Extensive bone erosion significantly correlated with worse prognosis but extensive soft tissue involvement did not correlate with prognosis in this study. The modification of

the University of Pittsburgh staging system[1] to include facial nerve paralysis as a prognostic factor of T4 stage represents an acceptable staging system for primary SCC of the temporal bone. The prognoses for patients with facial nerve paralysis at the first medical examination are quite poor and comparable to that of T4 disease. The prognoses for patients with insufficient resection are also quite poor. Complete resection of the tumor seems to be one of the most important prognostic factors of the temporal bone SCC.

REFERENCES

- [1] Moody SA, Hirsch BE, Myers EN. Squamous cell carcinoma of the external auditory canal: an evaluation of a staging system. *Am J Otol* 2000;21(4):582-8.
- [2] Moffat DA, Wagstaff SA, Hardy DG. The outcome of radical surgery and postoperative radiotherapy for squamous carcinoma of the temporal bone. *Laryngoscope* 2005;115(2):341-7.
- [3] Zhang B, Tu G, Xu G, Tang P, Hu Y. Squamous cell carcinoma of temporal bone: reported on 33 patients. *Head Neck* 1999;21(5):461-6.
- [4] Kunst H, Lavieille JP, Marres H. Squamous cell carcinoma of the temporal bone: results and management. *Otol Neurotol* 2008;29(4):549-52.
- [5] Nyrop M, Grontved A. Cancer of the external auditory canal. *Arch Otolaryngol Head Neck Surg* 2002;128(7):834-7.
- [6] Moore MG, Deschler DG, McKenna MJ, Varvares MA, Lin DT. Management outcomes following lateral temporal bone resection for

ear and temporal bone malignancies. *Otolaryngol Head Neck Surg* 2007;137(6):893-8.

- [7] Gillespie MB, Francis HW, Chee N, Eisele DW. Squamous cell carcinoma of the temporal bone: a radiographic-pathologic correlation. *Arch Otolaryngol Head Neck Surg* 2001;127(7):803-7.
- [8] Nakagawa T, Kumamoto Y, Natori Y, Shiratsuchi H, Toh S, Kakazu Y, et al. Squamous cell carcinoma of the external auditory canal and middle ear: an operation combined with preoperative chemoradiotherapy and a free surgical margin. *Otol Neurotol* 2006;27(2):242-8; discussion 249.
- [9] Pensak ML, Gleich LL, Gluckman JL, Shumrick KA. Temporal bone carcinoma: contemporary perspectives in the skull base surgical era. *Laryngoscope* 1996;106(10):1234-7.
- [10] Yin M, Ishikawa K, Honda K, Arakawa T, Harabuchi Y, Nagabashi T, et al. Analysis of 95 cases of squamous cell carcinoma of the external and middle ear. *Auris Nasus Larynx* 2006;33(3):251-7.

- [11] Ogawa K, Nakamura K, Hatano K, Uno T, Fuwa N, Itami J, et al. Treatment and prognosis of squamous cell carcinoma of the external auditory canal and middle ear: a multi-institutional retrospective review of 87 patients. *Int J Radiat Oncol Biol Phys* 2007;68(5):1326-34.
- [12] Arriaga M, Curtin H, Takahashi H, Hirsch BE, Kamerer DB. Staging proposal for external auditory meatus carcinoma based on preoperative clinical examination and computed tomography findings. *Ann Otol Rhinol Laryngol* 1990;99(9 Pt 1):714-21.

FIGURE LEGENDS and TABLE

Figure 1:

Kaplan-Meier survival curves of DSS for the patients with or without otalgia.

Figure 2:

Kaplan-Meier survival curves of DSS for the patients with or without hearing disturbance.

Figure 3:

Kaplan-Meier survival curves of DSS for patients with or without extensive bone involvement. A statistically significant increase was seen in OS and DSS of those patients with extensive bone involvement ($P < 0.05$).

Figure 4:

Kaplan-Meier survival curves of DSS for patients with or without extensive (≥ 0.5 cm) soft tissue involvement.

Figure 5:

Kaplan-Meier survival curves of DSS for early stage group (T1-2) and advanced stage group (T3-4).

Figure 6:

Kaplan-Meier survival curves of DSS for complete tumor removal cases and insufficient / no surgery cases.

Table 1:

University of Pittsburgh staging system for Squamous Cell Carcinoma of the external auditory canal

Table 2:

Summary of 16 patients with Squamous Cell Carcinoma of the temporal bone

Table 1. University of Pittsburgh staging system (Moody's modified) for Squamous Cell Carcinoma of the external auditory canal

T status

T1: tumor limited to the external auditory canal without bony erosion or evidence of soft tissue involvement

T2: tumor with limited external auditory canal bony erosion (not full-thickness), or limited (<0.5 cm) soft tissue involvement

T3: tumor eroding the osseous external auditory canal (full-thickness) with limited (<0.5 cm) soft tissue involvement, or tumor involving middle ear and/or mastoid

T4: tumor eroding the cochlea, petrous apex, medial wall of middle ear, carotid canal, jugular foramen, or dura, or with extensive (≥ 0.5 cm) soft tissue involvement, such as involvement of temporomandibular joint or styloid process, or evidence of facial paresis

N status

Lymph node involvement is a poor prognostic sign; any node involvement should automatically be considered as advanced stage, ie, T1N1 = stage III and T2, 3, 4 N1 = stage IV

M status

Distant metastases indicate a very poor prognosis and should be considered as stage IV disease

In the absence of metastatic lymph nodes or distant metastases, T status of the tumor defines the clinical stage

Table 2. Summary of 16 Patients With Squamous Cell Carcinoma of the Temporal Bone

Patient No.	Location	Age	Sex	Stage	Extensive Bone Involvement	Extensive Soft tissue involvement	Facial Paralysis	Treatment	Resection	Surgical margin	Outcome	Follow-up, mo
1	EAC	79	M	T1N0	No	No	No	S+XRT	LCR	—	ND	87
2	EAC	77	F	T1N0	No	No	No	S	LTBR	—	ND	44
3	EAC	74	F	T1N0	No	No	No	S+XRT	LCR	—	ND	38
4	EAC	49	M	T2N0	No	No	No	S+XRT	LTBR	—	ND	30
5	EAC	55	F	T2N0	No	No	No	S+XRT	LTBR	—	DOD	17
6	EAC	69	M	T3N0	Yes	No	No	S+XRT	LTBR	—	ND	65
7	EAC	63	M	T3N0	Yes	No	No	S+XRT	LTBR	—	ND	33
8	EAC	70	M	T3N0	Yes	No	No	S+XRT	LTBR	+	DOD	28
9	ME	72	F	T4N0	Yes	Yes	No	S	STBR	—	ND	60
10	EAC	39	M	T4N0	No	Yes	No	S+XRT	LTBR	—	ND	47
11	EAC	50	F	T4N0	No	Yes	No	S+XRT	LTBR	—	ND	32
12	EAC	60	F	T4N1	Yes	Yes	No	S+XRT	LTBR	+	DOD	21
13	EAC	41	F	T4N0	Yes	No	No	S+XRT	LTBR	+	DOD	13
14	ME	83	F	T4N0	Yes	No	Yes	XRT	—	—	DOD	12
15	ME	65	M	T4N0	Yes	No	Yes	XRT	—	—	DOD	12
16	EAC	78	F	T4N0	Yes	No	Yes	XRT	—	—	DOD	8

EAC, external auditory canal; ME, middle ear; S, Surgery; XRT, Radiation therapy; LTBR, lateral temporal bone resection; LCR, Local canal resection; STBR, subtotal temporal bone resection; ND, no disease; DOD, dead of disease

Extensive bone involvement: all T3 and T4 bone diseases, Extensive soft tissue involvement: T4 soft tissue disease

Figure 1: Otalgia

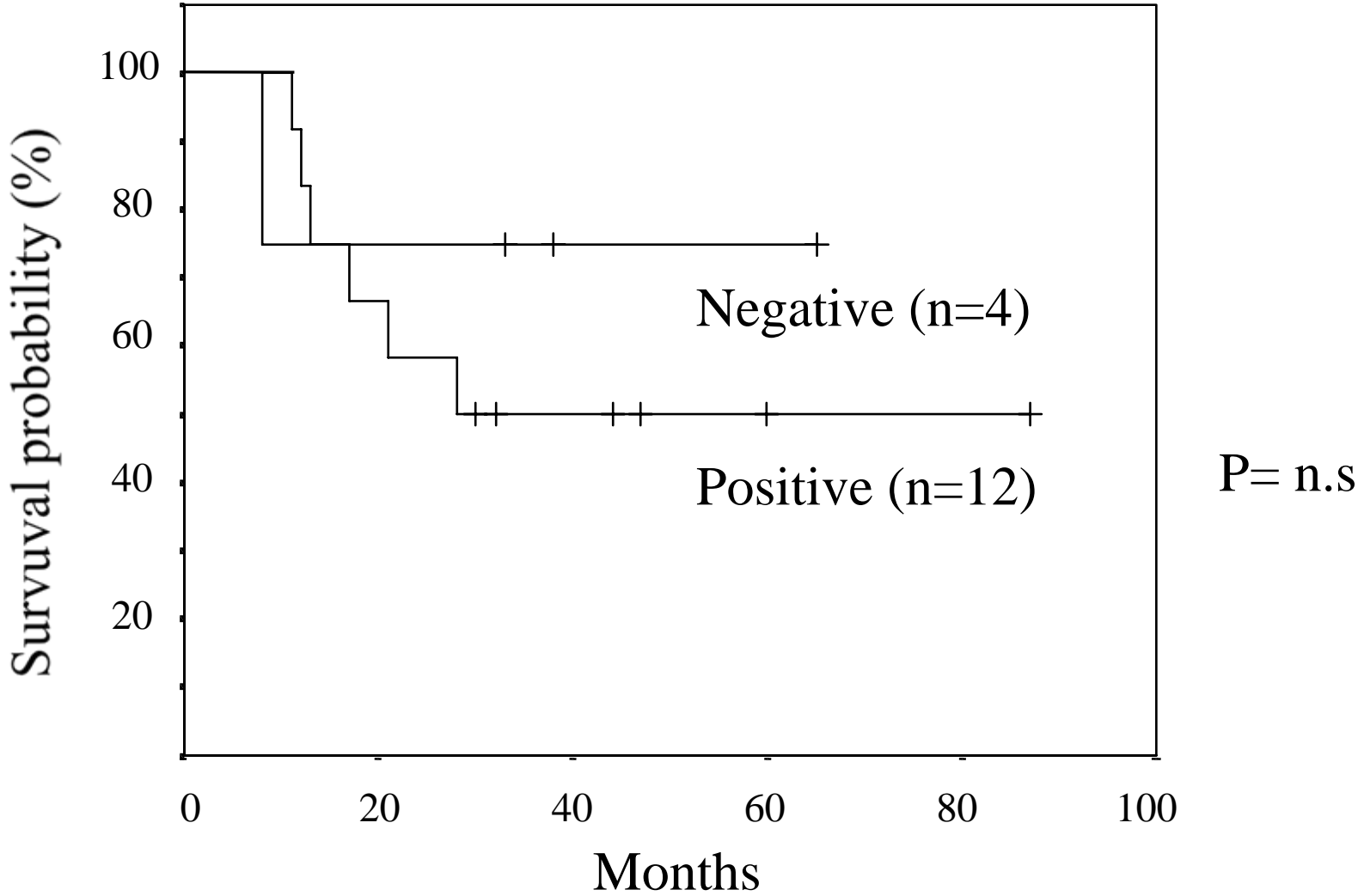


Figure 2: Hearing Disturbance

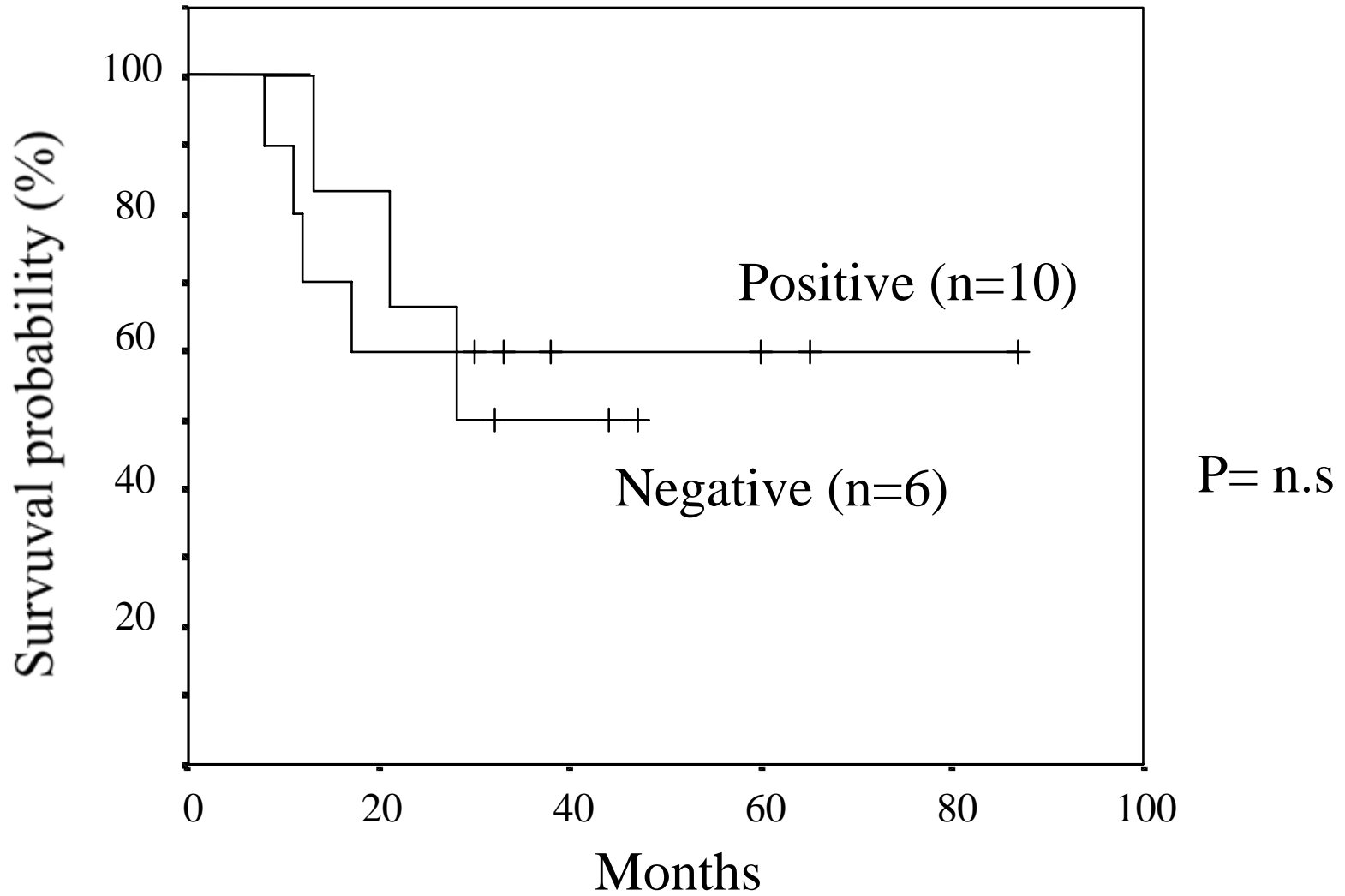


Figure 3: Extensive Bone Involvement

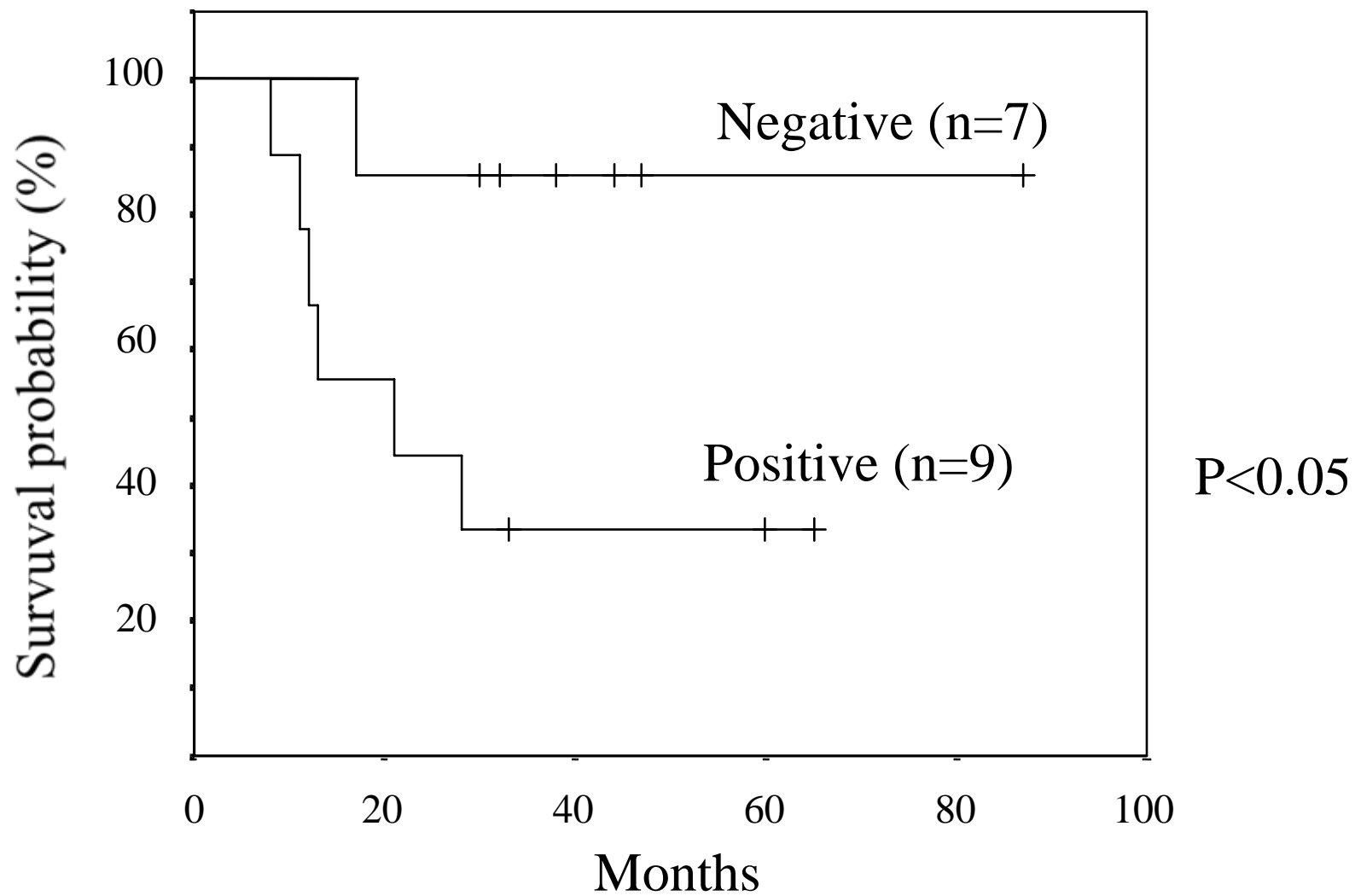


Figure 4: Extensive Soft Tissue Involvement

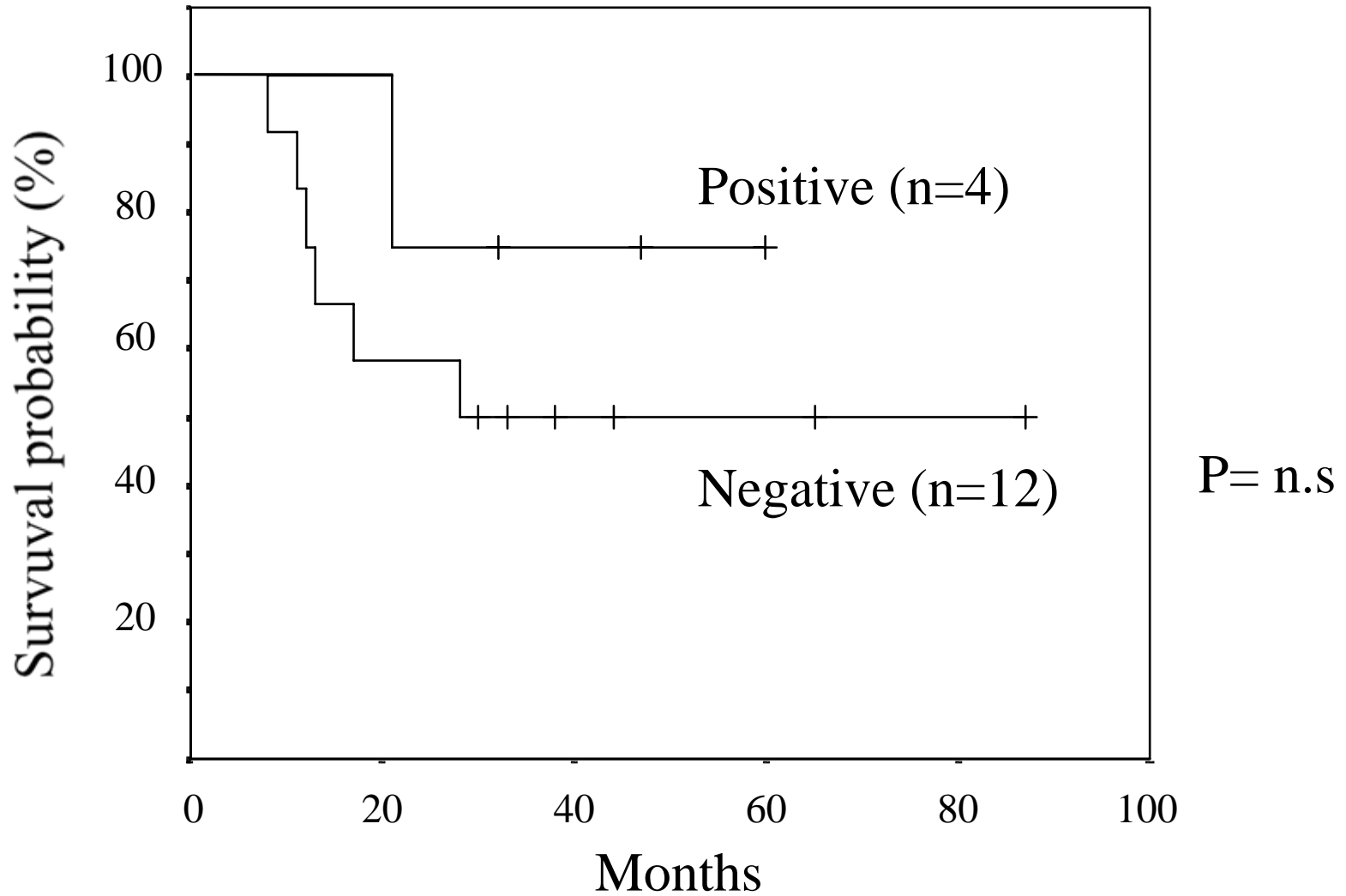


Figure 5: Early vs Advanced

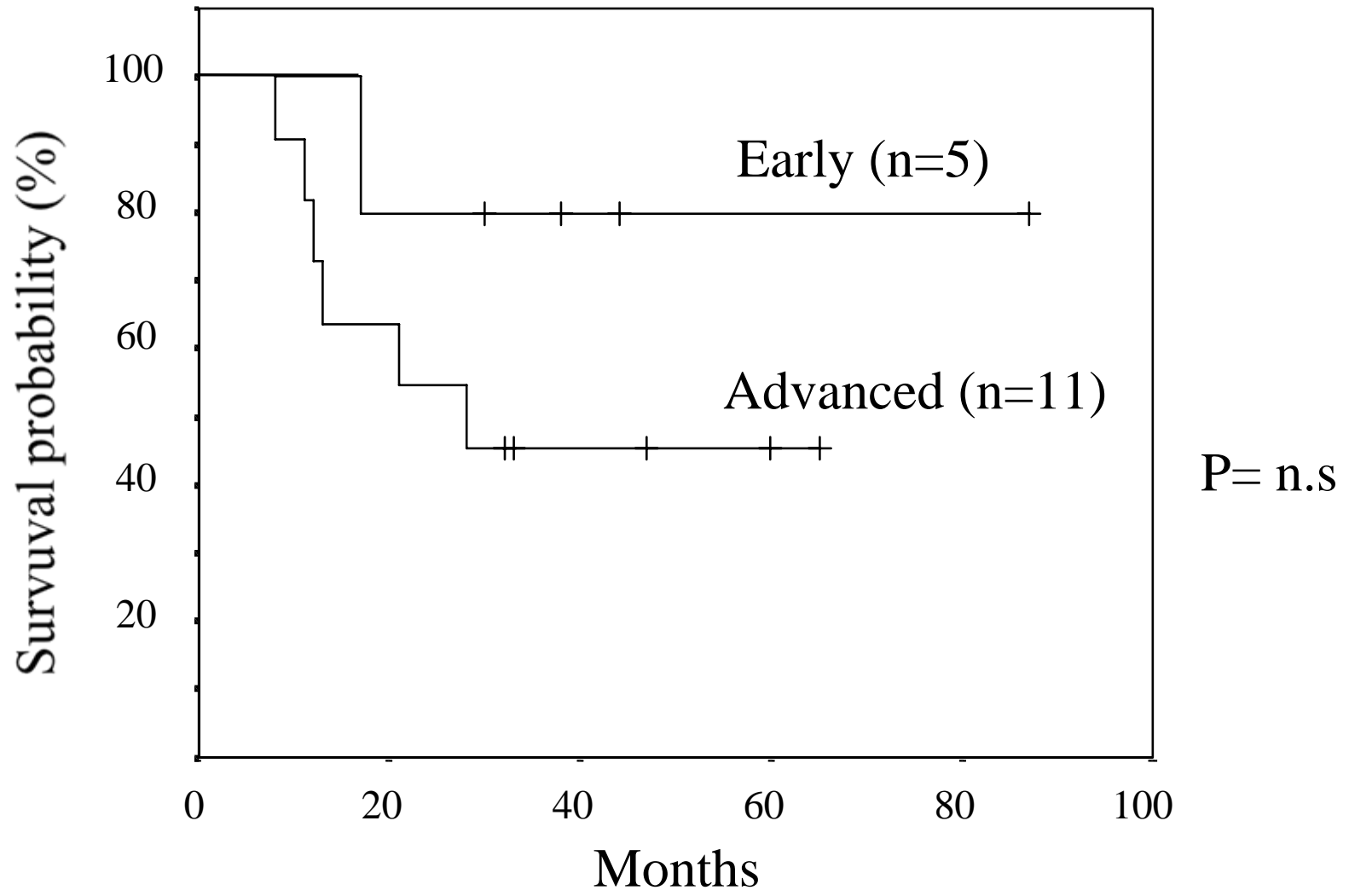


Figure 6: Complete tumor removal
vs Insufficient / no surgery

