

Myxedema Accompanied by Huge Portal-Systemic Shunt without Portal Hypertension

Yasushi YAMAGUCHI, Takashi OKAI, Hiroyuki WATANABE, Yoshiharu MOTOO, Masayoshi MAI*,
Osamu MATSUI**, Yasuni NAKANUMA*** and Norio SAWABU

Abstract

A 43-year-old woman with a huge portal-systemic shunt accompanied by myxedema showed slow speech and behavior. Several imaging studies revealed a bold portal-systemic shunt from the splenic vein to the left renal vein. In addition, hypothyroidism caused by chronic thyroiditis was diagnosed, and synthesized thyroxine replacement was effective for the symptoms. However, the serum ammonia and indocyanin green retention remained in the abnormal range, nevertheless the portal vein pressure was normal and findings of liver cirrhosis were not recognized histologically. Surgical shunt closure was performed, resulting in normalized serum ammonia levels and serum branched chain amino acids /aromatic amino acids ratio, and improvement of the ammonia tolerance test.

(Internal Medicine 40: 1200–1204, 2001)

Key words: hepatic encephalopathy, hypothyroidism, ammonia tolerance test

Introduction

Portal-systemic shunt is often found in the late stage of liver cirrhosis or idiopathic portal hypertension (IPH). Until the recent development of imaging studies, it had generally been diagnosed after the manifestation of encephalopathy or elevated serum ammonia levels. On the other hand, myxedema due to severe hypothyroidism is sometimes accompanied by consciousness disturbance, which may be mistaken as hepatic encephalopathy. We herein report a rare case of a patient with huge portal-systemic shunt without liver cirrhosis accompanied by myxedema due to chronic thyroiditis.

For editorial comment, see p 1170.

Case Report

A 43-year-old woman visited our clinic. She did not have a notable medical history such as abdominal operation. Since 1995, she had felt general malaise, which was associated with slow speech and behavior. In 1998, liver injury was incidentally found, and then she was admitted to the local hospital for closer examination of the liver. Elevation of serum ammonia levels was noted, and several imaging studies including angiography revealed a huge portal-systemic shunt from the splenic vein to the left renal vein via a dilated posterior gastric vein, and some of the blood of superior mesenteric vein flowed into the shunt (Fig. 1). Because a blind needle liver biopsy did not reveal liver cirrhosis or portal fibrosis but instead a normal liver, she was diagnosed with hepatic encephalopathy due to portal-systemic shunt. She then underwent per os branched chain amino acids (BCAA) agent treatment for encephalopathy, but her symptoms such as slow movements did not improve as expected. In November 1998, she was admitted to our hospital for the closer work.

On admission, struma was disclosed and typical myxedematous appearance such as hair loss, macroglossia, and edema of extremities was observed. Neither hepatosplenomegaly nor abdominal bruit was documented.

On laboratory examination, serum lactate dehydrogenase (LDH) (2,586 IU/l) and creatine phosphokinase (CPK) (3,673 IU/l) levels were markedly elevated in contrast to the mild elevation of transaminase levels (AST, aspartate aminotransferase, 140 IU/l, ALT, alanine aminotransferase, 60 IU/l). The hepaplastin test remained normal whereas Indocyanine green retention rate (ICG R15) was prolonged (47.4%) and the serum BCAA/aromatic amino acids (AAA) ratio was low (1.11). The serum ammonia level showed high value (129 µg/dl). Hepatitis B virus (HBV) and Hepatitis C virus (HCV) markers were not positive and neither anti-nucleic antibody nor anti-mitochondrial antibody was positive. Thyroid hormonal level was markedly decreased (free triiodothyronine <0.5 pg/µl, free thyroxine, T₄ 0.12 ng/ml, thyroid stimulating hormone >40 µU/

From the Department of Internal Medicine and Medical Oncology, *the Department of Surgical Oncology, Cancer Research Institute, **the Department of Radiology, and ***the 2nd Department of Pathology, School of Medicine, Kanazawa University, Kanazawa

Received for publication August 14, 2000; Accepted for publication June 4, 2001

Reprint requests should be addressed to Dr. Yasushi Yamaguchi, the Department of Internal Medicine and Medical Oncology, Cancer Research Institute, Kanazawa University, 13-1 Takaramachi, Kanazawa 920-8641

Myxedema Accompanied by Portal-Systemic Shunt

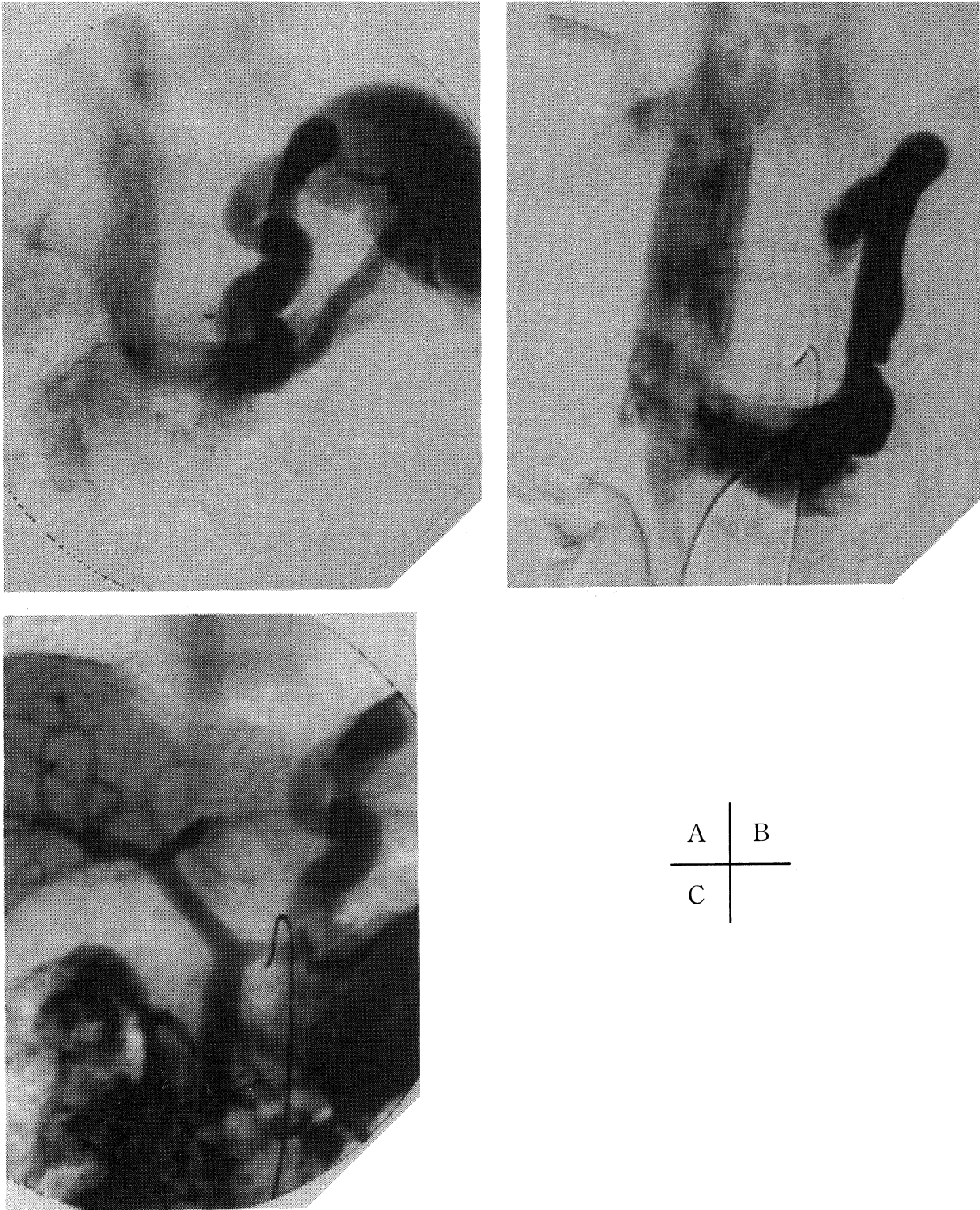


Figure 1. Portal phase of celiac arteriography indicated that most of the splenic vein blood flowed into the shunt (A). Selective left renal venography showing the shunt vessel connected to the left renal vein (B). Portal phase of superior mesenteric arteriography indicated that some of the superior mesenteric vein blood flowed into the shunt (C).

ml) and anti-thyroglobulin antibody and anti-microsome antibody were positive. Consequently, we diagnosed her with myx-

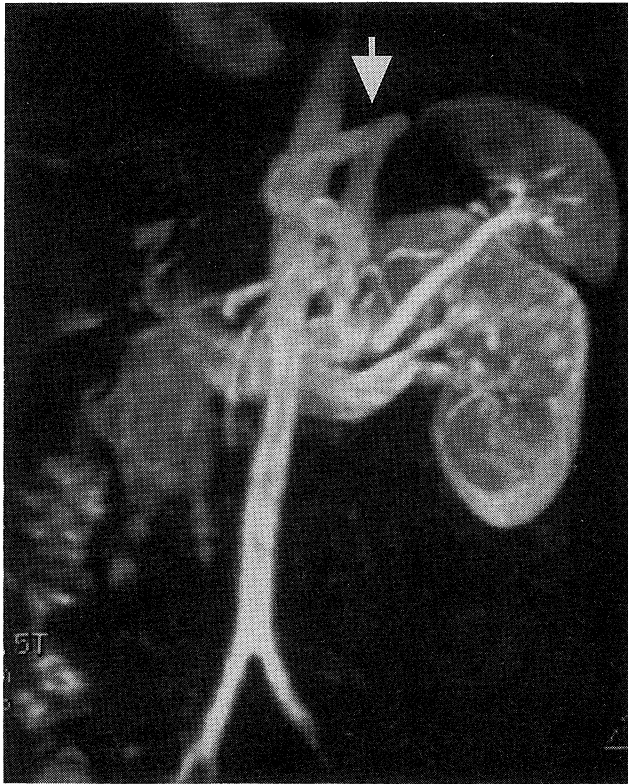


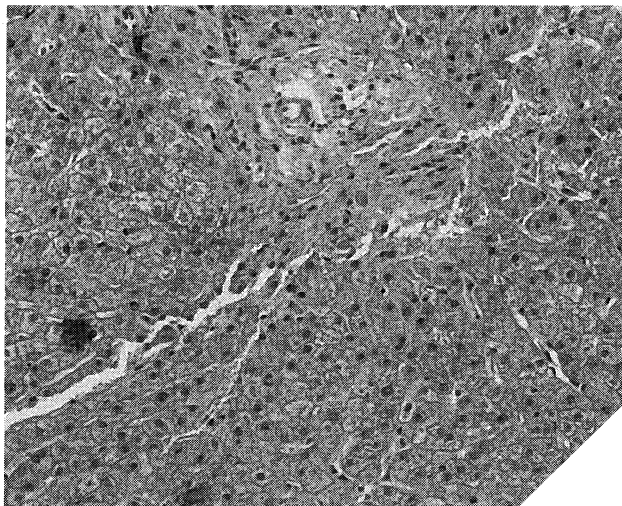
Figure 2. MRI findings. An abnormal abdominal vessel (arrow) connected the splenic vein to the left renal vein.

edema caused by chronic thyroiditis.

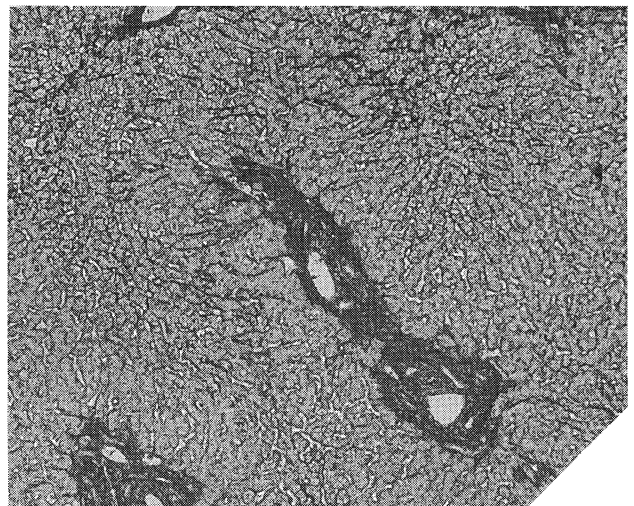
On computed tomography (CT) findings at admission, a large abdominal vessel that measured 1.5 cm in diameter was found, but the spleen was not swollen. Magnetic resonance image (MRI) revealed that this vessel ran between the splenic vein and the left renal vein (Fig. 2). Laparoscopic examination revealed a slightly whitish liver of normal size. Its surface was relatively smooth except for some small depressions, and the typical findings of IPH such as wavy surface, large elevation or depression, and splenomegaly, were not found. Liver biopsy disclosed that hepatic architecture was intact and no type of necrosis or regeneration in the parenchyma was found, while the portal tracts were mildly swollen accompanied by proliferated connective tissues (Fig. 3). It was noted that the portal vein was mildly narrowed due to smooth muscle proliferation. These findings were consistent with the early stage of IPH.

Portal vein pressure was determined using the Seldinger method. Briefly, a balloon catheter was introduced to the abnormal vessel through the left renal vein and the intravenous pressure was directly measured. The determined pressure was 8 mmHg, which became slightly elevated (11 mmHg) after occlusion by the balloon. Both of the measurements were determined to be within the normal range.

During the above studies, we started replacement therapy with synthesized T_4 for myxedema. Serum AST, LDH, CPK and thyroid hormone levels improved promptly and most of the symptoms and signs such as slow speech and behavior, macroglossia, and edema of extremities disappeared, whereas the serum ammonia level remained in high. We then decided to perform a shunt closure operation by open surgery. During the operation, the huge vessel was identified easily under the lesser curvature of the stomach, and the bold vessel (posterior gastric vein) connecting the splenic vein and left renal vein was oc-



A



B

Figure 3. Pathological findings by liver needle biopsy ($\times 100$). HE stain (A), and Azan stain (B). Mild portal fibrosis was noted.

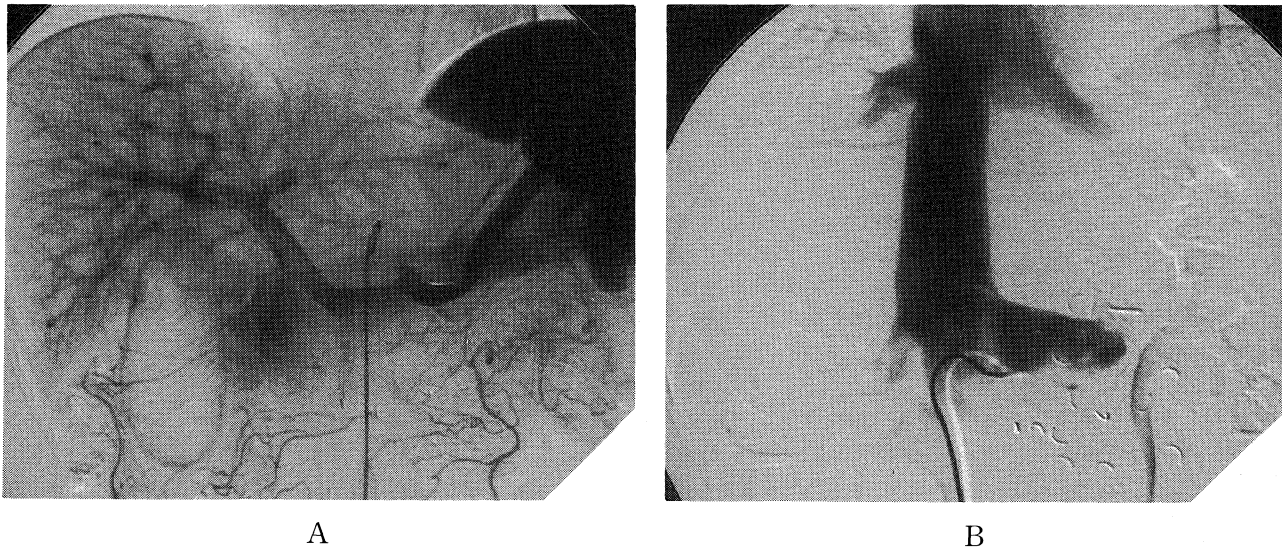


Figure 4. Angiographic findings after surgery in January 1999. In the portal phase of celiac arteriography, all splenic vein blood flowed into the vein and the shunt vessel disappeared (A). Selective left renal venography indicated all renal vein blood flowing into inferior vena cava (B).

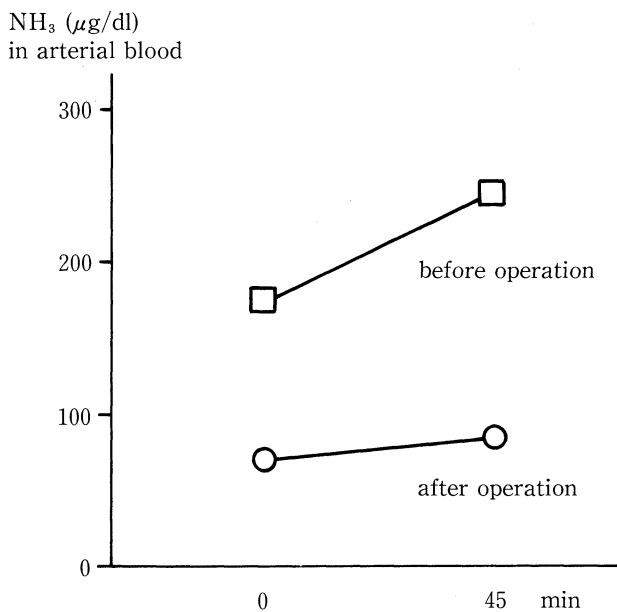


Figure 5. Results of the ammonia tolerance test before and after surgery. A marked decrease in serum ammonia levels was documented after NH₄Cl oral administration.

cluded by metal clips. Angiography after the operation revealed that the blood flow from the splenic vein and the superior mesenteric vein were changed to flow into the portal vein. Furthermore, blood flow from the left renal vein to the inferior vena cava was noted (Fig. 4).

Ammonia tolerance tests were performed before and after

the operation (Fig. 5). A marked decrease in serum ammonia levels was documented after NH₄Cl oral administration. Both ICG R15 and the serum BCAA/AAA ratio were also improved. She became clear headed. At about 2 year postsurgery, the patient showed no symptoms or signs due to portal hypertension or liver dysfunction.

Discussion

Extrahepatic portal-systemic shunt such as spleno-renal shunt is usually observed in cases of portal hypertension, which are often associated with liver cirrhosis, and rarely with IPH. Therefore, portal-systemic shunt without either liver cirrhosis or portal hypertension is very rare, and only a few reports on this anomaly have been reported (1-4). To explain the cause of this condition, three possible etiologies have been proposed: postoperative changes, a subgroup of idiopathic portal hypertension, and a congenital anomaly. It has been thought that this condition might be caused by adhesions around the portal vein resulting from abdominal operation (5, 6). Indeed, some patients had medical histories of abdominal operations. In other cases, however, no operations were performed (7). Therefore, other factors must also cause this condition.

About half of these cases are accompanied by mild portal fibrosis as shown in this case. From this finding, these cases might belong to a subgroup of IPH (6, 8). That is, in the early stage of IPH, portal hypertension might proceed, and collateral vessels might develop spontaneously, resulting in normalization of the portal pressure although portal fibrosis remains the same. Moreover, in general, it seems difficult to distinguish fibrosis in the portal tract from the early stage of IPH which does not show typical changes in liver histology (9). However,

at present, the concept of early stage IPH has not been widely accepted, and it is also difficult to think that a single huge shunt can develop merely as the result of early stage IPH.

On the other hand, portal-systemic shunt without liver cirrhosis or portal hypertension is generally thought to be a congenital anomaly because, in most such cases, portal pressure is normal. Furthermore, the shunt usually consists of a single but bold vessel in contrast to the cases of portal hypertension in which the shunt consists of a vessel network. This hypothesis is also supported by the existence of portal-systemic communications in the fetus (10). Uchino et al studied the long-term prognosis of this type of shunt from infant to aged patients, and described that the frequency of encephalopathy is increased over the age of 60 years (11). The reason for this may be explained as follows: the blood flow of the congenital shunt may gradually increase and subsequently the vessel becomes enlarged over the proceeding years (8), and the aging brain may be less capable of tolerating the presence of ammonia and other metabolic products (2). Mild portal fibrosis may also be understood by a reduction in blood flow leading to chronic hepatic ischemia and depressed nutritional support (3, 11). Based on these viewpoints, it seemed rational to regard the shunt of the present case as a congenital anomaly.

Interestingly, this case was accompanied by myxedema. Portal-systemic shunt has not been reported to be accompanied by an autoimmune disorder such as chronic thyroiditis. As many cases with portal-systemic shunt are diagnosed by the manifestation of hepatic encephalopathy, it was difficult to distinguish the consciousness disturbance due to hypothyroidism from encephalopathy due to portal-systemic shunt. In the present patient, in fact, slow speech and behavior were markedly improved after treatment for hypothyroidism. Therefore, we think that hypothyroidism rather than hepatic encephalopathy may play an important role in inducing the peculiar symptoms in this case. However, by the treatment of shunt exclosure, the serum ammonia levels had markedly decreased to normal, and serum BCAA/AAA ratio was normalized without admin-

istration of BCAA agent, resulting in improvement of her quality of life.

Acknowledgements: We are grateful to Dr. Takachi Yamada, Department of Internal Medicine, Kaga Central Hospital, and Dr. Kazuo Kitagawa, Department of Surgery, Kudo Hospital, Kaga City for important clinical information.

References

- 1) Edward AE. Functional anatomy of the porta-systemic communications. *Arch Intern Med* **88**: 137-154, 1951.
- 2) Kerlan RK Jr, Sollenberger RD, Palubinskas AJ, Raskin NH, Callen PW, Ehrenfeld WK. Portal-systemic encephalopathy due to a congenital portocaval shunt. *AJR Am J Roentgenol* **139**: 1013-1015, 1982.
- 3) Kiriya M, Takashima S, Sahara H, et al. Case report: Portal-systemic encephalopathy due to a congenital extrahepatic portosystemic shunt. *J Gastroenterol Hepatol* **11**: 626-629, 1996 (Clinical Hepatology).
- 4) Watanabe M, Takatama M, Okamoto K, Ohwada S, Fukusato T, Hirai S. Extrahepatic portal-systemic encephalopathy without portal hypertension. *Tohoku J Exp Med* **175**: 77-90, 1995.
- 5) Koyama H, Saitoh M, Sai S, Tsunoda T, Satoh S, Ohto M. A case of portal-systemic encephalopathy with a large gastrosplenic shunt in a patient with chronic hepatitis. —percutaneous transhepatic shunt embolization—. *Kanzo* **31**: 694-698, 1990 (in Japanese, Abstract in English).
- 6) Matsuura B, Akamatsu K, Kitai K, Kimura H, Ohta Y. A case report of portal-systemic encephalopathy with normal portal vein pressure and non-cirrhosis of the liver. *Nihon Shokakibyō Gakkai Zasshi* **84**: 1684-1689, 1987 (in Japanese).
- 7) Hamazaki K, Mimura H, Katoh T, et al. Five cases of portal-systemic (Inose type) encephalopathy due to porto-caval shunt. *Kan Tan Sui* **23**: 117-123, 1991 (in Japanese).
- 8) Takashi M, Igarashi M, Hino S, Goto N, Okuda K. Chronic portal-systemic encephalopathy with normal portal vein pressure possibly due to noncirrhotic portal fibrosis. *Dg Dis Sci* **29**: 669-673, 1984.
- 9) Ludwig J, Hashimoto E, Obata H, Baldus WP. Ideopathic portal hypertension. *Hepatology* **17**: 1157-1162, 1993 (Clinicopathology Conferences).
- 10) Reichardt W, Bützow GH, Erbe W. Anomalous venous connections involving the portal system. *Cardiovasc Radiol* **2**: 41-46, 1979.
- 11) Uchino T, Mastuda I, Endo F. The long term prognosis of congenital portosystemic venous shunt. *J Pediatr* **135**: 254-256, 1999.