Transcrusal approach to the retrochiasmatic region with special reference to temporal lobe retraction: an anatomical study

Transcrusal approach to the retrochiasmatic region with special reference to temporal lobe retraction: An anatomical study

Masashi Kinoshita[1], Mitsutoshi Nakada[1], Shingo Tanaka[1], Noriyuki Ozaki[2], Jun-ichiro Hamada[1], Yutaka Hayashi[1]

[1]Department of Neurosurgery, and [2]Department of Anatomy and Neuroembryology, Kanazawa University, Kanazawa, Japan

Corresponding Author:
Yutaka Hayashi, M.D.
Department of Neurosurgery, Kanazawa University
13-1 Takaramachi, Kanazawa 920-8641, Japan
E-mail: yuh@ns.m.kanazawa-u.ac.jp
Phone: 81762652384
Fax: 81762344262

Abstract

Background: The retrochiasmatic region is one of the most challenging areas to surgically expose. The authors evaluated the transcrusal approach, which involves removal of the superior and posterior semicircular canal from the ampulla to the common crus, to expose the retrochiasmatic region and compared it with the retrolabyrinthine approach, both of which are a variation of the posterior petrosal approach with hearing preservation, with a special emphasis on the influence of temporal lobe retraction.
Methods: Six sides of silicone-injected cadaveric heads were dissected using 2 approaches: the transcrusal approach and the retrolabyrinthine approach. For each craniotomy, 3 exposure parameters in the retrochiasmatic region were measured: (1) horizontal distance, (2) vertical distance, and (3) triangular area of exposure, at 3 different levels of temporal lobe retractions: 0 mm, 5 mm, and 10 mm of retraction from the level of the tentorial incisura.
Results: Without temporal lobe retraction, only the transcrusal and not the retrolabyrinthine approach provided a direct exposure of the retrochiasmatic region, especially in the horizontal distance ($p < 0.001$). At all levels of temporal lobe retraction, the transcrusal approach provided greater exposure in the horizontal and vertical distances and in the area of exposure. Nonetheless, in the horizontal distance, the difference between the transcrusal and retrolabyrinthine approaches decreased along with increased temporal lobe retraction, and almost no difference was obtained at 10 mm of retraction.
Conclusions: Posterior petrosal approaches can provide an excellent exposure of the retrochiasmatic region. Of these 2 approaches, namely, transcrusal and retrolabyrinthine with hearing preservation, the transcrusal approach offers greater exposure than the retrolabyrinthine approach. The beneficial effect of partial labyrinthectomy of the transcrusal approach to the retrochiasmatic region is accentuated in the exposure of the horizontal distance with less temporal lobe retraction.

Key words: Retrochiasmatic region, posterior petrosal approach, partial labyrinthectomy, transcrusal approach, retrolabyrinthine approach

Introduction

In the 1980s, various approaches were popularized for the treatment of lesions involving the skull base [1, 4, 6, 13, 17, 20, 23, 27, 30]. Among them, for approaching tumors and vascular lesions of the petroclival and posterior cavernous sinus area, the posterior petrosal approaches are well-established [1, 4, 13, 15, 26, 27, 30]. In several variations of the posterior petrosal approach, the retrolabyrinthine approach is frequently used because it is easy to perform and causes no deficit in hearing or vestibular function. However, the presence of the labyrinth obscures the view of the sigmoid dura, especially if the sigmoid sinus is large or dominant, and the vein of Labbé has an anterior drainage that limits temporal lobe retraction. To overcome this obstacle, the transcrusal approach, which consists of the standard retrolabyrinthine approach and partial labyrinthectomy including removal of the posterior and superior semicircular canals with petrous apicectomy, was introduced to provide better exposure. In addition, although the risk of hearing disturbances may exist, the meticulous and appropriate procedure of partial labyrinthectomy can maintain hearing preservation [5, 7, 14, 16, 24, 25, 28, 29].

Several reports have revealed that the posterior petrosal approach provides direct and wide exposure of not only the petroclival region but also the retrochiasmatic region [2, 3, 12]. The projection of the surgical corridor to the retrochiasmatic region obtained by the posterior petrosal approach is posterior-to-anterior and inferior upward. This projection facilitates dissection of the tumor in this region under direct visualization. There are 4 basic variations of the posterior petrosal approach: retrolabyrinthine, transcrusal (partial labyrinthectomy), transotic, and transcochlear. These approaches differ in the amount of temporal bone resection. In the case of upper and middle petroclival regions, several clinical and anatomical studies have indicated that the transcrusal approach provides increased exposure similar to that of the more aggressive transotic and transcochlear variants, and could be performed with much less risk to hearing and facial nerve functions [7, 15, 25, 26], although there have been no anatomical studies to evaluate the effect of partial labyrinthectomy in the transcrusal approach to the retrochiasmatic region.

In the present study, to evaluate the benefits of the posterior petrosal skull base approach with hearing preservation in the retrochiasmatic region, we quantitatively assessed exposures of the retrochiasmatic region in the retrolabyrinthine and transcrusal approaches related to the extended removal of semicircular canals under the influence of temporal lobe retraction.

Materials and Methods

Six sides of 3 formalin-fixed cadaver heads were used in this study. Colored silicon, red for arteries and blue for veins, was injected before dissection. The heads were rigidly fixed with a 3-pointed-pin head holder. Craniotomies were performed using a high-power drill, and dissection was performed under an operative microscope with adequate magnification. The 2 approaches were performed and compared to evaluate the benefits of partial labyrinthectomy to obtain direct visualization of the retrochiasmatic region. The first-stage dissection consisted of the presigmoid retrolabyrinthine approach and the second-stage of the transcrusal approach consisted of partial labyrinthectomy. In each approach, 3 levels of temporal lobe retraction, that is, 0 mm, 5 mm, and 10 mm of retraction, were applied, and 18 data sets were obtained in each approach.

Dissection techniques (all figures are on the left side of the specimen)

The cadaveric specimens were placed in a 90° lateral position. The initial steps were the same for each of the 2 variations of the posterior petrosal approaches and have been well described in the literature [7, 9, 10, 24].

In brief, the C-shaped skin incision used for a standard partial labyrinthectomy petrous apicectomy approach [19] was performed (Fig. 1A). In this procedure, the flap is reflected anteriorly to expose the posterior wall of the bony external auditory canal, including the spine of Henle (Fig. 1B). Subsequently, before mastoidectomy, an ‘L’-shaped temporo-suboccipital craniotomy that fully exposes the transverse-sigmoid sinus junction is performed (Fig. 1B).

The next step consists of a mastoidectomy. Using a large cutting burr, the mastoid bone and air cells are removed to define the temporal tegmen. Then, using a diamond burr, the sigmoid sinus is skeletonized. The mastoid antrum is found approximately 15 mm deep, posterior to the spine of Henle. The mastoid antrum is identified anteriorly just inferior to the temporal dura and opened widely to identify the yellowish compact bone of the lateral semicircular canal (Fig. 1C). For the retrolabyrinthine and transcrusal approaches, exposure of the inferior surface of the lateral semicircular canal is unnecessary. Then, on the basis of the key anatomical landmark of the lateral semicircular canal, the posterior and the superior semicircular canals are identified (Fig. 1D). At this point, the presigmoid dura and sinodural angle should be skeletonized. At the inferior half of the posterior semicircular canal, a dura attachment enters the bony canal posteriorly. This is the vestibular aqueduct, and the dura between this fibrous band and the sigmoid sinus forms the endolymphatic sac. To avoid leakage of endolymph, the duct should be ligated in dural incision. For removing bone

without damage to the dura, the bone should be removed using a diamond drill, leaving a thin shell (skeletonization), which may be removed with a dissector.

In the case of the transcrusal approach, a partial labyrinthectomy is performed next. The superior semicircular canal and part of the posterior semicircular canal are removed to facilitate exposure. The extent of resection is superior to Donaldson's line (an imaginary line in the place of the lateral canal back to the sigmoid sinus) (Fig. 2A). In the clinical setting, fenestrations of the posterior and superior bony canals are packed with bone wax to prevent leakage of the endolymph. This step is followed by resection of the petrous apex (Fig. 2B). During resection of the petrous apex, the surgeon should keep in mind that the intrapetrous carotid artery is usually running deep under the greater superficial petrosal nerve.

The next step is a dural incision. The middle fossa dura is incised along its base. Care should be taken to preserve the vein of Labbe. The middle fossa dural incision is extended in a T-shaped manner to the superior petrosal sinus, leaving a dural fringe. The posterior fossa dura is incised parallel to the sigmoid sinus and extended inferiorly towards the jugular bulb (Fig. 1D). Then, the superior petrosal sinus is ligated and cut, followed by a tentorial incision (Fig. 2B, 2C). The tentorial incision is extended to the edge, with special care for preserving the trochlear nerve. The freed tentorium is retracted anteroinferiorly (Fig. 2D).

With or without the retractor placed under the temporal lobe, the arachnoid dissection is begun next to obtain the area of exposure of the retrochiasmatic space (Fig. 3A, 3B). With a microscopic trajectory of posterior-to-anterior in an inferior upward direction, meticulous arachnoid dissection is performed. Even with a short-distance retraction of the temporal lobe, the surgeon should clearly expose the dorsal side of the internal carotid artery with the anterior choroidal and posterior communicating arteries, caudal surface of the optic chiasma, infundibulum, oculomotor nerve, and posterior cerebral artery (Fig. 3B). At this point of the procedure, measurements are obtained directory from the surgical field with a small, handmade small paper measuring device.

In the clinical setting, meticulous attention should be paid to the closure of the wound because of the high likelihood of CSF leakage. It is difficult to suture the dura of the posterior fossa in a watertight manner. Some type of duraplasty, in combination with either fascia or artificial dura, is necessary, and fat should be placed over the dura with fibrin glue to reinforce the epidural space.

Measurements (Fig.3B)

After dissection, the retrochiasmatic region was exposed and the following parameters were measured: (1) the horizontal distance between the posterior clinoid process and the most rostral point of the exposed retroinfundibular area, (2) the vertical

distance between the posterior clinoid process and the most rostral point of the exposed internal carotid artery, and (3) the area of exposure that was the triangular region built with the above 2 lines of distance (horizontal and vertical distances). Although the plane of the triangular area could not always face perpendicular the surgeon's line of view, to emphasize the field that could be caught in sight directly, the area of exposure was evaluated. All distances were measured directly in the surgical field with handmade paper measuring devices. The triangular area of exposure was calculated with Heron's formula [8], which can be adapted to three-dimensional triangular areas, as in the present case. If there was no visualization of any one of the 3 vertices, the measurement was defined as NA (not available).

Brain retraction

The temporal lobe was retracted using an 18 mm-wide straight brain spatula with a self-retaining retractor. The spatula was positioned on the basal surface of the temporal lobe parallel to the middle cranial fossa. The temporal lobe was retracted to 1 of the 3 levels: 0 mm, 5 mm, and 10 mm between its basal surface and the level of the tentorial incisura. The 3 above-described factors were then measured. None of the cadaver heads dissected in the present study had severe brain atrophy, and distortion of the brain produced by retraction was transient.

Statistical analysis

For the 3 factors measured at each of the 3 levels of brain retraction, statistical comparisons were performed using repeated-measures analysis of variance (ANOVA). Dunnett's procedure was used to determine significant differences in individual comparisons, and a probability value less than 0.05 was considered as significant.

Results (Fig. 4)

In general, the posterior petrosal approaches provide a direct visualization of the retrochiasmatic region. The transcrusal approach provides a wider view than the retrolabyrinthine approach with little or no temporal lobe retraction. In particular, without temporal lobe retraction, only the transcrusal approach provided direct visualization of the retrochiasmatic region.

The horizontal distance between the posterior clinoid process and the most dorsal point of the exposed retroinfundibular area obtained with the transcrusal approach was significantly longer ($p < 0.001$) than with the retrolabyrinthine approach without temporal lobe retraction. However, the benefit of partial labyrinthectomy diminished along with temporal lobe retraction, and almost no difference was obtained at 10 mm of retraction.

The vertical distance and triangular area of exposure were greater with the transcrusal approach than with the retrolabyrinthine approach for all the 3 levels of temporal lobe retraction, and the increased measurements did not diminish along with temporal lobe retraction.

Discussion

Several approaches have been proposed for treating the retrochiasmatic lesions, mainly craniopharyngiomas. These include midline transcranial (bifrontal transbasal, subfrontal, bifrontal), midline transnasal (transsphenoidal), anterolateral (pterional, orbitozygomatic), and posterior petrosal approaches. Among these approaches, only the transsphenoidal approach and the posterior petrosal approach can provide direct visualization of the retrochiasmatic region, especially the region just beneath the optic chiasm and nerves [21]. Although the recent advent of endoscopic instruments provides a wide view via the transsphenoidal route, careful and meticulous microdissection of vital neurovascular structures from the lesion can be difficult and at times precarious in the long and narrow endonasal transsphenoidal corridor. In particular, in case of lesions located in the retroinfundibular region, direct visualization cannot be obtained with the transsphenoidal approach without mobilization of the infundibulum [18]. In contrast to the endonasal transsphenoidal route, the posterior petrosal approaches can provide a wide and shallow operative field of the retrochiasmatic region, even in the retroinfundibular region. Among the variations of the posterior petrosal approaches, the retrolabyrinthine approach has been widely used because of the ease with which it can be performed and its preservation of hearing function.

However, several drawbacks of the retrolabyrinthine approach have been indicated, mainly prolonged temporal lobe retraction and potential injury to the vein of Labbé. In particular, if the vein of Labbé has an anterior drainage site close to the transverse-sigmoid sinus junction, the retraction of the temporal lobe may easily tear this vein. To overcome these drawbacks, the transcrusal approach was introduced to gain a wider surgical view with less temporal lobe retraction while still preserving hearing function. Although several anatomical studies have indicated the usefulness of the transcrusal approach to obtain the visualization of the petroclival region, no anatomical study has been performed to assess the merit of partial labyrinthectomy for providing a direct view of the retrochiasmatic region. In the present study, partial labyrinthectomy in the transcrusal approach provided a wider view of the retrochiasmatic region than the retrolabyrinthine approach.

The benefits of partial labyrinthectomy in the transcrusal approach for exposure of the retrochiasmatic region have different effects on the direction of exposure. With minimal temporal lobe retraction, the greatest beneficial effect was obtained in the horizontal direction of the retrochiasmatic region. Even without temporal lobe retraction, the retroinfundibular region could be widely visualized using a transcrusal approach. However, this beneficial effect decreased along with an increasing level of temporal lobe retraction, i.e., almost no difference of exposed horizontal distance is obtained at 10 mm of retraction. In

contrast to the horizontal direction, the vertical exposure was greater in the transcrusal approach than the retrolabyrinthine approach for all 3 levels of temporal lobe retraction, and the differences did not decrease along with increase in the level of temporal lobe retraction. Because the total area of exposure is influenced by the vertical distance, the area is also greater in the transcrusal approach than in the retrolabyrinthine approach at all 3 levels of retraction, and this approach had the same tendency with the vertical distance along with increasing the retraction level. Because the differences between the transcrusal and translabyrinthine approaches were nearly constant, the effect of partial labyrinthectomy may be adapted without exceptions. These characteristic beneficial effects in exposure direction could depend on the surgical trajectory to the retrochiasmatic region by using posterior petrosal approaches. Because the trajectory to the retrochiasmatic region is posterior-to-anterior and in an inferior upward direction, the horizontal exposure in the anterior-to-posterior direction should be restricted irrespective of temporal lobe retraction above a certain level.

The direct visualization of the retrochiasmatic region obtained in the posterior-to-anterior and inferior upward directions is a characteristic feature of the posterior petrosal approach, and this direction may be opposite to that obtained using an anterior petrosal approach such as the Kawase approach, which usually provides a wider direct visualization of the posterior fossa region, for example, around the lower basilar lesion or midclival lesion, in anterolateral-to-posteromedial and superior downward directions [19, 20]

In the clinical setting, when the vein of Labbé has a posterior drainage site, cerebrospinal fluid release during surgery and the plasticity of the brain tissue could make temporal lobe retraction over 10 mm possible. In such a situation, partial labyrinthectomy may be unnecessary to access lesions located mainly in the retroinfundibular region. However, if the vein of Labbé has an anterior drainage site or if there is difficulty in temporal lobe retraction because of the tight brain of a young patient or an increase in intracranial pressure due to a large mass lesion, the transcrusal approach should have the crucial advantage of less temporal lobe retraction to obtain the surgical view in the retrochiasmatic region. This advantage should be emphasized in adapting the language-dominant side approach. In addition, venous drainage of the inferolateral temporal lobe through the temporal bridging veins is complex, and the short bridging veins can easily be injured by moderate temporal lobe retraction [11, 22]. To avoid such a situation, less retraction is necessary, and presurgical evaluation of the venous system with angiography can be useful for selecting an appropriate approach.

Conclusion

Posterior petrosal approaches can provide excellent exposure of the retrochiasmatic region. However, because the procedure can be complex and time-consuming for neurosurgeons who are not familiar with it, presurgical practice with a cadaver or in coordination with ENT surgeons is recommended.

With preservation of hearing, the transcrusal approach offers greater exposure than the retrolabyrinthine approach. The advantage of the partial labyrinthectomy of the transcrusal approach to retrochiasmatic region is due to the exposure of the retroinfundibular region with less temporal lobe retraction; however, the beneficial effect in the horizontal direction decreased along with increasing retraction.

In clinical settings, the ease and safety of surgical procedures are associated not only with achieving a wide visualization of the lesion but also with the usability of microsurgical instruments, multidirectional accessibility, and the depth of the lesion relative to the operative surface. At this point, posterior petrosal approaches may be more usable than transsphenoidal approaches in some complex cases in the retrochiasmatic region. However, it should be kept in mind that, although the transcrusal approach provides a greater usability of instruments than the transsphenoidal approach, the bony canal may prevent movements of instruments, especially in the inferior direction

References

1. Al Mefty O, Fox JL, Smith RR (1988) Petrosal approach for petroclival meningiomas.
Neurosurgery 22: 510-517

2. Al-Mefty O, Ayoubi S, Kadri PAS (2007) The petrosal approach for the total removal of giant retrochiasmatic craniopharyngiomas in children.
J Neurosurg (2 Suppl Pediatrics) 106: 87-92

3. Al-Mefty O, Ayoubi S, Kadri PAS (2008) The petrosal approach for the resection of retrochiasmatic craniopharyngiomas.
Neurosurgery 62: ONS331-ONS336

4. Baldwin HZ, Miller CG, van Loveren HR, Keller JT, Daspit CP, Spetzler RF (1994) The far lateral/combined supra-and infratentorial approach. A human cadaveric prosection model for routes of access to the petroclival region and ventral brain stem.
J Neurosurg 81: 60-68

5. Brandt MG, Poirier J, Hughes B, Lownie SP, Parnes LS (2010) The transcrusal approach: a 10-year experience at one Canadian center.
Neurosurgery 66: 1017-1022

6. Bricolo AP, Turazzi S, Talacchi A, Cristofori L (1992) Microsurgical removal of petroclival meningiomas: A report of 33 cases.
Neurosurgery 31: 813-828

7. Chanda A, Nanda A (2002) Partial labyrinthectomy petrous apicectomy approach to the petroclival region: An anatomic and technical study.
Neurosurgery 51: 147-160

8. Coxeter HSM (1969) Introduction to Geometry. Wiley, New York, NY, p12

9. Day JD (1996) Microsurgical dissection of the cranial base.
Churchill Livingstone, New York, NY,, pp 100-106

10. Fukushima T (2004) Combined petrosal approach (exercise 9). In: Fukushima T (ed)

Manual of skull base dissection. AF Neuro Video, Raleigh, NC

11. Guppy KH, Origitano TC, Reichman OH, Segal S. (1997) Venous drainage of the inferolateral temporal lobe in relationship to transtemporal/transtentorial approaches to the cranial base. Neurosurgery 41: 615-620

12. Hakuba A, Nishimura S, Inoue Y (1985) Transpetrodal-transtentorial approach and its application in the therapy of retrochiasmatic craniopharyngioma.
Surg Neurol 24: 405-415

13. Hakuba A, Nishimura S, Jang BJ (1988) A combined retroauricular and preauricular transpetrosal-transtentorial approach to clivus meningioma.
Surg Neurol 30: 108-116

14. Hirsch BE, Cass SP, Sekhar LN, Wright DC (1993) Translabyrinthine approach to skull base tumors with hearing preservation.
Am J Otol 14: 533-543

15. Horgan MA, Anderson GJ, Kellogg JX, Schwartz MS, Spektor S, McMenomey SO, Delashaw JB (2000) Classification and quantification of the petrosal approach to the petroclival region.
J Neurosurg 93: 108-112

16. Horgan MA, Delashaw JB, Schwartz MS, KelloggJX, Spektor S, McMenomey SO (2001) Transcrusal approach to the petroclival region with hearing preservation. Technical note and illustrative cases.
J Neurosurg 94: 660-666

17. House WF, Hitselberger WE (1976) The transcochlear approach to the skull base.
Arch Otolaryngol 102: 334-342

18. Kassam AB, Gardner PA, Snyderman CH, Carrau RL, Mintz AH, Prevedello DM (2008) Expanded endonasal approach, a fully endoscopic transnasal approach for the resection of midline suprasellar craniopharyngiomas: a new classification based on the infundibulum.
J Neurosurg 108: 715-728

19. Kawase T, Toya S, Shiobara R, Mine T. (1985) Transpetrosal approach for aneurysms of the lower basilar artery. J Neurosurg 68: 857-861

20. Kawase T, Shiobara R, Toya S (1991) Anterior transpetrosal-transtentorial approach for sphenopetroclival meningioma: surgical method and results in 10 patients.
Neurosurgery 28: 869-876

21. Liu JK, Christiano LD, Gupta G, Carmel P (2010) Surgical nuances for removal of retrochiasmatic craniopharyngiomas via the transbasal subfrontal translamina terminalis approach.
Neurosurg Focus 28: E6

22. Sakata K, Al-Mefty O, Yamamoto I. (2000) Venous consideration in petrosal approach: microsurgical anatomy of the temporal bridging vein. Neurosurgery 47: 153-161

23. Samii M, Ammirati M, Mahran A, Bini W, Sepehrnia A (1989) Surgery of petroclival meningiomas: report of 24 cases.
Neurosurgery 24: 12-17

24. Sekhar LN, Schessel DA, Bucur SD, Raso JL, Wright DC (1999) Partial labyrinthectomy petrous apicectomy approach to neoplastic and vascular lesions of the petroclival area.
Neurosurgery 44: 537-550

25. Sincoff EH, McMenomey SO, Delashaw JB Jr.: Posterior transpetrosal approach (2007) less is more.
Neurosurgery 60: ONS53-ONS59

26. Siwanuwatn R, Deshmukh P, Figueiredo EG, Crawford NR, Spetzler RF, Preul M (2006) Quantitative analysis of the working area and angle of attack for the retrosigmoid, combined petrosal, and transcochlear approaches to the petroclival region.
J Neurosurg 104: 137-142

27. Spetzler RF, Daspit CP, Pappas CTE (1992) The combined supra- and infratentorial approach for lesions of the petrous and clival regions: Experience with 46 cases.
J Neurosurg 76: 588-599

28. Taplin MA, Anthony R, Tymianski M, Wallace MC, Rutka JA (2006) Transmastoid partial labyrinthectomy for brainstem vascular lesions: clinical outcomes and assessment of postoperative cochleovestibular function.
Skull base 16: 133-143

29. Tatagiba M, Samii M, Matthies C, Azm ME, Schonmayr R. (1992) The significance for postoperative hearing of preserving the labyrinth in acoustic neurinoma surgery. J Neurosurg 77: 677-684

30. Tedeschi H, Rhoton AL Jr (1994) Lateral approached to the petroclival region.
Surg Neurol 41: 180-216

Disclosure:

The authors report no conflict of interest concerning the materials or methods used in this study or the findings specified in this paper, and there is no financial disclosure.

Figure legends

Figure 1.

A, Skin incision used for the retrolabyrinthine and transcrusal approaches (dotted line). B, 'L' shaped craniotomy is drawn with white circles and a dotted line. C, Mastoidectomy has been performed. The sigmoid sinus, mastoid antrum, and a part of lateral semicircular canal are exposed. D, The dural incision is drawn (dotted line). LSCC, lateral semicircular canal; MFD, middle fossa dura; PFD, posterior fossa dura; PSCC, posterior semicircular canal; SSCC, superior semicircular canal.

Figure 2.

Photographs of a partial labyrinthectomy and a tentorial incision. The middle fossa dura has already been resected. A, Photomicrograph illustrating Donaldson's line (dotted line). B, In the transcrusal approach, partial mastoidectomy above Donaldson's line has been performed. C, The tentorium has been cut. D, The tentorium was reflected anterolaterally.

Figure 3.

Photographs obtained through the surgical microscope to illustrate exposure of the retrochiasmatic region obtained by the transcrusal approach. The microscope angle (trajectory) is posterior-to-anterior in an inferior upward direction. A, Without temporal lobe retraction, the infundibulum is seen. B, With temporal lobe retraction (10 mm), a wider view of the retrochiasmatic region can be seen. CN III, oculomotor nerve; CN IV, trochlear nerve; IC, internal carotid artery; PCA, posterior cerebral artery; PCP, posterior clinoid process; PCom, posterior communicating artery; dotted lines and triangle indicate the measured distances and area of exposure.

Figure 4.

Three parameters measured in the exposed retrochiasmatic region. With no temporal retraction, only the transcrusal approach provided exposure in the retrochiasmatic region, especially in the horizontal distance ($p < 0.001$) as compared to the translabyrinthine approach. With all 3 levels of temporal lobe retraction, the transcrusal approach provided greater exposure than the translabyrinthine approach.

Figure 1

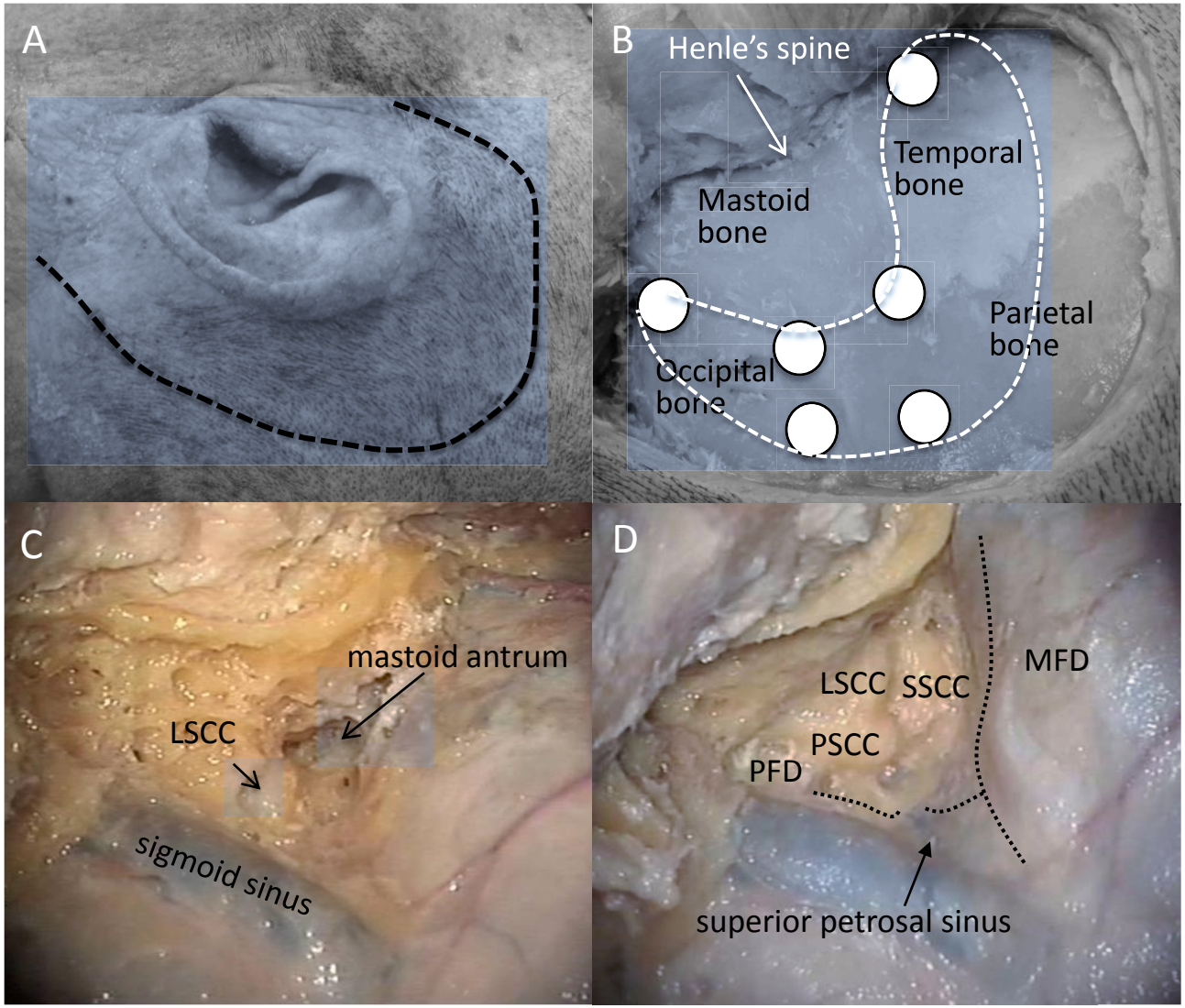
A
B
Henle's spine
Temporal bone
Mastoid bone
Parietal bone
Occipital bone
C
mastoid antrum
LSCC
sigmoid sinus
D
MFD
LSCC
SSCC
PSCC
PFD
superior petrosal sinus

Figure 2

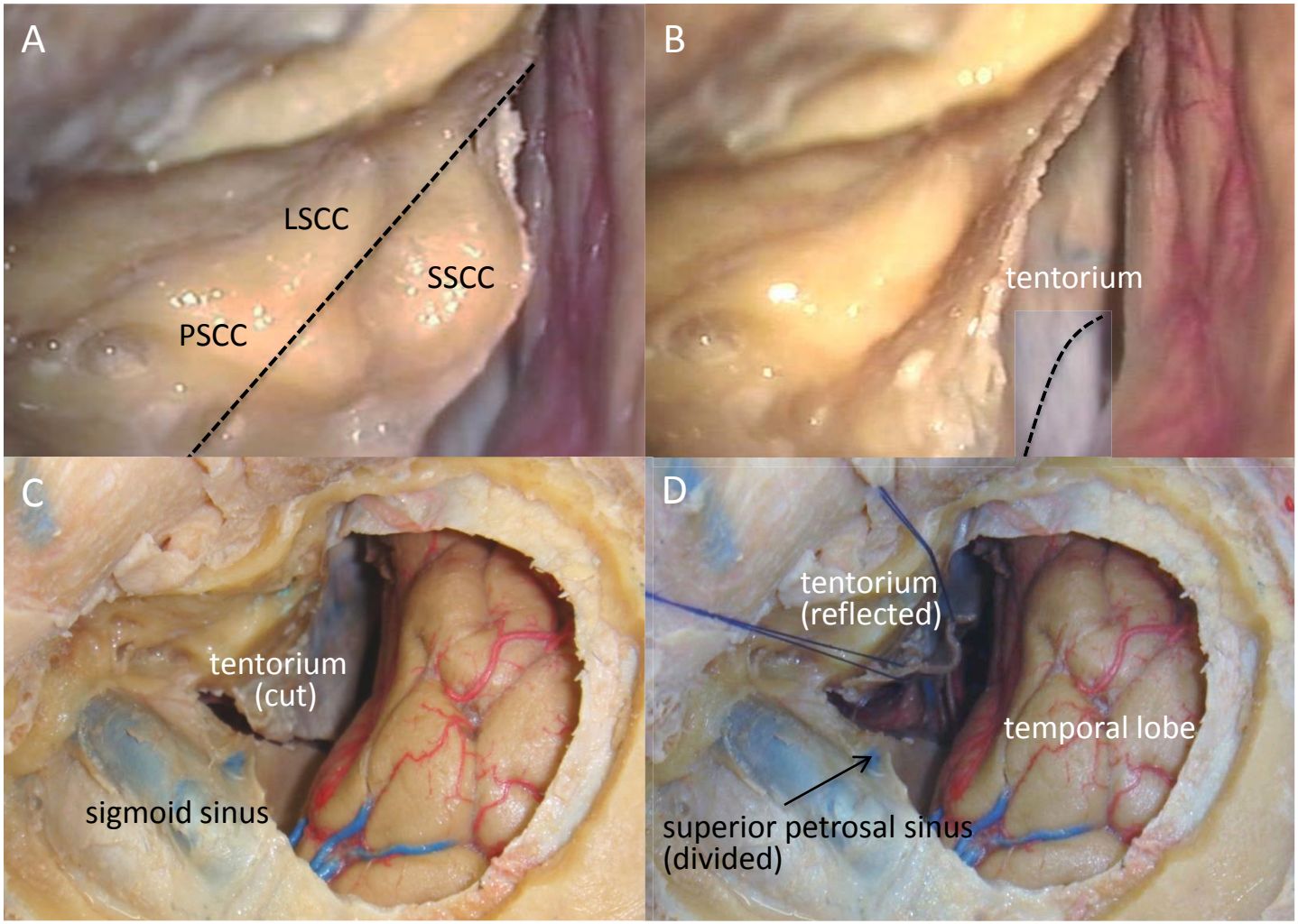
A
LSCC
SSCC
PSCC
B
tentorium
C
tentorium
(cut)
sigmoid sinus
D
tentorium
(reflected)
temporal lobe
superior petrosal sinus
(divided)

Figure 3

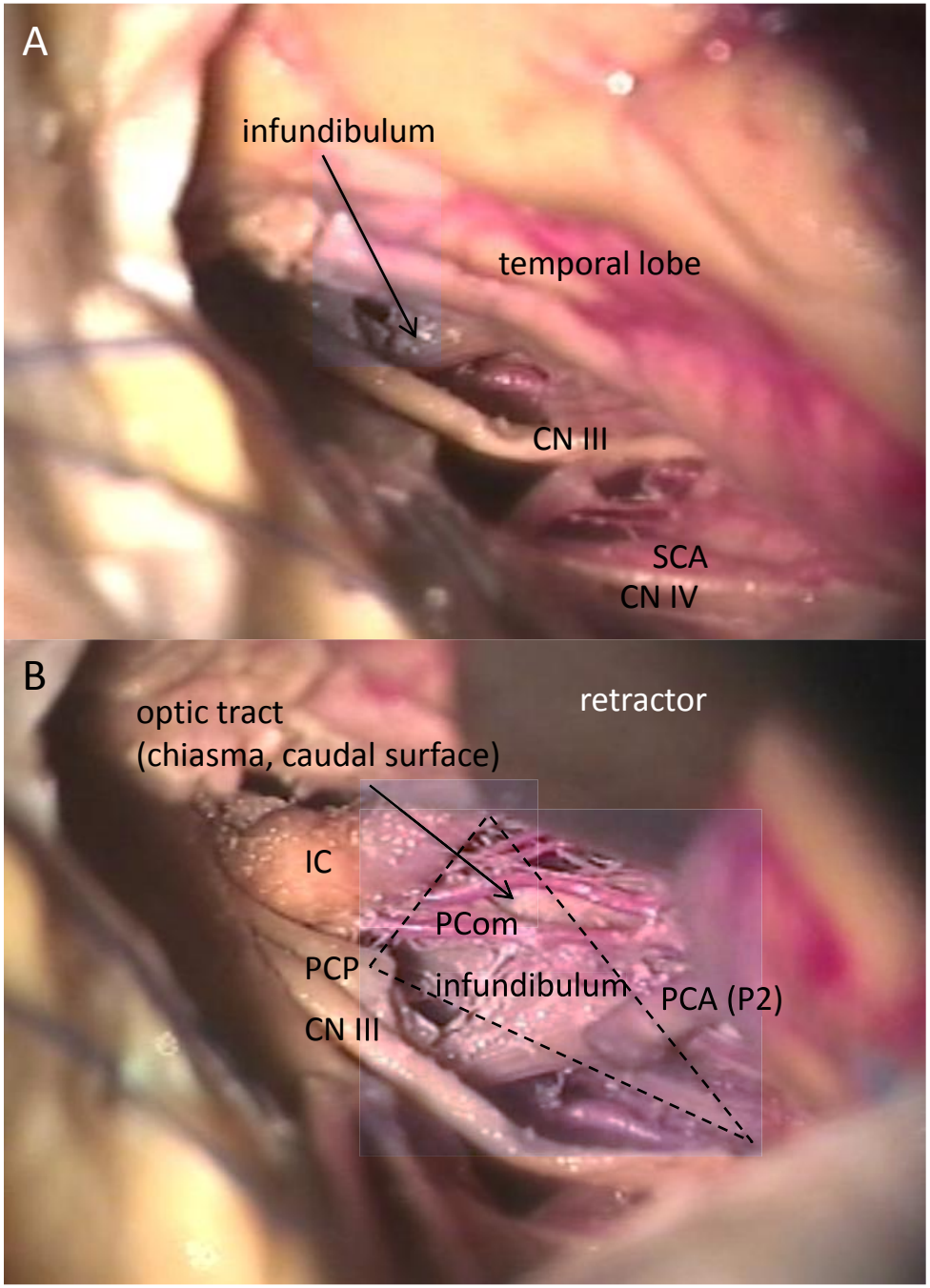
A
infundibulum
temporal lobe
CN III
SCA
CN IV
B
optic tract
(chiasma, caudal surface)
retractor
IC
PCom
PCP
infundibulum
PCA (P2)
CN III

Figure 4

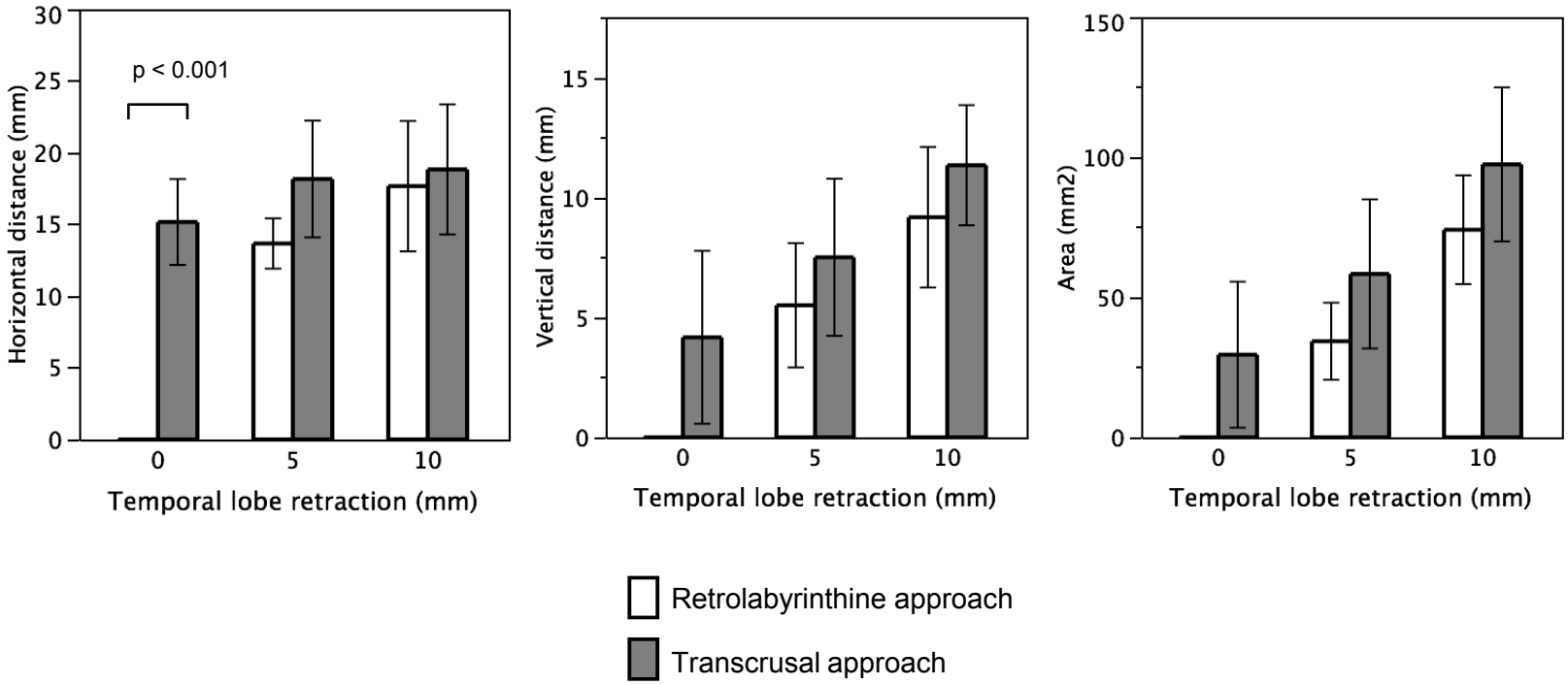
p < 0.001
Horizontal distance (mm)
Temporal lobe retraction (mm)
Vertical distance (mm)
Temporal lobe retraction (mm)
Area (mm2)
Temporal lobe retraction (mm)
Retrolabyrinthine approach
Transcrusal approach