

Assessment of bone healing and hypoesthesia in the upper lip after Le Fort I osteotomy with self-setting α -tricalcium phosphate and absorbable plates

メタデータ	言語: eng 出版者: 公開日: 2017-10-03 キーワード (Ja): キーワード (En): 作成者: メールアドレス: 所属:
URL	http://hdl.handle.net/2297/31964

Assessment of bone healing and hypoesthesia in the upper lip after Le Fort I osteotomy with self-setting α -tricalcium phosphate and absorbable plates

Koichiro Ueki, DDS, PhD1, Katsuhiko Okabe, DDS1, PhD1, Kohei Marukawa, DDS, PhD1, Aya Mukozawa, DDS1, Akinori Moroi, DDS1, Mao Miyazaki, DDS1, Megumi Sotobori, DDS1, Yuri Ishihara, DDS1, Kunio Yoshizawa, DDS, PhD1, Kazuhiro Ooi, DDS, PhD1, Shuichi Kawashiri, DDS1, PhD1

1Department of Oral and Maxillofacial Surgery (Head: Prof. Dr. S. Kawashiri), Graduate School of Medicine, Kanazawa University, 13-1 Takaramachi, Kanazawa 920-8641, Japan

Address correspondence to: Koichiro Ueki, DDS, PhD.

Department of Oral and Maxillofacial Surgery, Graduate School of Medicine, Kanazawa University, 13-1 Takaramachi, Kanazawa 920-8641, Japan

Tel: +81-76-265-2444; Fax: +81-76-234-4268

E-mail: kueki@med.kanazawa-u.ac.jp

Abstract

Purpose. The purpose of this study was to evaluate hypoesthesia of the upper lip and bone formation using self-setting α -tricalcium phosphate (Biopex®) between the segments following Le Fort I osteotomy with bent absorbable plate fixation.

Subjects and Methods. The subjects were 47 patients (94 sides) who underwent Le Fort I osteotomy with and without mandibular osteotomy. They were divided into a Biopex® group (48 sides) and a control group (46 sides). The Biopex® was inserted into the anterior part of the gap between the segments in the Biopex® group. Trigeminal nerve hypoesthesia at the region of the upper lip was assessed bilaterally by the trigeminal somatosensory-evoked potential (TSEP) method. The area of the Biopex® at the anterior part in the maxilla was assessed immediately after surgery and 1 year postoperatively by computed tomography (CT).

Results. The mean measurable period and standard deviation were 13.2 ± 18.5 weeks in the control group, 14.5 ± 17.9 weeks in the Biopex® group, and there was no significant difference in TSEP. The area of the Biopex® after 1 year was significantly smaller than that immediately after surgery (right side: $P=0.0024$, left side: $P=0.0001$) and bone defects between the segments could not be found in the Biopex® group. In the control group, although the areas of bone defect after 1 year were significantly smaller than that immediately after surgery on the right side ($P=0.0133$) and left side ($P=0.0469$) in the

frontal view, complete healing of the bone defects could be seen in 12 of 46 sides after 1 year.

Conclusion. This study suggested that inserting Biopex® in the gap between the maxillary segments was useful for new bone formation and it did not prevent the recovery of upper lip hypoesthesia after Le Fort I osteotomy with absorbable plate fixation.

Key words:

Self-setting α -tricalcium phosphate (Biopex®), Trigeminal somatosensory-evoked potential (TSEP), Le Fort I osteotomy, Computed tomography (CT), Absorbable plate

Introduction

Our previous study showed that bony healing could occur in spaces between the segments of the maxilla and pterygomaxillary regions as well as the region of the anterior and lateral walls in the maxilla, but it is not always complete within 1 year after Le Fort I osteotomy (Ueki et al., 2011). To obtain long-term stability, use of various alternative materials between the segments should be considered. Autogenous bone from the iliac crest or rib has been recommended (Araujo et al., 1978; Bloomquist, 1980; Bloomquist, 1982), although freeze dried bone (Epker et al., 1976), proplast blocks (Burton et al., 1980), and the solid-block form of hydroxy apatite have also been advocated (Kent et al., 1986). Self-setting α -tricalcium phosphate (Biopex®) (Pentax Co, Tokyo, Japan) has also been recognized as one of the very useful bone alternative materials (Manma et al., 1988; Ueki et al., 2011), and has been used in Japan.

Recently, an absorbable fixation plate system (Super-FIXSORB®-MX. Takiron Co. Ltd, Osaka) was newly developed for use in orthopedic or cranio-facial, oral and maxillofacial or plastic and reconstructive surgeries (Shikinami & Okuno, 1999; Shikinami & Okuno, 2001; Shikinami et al, 2005). The previous study suggested that there were no significant differences in the postoperative time-course changes among the u-HA/PLLA plate system, PLLA plate system and conventional titanium plate system in orthognathic surgery (Ueki et al, 2011b). Moure et al (2012) also reported that the bimaxillary orthognathic procedure with bioresorbable osteosynthesis is a reliable and reproducible method in Angle Class III

malocclusions. However, when the absorbable plate system was used in cases where the space between the bony segments was wide, whether proper rigidity and stability can be achieved was also considered. Therefore, the combined use of segmental fixation with an absorbable plate system and filling in the space between the segments were assumed to be clinically necessary.

On the other hand, disturbance of the sensitivity of the upper lip should be considered after Le Fort I osteotomy with some materials. One year postoperatively a partial to total recovery of sensation of the affected area has been reported (Nelson et al., 1977; de Jongh et al., 1986; Kahnberg and Emgström, 1987). The previous study objectively showed that hypoesthesia occurs in the upper lip following Le Fort I osteotomy with (trigeminal somatosensory-evoked potential) TSEP (Ueki et al, 2007). When the alternative materials are used at the area between the maxillary segments, it is unclear whether the recovery period of the upper lip hypoesthesia can be delayed.

The purpose of this study was to evaluate hypoesthesia of the upper lip with TSEP and bone formation using self-setting α -tricalcium phosphate (Biopex®) between the maxillary segments after Le Fort I osteotomy with bent absorbable plate fixation.

Patients and Methods

Patients

Forty seven Japanese adults (men: 18, women: 29) in this study presented with jaw deformities diagnosed as mandibular prognathism with and without maxillary deformity. At the time of orthognathic surgery, the patients ranged in age from 16 to 48 years, with a mean age of 26.1years (standard deviation, 7.5 years). Informed consent was obtained from the patients and the study was approved by Kanazawa University Hospital.

Surgery

The patients were divided into a Biopex® group (24 cases, 48 sides) and a control group (23 cases, 46 sides). In the Biopex® group, 22 of 24 patients underwent Le Fort I osteotomy and bilateral sagittal split ramus osteotomy (SSRO), 2 patients underwent Le Fort I osteotomy alone. In the control group, 20 of 23 patients underwent Le Fort I osteotomy with bilateral SSRO, two patients underwent Le Fort I osteotomy with SSRO for one side and intraoral vertical ramus osteotomy (IVRO) for the other side and one patient underwent Le Fort I osteotomy with bilateral IVRO.

All patients underwent a standard Le Fort I osteotomy following a periodontal incision at the anterior teeth and a vestibular incision at the posterior teeth to prevent any postoperative scar at the labial gingival tissue, with inter-maxillary fixation screws (Jeil Medical, Seoul, Korea) implanted in the bimaxillary anterior alveolar bone, according to the previous report (Ueki et al., 2004; Ueki et al., 2009). Two L-type titanium plates at the site of the piriform rim, two straight titanium plates at the site of the zygomatic buttress and screws (Universal Mid-face fixation module, Stryker, Freiburg, German) were used for four

patients, Two L-type absorbable plates at the site of the piriform rim, two straight absorbable plates at the site of the zygomatic buttress and screws (uncalcined and unsintered hydroxyapatite and poly-L-lactic acid (uHA/PLLA): super FIXSORB®MX, Takiron Co. Ltd, Osaka, Japan) were used for all patients. Post-operative inter-maxillary fixation was not performed, but traction by elastic was performed in all cases.

CT assessment

The patients were placed in the gantry with the tragacanth line perpendicular to the ground for CT scanning. They were instructed to breathe normally and to avoid swallowing during the scanning process. CT scans were obtained in the radiology department by skilled radiology technicians using a high-speed, advantage-type CT generator (Light Speed Plus; GE Healthcare, Milwaukee, WI, USA) with each sequence taken 1.25 mm apart for the 3D reconstruction (120 kV, average 150 mA, 0.7 sec/rotation, helical pitch 0.75). The 3D image was reconstructed by a 3D visualization and measurement software, Med View version 5.5 (LEXI Co, Tokyo, Japan). At 1 week after surgery and the 1 year follow up, CT scans were taken for all patients who underwent orthognathic surgery and gave their informed consent.

Measurements using CT

In the control group, the threshold of the CT value (Hounsfield units: HU) of the measurable maxillary bone was standardized as over 1200. The frontal (right and left) view perpendicular to the FH (Frankfurt) plane was reconstructed to measure the bone defect area between segments of the maxilla after Le Fort I osteotomy on the right and left sides (Fig. 1). A total of 46 sides (23 right and 23 left sides) were measured. In the Biopex® group, the threshold of the CT value (Hounsfield units: HU) of the measurable maxillary bone was standardized as from 1200 to 2200 HU and the threshold of the measurable CT value of the Biopex® inserted at the maxilla was standard at over 2200. The 3D CT image from 1200 HU to 2200HU was treated at 80% transparency and superimposed on the image of the over 2200 HU. The area over 2200 HU was measured as Biopex® at the anterior area of the maxilla (Fig. 2). A total of 48 sides (24 right and 24 left sides) were measured. The defective area in the control group and the high density area in the Biopex group were measured in the frontal view (as 2 dimensional images) made from the 3D CT images using the image software (Scion image, Scion corporation ML, USA) and the Med View version 5.5 (LEXI Co, Tokyo, Japan).

All CT images were measured by an author (K.U.). Fifteen patients were selected and the calculation performed using Dahlberg's formula (Dahlberg, 1940):

$$ME = \sqrt{\sum d^2 / 2n}$$

Where d is the difference between 2 registrations of a pair, and n is the number of double registrations. The random errors did not exceed 0.21 mm for the linear measurements and 2.0 mm² for the square measurements.

Trigeminal nerve hypoesthesia was assessed bilaterally by the TSEP method. The methodology and values of TSEP have been described previously in our preliminary studies (Nakagawa et al., 1997; Nakagawa et al., 2001; Nakagawa et al., 2003). The electrodes were placed exactly above the highest point of the vermilion border and on the mucosa of the upper lip. An electroencephalograph recording system (Neuropack Sigma™; Nihon Koden Corp., Tokyo, Japan) was used to measure the potentials. The right and left sides were measured separately so that a total of 94 sides could be assessed. Each patient was evaluated pre-operatively and then post-operatively at 1 and 2 weeks, 1, 3, 6 months, 1 year and 1.5 years. The measurable period was determined as the time when TSEP was first measurable post-operatively. Measurement of TSEP after surgery was continued until it became measurable.

Trigeminal hypoesthesia was assessed by the latency of P1 and N2 in the recorded TSEP spectra. An earlier pilot study in healthy volunteers showed that these peaks produced an accurate figure and tended to result in better reproducibility. Measurable periods of TSEP were defined as periods before the peaks of N1 (N13), P1 (P17), N2 (N27), and P2 (P36) that were identified clearly as early components of the TSEP wave. Actual data was recorded as the latency period (msec) in each peak.

Statistical analysis

Data were statistically analyzed with StatView software, version 4.5 (ABACUS Concepts, Inc., Berkeley, CA, USA) and Dr. SPSSII (SPSS Japan Inc., Tokyo, Japan). Differences were considered significant at $p < 0.05$.

Results

No fracture was noted in the upper third of the pterygoid plates, and there was no fracture of the cranial base. Intended maxillary movement by simulation surgery could be achieved in all cases. Therefore, there was no difference between the intended maxillary movement and the actual post-operative maxillary movement. Blood loss was small and no patient required transfusion.

At 1 year after surgery, the shape of the uHA/PLLA plate did not change in all cases. Therefore, the area of overlap between the bone defect and the plate was not included in the measurement of the area in the cases where the uHA/PLLA plates were used in the control group.

In the control group, the results of the statistical analysis showed that the areas of bone defect after 1 year were significantly smaller than those immediately after surgery on the

right side ($p=0.0133$) and left side in the frontal view ($p=0.0469$). After 1 year, complete bone continuity between segments could be recognized just in 5/23 sides on the right and 7/23 sides on the left in the frontal view. However, the area of bone defect after 1 year was seen in 18 /23 sides on the right and 16/23 sides on the left in the frontal view (Fig.1A, Table. 1A).

On the other hand, in the Biopex® group, the area of bone defect after 1 year could not be seen in all sides. The area of the Biopex® after 1 year was significantly smaller than that immediately after surgery (right side: $P=0.0024$, left side: $P=0.0001$), when the setting for Biopex® was considered as over 2200 HU in the CT image (Fig.1B, Table. 1B).

In the control group, TSEP was measurable within 1 week in 16 of 46 (34.8%) sides of the upper lip, within 2 weeks in 22 sides (47.8%), within 1 month in 28 sides (60.9%), within 3 months in 32 sides (69.6%), within 6 months in 42 sides (80.4%), within 1 year in 42 sides (91.3%) and within 1.5 years in 44 sides (95.7%). Pre- and postoperative measurements of TSEP were impossible in the remaining 2 sides in one patient.

In the Biopex® group, TSEP was measurable within 1 week in 6 of 48 (12.5%) sides of the upper lip, within 2 weeks in 11 sides (22.9 %), within 1 month in 28 sides (58.3%), within 3 months in 34 sides (70.8%), within 6 months in 41 sides (85.4%), within 1 year in 45 sides (93.8%), and within 1.5 year in 48 sides (100%).

In the latency period, the Biopex® group significantly showed a lower value than the control group preoperatively (N1; $P=0.0145$, P1; $P=0.0332$, N2; $P=0.0295$), however, there was no significant difference between the two groups postoperatively. The values in the

post-operative measurable period were significantly longer than those in the pre-operative period in the latency period in N1, P1 and N2 in the control group (N1; P=0.0015, P1; P=0.0018, N2; P=0.0246), and in N1, P1, N2 and P2 in the Biopex® group (N1; P<0.0001, P1; P<0.0001, N2; P<0.0001, P2; P<0.0001) (Table 2).

The mean measurable period and standard deviation were 13.2±18.5 weeks in the control group, 14.5±17.9 weeks in the Biopex® group, and there was no significant difference.

Discussion

It was unclear whether the insertion of the alternative bone material could affect bone healing and the recovery of the infra-orbital nerve in the gap between the segments in Le Fort I osteotomy with absorbable plate fixation. This study was performed to evaluate the combined use of an absorbable plate system and bone substitute material from the view of morphological change in maxillary bone healing and sensory disturbance of the upper lip.

Factors that have been implicated for instability after Le Fort I osteotomies include presurgical orthodontics, inadequate mobilization, inappropriate or lack of grafting, increased masticatory forces, inadequate methods of fixation, type and amount of

movement, soft tissue tension, and presence of a cleft. Various fixation techniques have been used for maxillary stabilization including trans-osseous and suspension wires, intraoral skeletal fixation appliances, and bone plating (Ueki et al., 2007; Marşan et al., 2009; Mavili et al., 2009; Kretschmer et al., 2010). Post-operatively, the maxilla appears to be healed and in a stable position on clinical assessment.

With regard to animal studies, Bell et al. have reported primate studies that provide biologic insight into the bone healing and revascularization processes that accompany maxillary osteotomies (Bell, 1969; Bell & Levy, 1971; Bell et al., 1975). These studies have indicated that osseous union of osteotomized sites occurs as early as six weeks postoperative.

However, there have been few histologic studies on human tissues to verify the type of repair that is initiated. A previous study by Compton et al. (1984) indicated that the area between the segments healed with mature compact bone, from the evaluation of punch biopsy at the osteotomy site of five patients after Le Fort I osteotomy. However, the period of biopsy was not constant, ranged from 17 to 30 months, and there was no detailed description of the site that was taken for biopsy. It was unclear whether all the sites on the osteotomy line could induce new bone.

In Le Fort I osteotomy, incomplete ossification of osteosynthesis is one of the major problems (Proffit et al., 2003). If the size of the defect between the advanced inferior maxillary segment and the superior segment exceeds 3mm at the levels of the piriform rim and zygomaticomaxillary junction following Le Fort I osteotomy, use of a bone graft can become necessary for stabilization. Furthermore, bone recovery would be inadequate if

there is a defect of more than 3 mm between the segments along the line of osteosynthesis. The line of osteosynthesis would involve fibrous tissue rather than osseous tissue. In this instance, resistance to relapse would be via this fibrous tissue and the initial plate and screw rather than a robust osseous tissue (Holmes et al., 1988; Proffit et al., 2003). However, there has been no well-controlled study in which the maxilla is advanced to a large distance with and without bone grafting.

The resorbable bone fixation devices have been developed for use in orthopedic or cranio-facial, oral and maxillofacial or plastic and reconstructive surgeries (Shikinami & Okuno, 1999; Shikinami & Okuno, 2001; Shikinami et al., 2005). These devices are made from composites of uncalcined and unsintered hydroxyapatite (u-HA) particles and poly-L-lactide (PLLA), and they are produced by a forging process, which is a unique compression molding, and machining treatment. They have a modulus of elasticity close to that of natural cortical bone, and they can retain a high strength during the period required for bone healing. They can also show optimal degradation and resorption behaviour, osteoconductivity, and bone bonding capability. In this study, the absorbable plate remained after 1 year as confirmed by CT imaging, although characteristic material changes were not observed.

Monma et al. (1988) have originally developed a self-setting cement-type calcium phosphate material consisting of α -TCP, dicalcium phosphate dibasic (DCPD) and tetracalcium phosphate monoxide (TeCP). According to their extensive studies, this cement-type material could be refined, demonstrating better biocompatibility and direct

integration to bone without any participation of peripheral soft tissue (Kurashina et al., 1997a,b; Yamamoto et al., 1998; Yuan et al., 2000). As it is free of infiltration over time of residual monomers of methacrylate resin, which has long been used for orthopedic treatment, this self-setting cement came to be rapidly targeted for clinical use in Japan.

The combined use of segmental fixation with an absorbable plate system and filling in the space between the segments were assumed to be clinically necessary. Prior to this clinical study, a previous study using rabbit suggested that the use of an absorbable plate (Super FIXSORB®-MX) in combination with Biopex® was useful and both Super FIXSORB®-MX and Biopex® could provide adequate bone regeneration and maintain strength and stability in the surgical bone space (Okabe et al., 2010).

In fact, it was difficult to evaluate the healing in the segmental gap using the absorbable plate and the alternative bone material. When the 3DCT reconstruction was performed and evaluated, the threshold of the CT value was very important to judge whether it was that of matured bone or soft tissue. Lettry et al. (2003) reported that the CT values of mandibular cortical bones in 10 cadavers ranged from 976 HU to 1478 HU, with a mean of 1183.9 HU (SD 112.1). However, there is no report regarding the anterior and lateral walls of the maxillary bone that will allow CT values to be determined as over 1200 HU according to our previous report (Ueki et al, 2011a). Furthermore, the CT value of setting Biopex® was also unclear. After the CT value was changed repeatedly in the image software, the threshold of the CT value measurable of Biopex® inserted at the maxilla was standard as over 2200. This value was clearly higher than the surrounding cortical bone at the anterior

part of the maxilla so that the mother bone could be detected. Although immature bone tissue may not be detected in this study, this determination of the CT value was considered acceptable, because the detection of just hard bone tissue to keep the skeletal strength and stability was necessary for this study.

In this study, the areas of bone defect after 1 year were significantly smaller than those immediately after surgery in the right and left anterior walls of the maxilla, similarly to in the previous study. The previous study suggested that the complete bone healing was not associated with the movement of the maxilla and bony contact between segments.

A significant decrease in the square of the Biopex® after 1 year suggested that Biopex® is likely absorbed. Although it was difficult to judge the segmentation of new bone and the Biopex® accurately, the remnant Biopex® could be identified as a block over 2200 HU. Actually, the small particles surrounding the remnant Biopex® could not be detected. However, the surroundings of the blocks of Biopex that decreased the square were filled with bone tissue after 1 year in all cases. If the Biopex® could not be replaced with new bone over 1200 HU, the soft tissue or bone tissue under 1200 HU was detected as the bone defect. In all sides of the Biopex® group, the bone defect at the anterior part of the maxilla was not seen after 1 year. In contrast, in 34/46 sides of the control group, the bone defect (over 1200HU) was observed after 1 year.

The presence of remnant Biopex® after 1 year also suggested that the resorption of the Biopex® was comparatively slow. In the study of Hao et al. (2004) using rabbit femoral cortical bone, a range of osteoclasts accumulated on the surface of the Biopex®, whilst

many osteoblasts were localized on the surface opposing the Biopex® from days 5 to 10. However, remnants of the Biopex® particles were present in the new bone with a profile of compact bone on days 30 and 40. The Biopex® was very hard such that the osteoclasts could not resorb it rapidly. In orthognathic surgery, use of Biopex can compensate the strength and rigidity between segments from the early post-surgery period. It was considered that the slow replacement of the Biopex® could also contribute to maintaining the strength of the mandible after surgery.

On the other hand, disturbance of the sensitivity of the upper lip should be considered after Le Fort I osteotomy with some materials. In Le Fort I osteotomy, the three superior alveolar nerves are transected as part of the osteotomy, and the terminal labial branches of the infraorbital nerve are transected as part of the mucosal incision. After the infraorbital nerve emerges from the infraorbital foramen, it may be subjected either to direct laceration or to traction injury, as a result of the forceful use of retractors during the operation (Posnic et al., 1994).

TSEP, a somatosensory evoked potential of the peripheral nerves has been used previously to investigate the causal factors of trigeminal sensory hypoesthesia that occurs after SSRO (Nakagawa et al., 1997; Nakagawa et al., 2001; Nakagawa et al., 2003; Hashiba et al., 2007; Hashiba et al., 2008). This method is highly objective and reliable as the potential changes of cerebral origin can be detected on the scalp in human subjects following electrical stimulation of the peripheral nerves. SEP data is collected directly from the electroencephalography derived from the cerebral cortex making data of TSEP more

objective and reliable. Thus, differences between objective and subjective assessments may occur. Furthermore, there may also be differences between the actual return of sensation and registration of nerve conduction. Advancements in the field of neurophysiology have revealed posttraumatic changes in the central nervous system. Functional disturbance in the central nervous system after peripheral nerve injury is known as central sensitization (Coderre et al., 1993; McQuay et al., 1994). In this study, the result of data using TSEP was considered as valid and reliable.

The previous study objectively shows that hypoesthesia occurs in the upper lip following Le Fort I osteotomy with TSEP. The measurable period (i.e., when the TSEP wave appears firstly after surgery) of the upper lip following Le Fort I osteotomy tended to be longer than that of the lower lip in the patients who underwent SSRO and IVRO. Furthermore, temporary hypoaesthesia of the upper lip after Le Fort I osteotomy could not be avoided, however, the osteotomy line, plate/screw position and pterygoid plate fracture in Le Fort I osteotomy did not affect the recovery period of the upper lip hypoaesthesia with TSEP. When alternative materials are used at the area between the maxillary segments, it is unclear whether use of such material can affect the recovery period of upper lip hypoesthesia (Ueki et al., 2007; Ueki et al., 2008).

In this study, age and gender were not correlated to the recovery period of TSEP. In both groups, post-operative latency period was significantly longer than the preoperative value. The measurable period was the first peak time of the TSEP wave that could be identified post-operatively, and the upper lip seemed less sensitive in this time. Interestingly, this

tendency was different from the result of recovery period of lower lip hypoesthesia after SSRO with TSEP reported previously (Hashiba et al., 2007). However, there was no significant difference between the two groups regarding the recovery period of upper lip hypoesthesia postoperatively, in this study. In the previous study, temporary hypoesthesia of upper lip after Le Fort I osteotomy could not be avoided, however, the osteotomy line, plate/screw position and pterygoid plate fracture in Le Fort I osteotomy did not affect the recovery period of upper lip hypoesthesia with TSEP (Ueki et al., 2008). Similarly, this study suggested that use of the Biopex® did not affect the recovery period of upper lip hypoesthesia in Le Fort I osteotomy.

Conclusion

This study suggested that inserting Biopex® in the gap between the maxillary segments was useful for new bone formation and it did not prevent the recovery of upper lip hypoesthesia after Le Fort I osteotomy with absorbable plate fixation.

References

Araujo A, Schendel SA, Wolford LM, Epker BN: Total maxillary advancement with and without bone grafting. *J Oral Surg* 36: 849-58, 1978.

Bell WH: Revascularization and bone healing after posterior maxillary osteotomy. *J Oral Surg* 27:249-55, 1969.

Bell WH, Fonseca RJ, Kennedy JW, Levy BM: Bone healing and revascularization after total maxillary osteotomy. *J Oral Surg* 33: 253-60, 1975.

Bell WH, Levy BM: Revascularization and bone healing after posterior maxillary osteotomy. *J Oral Surg* 29: 313-20, 1971.

Bloomquist DS: The posterior ilium as a donor site for maxilli-facial bone grafting. *J Maxillofac Surg* 8:60-4, 1980.

Bloomquist DS: Long-term results of subperiosteal implants combined with cancellous bone graft. *J Oral Maxillofac Surg* 40: 348-52, 1982.

Burton DM, Berarducci JP, Scheffer RB: Proplast grafting: A new method for stabilization of maxillary advancements. *J Oral Surg* 50: 387-9, 1980.

Coderre TJ, Katz J, Vaccarino AL, Melzack R: Contribution of central neuroplasticity to pathological pain: review of clinical and experimental evidence. *Pain* 52:259-85, 1993.

Compton JE, Jacobs JD, Dunsworth AR: Healing of the bone incision following Le Fort I osteotomy. *J Oral Maxillofac Surg* 42: 665-667, 1984.

Dahlberg G: *Statistical methods for medical and biological students*. George Allen and Unwin, London, pp. 122-132. 1940.

de Jongh M, Barnard D, Birnie D. Sensory nerve morbidity following Le Fort I osteotomy. *J Maxillofac Surg* 14:10-13, 1986.

Epker BN, Friedlaender NC, Wolford LM, West RA: The use of freeze-dried bone in middle-third face advancements. *J Oral Surg* 42: 278-89, 1976.

Hao H, Amizuka N, Oda K, Fujii N, Ohnishi H, Okada A, Nomura S, Maeda T: A histological evaluation on self-setting alpha-tricalcium phosphate applied in the rat bone cavity. *Biomaterials* 25: 431-42, 2004.

Hashiba Y, Ueki K, Marukawa K, Nakagawa K, Yamamoto E, Matsubara K: Relationship between recovery period of lower lip hypoesthesia and sagittal split area or plate screw position after sagittal split ramus osteotomy. *Oral Surg Oral Med Oral Pathol Oral Radiol Endod* 105: 11-5, 2008.

Hashiba Y, Ueki K, Marukawa K, Shimada M, Yoshida K, Shimizu C, Alam S, Nakagawa K: A comparison of lower lip hypoesthesia measured by trigeminal somatosensory-evoked potential between different types of mandibular osteotomies and fixation. *Oral Surg Oral Med Oral Pathol Oral Radiol Endod* 104: 177-85, 2007.

Holmes RE, Wardrop RW, Wolford LM: Hydroxyapatite as a bone graft substitute in orthognathic surgery: histologic and histometric findings. *J Oral Maxillofac Surg* 46: 661-71, 1988.

Kahnberg KE, Engström H. Recovery of maxillary sinus and tooth sensibility after Le Fort I osteotomy. *Br J Oral Surg* 25:68-73, 1987.

Kent JN, Zinde MF, Kay JF, Jarcho M: Hydroxyapatite blocks and particles as bone graft substitutes in orthognathic and reconstructive surgery. *J Oral Maxillofac Surg* 44: 597-605, 1986.

Kretschmer WB, Baciut G, Baciut M, Zoder W, Wangerin K: Stability of Le Fort I osteotomy in bimaxillary osteotomies: single-piece versus 3-piece maxilla. *J Oral Maxillofac Surg* 68: 372-80, 2010.

Kurashina K, Kurita H, Hirano M, Kotani A, Klein CP, de Groot K: In vivo study of calcium phosphate cements: implantation of an alpha-tricalcium phosphate/dicalcium phosphate dibasic/tetracalcium phosphate monoxide cement paste. *Biomaterials* 18: 539-43, 1997a.

Kurashina K, Kurita H, Kotani A, Takeuchi H, Hirano M: In vivo study of a calcium phosphate cement consisting of alpha-tricalcium phosphate/dicalcium phosphate dibasic/tetracalcium phosphate monoxide. *Biomaterials* 18: 147-51, 1997b.

Lettry S, Seedhom BB, Berry E, Cuppone M: Quality assessment of the cortical bone of the human mandible. *Bone* 32: 35-44, 2003.

Marşan G, Cura N, Emekli U: Soft and hard tissue changes after bimaxillary surgery in Turkish female Class III patients. *J Craniomaxillofac Surg* 37: 8-17, 2009.

Mavili ME, Canter HI, Saglam-Aydinatay B: Semirigid fixation of mandible and maxilla in orthognathic surgery: stability and advantages. *Ann Plast Surg* 63: 396-403, 2009.

McQuay HJ, Carroll D, Jadad AR, Glynn CJ, Jack T, Moore RA, Wiffeh PJ:
Dextromethorphan for the treatment of neuropathic pain: a double-blind randomized controlled crossover trial with integral n-of-1 design. *Pain* 59:127-33, 1994.

Monma H, Ohta K, Takahashi S: A study of the newly developed α -tricalcium phosphate cement. *FC Rep* 6: 475, 1988.

Moure C, Qassemyar C, Dunaud O, Neiva C, Testelin S, Devauchelle B. Skeletal stability and morbidity with self-reinforced P (L/DL) LA resorbable osteosynthesis in bimaxillary orthognathic surgery. *J Craniomaxillofac Surg* 40: 55-60, 2012.

Nakagawa K, Ueki K, Matsumoto N, Takatsuka S, Yamamoto E, Ooe H: The assessment of trigeminal sensory nerve paraesthesia after bilateral sagittal split osteotomy: modified somatosensory evoked potentials recording method. *J Craniomaxillofac Surg* 25: 97-101, 1997.

Nakagawa K, Ueki K, Takatsuka S, Daisuke T, Yamaomoto E. Somatosensory-evoked potential to evaluate the trigeminal nerve after sagittal split osteotomy. *Oral Surg Oral Med Oral Pathol Oral Radiol Endod* 91: 146-152, 2001.

Nakagawa K, Ueki K, Takatsuka S, Yamamoto E: Trigeminal nerve hypesthesia after sagittal split osteotomy in setback cases: Correlation of postoperative computed tomography and long-term trigeminal somatosensory evoked potentials. *J Oral Maxillofac Surg* 61: 898-903, 2003.

Nelson RL, Path G, Ogle RG, Waite DE, Meyer MW. Quantitation of blood flow after Le Fort I osteotomy. *J Oral Surg* 977; 35:10-16.

Okabe K, Ueki K, Marukawa K, Mukozawa A, Miyazaki M, Nakagawa K: An experimental study of use of absorbable plate in combination with self-setting alpha-tricalcium phosphate for orthognathic surgery. *Oral Surg Oral Med Oral Pathol Oral Radiol Endod* 110: 560-9, 2010.

Posnick JC, Mohammed M, Al-Qattan M, Pron G. Facial sensitivity in adolescents with and without clefts 1 year after undergoing Le Fort I osteotomy. *Plast Reconstr Surg* 94:431-435, 1994.

Proffit WR, White RP, Sarver DM: Contemporary treatment of dentofacial deformity. 1st ed. St Louis: Mosby; 298-9, 2003.

Shikinami Y, Matsusue Nakamura T. The complete process of bioresorption and bone replacement using devices made of forged composite of raw hydroxyapatite particles/poly L-lactide (F-u-HA/PLLA). *Biomaterials* 26: 5542-51, 2005.

Shikinami Y, Okuno M. Bioresorbable devices made of forged composites of hydroxyapatite (HA) particles and poly-L-lactide (PLLA): Part I. Basic characteristics. *Biomaterials* 20: 859-77, 1999.

Shikinami Y, Okuno M. Bioresorbable devices made of forged composites of hydroxyapatite (HA) particles and poly-L-lactide (PLLA): Part II. Practical properties of miniscrews and miniplates. *Biomaterials* 22: 3197-211, 2001.

Ueki K, Hashiba Y, Marukawa K, Nakagawa K, Alam S, Yamamoto E. The evaluation of surgical factors related to recovery period of upper lip hypoesthesia after Le Fort I osteotomy. *J Craniomaxillofac Surg* 65: 900-4, 2008.

Ueki K, Hashiba Y, Marukawa K, Okabe K, Alam S, Nakagawa K, Yamamoto E. Assessment of pterygomaxillary separation in Le Fort I osteotomy in Class III patients. *J Oral Maxillofac Surg* 67: 833-9, 2009.

Ueki K, Miyazaki M, Okabe K, Mukozawa A, Marukawa K, Moroi A, Nakagawa K, Yamamoto E. Assessment of bone healing after Le Fort I osteotomy with 3-dimensional computed tomography. *J Craniomaxillofac Surg* 39:237-43, 2011a.

Ueki K, Nakagawa K, Marukawa K, Shimada M, Yoshida K, Hashiba Y, Shimizu C, Yamamoto E. Evaluation of upper lip hypoesthesia with a trigeminal somatosensory-evoked potential following Le Fort I osteotomy in combination with mandibular osteotomy. *Oral Surg Oral Med Oral Pathol Oral Radiol Endod.* 103:169-74, 2007.

Ueki K, Nakagawa K, Marukawa K, Yamamoto E. Le Fort I osteotomy using an ultrasonic bone curette to fracture the pterygoid plates. *J Craniomaxillofac Surg* 32: 381-6, 2004.

Ueki K, Okabe K, Miyazaki M, Mukozawa A, Marukawa K, Nakagawa K, Yamamoto E. Skeletal stability after mandibular setback surgery: Comparisons among unsintered hydroxyapatite/poly-L-lactic acid plate, poly-L-lactic acid plate and titanium plate. *J Oral Maxillofac Surg.* 69:1464-8, 2011b.

Ueki K, Okabe K, Marukawa K, Mukozawa A, Moroi A, Miyazaki M, Nakagawa k, Yamamoto E. Effect of self-setting α -tricalcium phosphate between segments for bone healing and hypoesthesia in lower lip after sagittal split ramus osteotomy. *J Craniomaxillofac Surg* 40: e119-24, 2012.

Yamamoto H, Niwa S, Hori M, Hattori T, Sawai K, Aoki S, Hirano M, Takeuchi H: Mechanical strength of calcium phosphate cement in vivo and in vitro. *Biomaterials* 19: 1587-91, 1998.

Yuan H, Li T, de Bruijn JD, de Groot K, Zhang X: Tissue response of calcium phosphate cement: a study in dogs. *Biomaterials* 21: 1283-90, 2000.

Legends

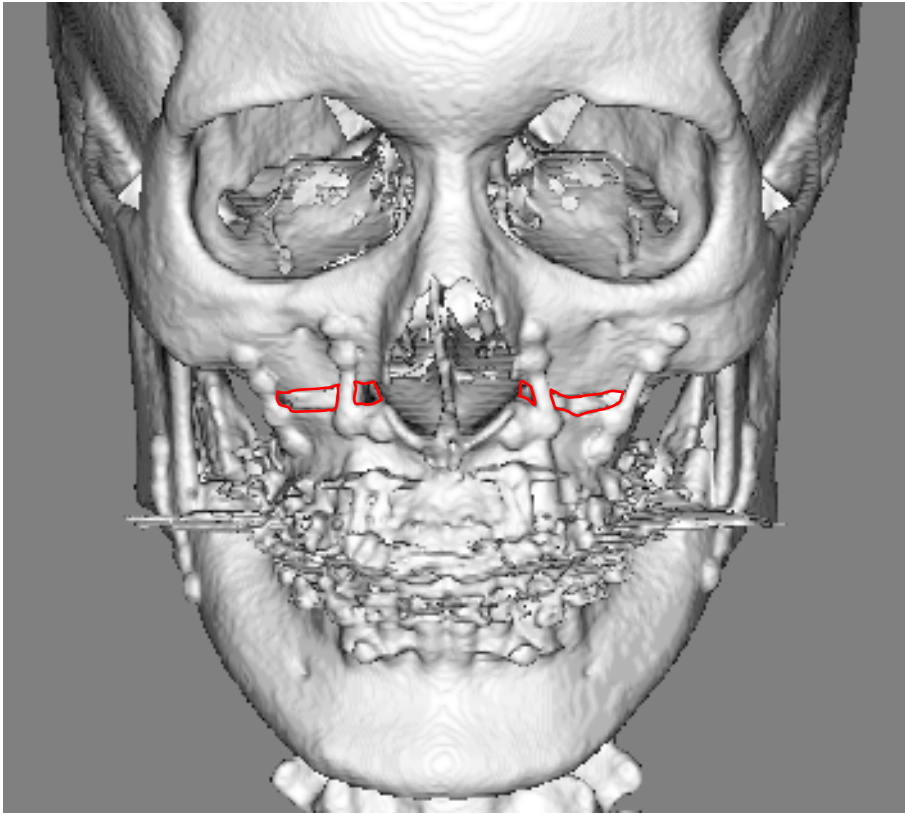
Fig.1 Measurements of the areas of bone defects on 3DCT image. A: immediately after surgery, B: 1 year after surgery. Red area shows a bone defect. uHA/PLLA plates were recognized. In this case, complete bone healing was not found after 1 year.

Fig. 2 Measurements of the area of Biopex® on 3DCT image. A: immediately after surgery, B: 1 year after surgery. Red area shows the Biopex®. Yellow area shows a 3D reconstruction image over 2200 HU and the transparent blue area shows a 3D reconstruction image from 1200 HU to 2200 HU. uHA/PLLA plates were recognized.

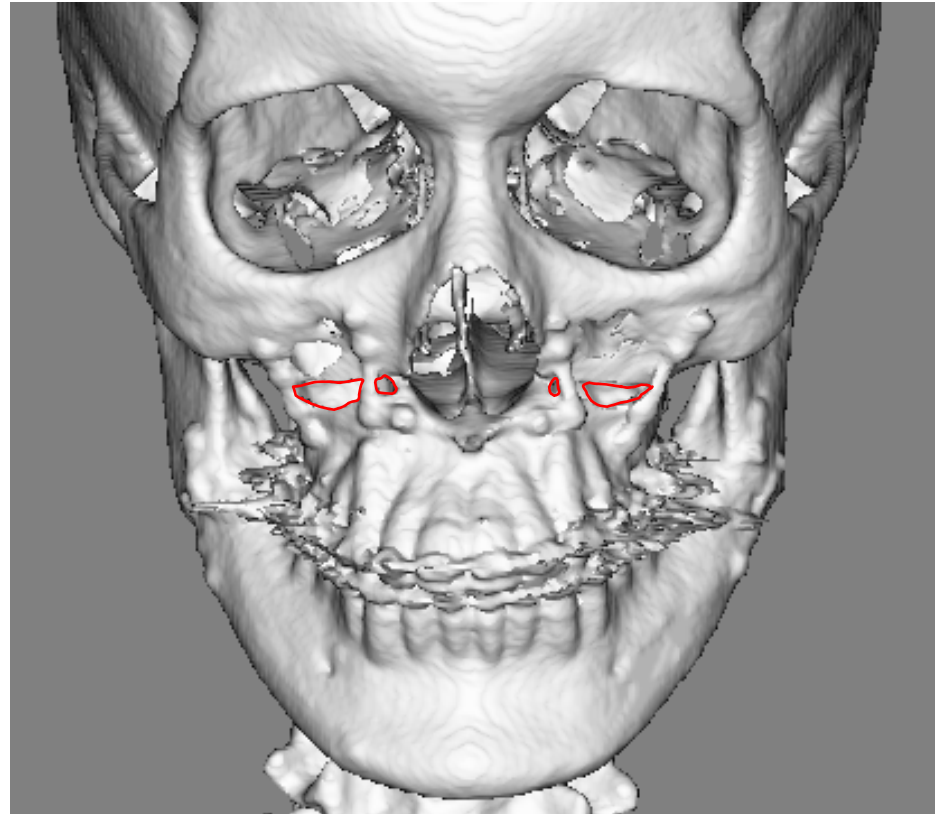
Fig. 3 A: The area of defects between segments. Error bars show the standard deviation. * indicates a significant difference at $P<0.05$. B: the area of Biopex®. Error bars show the standard deviation. * indicates a significant difference at $P<0.05$.

Table 1. A: The area of defects between segments. SD indicates standard deviation. B: the area of Biopex®. SD indicates standard deviation.

Table 2. Latency period in each peak of the TSEP wave. SD indicates standard deviation.

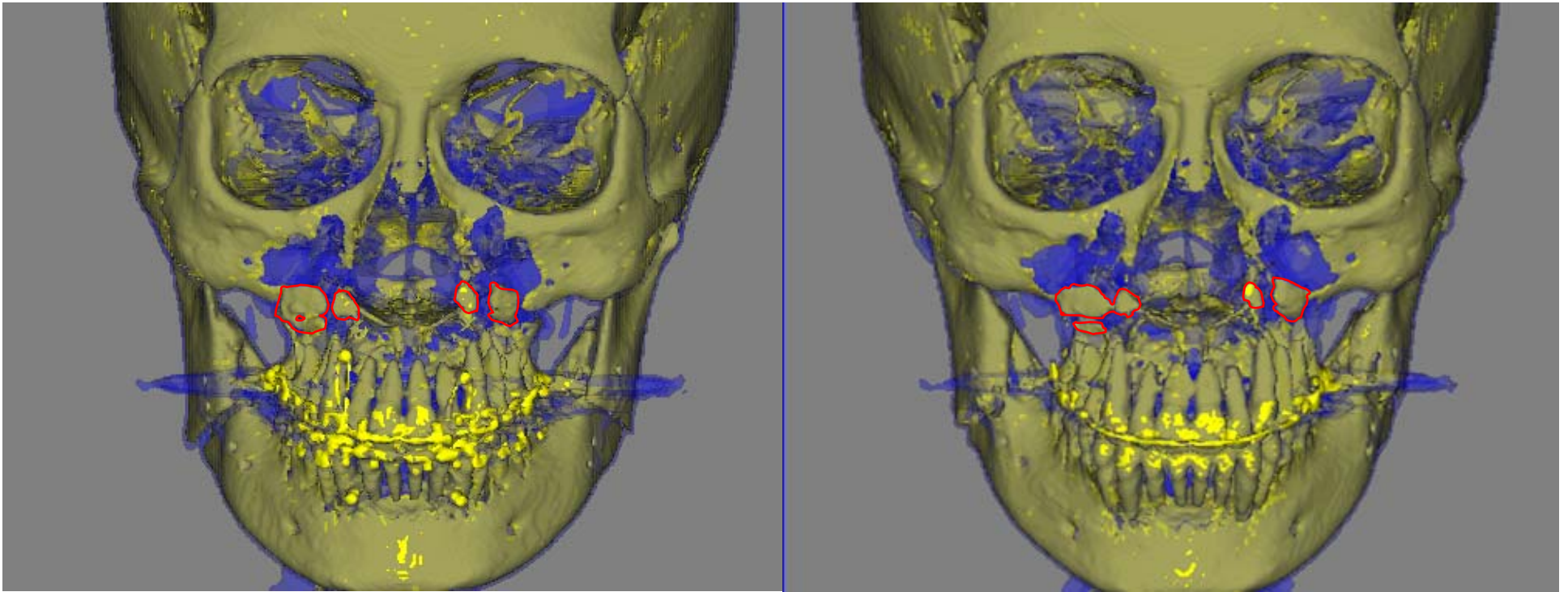


A



B

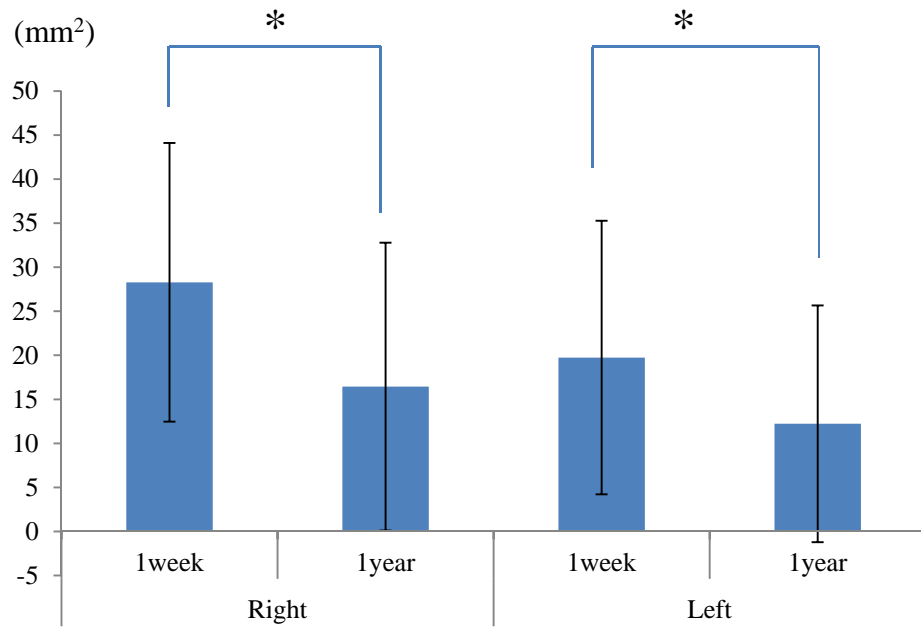
Fig. 1



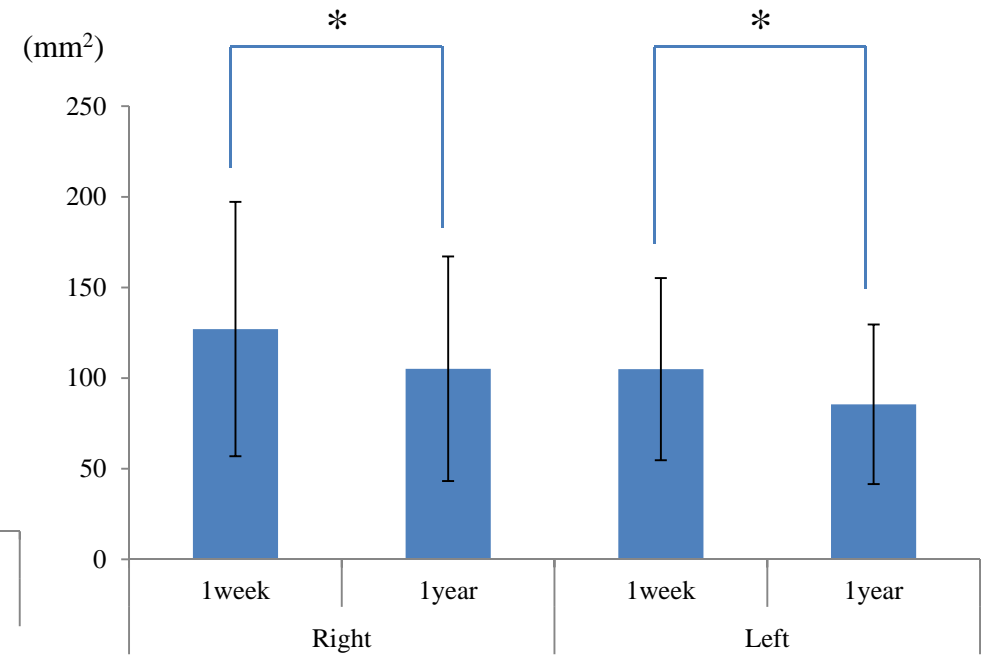
A

B

Fig. 2



A



B

Fig.3

		1week		1year		
		Mean	SD	Mean	SD	
		(mm ²)				
A	Area of bone defect	Right	28.3	15.8	16.5	16.3
		Left	19.7	15.5	12.2	13.5
<hr/>						
		1week		1year		
		Mean	SD	Mean	SD	
		(mm ²)				
B	Area of Biopex®	Right	127.0	70.2	105.2	62.0
		Left	104.9	50.3	85.6	44.0

Table. 1

	Latency period (Seconds)	N1		P1		N2		P2		Measurable period (weeks)	
		Mean	SD	Mean	SD	Mean	SD	Mean	SD	Mean	SD
Biopex® group	Pre-operation	13.7	1.3	17.8	1.5	27.3	2.2	37.2	2.0		
	Post-operation	15.6	1.6	20.1	2.1	29.8	3.0	39.5	3.4	14.5	17.9
Control group	Pre-operation	14.5	1.6	18.5	1.6	28.3	2.3	37.7	2.3		
	Post-operation	15.4	1.8	19.5	2.0	29.2	2.1	38.4	2.5	13.2	18.5

Table. 2