Participation of natural killer cells in the pathogenesis of bile duct lesions in biliary atresia

メタデータ	言語: English 出版者: 公開日: 2017-10-03 キーワード (Ja): キーワード (En): 作成者: Okamura, Atsushi, Harada, Kenichi, Nio, Masaki, Nakanuma, Yasuni メールアドレス: 所属:
URL	http://hdl.handle.net/2297/34330

Participation of natural killer cells in the pathogenesis of bile duct lesions in biliary atresia

Atsushi Okamura,[1) 2)*] Kenichi Harada,[1)*] Masaki Nio,[2)] and Yasuni Nakanuma[1)]

[1)]Department of Human Pathology, Kanazawa University Graduate School of Medicine, Kanazawa, and [2)]Department of Pediatric Surgery, Tohoku University Graduate School of Medicine, Sendai, Japan

Running title: NK cells in biliary atresia

Conflict of interest: No conflicts of interest

Financial support: This work was supported by grant No.23590393 from the Ministry of Education, Culture, Sports, Science and Technology of Japan (K.H.) and by Health and Labour Sciences Research Grants for the Research on Measures for Intractable Diseases.

Address correspondence to: Yasuni Nakanuma, M.D
Department of Human Pathology
Kanazawa University Graduate School of Medicine
Kanazawa 920-8640, Japan
Tel: +81-76-265-2197 (Japan)
Fax: +81-76-234-4229 (Japan)
E-mail: nakanuma@staff.kanazawa-u.ac.jp

Contribution of the authors: Dr. Okamura* and Dr. Harada* contributed equally in this study, and Dr. Nakanuma and Dr. Nio were mainly involved in the concept of this study and preparation of the manuscript.

Abstract

Aims: Immunological disturbances including innate immunity after a suspected viral infection are considered important to the pathogenesis of bile duct lesions in cases of biliary atresia (BA). Herein, we tried to evaluate whether natural killer (NK) cells and CX3CL1 (Fractalkine) and its receptor (CX3CR1) are involved in the bile duct injury. **Methods:** Using the section of BA (22 cases) and controls, immunohistochemistry for CD56, CD16, CD68, CX3CL1, and CX3CR1 was performed. Moreover, using cultured biliary epithelial cells (BECs) and NK cells, the production of CX3CL1 in BECs and the migration of NK cells were evaluated. **Results:** It was found that CD56(-)CD16(+)CD68(-) NK cells were increased around the damaged small and large bile ducts in BA and HCV-related chronic hepatitis in comparison with other controls. CX3CL1 was strongly expressed on the damaged bile ducts in BA, while this expression was relatively weak or absent in the bile ducts of normal liver. The results suggest the CD56(-)CD16(+) NK cells to be involved in the development of bile duct injuries in BA. These CD16(+) NK cells were positive for CX3CR1, and attracted by CX3CL1 expressed on bile ducts. Further study revealed that stimulation with poly(I:C) (a synthetic analogue of viral dsRNA) increased the expression of CX3CL1 on cultured BECs followed by increased migrational activity of cultured NK cells. **Conclusion:** CD56(-)CD16(+) NK cells with reduced NK activity may be involved in the bile duct damage in BA, and CD16(+) NK cells expressing CX3CR1 may be attracted by and interact with bile ducts expressing CX3CL1.

Key words; biliary tree, biliary epithelial cells, biliary atresia, natural killer cells, innate immunity

Introduction

Biliary atresia (BA) is a neonatal obstructive cholangiopathy characterized by the progressive destruction of extrahepatic bile ducts. Intrahepatic large bile ducts are also involved.[1] Clinical and experimental evidence suggests that a viral infection triggers the development of bile duct lesions in BA. The infection of newborn Balb/c-mice with Reoviridae (rotavirus and reovirus, dsRNA virus) leads to bile duct obstruction and cholestasis resembling human BA.[1] In this animal model, viral infections of the biliary tree and subsequent cellular autoimmunity against the bile ducts are important for progressive cholangiopathy and loss.[2,3] Reoviridae reportedly show epitheliotropism and apoptosis in intestinal epithelial cells.[1,2,4-6] We reported that human biliary epithelial cells (BECs) possess dsRNA-related innate immune systems via a dsRNA-recognizing receptor such as Toll-like receptor 3 (TLR3), suggesting that Reoviridae infections directly relate to the pathogenesis of cholangiopathies in BA.[7-11]

Natural killer (NK) cells constitute an important part of the first line of defense against many microbial infections, and play a significant role in immunity and the immunopathology of hepatobiliary diseases. The majority of NK cells which are strongly cytolytic effector cells fall within the CD56(+) subset. Recently, a population of CD56(-)CD16(+) NK cells has been described in human immunodeficiency virus (HIV) and hepatitis C virus (HCV)-infected patients: these cells have impaired cytolytic functions and cytokine production.[12-13] HIV and HCV infections have been strongly associated with a loss of CD56(+) NK cells, at least partly compensated for by an expansion in the number of CD56(-)CD16(+) cells.[5,12-13] This replacement of CD56-expressing NK cells by functionally defective CD56(-)CD16(+) NK cells might be one of the mechanisms by which HIV and HCV impair the overall NK cell response. Shivakumar et al reported NK cells in the vicinity of intrahepatic bile ducts in infants with BA.[14] It remains unclear whether NK cells play an important role in the pathology of BA.

CX3CL1 (Fractalkine) plays an important role in the cell migration to target sites under physiological as well as pathological conditions and is expressed on vascular endothelial cells and epithelial cells in

response to proinflammatory cytokines and TLR ligands. CX3CR1, a receptor of CX3CL1, is expressed on inflammatory cells including NK cells, suggesting that NK cells are attracted by CX3CL1 expressed in the liver, particularly around damaged bile ducts. Such a scenario has been shown in bile duct lesions in primary biliary cirrhosis (PBC).[15]

In this study, to clarify the participation of NK cells int the pathogenesis of cholangiopathy in BA, we first examined immunohistochemically the distribution of NK cells, particularly CD56(-)CD16(+) NK cells, in the liver tissue of BA patients. We also examined the expression of CX3CL1 on bile ducts and infiltration of mononuclear cells expressing CX3CR1, particularly around damaged bile ducts. Then, the migration of cultured NK cells was examined with respect to the expression and secretion of CX3CL1 in cultured BECs.

Materials and Methods

I. Tissue studies of liver and bile ducts

A. Anatomical classification of the biliary tree

Extrahepatic bile duct consists of the common hepatic and bile ducts, the right and left hepatic ducts, and their confluence. The branches of the right and left hepatic ducts are largely divided into the large intrahepatic bile duct and small intrahepatic bile ducts. The former roughly correspond to the first to third branches of the right and left hepatic ducts. The small bile ducts are further classified into the septal and interlobular bile ducts.[16] The peribiliary glands are present along the extrahepatic bile ducts and the large intrahepatic bile ducts, and the peribiliary vascular plexus is also identifiable around the bile ducts. In this study, the hilar bile ducts and intrahepatic large bile ducts are collectively called the large bile duct.

B. Case collection and preparation of liver and bile duct specimens

1) Case selection: The details of these cases are shown in Table 1. For the examination of small intrahepatic

bile ducts, 22 cases of BA, 9 cases of chronic viral hepatitis C (CH-C), 9 cases of nonalcoholic steatohepatitis (NASH), and 12 cases of normal liver were examined (43 cases were of needle or wedge liver biopsies and the remaining 9 cases, surgically resected). For the large bile duct, 21 cases of BA, 8 autopsy cases of fetus, and 4 normal controls were examined (all cases were surgically resected). Normal livers for small intrahepatic bile ducts and large bile ducts were from non-neoplastic parts of metastatic liver carcinoma.

2) Tissue preparation: All of these tissue specimens were fixed in 10% neutral buffered formalin and embedded in paraffin. More than 20 consecutive 4-μm-thick sections were cut from each paraffin block, and some of them were stained with hematoxylin and eosin (H&E) and Azan-Mallory stain for the identification of bile duct lesions. The remaining sections were used for immunohistochemistry.

C. Immunohistochemistry

Immunostaining was performed using formalin-fixed, paraffin-embedded tissue sections of BA patients and controls (other diseases). The primary antibodies and their sources, optimal dilution, and antigen retrieval method are shown in Table 2. The small bile ducts and large bile ducts and their surrounding areas were mainly examined.

1) Distribution of CD56(-)CD16(+)CD68(-) NK cells

Immunostaining: After antigen retrieval (pressure with citric acid method) for 20 minutes, immunostaining for CD56 was performed using the CSA II System (biotin-free tyramide signal amplification system, DakoCytomation). Color development was performed by a benzidine reaction. After microwaving with citric acid, the sections were incubated overnight at 4°C with a primary monoclonal antibody against CD68. The sections were then treated with secondary antibodies conjugated to a peroxidase-labeled polymer (EnVision system, DakoCytomation). Color development was performed using Histogreen. The sections were counterstained with hematoxylin. Expression of CD56 (brown) and CD68 (green) in the cytoplasm of mononuclear cells was regarded as positive. Negative controls were carried out. Cells positive for CD56 or

CD68 were identified around the small bile ducts and also beneath the large bile duct epithelia. Two areas around the small bile ducts and two areas beneath the large bile duct epithelia were photographed (Photograph A) in each case. After decolorization by microwaving with citric acid for 5 minutes in which green-colored CD68 was abolished, the sections were incubated overnight at 4°C with a primary monoclonal antibody for CD16, and the sections were then treated with secondary antibodies conjugated to a peroxidase-labeled polymer (EnVision system, DakoCytomation). Color development was performed using Histogreen. The sections were counterstained with hematoxylin. Negative controls were carried out. Cells positive for CD56 (brown) or CD16 (green) were identified around the small bile ducts and also beneath the large bile duct epithelia, and two areas in the former and two in the latter in the same areas as photographed in photo A were again photographed (Photograph B) in each case.

Semiquantitative evaluation: Photographs A and B in the same areas were compared, and CD56(-)CD16(+)CD68(-) NK cells, which were green in photo B but not photo A, were counted around the small bile ducts and also beneath the large bile duct epithelia. The average for the two photographs was regarded as the number of CD56(-)CD16(+)CD68(-) NK cells in each case.

2) Immunostaining of CX3CR1/CD16

Immunostaining*:* CX3CR1(+) mononuclear cells were characterized with respect to CD16 NK cells in BA. After blocking of the endogenous peroxidase and antigen retrieval for 20 minutes, the sections were incubated overnight at 4°C with a polyclonal rabbit anti-CX3CR1 antibody. The sections were then treated with secondary antibodies conjugated to a peroxidase-labeled polymer (EnVision system, DakoCytomation). Color development was performed by a benzidine reaction. After microwaving with citric acid, the sections were incubated overnight at 4°C with a primary monoclonal antibody against CD16. The sections were next treated with secondary antibodies conjugated to a peroxidase-labeled polymer (EnVision system, DakoCytomation). Color development was performed using Histogreen. The sections were counterstained with hematoxylin. Expression of CX3CR1 and CD16 in the cytoplasm of mononuclear cells was regarded as positive. Cells

positive for CX3CR1 (brown) or CD16 (green) identified around the small bile ducts and also beneath the large bile duct epithelia were evaluated in individual cases. Negative controls were carried out.

Semiquantitative evaluation: Double positive cells (CX3CR1 is brown and CD16 is green) were counted around the small bile ducts (two bile ducts) and beneath the large bile ducts (two areas) in BA patients and controls, and the average of two values for each case was regarded as the number of CX3CR1(+)CD16(+) NK cells in each case.

3) Immunostaining of CX3CL1

Immunostaining: After blocking of the endogenous peroxidase, the sections were incubated in protein block solution (DakoCytomation). The sections were incubated overnight at 4°C with primary polyclonal antibodies against CX3CL1. The sections were then treated with secondary antibodies conjugated to a peroxidase-labeled polymer (EnVision system, DakoCytomation). After a benzidine reaction, the sections were counterstained lightly with hematoxylin. Negative controls were also done.

Semiquantitative evaluation: CX3CL1 expression in bile ducts was evaluated as either absent/faint (±), slightly positive (+), or strongly positive (++).

II. Culture studies

A. Cultures of human BECs

A line of human biliary epithelial cells (BECs) was established and cultured as previously reported.[17] BECs were established from the explant liver of a 24 year-old male with BA. More than 95% of the cultured cells were confirmed to be BECs by the expression of biliary-type cytokeratins (CK7 and CK19). Informed consent for research was obtained from the patient prior to surgery. This study was approved by the Kanazawa University Ethics Committee. Cultured BECs were stimulated with polyinosinic-polycytidylic acid [poly(I:C), TLR3 ligand, a synthetic analogue of viral dsRNA; 25 µg/ml; Invitrogen, San Diego, CA, USA] and mRNA and supernatant of cells were used in the mRNA analysis and migration assay, respectively.

B. RT-PCR for CX3CL1

For the evaluation of the mRNA of CX3CL1 in cultured BECs, total RNA was isolated and 1μg was reverse-transcribed with an oligo-(dT) primer and reverse transcriptase to synthesize cDNA. The cDNA was amplified by PCR using specific primers designed to specifically amplify a 262bp portion of CX3CL1. As a positive control of the PCR, primers for the GAPDH gene mRNA were used. The PCR products were subjected to electrophoresis on 1.5% agarose gels containing ethidium bromide.

In addition, to carry out relative quantification, real-time quantitative PCR was performed for measurements of CX3CL1 mRNA according to a standard protocol using the SYBR Green PCR Master Mix and ABI PRISM 7700 Sequence Detection System (Applied Biosystems, Tokyo, Japan). Results are shown as relative mRNA expression compared with the level without any treatments (PBS). In addition, real-time quantitative PCR was performed for measurements of Notch1, Ascl1, and chromogranin A mRNAs according to a standard protocol using the Brilliant II SYBR Green QPCR Reagents and Mx300P QPCR system (Stratagene Japan, Tokyo, Japan) and relative gene expression was calculated using the comparative cycle threshold method. Specific primers were as follows: CX3CL1 forward, 5'-GATGGCTCCGATATCTCTG-3', and Reverse 5'-CTGCTGCATCGCGTCCTTG-3' and glyceraldehyde 3 phosphate dehydrogenase (GAPDH, internal positive control), forward, 5’-GGCCTCCAAGGAGTAAGACC-3’, and reverse, 5’-AGGGGTCTACATGGCAACTG-3’.

C. Migration assay of NK cells with cultured BECs

1) Preparation of cultured NK cells: NK cells were isolated from the peripheral blood mononuclear cells of a healthy volunteer according to MACS protocols of the NK cell isolation kit (MACS, Miltenyi Biotec K.K., Tokyo, Japan). These cells were maintained on culture dishes with standard medium, Lymphocyte Growth Medium-3 (Takara, Ohtsu, Japan) at 37°C in 95% air and 5% CO2.

2) Migration assay of NK cells with cultured BECs stimulated by poly(I:C): The chemoattractant activity of CX3CL1 secreted by cultured BECs stimulated with poly(I:C) was assessed in 96-well plates assembled with

the Cultrex® 96-well collagen I cell invasion assay (Treigen, Gaithersburg, MD) according to the manufacturer's directions using isolated NK cells expressing CX3CR1 and showing efficient chemotaxis and adherence in a CX3CL1-dependent manner. Briefly, the NK cell suspension was seeded and the supernatant of BECs cultured with poly(I:C) for 3 days or the human recombinant CX3CL1 (10ng/mL, PeproTech, Rocky Hill, NJ) was added to lower wells at 1:100 or 1:10. After 24 hours, the transferred cells were collected and their number was evaluated by optical density (OD).

Statistical analysis

Numerical data are presented as the mean±standard deviation (SD). Data from different groups were compared using a one-way analysis of variance and examined with the Mann-Whitney U-test. Differences in the proportions of categorical data were tested using the Chi-square test. The correlation coefficient of two factors was evaluated using Spearman's rank correlation test. For the migration assay of NK cells, Welch's t test was used. The results were considered significant if the p value was <0.05.

Results

I. Tissue studies of liver and bile ducts

1. Infiltration of CD56(-)CD16(+)CD68(-)NK cells

Small bile ducts: In normal livers, there were no or few CD56(-)CD16(+)CD68(-) NK cells in portal tracts. In contrast, in diseased livers including BA, there were variable numbers of such NK cells admixed with other inflammatory cells, and these cells were rather frequent in BA (Fig. 1A,B,C,D). Their numbers counted around small bile ducts are plotted in Fig. 1E. The cells were rather dense in BA in comparison with NASH and normal livers ($p<0.01$).

Large bile ducts: There were no or few CD56(-)CD16(+)CD68(-) NK cells beneath biliary epithelia of the large bile duct in normal adult livers, while they were identifiable in BA (Fig. 2A,B,C,D). Their numbers are

plotted in Fig. 2E. They were more abundant in BA than in normal livers ($p<0.01$).

2. Immunohistochemistry for CX3CL1

A. Infiltration of CX3CR1(+)CD16(+) mononuclear cells

Small bile ducts: CX3CR1(+)CD16(+) mononuclear cells admixed with other inflammatory cells were frequently present in portal tracts around damaged small bile ducts in cases of BA (Fig. 3A), while such cells were sparse in cases of other liver diseases and normal livers (Fig. 3B). Their number in the portal tracts is plotted in Fig. 3C. They were rather dense in BA in comparison with other liver diseases and normal livers.

Large bile ducts: CX3CR1(+)CD16(+) mononuclear cells admixed with other inflammatory cells were found around the large bile ducts in cases of BA, but were not found in normal livers. The incidence of these cells is shown in Fig. 3D.

B. Expression of CX3CL1 in bile ducts

Small bile ducts: In normal livers, small bile ducts were generally negative or faintly positive for CX3CL1, and endothelial cells of small vessels of PBP were negative or slightly positive for CX3CL1 (Fig. 4A). In CH-C, and NASH livers, small bile ducts were negative or slightly positive for CX3CL1. Small bile ducts of BA patients were strongly positive for CX3CL1 (Fig. 4B). The incidence of small bile ducts with mild to moderate and strong expression in normal liver, BA and other liver diseases is shown in Fig. 4C. Endothelial cells around injured interlobular bile ducts of BA patients also were strongly positive for CX3CL1 and their intensity was higher in comparison with other disease controls (Fig. 4A and 4B).

Large bile ducts: CX3CL1 was not expressed or only faintly expressed in large bile ducts and peribiliary glands and PBP in normal livers (Fig. 5A), while it was strongly expressed in biliary epithelial cells of large bile ducts and peribiliary glands in cases of BA and also endothelial cells of PBP around large bile ducts in BA (Fig. 5B,C), while such expression was faint or absent in normal livers. The incidence of bile ducts with mild to moderate and strong expression of CX3CL1 is shown in Fig. 5D.

II. Culture studies

1. Expression of CX3CL1 **mRNA in cultured BECs treated with poly(I:C)**

RT-PCR revealed that the amplicon of CX3CL1 mRNA could not be detected in cultured BECs without any stimulants (PBS), whereas treatment with poly(I:C) induced its expression (Fig. 6A). As shown in Fig. 6B, real-time PCR analysis revealed that treatment with poly(I:C) significantly up-regulated the expression of CX3CL1 mRNA 21.9-fold (Fig. 6B).

2. Migration of NK cells

Optical density reflecting the number of NK cells that transmigrated was significantly increased in the bottom chamber containing recombinant CX3CL1 and supernatant of poly(I:C)-treated BECs, compared with that containing the negative control medium (PBS). The effect of the supernatant was concentration (dose)-dependent (Fig. 7).

Discussion

The findings obtained in this study can be summarized as follows: i) CD56(-)CD16(+) NK cells were increased around the small bile ducts and beneath the biliary epithelia of large bile ducts in comparison with other diseases and normal livers, ii) such CD16(+) cells expressed CX3CR1, a receptor of CX3CL1, iii) CX3CL1 was strongly expressed in BECs of small bile ducts and also of large bile ducts in BA, and iv) stimulation with poly(I:C) (a synthetic analogue of viral dsRNA) increased the expression of CX3CL1 on cultured BECs and increased migration of cultured NK cells.

The pathogenesis of BA may be the virus-induced autoimmune-mediated injury of bile ducts.[6] In fact, Reoviridae (type 3 reovirus and type C rotavirus) and herpes virus including cytomegalovirus have all been considered possible candidates for the initiating agent.[1] Studies in the rotavirus mouse model of BA indicate that a viral infection of the biliary epithelium is an initial event leading to biliary inflammation and obstruction

and autoreactive T cells and autoantibodies specific to bile duct epithelia have been reported.[3,18] Specific host factors related to innate and acquired immunopathologic processes with respect to viral infection may also play a key role in experimental BA.[18] Recently, many genetic studies, moreover, have recently reported. Genomic study including genome-wide association study identified a susceptibility locus for BA on 10q24.2 and 2q37.3.[19-20] Moreover, DNA hypermethylation at the CD11a locus in CD4+ cells, polymorphisms of vascular endothelial growth factor gene, and two microRNAs (miR-29a/29b1) may contribute significantly to BA susceptibility, but polymorphisms of IL-4, IL-18, IFN-γ genes were unlikely.[21-26] These genetic analyses revealed a link to the susceptibility to BA with respect of immunopathologic processes.

Recent studies showed the roles of NK cells in addition to T cells in the destruction of extrahepatic bile ducts in BA.[18,27] That is, the inflammatory milieu from portal tracts and/or biliary remnants showed greater numbers of T cells and NK cells, and up-regulation of CD8(+) costimulatory molecules in BA.[27] In experimental BA, activated NK cells were reportedly the most abundant cells in extrahepatic bile ducts and such NK cells were regarded as key initiators of bile duct injury.[14] However, the exact roles of NK cells and their phenotypic and functional alterations have not been studied in BA.

The CD56(-)CD16(+) NK subset is greatly expanded in HIV-viremic individuals.[28] The CD56(-) NK fraction was associated with extremely poor in vitro cytotoxic functions.[28] In addition, the secretion of certain cytokines important for initiating antiviral immune responses was markedly reduced in the CD56(-) NK cells. Elevated levels of CD56(-) NK cells are also found in many CH-C patients.[5,6] These CD56(-) NK cells were functionally impaired with respect to cytokine production upon target cell recognition.[29] Furthermore, high levels of these cells reveal a disturbance in innate cellular immunity that is associated with an impaired ability to respond to antiviral treatment with IFN-α and ribavirin. Taken together, these findings suggest that the expansion of this highly dysfunctional CD56(-) NK cell subset in humans infected with HIV-1 and HCV largely accounts for the impaired function of the total NK cell population.[12] So far, such issues have not been examined in BA.

It was found in this study that CD56(-)CD16(+) NK cells were increased around the damaged small and large bile ducts in BA, and the proportion of these cells was relatively high in BA in comparison with controls, suggesting that increased CD56(-)CD16(+) NK cells with reduced NK activities were involved in the development of bile duct injuries in BA. It seems possible that inadequate removal of BECs infected with cholangiotrophic virus by abundant CD56(-)CD16(+) NK cells with reduced antiviral activities leads to the induction of secondary immunization against the cholangiotrophic virus as well as BECs in BA. Cross-reactivity between viral and self-antigens is also proposed to trigger secondary autoimmunity.[2,6] This may be in turn followed by extensive autoimmune-mediated destruction of the bile ducts by CD8(+) cytotoxic T cells and other effector cells. CD8(+) T cells were reportedly necessary for induction of bile duct injury and obstruction in an experimental model of BA with autoimmune features.[30]

It was also found in this study that CD16(+) NK cells were positive for CX3CR1, and CX3CL1 was strongly expressed on the damaged bile ducts in BA. While the expression of CX3CL1 was relatively weak or absent in the bile ducts of normal liver and CH-C, CX3CL1 was also strongly expressed in the damaged bile ducts in PBC, in which the interaction of CX3CR1-expressing lymphocytes and CX3CL1-expressing bile ducts and endothelial cells of PBP is important in the bile duct destruction.[15] CX3CL1 is a chemokine with both chemoattractant and cell-adhesive functions, and in the intestine it is involved with its receptor CX3CR1 in the chemoattraction and recruitment of intraepithelial lymphocytes.[15] It seems likely that CD16(+) NK cells with expression of CX3CR1 may be chemoattracted and infiltrate around the bile ducts expressing CX3CL1 and this may be followed by the immunological interaction of NK cells and bile ducts, possibly virus infected.

Expression of CX3CL1 in human BECs in response to a TLR3 ligand, poly(I:C), was examined using a human intrahepatic BEC line. Consequently, the expression of CX3CL1 mRNA was low under normal conditions, but significantly up-regulated by the stimulation with poly(I:C). We have already reported that BECs express multiple functionally active TLRs and respond to the corresponding bacterial or viral TLR

ligands including poly(I:C).[7] Moreover, we previously demonstrated the diffuse expression of TLR3 in extrahepatic and intrahepatic bile ducts of patients with biliary atresia. Therefore, BECs infected by Reoviridae (reovirus and rotavirus) having a double-strand RNA are speculated to induce the expression of CX3CL1 via biliary innate immunity in biliary atresia patients. Moreover, the chemotaxis of human NK cells expressing the CX3CL1 ligand CX3CR1, and showing efficient chemotaxis and adherence in a CX3CL1-dependent manner was assayed using a cell invasion assay kit. The human NK cells showed chemotaxis toward recombinant CX3CL1 and also the culture medium which was speculated to contain CX3CL1 secreted by poly(I:C)-stimulated BECs. Therefore, dsRNA viruses in the microenvironment of injured bile ducts resulting from BA induce the upregulation of CX3CL1 expression in BECs, followed by the chemoattraction of CX3CR1-expressing mononuclear cells including NK cells, and their adhesion to BECs.

The elevation of CD56(-)CD16(+) NK subset was reported in the peripheral blood mononuclear cell of HCV- and HIV- infected patients.[13] We could confirm the increase of CD56(-)CD16(+)CD68(-) NK cells in liver specimens of CH-C as well as BA by the immunohistochemistry, though statistical significance was not obtained in CH-C, compared with NASH and normal liver. Therefore, impaired NK function caused by an increased CD56(-)CD16(+) NK subset in liver tissue is presumable in BA and CH-C, but not NASH or normal livers. Moreover, it is speculated that these NK cells were attracted by CXCL1 produced in BECs via an innate immunity against virus. This scenario might be common in several virus-related diseases including CH-C and BA.

Take home messages

- CD56(-)CD16(+) NK cells with reduced NK activities accumulated around damaged small and large bile ducts may be involved in the development of BA.
- By the biliary innate immunity for dsRNA, BECs expressed CX3CL1, which may attract CD16(+) NK cells around the damaged bile ducts.

- These findings may be followed by acquired immunity against the infected bile ducts.

References

1. Sokol RJ, Mack C. Etiopathogenesis of biliary atresia. Semin Liver Dis 2001; 21: 517-524.
2. Al-Masri AN, Flemming P, Rodeck B, et al. Expression of the interferon-induced Mx proteins in biliary atresia. J Pediatr Surg 2006; 41: 1139-1143.
3. Bjorkstrom NK, Ljunggren HG, Sandberg JK. CD56 negative NK cells: origin, function, and role in chronic viral disease. Trends Immunol 2010; 31: 401-406.
4. Sharland A, Gorrell MD. Cooperation of innate and adaptive immunity in the pathogenesis of biliary atresia: there's a killer on the run. Hepatology 2009; 50: 2037-2040.
5. Mack CL. The pathogenesis of biliary atresia: evidence for a virus-induced autoimmune disease. Semin Liver Dis 2007; 27: 233-242.
6. Shivakumar P, Sabla G, Mohanty S, et al. Effector role of neonatal hepatic CD8+ lymphocytes in epithelial injury and autoimmunity in experimental biliary atresia. Gastroenterology 2007; 133: 268-277.
7. Mack CL, Tucker RM, Lu BR, et al. Cellular and humoral autoimmunity directed at bile duct epithelia in murine biliary atresia. Hepatology 2006; 44: 1231-1239.
8. Harada K, Sato Y, Itatsu K, et al. Innate immune response to double-stranded RNA in biliary epithelial cells is associated with the pathogenesis of biliary atresia. Hepatology 2007; 46: 1146-1154.
9. Nakanuma Y, Harada K, Sato Y, et al. Recent progress in the etiopathogenesis of pediatric biliary disease, particularly Caroli's disease with congenital hepatic fibrosis and biliary atresia. Histol Histopathol 2010; 25: 223-235.
10. Harada K, Nakanuma Y. Biliary innate immunity in the pathogenesis of biliary diseases. Inflamm Allergy Drug Targets 2010; 9: 83-90.
11. Harada K, Nakanuma Y. Biliary innate immunity: function and modulation. Mediators Inflamm 2010; 2010.
12. Hong HS, Eberhard JM, Keudel P, et al. Phenotypically and functionally distinct subsets contribute to the expansion of CD56-/CD16+ natural killer cells in HIV infection. AIDS 2010; 24: 1823-1834.
13. Hong HS, Eberhard JM, Keudel P, et al. HIV infection is associated with a preferential decline in less-differentiated CD56dim CD16+ NK cells. J Virol 2010; 84: 1183-1188.
14. Fauci AS, Mavilio D, Kottilil S. NK cells in HIV infection: paradigm for protection or targets for ambush. Nat Rev Immunol 2005; 5: 835-843.
15. Shivakumar P, Sabla GE, Whitington P, et al. Neonatal NK cells target the mouse duct epithelium via Nkg2d and drive tissue-specific injury in experimental biliary atresia. J

Clin Invest 2009; 119: 2281-2290.

16. Isse K, Harada K, Zen Y, et al. Fractalkine and CX3CR1 are involved in the recruitment of intraepithelial lymphocytes of intrahepatic bile ducts. Hepatology 2005; 41: 506-516.
17. Nakanuma Y, Hoso M, Sanzen T, et al. Microstructure and development of the normal and pathologic biliary tract in humans, including blood supply. Microsc Res Tech 1997; 38: 552-570.
18. Harada K, Ohba K, Ozaki S, et al. Peptide antibiotic human beta-defensin-1 and -2 contribute to antimicrobial defense of the intrahepatic biliary tree. Hepatology 2004; 40: 925-932.
19. Garcia-Barceló MM, Yeung MY, Miao XP, Tang CS, Cheng G, So MT, Ngan ES, Lui VC, Chen Y, Liu XL, Hui KJ, Li L, Guo WH, Sun XB, Tou JF, Chan KW, Wu XZ, Song YQ, Chan D, Cheung K, Chung PH, Wong KK, Sham PC, Cherny SS, Tam PK. Genome-wide association study identifies a susceptibility locus for biliary atresia on 10q24.2. Hum Mol Genet. 2010;15;19(14):2917-25.
20. Leyva-Vega M, Gerfen J, Thiel BD, Jurkiewicz D, Rand EB, Pawlowska J, Kaminska D, Russo P, Gai X, Krantz ID, Kamath BM, Hakonarson H, Haber BA, Spinner NB. Genomic alterations in biliary atresia suggest region of potential disease susceptibility in 2q37.3. Am J Med Genet A. 2010;152A(4):886-95.
21. Lee HC, Chang TY, Yeung CY, Chan WT, Jiang CB, Chen WF, Chan HW, Yang HW, Lin M, Lee YJ. Genetic variability of interleukin4 gene in Taiwanese children with biliary atresia. Cytokine. 2012 Mar;57(3):402-5.
22. Lee HC, Chang TY, Yeung CY, Chan WT, Jiang CB, Chan HW, Chen WF, Yang HW, Lin M, Lee YJ. Association of polymorphisms in the Interleukin-18 gene with susceptibility to biliary atresia. J Pediatr Gastroenterol Nutr. 2011;52(5):607-11.
23. Lee HC, Chang TY, Yeung CY, Chan WT, Jiang CB, Chen WF, Chan HW, Liu HF, Lin M, Lee YJ. Association of interferon-gamma gene polymorphisms in Taiwanese children with biliary atresia. J Clin Immunol. 2010;30(1):68-73.
24. Lee HC, Chang TY, Yeung CY, Chan WT, Jiang CB, Chen WF, Chan HW, Liu HF, Lin M, Lee YJ. The VEGF +936 C/T polymorphism and particularly the C allele are associated with BA, possibly conferring increased susceptibility to the disease. J Clin Gastroenterol. 2010;44(2):135-9.
25. Dong R, Zhao R, Zheng S, Zheng Y, Xiong S, Chu Y. Abnormal DNA methylation of ITGAL (CD11a) in CD4+ T cells from infants with biliary atresia. Biochem Biophys Res Commun. 2012,20;417(3):986-90.
26. Dong R, Zhao R, Zheng S. Changes in epigenetic regulation of CD4+ T lymphocytesin biliary atresia. Pediatr Res. 2011;70(6):555-9.
27. Hertel PM, Estes MK. Rotavirus and biliary atresia: can causation be proven? Curr Opin

Gastroenterol 2012; 28: 10-17.

28. Guo C, Zhu J, Pu CL, et al. Combinatory effects of hepatic CD8+ and NK lymphocytes in bile duct injury from biliary atresia. Pediatr Res 2012; 71: 638-644.
29. Mavilio D, Lombardo G, Benjamin J, et al. Characterization of CD56-/CD16+ natural killer (NK) cells: a highly dysfunctional NK subset expanded in HIV-infected viremic individuals. Proc Natl Acad Sci U S A 2005; 102: 2886-2891.
30. Turner R, Lozoya O, Wang Y, et al. Human hepatic stem cell and maturational liver lineage biology. Hepatology 2011; 53: 1035-1045.

Table 1. Main clinical features of cases examined

Cases for the study of intrahepatic small bile ducts

	Age (mean±SD; range)	Sex (M:F)
Biliary atresia (n=22)	1.77±0.86 m; 0.7－12 m	10:12
Chronic viral hepatitis C (n=9) [a)]	59.0±13.0 y; 27－72 y	4:5
Nonalcoholic steatohepatitis (n=9) [b)]	44.4±14.4 y; 25－69 y	3:6
Adult normal liver (n=12)	62.1±13.1 y; 47－82 y	6:6

Cases for study of large bile ducts

	Age (mean±SD; range)	Sex (M:F)
Biliary atresia (n=21)	1.71±0.81 m; 0.7－12 m	9:12
Normal common bile duct (fetus) [c)] (n=8)		6:2
Adult normal liver [d)] (n=4)	58.7±17.0 y; 42－76 y	2:2

m, months; y, years; M, male; F, female; n, number of cases; a), staging; stage 1, 6 cases; stage 2, 0 cases; stage 3, 0 cases; stage 4, 3 cases ; b), staging; stage 1, 2 cases; stage 2, 3 cases; stage 3, 3 cases; stage 4, 1 cases ; c), autopsy cases of fetus ; d), surgical cases

Table 2. Antibodies used in this study

Primary antibody against	Type of antibody and immunized animal	Clone	Dilution	Source	Antigen retrieval method
CD16	Monoclonal (mouse)	2H7	1: 200	Leica, Tokyo, Japan	microwave
CD56	Monoclonal (mouse)	1B6	diluted*	Nichirei, Tokyo, Japan	pressure cooker
CD68	Monoclonal (mouse)	PG-M1	diluted*	Nichirei, Tokyo, Japan	microwave
CX3CL1 (Fractalkine)	Polyclonal (rabbit)		1: 500	Immuno-Biological Laboratories, Fujioka, Japan	microwave
CX3CR1	Polyclonal (rabbit)		1: 1000	Immuno-Biological Laboratories, Fujioka, Japan	microwave

*, already diluted; microwave, microwaved in 10mM citrate buffer for 20 minutes in a microwave oven; pressure cooker, treated in 10mM citrate buffer pressure cooker

Figure legends

Fig. 1 Density of CD56(-)CD16(+)CD68(-) NK cells around intrahepatic small bile ducts. (A,C) Expression of CD56 (brown) and CD68 (green). (B,D) Expression of CD56 (brown) and CD16 (green). Two photographs in the same areas of NASH (A,B) were compared. CD56(-)CD16(+)CD68(-) NK cells were green in photo B but not photo A. There were no or few CD56(-)CD16(+)CD68(-) NK cells in portal tracts. In contrast, in BA (C,D), there were variable numbers of such NK cells admixed with other infiltrated inflammatory cells. (E) The number of such NK cells around small bile ducts is rather high in BA in comparison with NASH and normal livers. Mean±SD in BA, CVH-C, NASH, and adult normal livers were 4.37±3.83, 3.00±2.06, 0.11±0.33, and 0.58±0.66, respectively. Effect size and confidence interval; BA vs CVH-C (effect size=0.18, confidence interval -1.39 to 4.14), BA vs NASH (effect size=051, confidence interval 1.63 to 6.90), and BA vs adult normal livers (effect size=0.50, confidence interval 1.51 to 6.07). Bars indicate the mean±SD. *<0.01.

Fig. 2 Density of CD56(-)CD16(+)CD68(-) NK cells around large bile ducts. (A,B) There were no or few CD56(-)CD16(+)CD68(-) NK cells beneath biliary epithelia of the large bile duct in normal adult livers. (C,D) Such NK cells were identifiable in BA. (E) These cells were more abundant in BA than in normal livers. Mean±SD in BA, CBD of fetus, and adult large bile ducts were 2.50±2.34, 2.00±1.41, and 0.33±0.57, respectively. Effect size and confidence interval; BA vs CBD of fetus (effect size=0.08, confidence interval -1.44 to 2.20) and BA vs adult large bile ducts (effect size=0.58, confidence interval 0.66 to 3.10). Bars indicate the mean±SD. *<0.01.

Fig. 3 CX3CR1(+)CD16(+) mononuclear cells around intrahepatic bile ducts. (A) CX3CR1(+)CD16(+)

mononuclear cells were frequently present in portal tracts around damaged small bile ducts in BA. (B) Such cells were sparse in normal livers and other liver diseases. (C) They were rather dense in BA in comparison with other liver diseases and normal livers. Mean±SD in BA, CVH-C, NASH, and adult normal livers were 4.30±3.03, 1.88±1.05, 0.77±0.83, and 1.50±1.37, respectively. Effect size and confidence interval; BA vs CVH-C (effect size=0.39, confidence interval 0.28 to 4.55), BA vs NASH (effect size=053, confidence interval 1.41 to 5.64), and BA vs adult normal livers (effect size=0.39, confidence interval 0.166 to 5.44). (D) CX3CR1(+)CD16(+) mononuclear cells were found around the large bile ducts in BA, but not in normal livers of fetuses or adults. Mean±SD in BA, CBD of fetus, and adult large bile ducts were 6.66±2.41, 0.50±0.53, and 0.75±0.50, respectively. Effect size and confidence interval; BA vs CBD of fetus (effect size=0.81, confidence interval 4.38 to 7.95) and BA vs adult large bile ducts (effect size=0.71, confidence interval 3.37 to 8.47). Bars indicate the mean±SD. *<0.05.

Fig. 4 Expression of CX3CL1 in intrahepatic small bile duct epithelia. (A) Normal livers. Small bile ducts were generally negative or faintly positive for CX3CL1. (B) BA. Small bile ducts were strongly positive for CX3CL1. (C) The incidence of small bile ducts with mild to moderate and strong expression in normal liver, BA and other liver diseases.

Fig. 5 Expression of CX3CL1 in large bile duct epithelia. (A) CX3CL1 was not or faintly expressed in large bile ducts and peribiliary glands and PBP of normal livers. (B,C) It was strongly expressed in biliary epithelial cells of large bile ducts and peribiliary glands and also endothelial cells of PBP around large bile ducts in BA. (D) The incidence of bile ducts with mild to moderate and strong expression of CX3CL1. *<0.01.

Fig. 6 Expression of CX3CL1 mRNA in cultured human biliary epithelial cells (BECs). (A) Representative images of RT-PCR using cultured BECs. The amplicon of CX3CL1 mRNA could not be detected without the stimulant (-). de novo expression was found in the poly(I:C)-treated cells 3h after treatment with poly(I:C). (B) Quantitative analysis using real-time PCR revealed the increase in the level of CX3CL1 mRNA on poly(I:C) treatment to be 21.9±2.2 (mean±SEM)-fold and statistically significant compared to that without treatment (effect size=0.97, confidence interval -26.09 to -15.61). Results were obtained from four independent experiments. Bars indicate the mean±SEM. *<0.05.

Fig. 7 Migration assay of NK cells. Optical density (OD) reflecting the number of transmigrated NK cells was significantly increased in the lower chamber containing recombinant CX3CL1 (10ng/ml, OD=0.49±0.02 (mean±SEM), effect size=0.66, confidence interval -0.09 to -0.01) and supernatant of poly(I:C)-treated BEC diluted 1:100 (OD=0.47±0.02, effect size=0.51, confidence interval -0.08 to 0.01) and 1:10 (OD=0.51±0.02, effect size=0.73, confidence interval -0.12 to -0.02), compared with that containing the negative control medium (PBS, OD=0.44±0.008). Results were obtained from eight independent experiments. Bars indicate the mean±SEM. *<0.05.

Table 1. Main clinical features of cases examined

Cases for the study of intrahepatic small bile ducts

	Age (mean±SD; range)	Sex (M:F)
Biliary atresia (n=22)	1.77±0.86 m; 0.7－12 m	10:12
Chronic viral hepatitis C (n=9) [a)]	59.0±13.0 y; 27－72 y	4:5
Nonalcoholic steatohepatitis (n=9) [b)]	44.4±14.4 y; 25－69 y	3:6
Adult normal liver (n=12)	62.1±13.1 y; 47－82 y	6:6

Cases for study of large bile ducts

	Age (mean±SD; range)	Sex (M:F)
Biliary atresia (n=21)	1.71±0.81 m; 0.7－12 m	9:12
Normal common bile duct (fetus) [c)] (n=8)		6:2
Adult normal liver [d)] (n=4)	58.7±17.0 y; 42－76 y	2:2

m, months; y, years; M, male; F, female; n, number of cases; a), staging; stage 1, 6 cases; stage 2, 0 cases; stage 3, 0 cases; stage 4, 3 cases ; b), staging; stage 1, 2 cases; stage 2, 3 cases; stage 3, 3 cases; stage 4, 1 cases ; c), autopsy cases of fetus ; d), surgical cases

Table 2. Antibodies used in this study

Primary antibody against	Type of antibody and immunized animal	Clone	Dilution	Source	Antigen retrieval method
CD16	Monoclonal (mouse)	2H7	1 : 200	Leica, Tokyo, Japan	microwave
CD56	Monoclonal (mouse)	1B6	diluted*	Nichirei, Tokyo, Japan	pressure cooker
CD68	Monoclonal (mouse)	PG-M1	diluted*	Nichirei, Tokyo, Japan	microwave
CX3CL1 (Fractalkine)	Polyclonal (rabbit)		1 : 500	Immuno-Biological Laboratories, Fujioka, Japan	microwave
CX3CR1	Polyclonal (rabbit)		1 : 1000	Immuno-Biological Laboratories, Fujioka, Japan	microwave

*, already diluted; microwave, microwaved in 10mM citrate buffer for 20 minutes in a microwave oven; pressure cooker, treated in 10mM citrate buffer pressure cooker

Fig. 1

CD56(DAB)CD68(Green)

CD56(DAB)CD16(Green)

NASH

BA

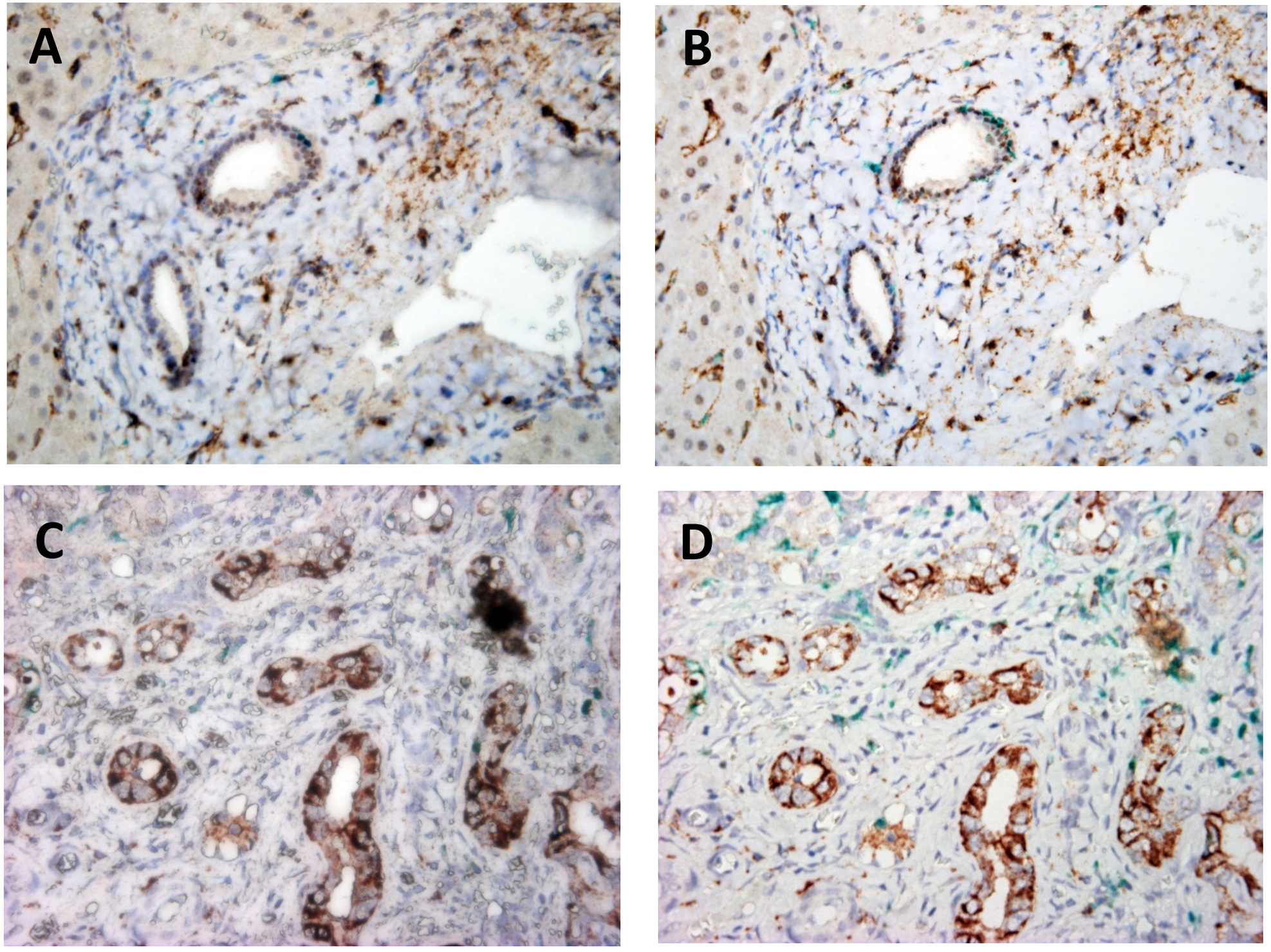

Fig. 1E Density of CD56(-)CD16(+)CD68(-) NK cells around intrahepatic small bile ducts

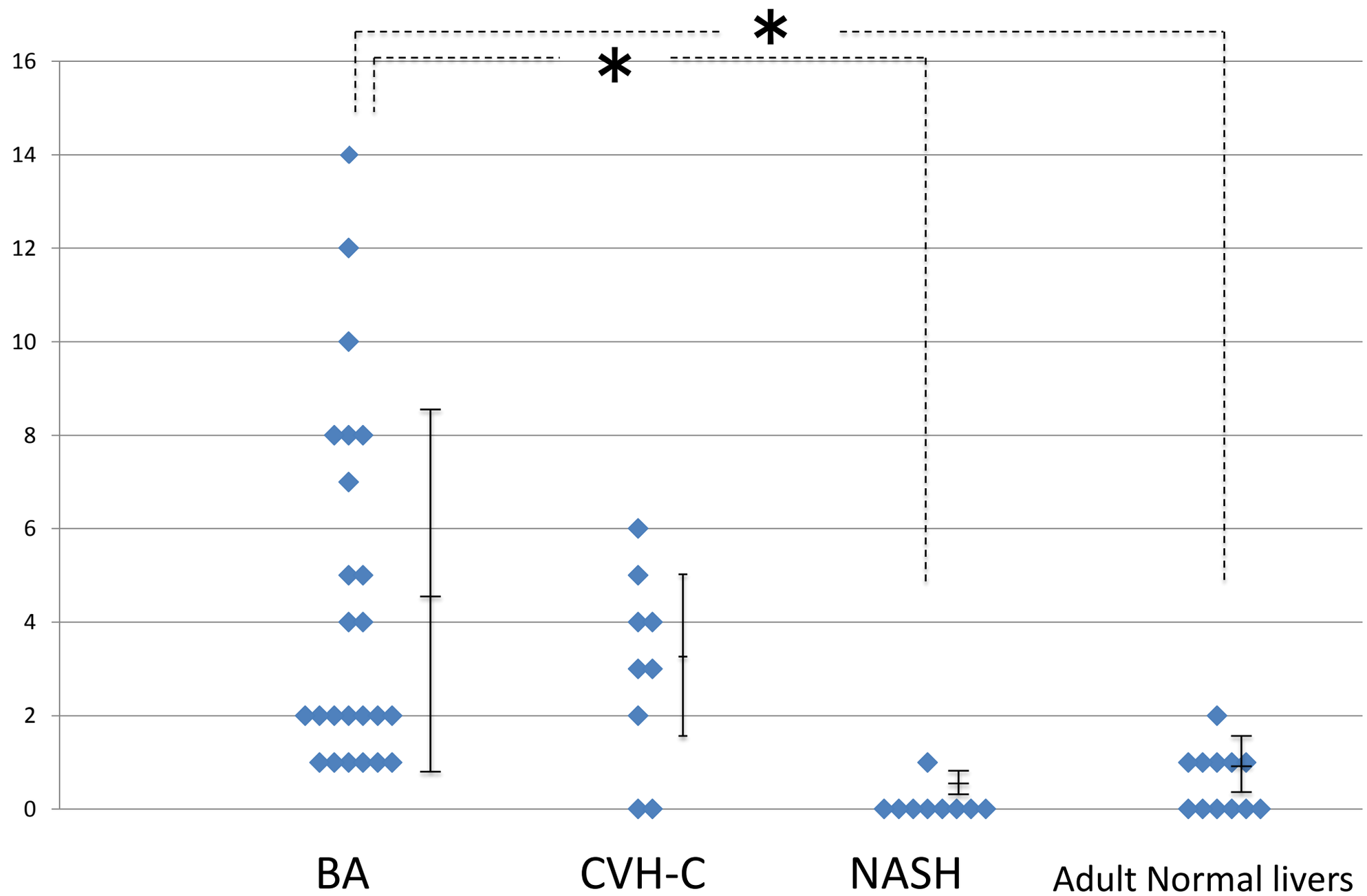

Fig. 2

CD56(DAB)CD68(Green)

CD56(DAB)CD16(Green)

Normal

BA

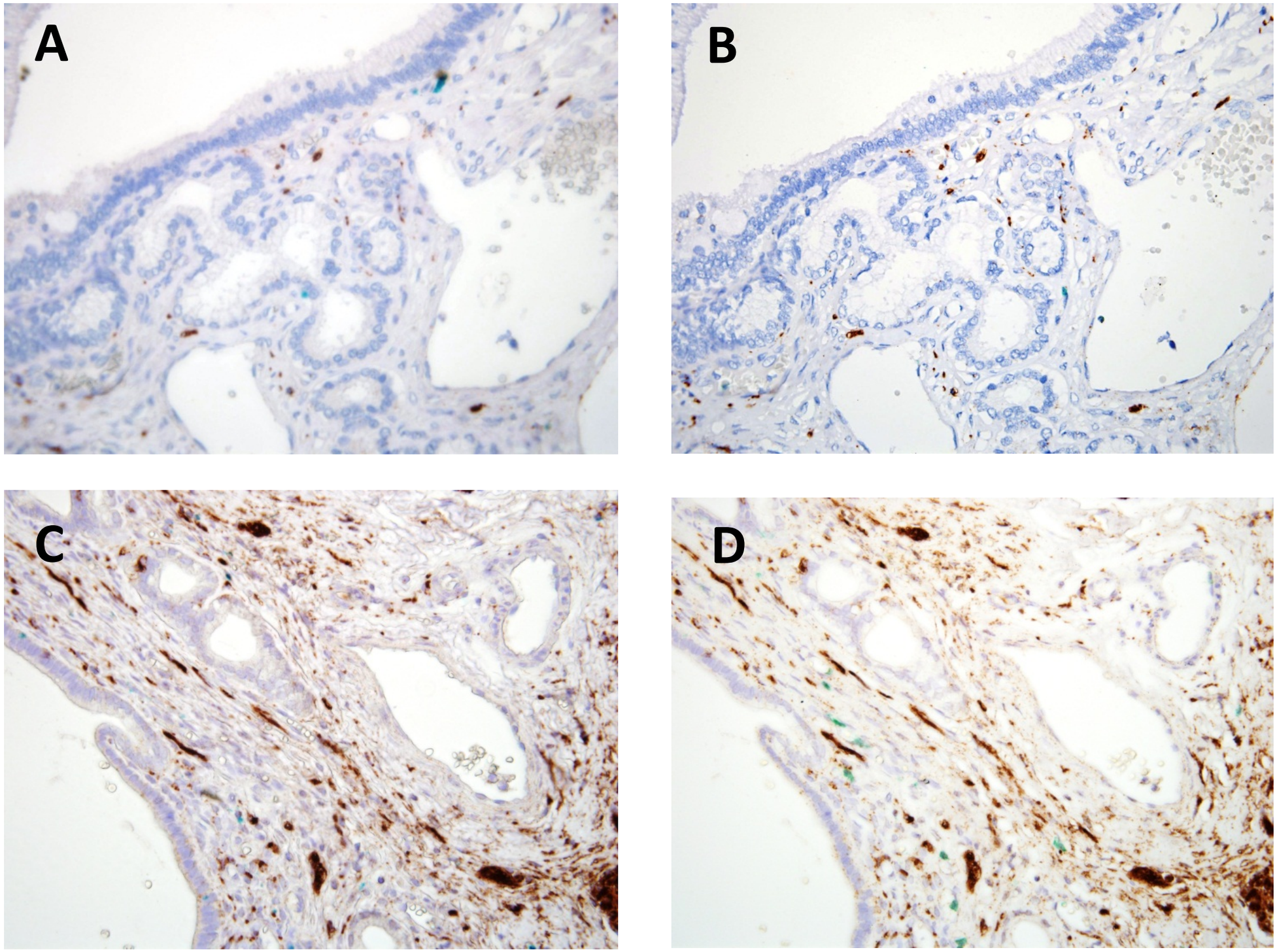

Fig.2E Density of CD56(-)CD16(+)CD68(-) NK cells around large bile ducts

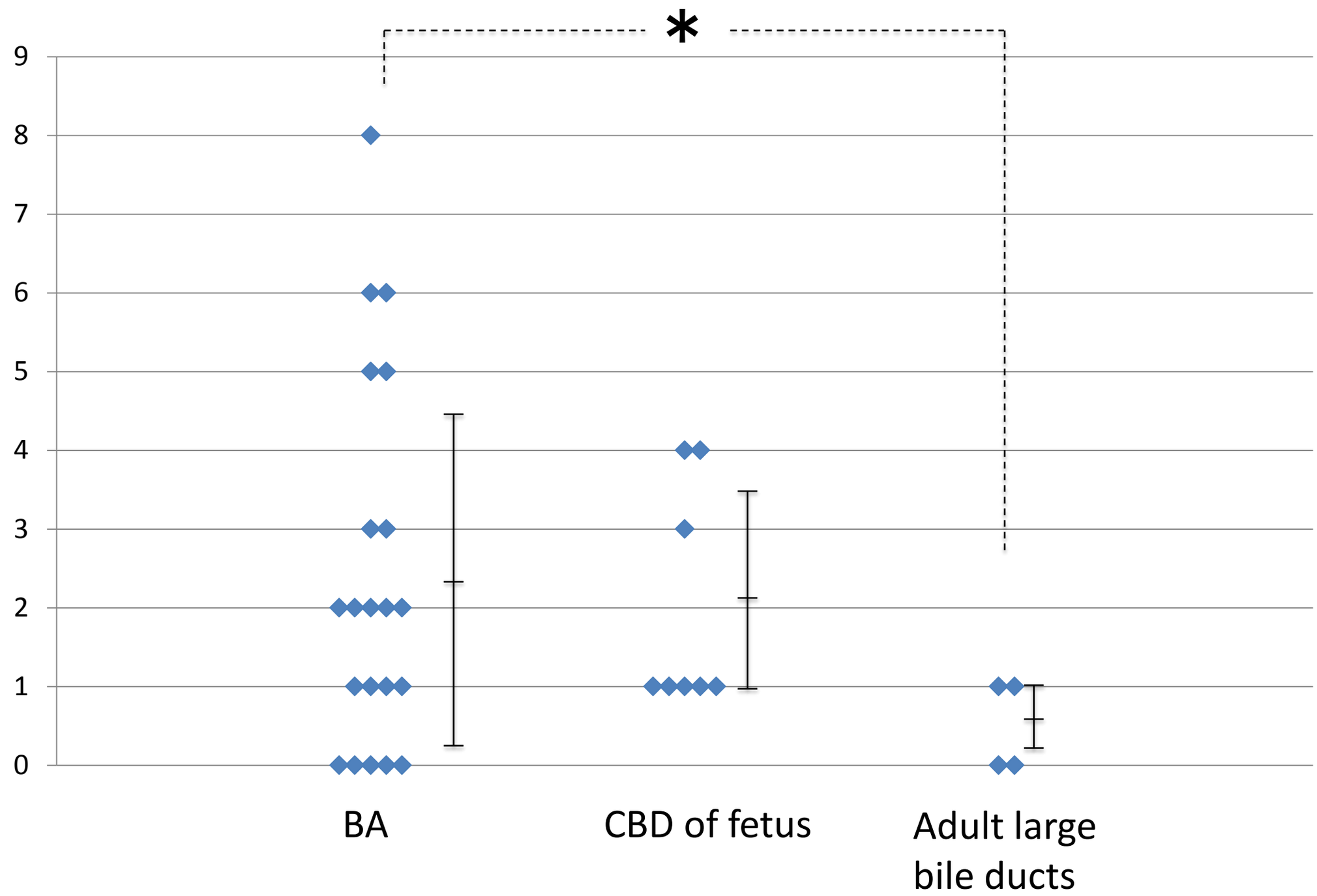

Fig.3

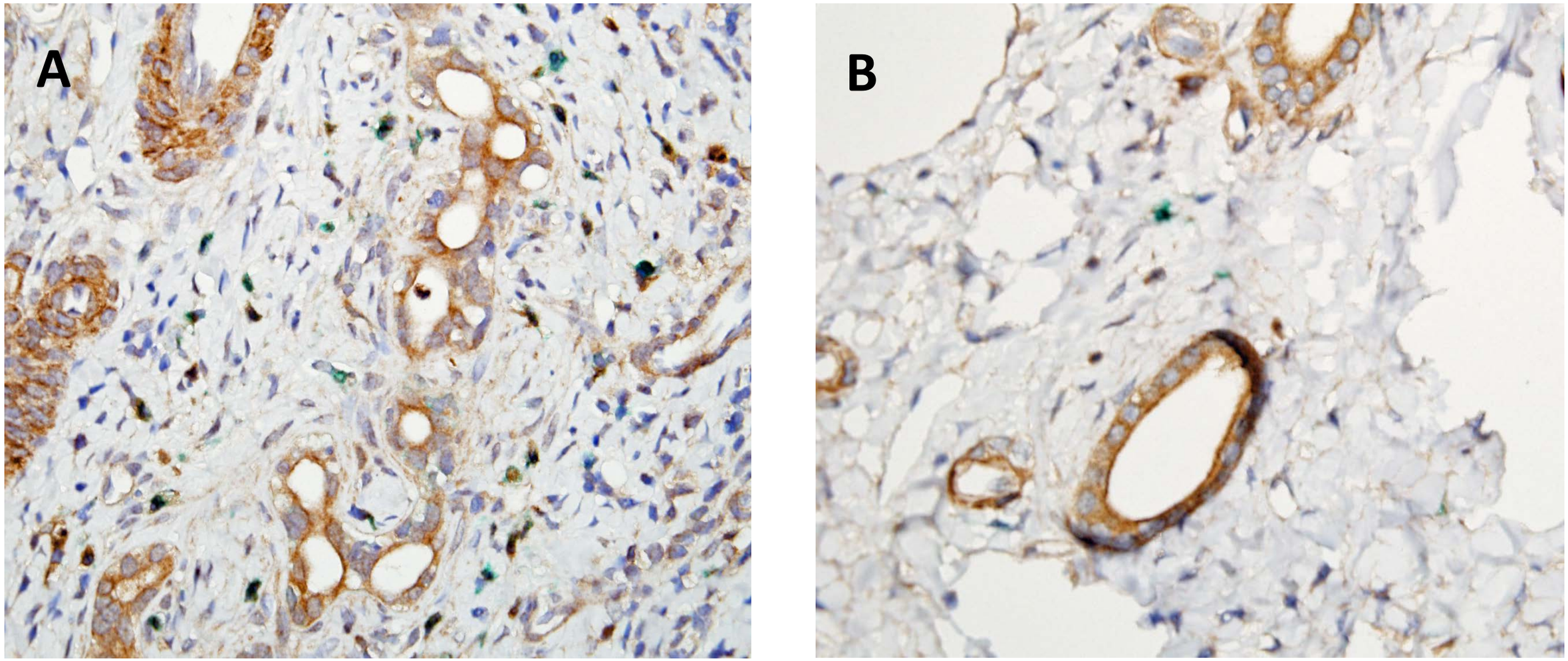

CX3CR1(DAB)CD16(Green)

Fig.3C CX3CR1(+)CD16(+) monomuclear cells around intrahepatic bile ducts

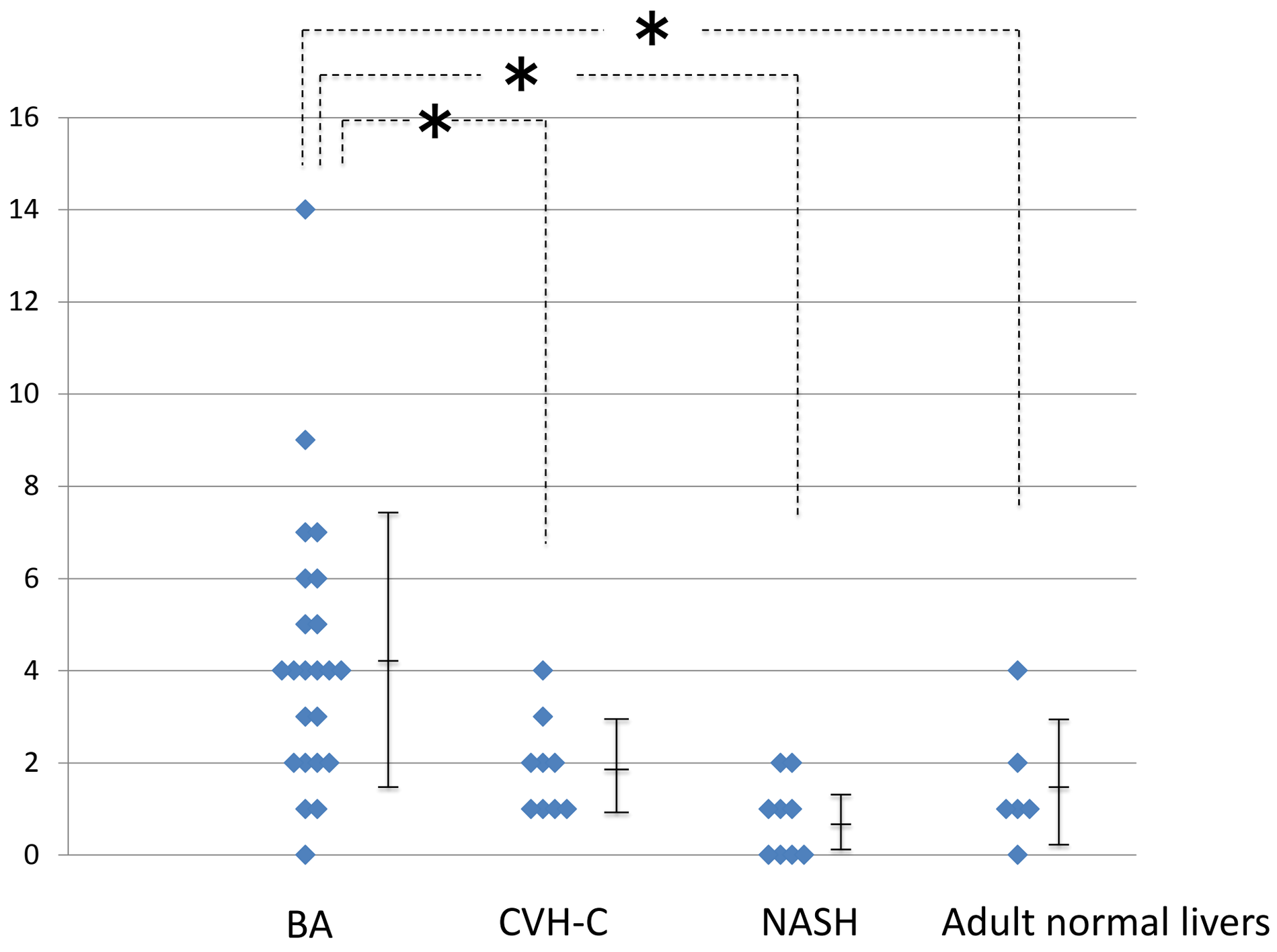

Fig. 3D CX3CR1(+)CD16(+) mononuclear cells around large bile ducts

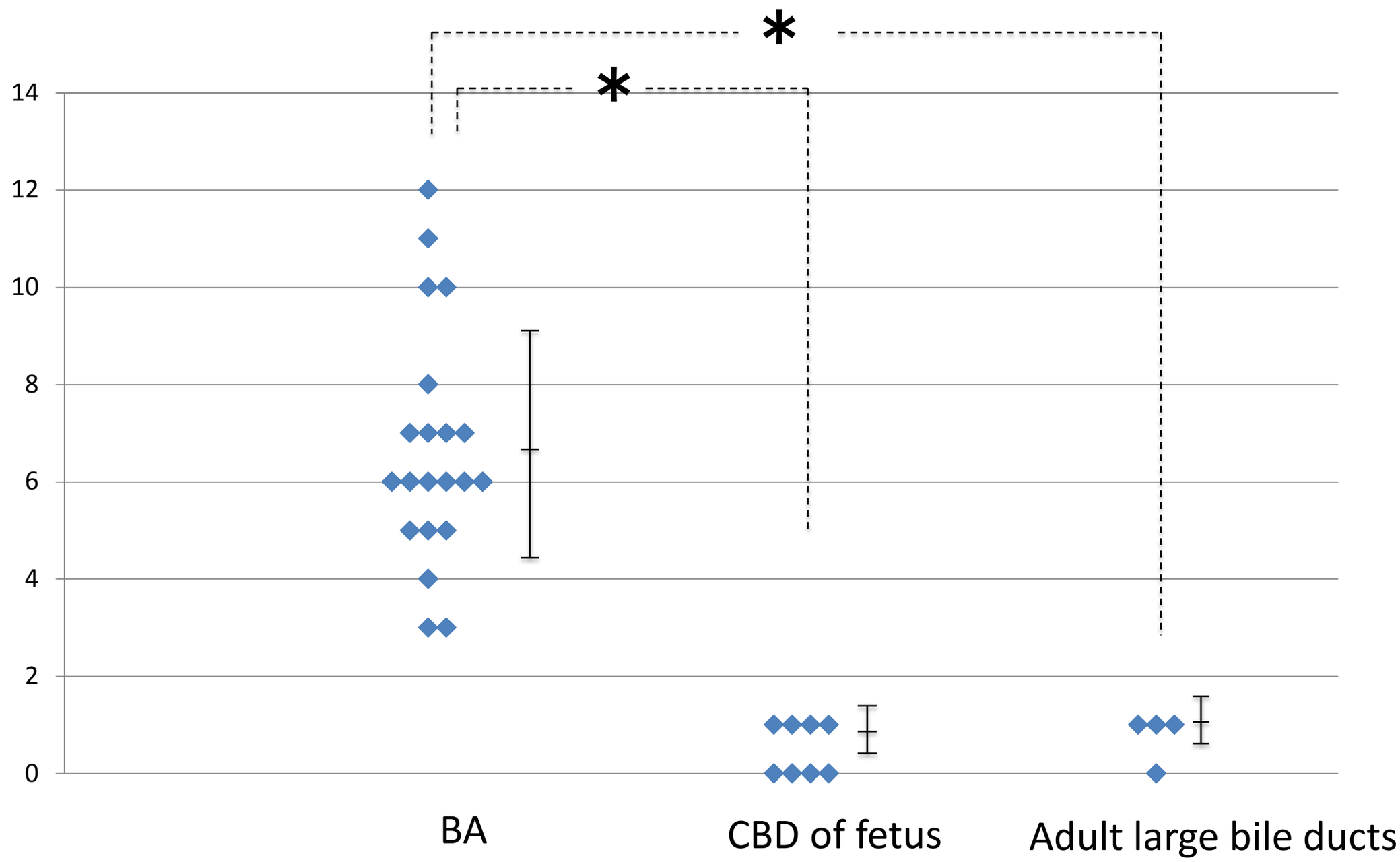

Fig.4

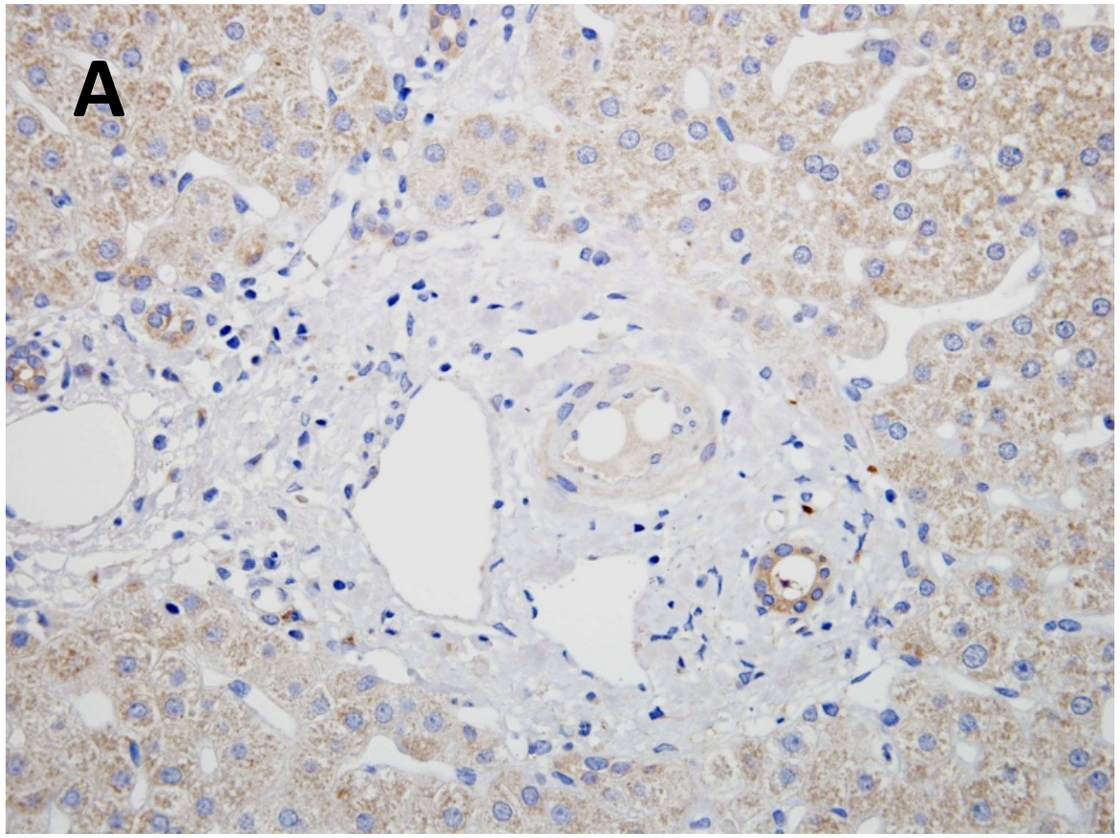

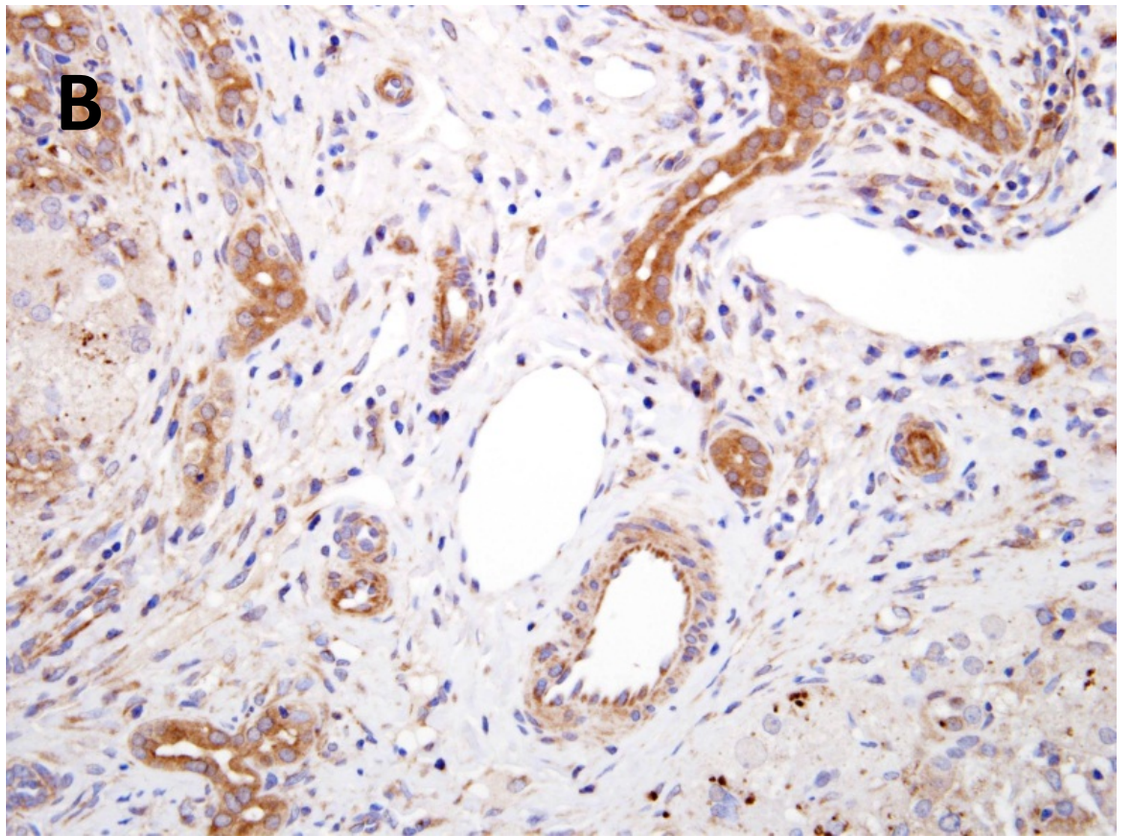

Fig. 4C Expression of CX3CL1 in intrahepatic small bile duct epithelia

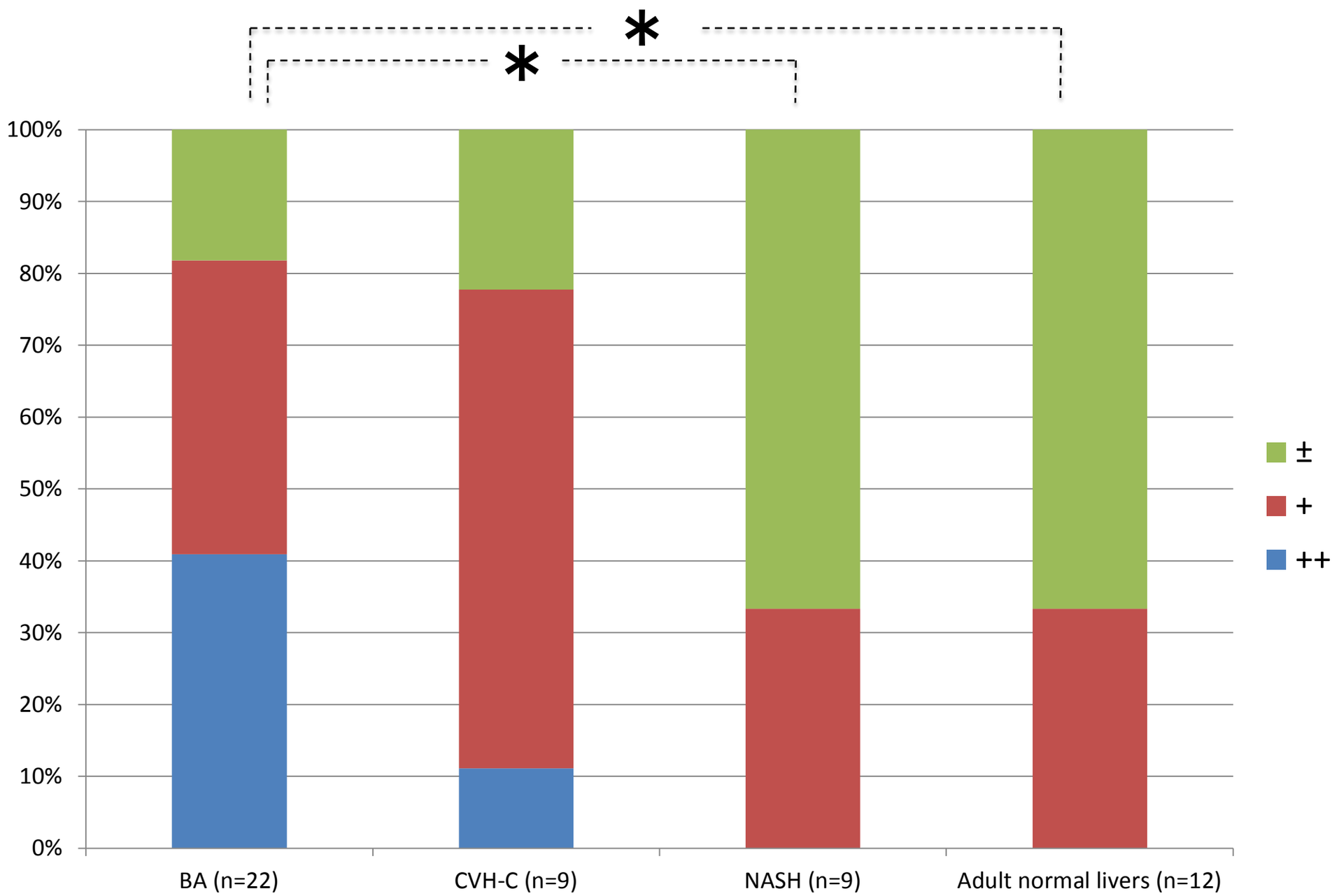

±, absent/faint; +, slightly positive; ++, strongly positive

Fig.5

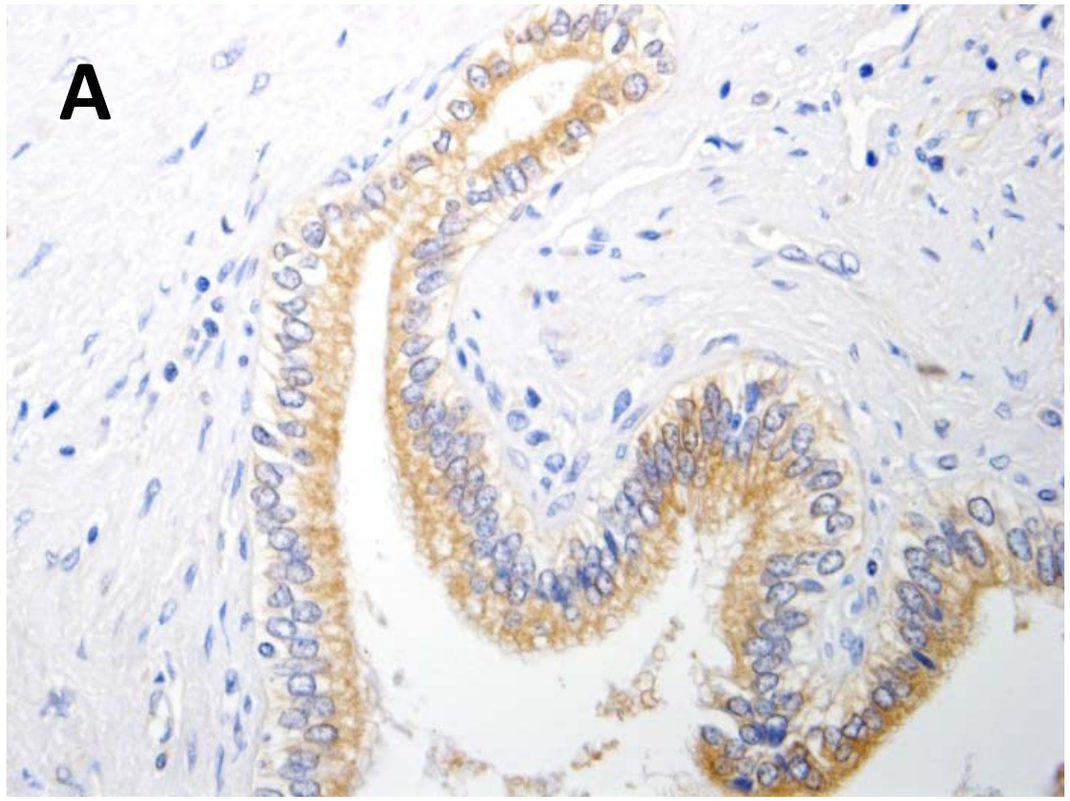

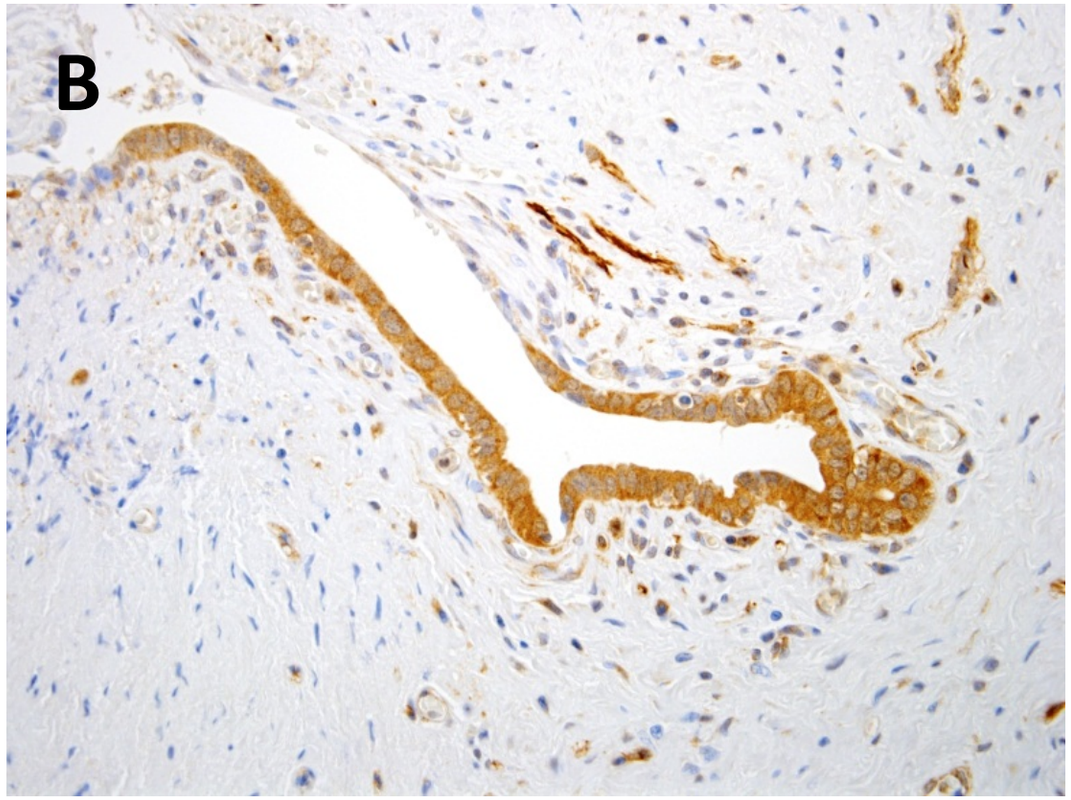

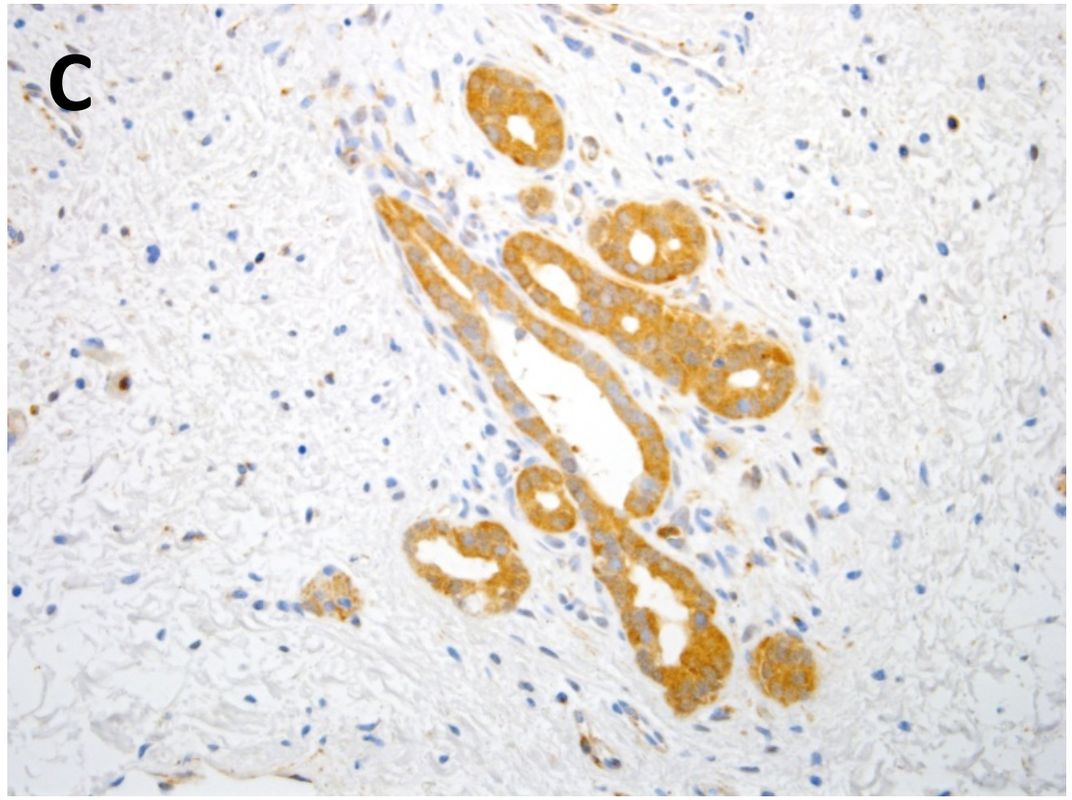

Fig. 5D Expression of CX3CL1 in large bile duct epithelia

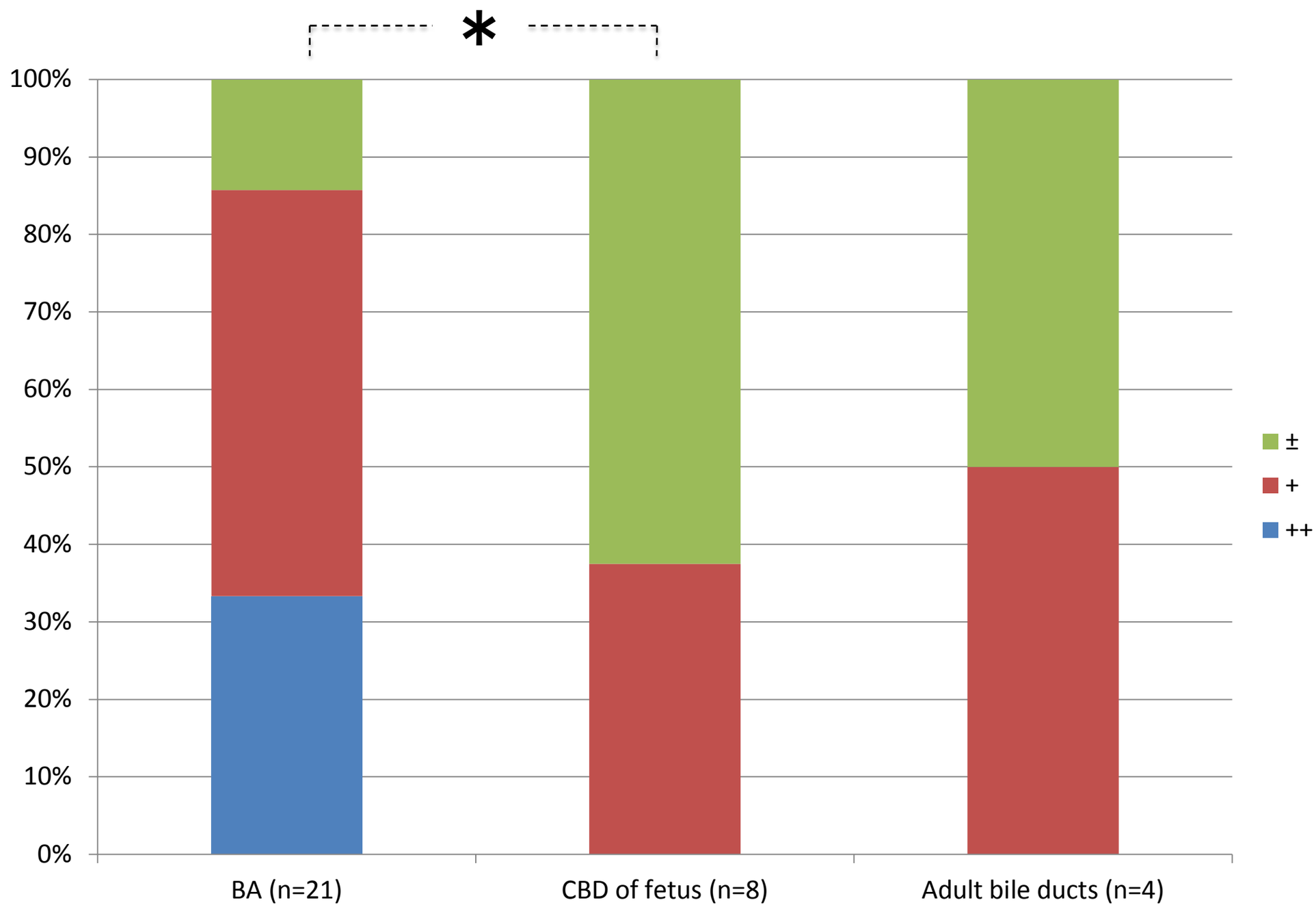

±, absent/faint; +, slightly positive; ++, strongly positive

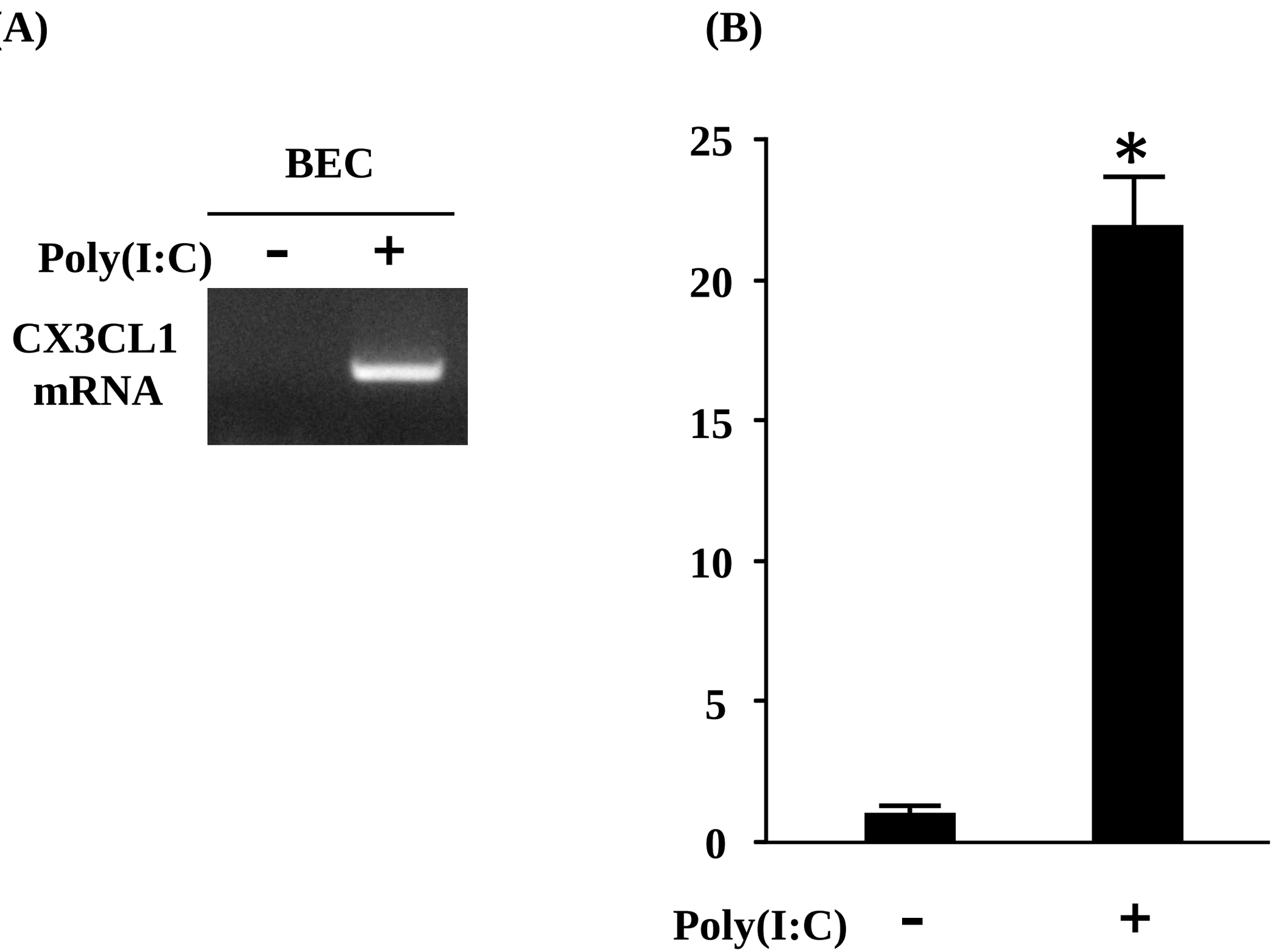

Fig.6

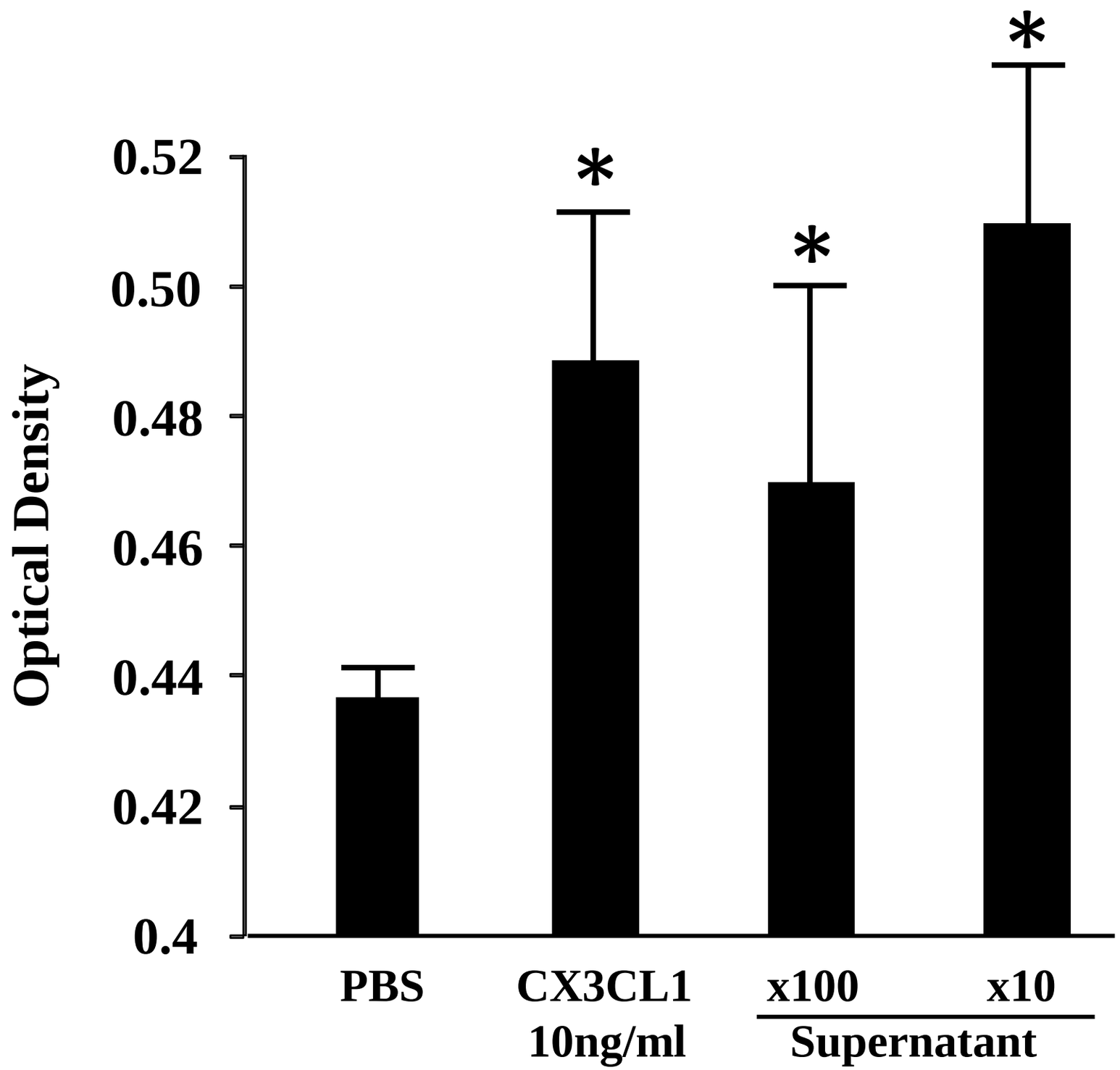
Optical Density
0.52
0.50
0.48
0.46
0.44
0.42
0.4
*
*
*
PBS
CX3CL1
10ng/ml
x100
x10
Supernatant

Fig.7