

Aneurysm clipping after partial endovascular embolization for ruptured cerebral aneurysms

メタデータ	言語: eng 出版者: 公開日: 2017-10-03 キーワード (Ja): キーワード (En): 作成者: メールアドレス: 所属:
URL	http://hdl.handle.net/2297/40418

Aneurysm Clipping after Partial Endovascular Embolization for Ruptured Cerebral Aneurysms

M. NOMURA, S. KIDA, N. UCHIYAMA, T. YAMASHIMA, J. YAMASHITA, J. YOSHIKAWA*, O. MATSUI*

Departments of Neurosurgery and *Radiology, Kanazawa University School of Medicine; Kanazawa

Key words: ruptured cerebral aneurysm, partial embolization, clipping, electrolytically detachable coil

Summary

The aim of this study was to investigate the advantages and disadvantages of a two-stage treatment for ruptured cerebral aneurysms; partial embolization in acute stage followed by clipping in chronic stage of subarachnoid hemorrhage.

Between April 1997 and August 1999, twenty ruptured cerebral aneurysms were initially treated endovascularly using Guglielmi detachable coils in our institution. Among them, complete embolization could not be achieved in 6 lesions. For these lesions, subsequent clipping was added. The radiological and operative findings, and outcomes of these cases were retrospectively reviewed.

In 1 case, rerupture occurred during the endovascular procedure. Rerupture was not observed in any cases in the postembolization period. In 2 cases, complications related to the clipping but not the endovascular procedure occurred. These complications included impaired visual acuity for unverified reasons, and memory disturbance due to sacrifice of a perforator arising from the anterior communicating artery. In 3 cases, coil extraction was needed during the clipping, because the loops of the coil extended into the residual neck. Complications related to coil extraction were not observed in these 3 cases.

Acute partial embolization of ruptured aneurysm appears to be effective for the prevention of subsequent rerupture during the subacute period, in which treatment for vasospasm should be performed, and the clipping procedure. However, in the case of relatively large aneurysms, small arteries or other normal structures behind the aneurysm cannot be observed directly during surgery, because of the immobility of the embolized aneurysm. Further, complete clip closure is impossible when loops of coil herniate into the neck. In such situations, coil extraction with or without resection of the aneurysm might be necessary, and care must be taken not to damage parent artery and surrounding vessels.

Introduction

The goal of treatment for cerebral aneurysm is complete obliteration and exclusion of the lesion from the arterial circulation. Recently, endovascular embolization using electrolytically detachable coils has become an effective treatment for intracranial aneurysms. However, it is sometimes difficult to totally embolize the ruptured aneurysms¹.

For these cases, partial embolization for the

Table 1 Clinical findings in six patients

Case	Age / Sex	SAH Grade (H&K)	Location	Aneurysm Size (mm)	Dome/Neck (mm)	Dome/Neck Ratio	Ictus from Onset to Embolization	Complication Related to Embolization	Symptomatic Vasospasm	Spinal Drainage	Hydrocephalus	Ictus from Embolization to Clipping	Operative Findings	Complication Related to Clippings	Outcome (GOS)
1	44 / F	IV	IC-Ant Chor (lt)	5	4/3	1.33	3.5h	rerupture	—	+	+	44d	aneurysm resection with coils	—	GR
2	36 / M	II	IC-bifurcation (lt)	5	2.2/2	1.1	29h	—	—	+	—	42d	—	visual disturbance (unknown etiology)	MD
3	75 / M	II	IC-PC (rt)	11	8/7	1.14	3d	—	—	+	+	54d	coil extraction	—	GR
4	34 / F	III	IC-PC (rt)	6	5/3.5	1.43	7.5h	—	transient	+	—	43d	—	—	GR
5	52 / M	II	AComA	9	6/6	1.0	7d	—	—	+	—	12d	—	—	GR
6	56 / M	I	AComA	10	6/5	1.2	15h	—	—	+	—	16d	perforator occlusion aneurysm resection with coils	Infarction (due to perforator occlusion)	MD

AComA = anterior communicating artery; Ant Chor = anterior choroidal artery; GOS = Glasgow Outcome Scale (GR = good recovery, MD = moderately disabled, D = dead); H&K = Hunt and Kosnik; IC = internal carotid artery; lt = left; PC = posterior communicating artery; rt = right

ruptured site with Guglielmi detachable coils (GDCs) is performed in the acute stage, and clipping is added in the chronic stage of subarachnoid hemorrhage (SAH) in our institution. To our knowledge, there have been only four articles describing in detail clipping after endovascular embolization with GDCs²⁻⁵. In this report, we present our experiences of 6 cases in which partial endovascular embolization followed by clipping was performed, and discuss the effectiveness and difficulties of this two-staged treatment.

Patients and Methods

Between April 1997 and August 1999, fifty patients with ruptured cerebral aneurysms were treated in our institution. Twenty patients were initially treated by endovascular embolization with GDCs. Among them, six patients were treated by partial embolization in the acute stage of SAH, and subsequent clipping was performed in the chronic stage. A summary of these six patients is presented in table 1. The six patients included three men and three women ranging in age from 34 to 75 years. All these patients presented with SAH and were classified according to the grading of Hunt and Kosnik. The aneurysm sizes ranged from 5 to 11 mm (mean, 7.7 mm), and the dome/neck ratio ranged from 1.0 to 1.43 (mean, 1.2). For these lesions, endovascular embolization with GDCs was initially performed within 72 h from onset except 1 case (case 5). Endovascular procedures were performed under local anesthesia. A microcatheter was advanced into the aneurysm cavity via the femoral artery. After embolization, a spinal drain was inserted to drain bloody cerebrospinal fluid for all patients.

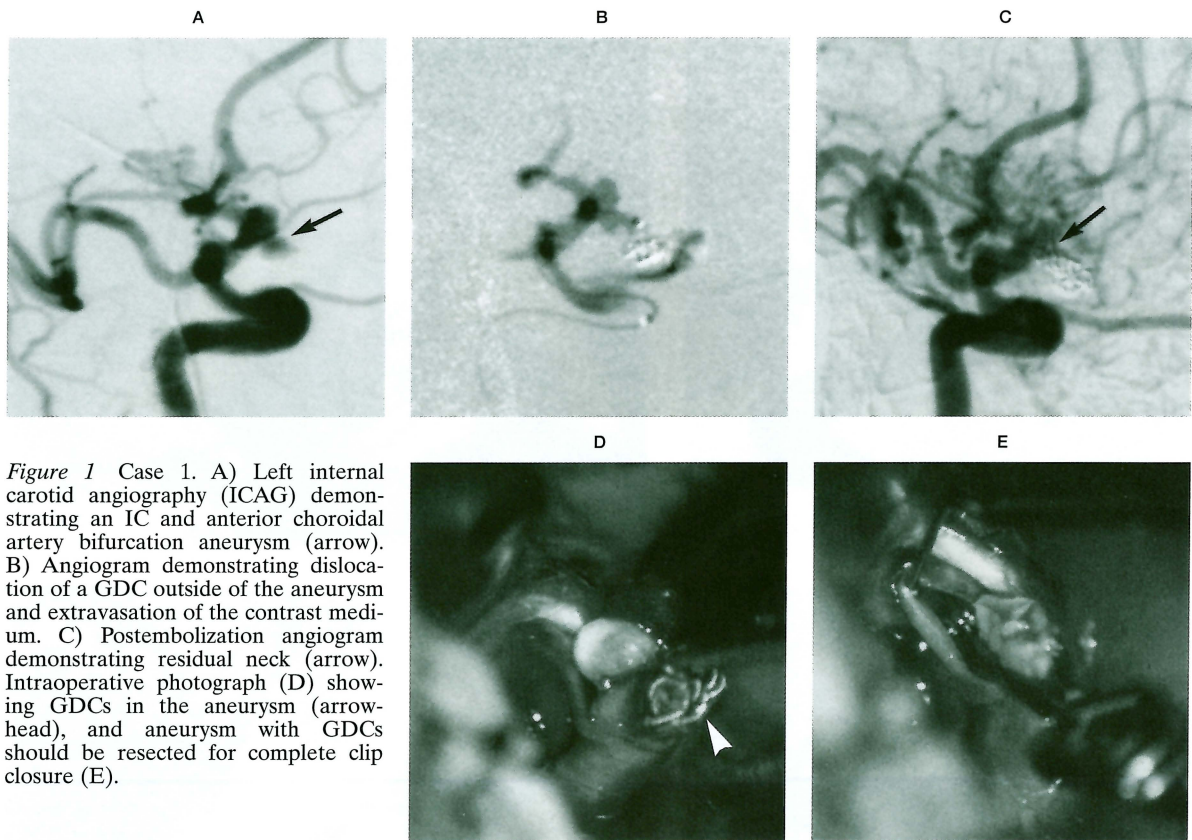


Figure 1 Case 1. A) Left internal carotid angiography (ICAG) demonstrating an IC and anterior choroidal artery bifurcation aneurysm (arrow). B) Angiogram demonstrating dislocation of a GDC outside of the aneurysm and extravasation of the contrast medium. C) Postembolization angiogram demonstrating residual neck (arrow). Intraoperative photograph (D) showing GDCs in the aneurysm (arrowhead), and aneurysm with GDCs should be resected for complete clip closure (E).

Treatments for preventing vasospasm, triple-H (hypertensive, hypervolemic, and hemodilutional) therapy, and intravenous administration of nicardipine hydrochloride and fasudil hydrochloride, were continued for about 3 weeks after the onset. In the chronic stage of SAH, clipping was added for the neck remnants of aneurysms. Ictus from endovascular treatment to clipping varied from 12 to 54 days (mean, 35 d). The radiological and operative findings, and operative outcomes of these six patients were retrospectively reviewed.

Results

The overall results, with the clinical and radiological features, are summarized in table 1.

The reasons why these 6 lesions were not embolized completely were: 1) failure of microcatheter placement due to small neck remnant (case 4); 2) impossibility of adding GDC due to small neck remnant (cases 1, 2 and 6); and 3) impossibility of GDC detachment due to migration of a coil into the parent artery (case 3) or arterial branch (case 5). Complications relat-

ed to the endovascular procedure were observed in 1 case (case 1).

In this case, perforation of the aneurysm by GDC and extravasation of the contrast medium were observed.

After partial embolization, rerupture of the aneurysm did not occur in any cases. Symptomatic vasospasm was observed in one case (case 4). This patient transiently presented memory disturbance. Normal pressure hydrocephalus developed in 2 cases, and ventriculoperitoneal shunts were needed.

During the clipping procedure, loops of coil were found to extend into the residual neck, and coil extraction with or without aneurysm resection was needed in 3 cases (cases 1, 3 and 6). Complications related to the coil extraction did not occur. Complications related to the clipping were observed in 2 cases (cases 2 and 6). In case 2, ipsilateral visual disturbance occurred after clipping, although the etiology was not verified. In case 6, the aneurysm dome which had been packed with the coils was larger than the residual neck. Therefore, the aneurysm was not moved easily, and dissection of

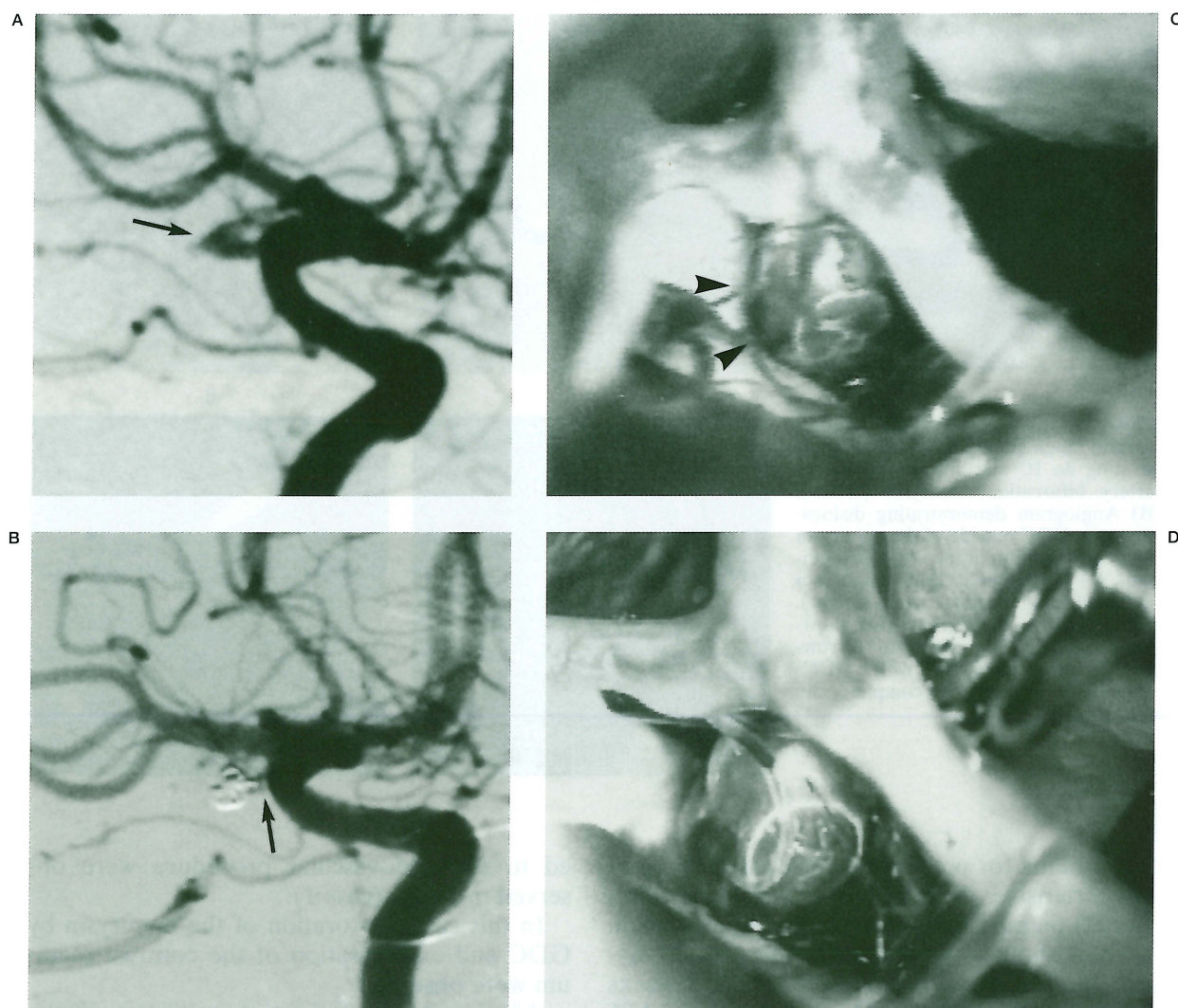


Figure 2 Case 2. A) Right ICAG demonstrating an aneurysm at the IC terminal portion (arrow). B) Postembolization angiogram revealing residual neck (arrow). C) Intraoperative photograph showing the partially embolized aneurysm (arrowheads). D) The aneurysm can be clipped without coil extraction or aneurysm resection.

the aneurysm from the surrounding structure and observation of the deeper side of the aneurysm were very difficult. Finally, a small perforator arising from the anterior communicating artery (AComA) was included within the clip and obliterated.

Case Reports

Case 1

A 44-year-old woman was admitted to our hospital with coma. She presented anisocoria and decerebrated posture on admission. CT revealed SAH and angiography demonstrated an

aneurysm at the left internal carotid artery (IC) and anterior choroidal artery bifurcation (figure 1A). Angiography also revealed occlusion of the left middle cerebral artery at the M1 segment. Due to the severe SAH grade and M1 occlusion, we selected endovascular treatment. During the coil delivery, the aneurysm reruptured and a GDC migrated outside the aneurysm. Extravasation of the contrast medium was observed (figure 1B). At this time, her systolic blood pressure elevated to 194 mmHg. The coil was detached outside of the aneurysm, and an additional two GDCs were placed in the aneurysm. After the endovascular emboliza-

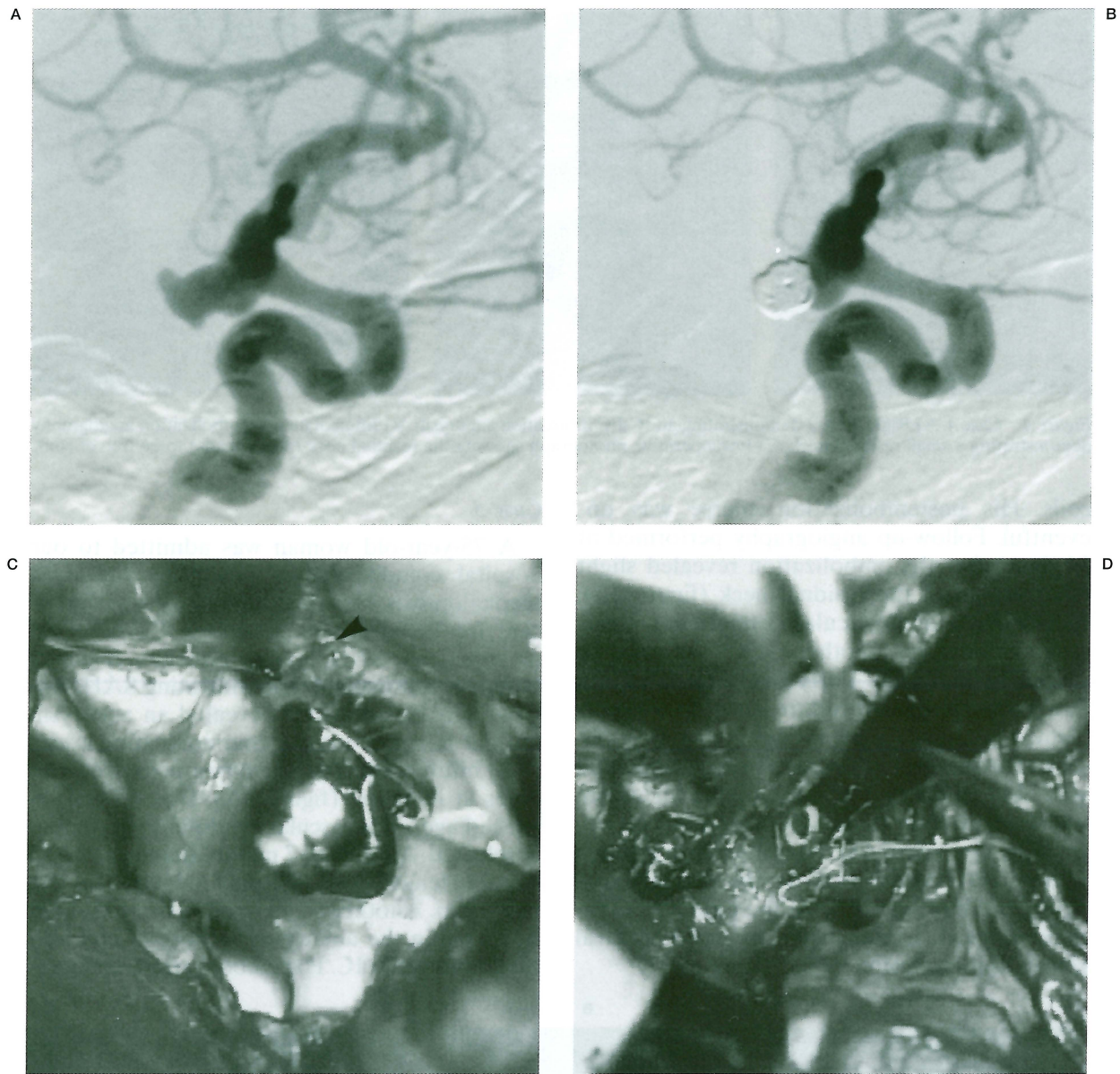


Figure 3 Case 3. A) Right ICAG demonstrating an IC-PC bifurcation aneurysm with blebs. B) Immediate postembolization angiography demonstrating obliteration of the blebs, however the residual neck can still be seen. C) Intraoperative photograph after clip application showing coils within the aneurysm (arrowhead). D) Intraoperative photograph showing coil extraction.

tion, she regained consciousness and gradually recovered. Follow-up angiography performed 27 days after the embolization showed the residual aneurysm neck (figure 1C). Forty-four days after the embolization, the residual neck was clipped. A loop of the GDC extended into the residual neck, and coil extraction with aneurysm resection was needed for complete clipping (figures 1D, E).

Case 2

A 36-year-old man was admitted to our hospital complaining of headache and vomiting. CT revealed SAH and angiography demonstrated a long-shaped aneurysm at the right IC terminal (figure 2A). The aneurysm was embolized with 2 GDCs. Additional GDC could not be placed and the neck remained free of

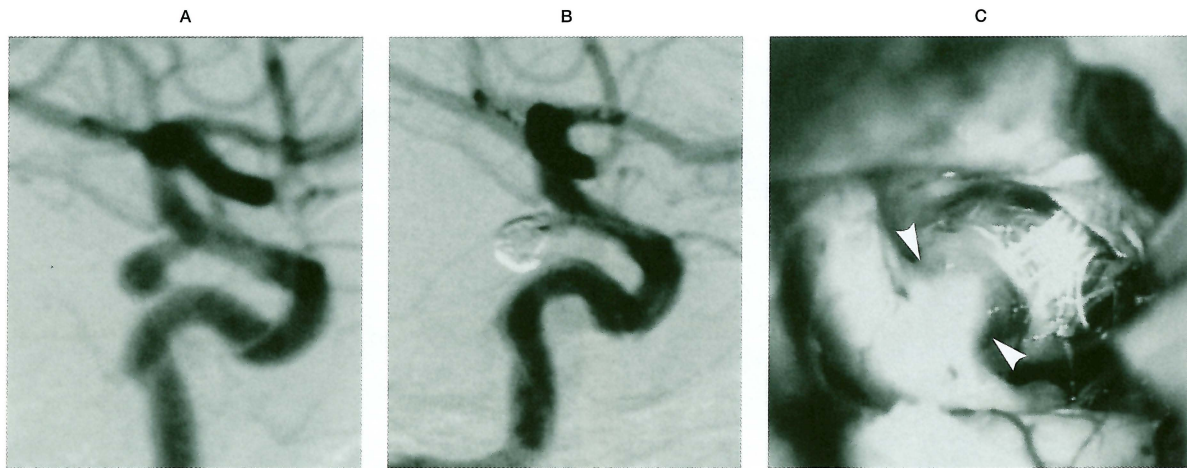


Figure 4 Case 4. A) Right ICAG demonstrating an IC-PC bifurcation aneurysm. B) Immediate postembolization angiography demonstrating a small residual neck. C) Intraoperative photograph showing the residual neck (arrowheads) to be free of coils.

coils. His postembolization course was uneventful. Follow-up angiography performed at 34 days after the embolization revealed slight enlargement of the residual neck (figure 2B). Additional endovascular treatment was planned, however, another GDC could not be placed in the neck. Forty-five days after the first endovascular procedure, clipping was performed. A small perforating artery was observed arising from the unembolized dome and was obliterated by the clip. As the aneurysm was free of coils (figure 2C), neither coil extraction nor aneurysm resection were needed (figure 2D). Postoperatively the patient complained of blurred vision of the right eye. Ophthalmological examination revealed central retinal vein occlusion.

Case 3

A 75-year-old woman was admitted to our hospital complaining of headache and right blepharoptosis. Her medical history was significant for hypertension. Although CT revealed no significant SAH, lumbar puncture revealed bloody cerebrospinal fluid indicating SAH. Angiography on admission revealed an aneurysm at right IC and posterior communicating artery (PC) bifurcation. The aneurysm possessed two blebs at its dome (figure 3A). Due to her advanced age, endovascular treatment was initially selected. A GDC of 7 mm in diameter and 20 cm in length was initially placed in the aneurysm. Another small sized-GDC could not be added in the aneurysm because of coil herniation into the IC. Postembolization angiogra-

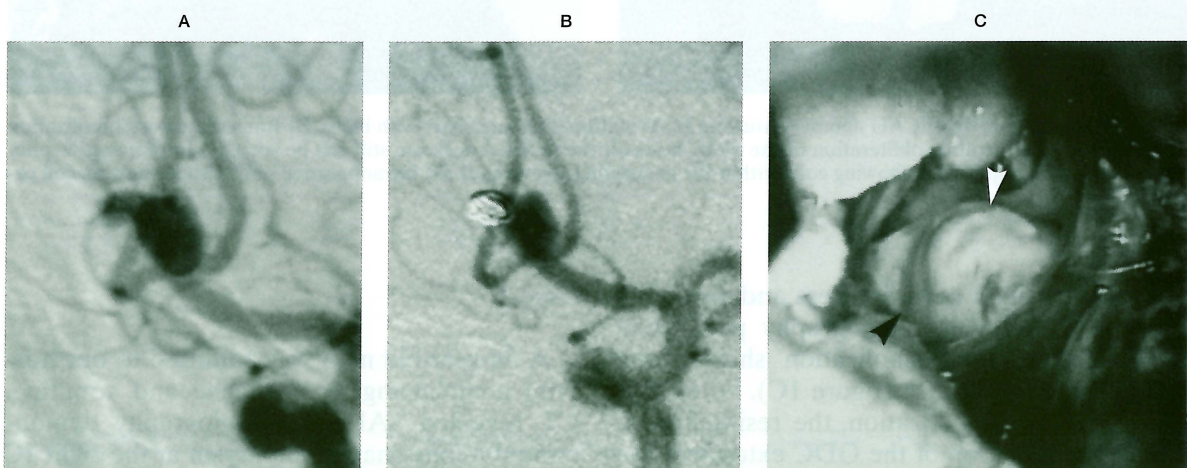


Figure 5 Case 5. A) Preembolization angiography demonstrating an AComA aneurysm with a bleb. B) Immediate postembolization angiography demonstrating that the bleb is obliterated with a GDC. C) Intraoperative photograph showing that the aneurysm neck is free of coils (arrowheads).

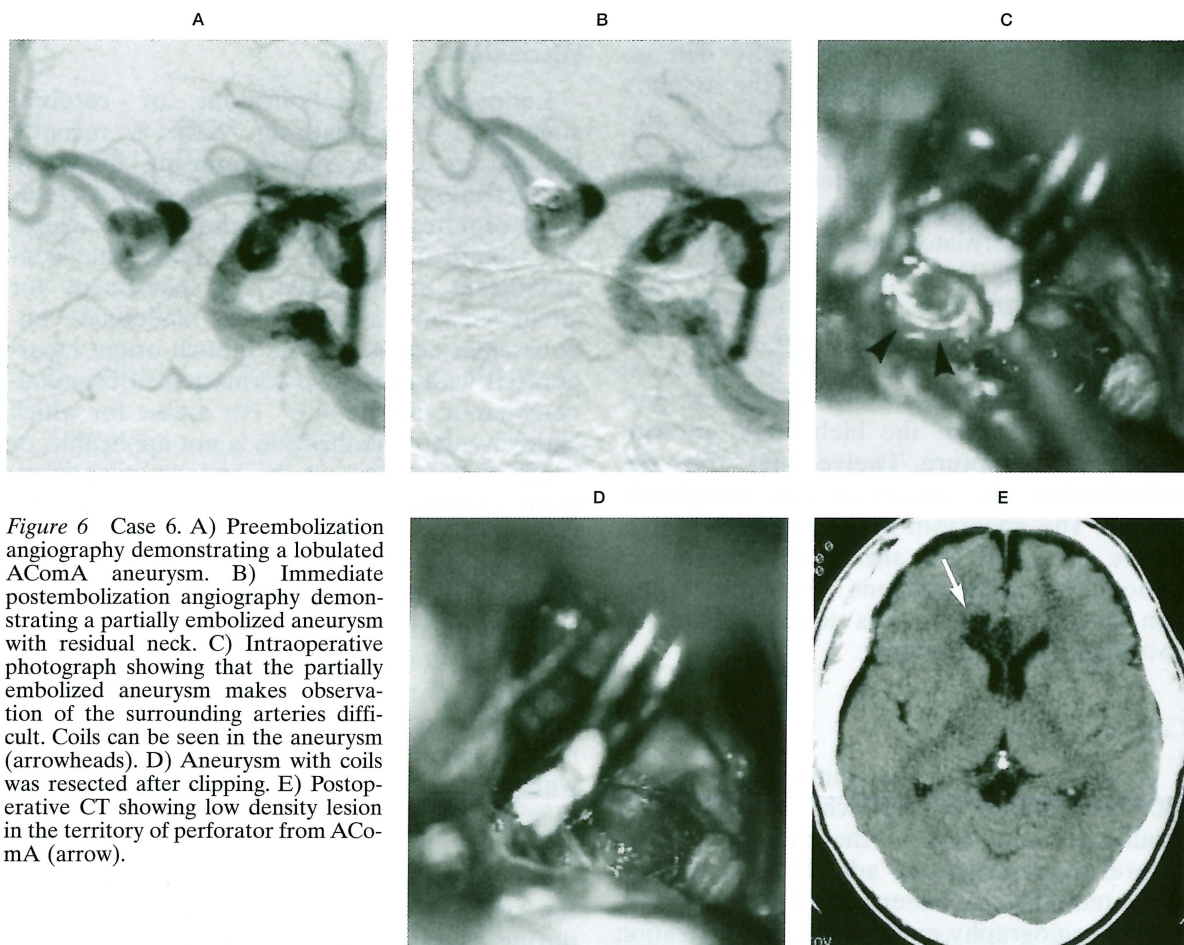


Figure 6 Case 6. A) Preembolization angiography demonstrating a lobulated AComA aneurysm. B) Immediate postembolization angiography demonstrating a partially embolized aneurysm with residual neck. C) Intraoperative photograph showing that the partially embolized aneurysm makes observation of the surrounding arteries difficult. Coils can be seen in the aneurysm (arrowheads). D) Aneurysm with coils was resected after clipping. E) Postoperative CT showing low density lesion in the territory of perforator from AComA (arrow).

phy revealed obliteration of the blebs, however the residual neck was observed (figure 3B). Forty-two days after the endovascular treatment, clipping was added. A coil was observed transparently within the aneurysm (figure 3C). As a loop of the coil herniated into the aneurysm neck, complete occlusion of the aneurysm by the clip was impossible. Microvascular Doppler ultrasound revealed blood flow in the aneurysm. The coil was then extracted from the aneurysm and complete clipping could be achieved (figure 3D). Postoperative angiography revealed no opacification of the aneurysm. Postoperatively, the right blepharoptosis gradually improved and the patient was discharged without any neurological deficits.

Case 4

A 34-year-old woman without any medical history was admitted to our hospital complaining of headache. CT revealed SAH and ventric-

ular dilatation. Angiography revealed a right IC-PC bifurcation aneurysm (figure 4A). Following angiography, the aneurysm was embolized with 3 GDCs, leaving a small residual neck (figure 4B). Eight days after the embolization, the patient presented disorientation and mild vasospasm was observed at the C1 to C2 portion of the right IC on angiography. Intravenous administration of low molecular dextrane and albumin, and induced hypertension improved her consciousness. Forty-three days after the embolization, clipping was performed. The residual neck was free of coils (figure 4C), and complete clipping could be achieved without any complications. Postoperative angiography showed complete obliteration of the aneurysm.

Case 5

A 52-year-old man suffered sudden onset of headache 7 days before admission. CT on admission showed SAH and a small hematoma in

the right frontal lobe. Angiography demonstrated an aneurysm with a bleb at the AComA (figure 5A). Following the angiography, embolization was performed. Initially, placing of a GDC of 6 or 7 mm in diameter was attempted in the proximal portion of the aneurysm. However, the coil herniated into the IC and could not be detached. Then a small sized-GDC of 4 mm in diameter and 10 cm in length was placed only in the bleb (figure 5B). The aneurysm was considered likely to rupture at the site of the bleb, therefore we thought partial embolization of the bleb could prevent subsequent rerupture. Twelve days after the embolization, the aneurysm was completely clipped. The aneurysm neck was free of coils (figure 5C), and the aneurysm was clipped without any complications. Complete occlusion of the aneurysm was confirmed on the postoperative angiography.

Case 6

A 56-year-old man was admitted to our hospital complaining of headache. CT showed a small amount of SAH in the interhemispheric fissure. Angiography on admission revealed a lobulated AComA aneurysm (figure 6A). Following angiography, endovascular embolization was performed. Initially, the packing of aneurysm was attempted with a GDC of 5 or 6 mm in diameter. However, the coil herniated to the parent artery and could not be detached. Two small sized-GDCs of 3 and 2 mm in diameter were then placed (figure 6B). His postembolization course was uneventful. Sixteen days after the embolization, clipping was performed. During the operation, the embolized immobile aneurysm made it difficult to visualize the normal structure around the aneurysm (figure 6C). The clip was applied with failure of finding a perforating artery from AComA. Although the aneurysm with coils was resected after clipping, a perforating artery from AComA was included in the clip (figure 6D). Postoperatively, the patient presented memory disturbance. Although postoperative angiography revealed complete obliteration of the aneurysm, CT showed an infarction in the corpus callosum and right cingulate gyrus due to occlusion of the perforator arising from AcomA by the clip (figure 6E). He was discharged with memory disturbance.

Discussion

Endovascular embolization of cerebral aneurysms with platinum coils is recently thought to be the most promising approach. The selection of endovascular or surgical treatment requires an understanding of the anatomy around the lesion. The features that contraindicate endovascular coil placement for aneurysms are a wide neck, inadequate endovascular access, arterial branch origin incorporated with neck, and formation of pseudoaneurysm at rupture site¹. For a case for which endovascular embolization is not applicable, or which shows failure of the endovascular treatment, clipping is selected. In some cases, total embolization of the aneurysm cannot be achieved due to angioanatomical features, and results in a neck remnant. For these cases, clipping or additional endovascular treatment should be considered, because the neck remnant may present a possibility of rupture⁶. In our institution, partial embolization is planned in the acute stage of SAH for the cases in which total endovascular embolization is not possible. Then, in the chronic stage, clipping is added for these cases.

As advantages of this two-staged treatment, the risk of subsequent rerupture before and during clipping could be decreased by partial embolization. As the majority of aneurysms might rupture at their dome or fundus, the rupture point is usually protected even by a partial embolization². Therefore, treatment for vasospasm can be performed without risk of rerupture after partial embolization. In addition, as the ruptured site has been already embolized in the acute stage, aneurysm rerupture by mechanical manipulation during the clipping procedure can be also prevented. The aneurysm can be dissected from the surrounding structures more safely than in cases of untreated ruptured aneurysms. In our 6 cases, no patient suffered rerupture during the postembolization period, including during the operative procedure. The ictus from embolization to clipping was 35 days on average in our cases. In this period, the patients recovered from the acute SAH event, and the aneurysm could be clipped with a patient in a better condition. Another advantage for selecting endovascular treatment as an initial treatment is reduction of the incidence of vasospasm. Yalamanchili et al⁷ reported that the frequency and severity of

cerebral vasospasm may be reduced in cases treated by endovascular procedure as compared with those treated by direct clipping. Surgical manipulation of cerebral vessels has been shown to initiate vasospasm⁸. Vasospasm is the leading cause of death and permanent neurological disability in patients with SAH. Therefore, after preventative treatment for rebleeding, treatment for vasospasm is very important. From this point of view, endovascular embolization of the rupture point in the acute stage of SAH followed by clipping in the chronic stage may be a reasonable treatment.

There are cases in which previous endovascular treatment makes clipping either easier or more difficult⁹. Horowitz et al⁵ mentioned that repeated coiling is the ideal mode of treatment for the partially embolized aneurysm, because the surgical treatment is often difficult and carries a risk of parent vessel damage or occlusion. Concerning the disadvantages of this two-staged treatment, the partially embolized aneurysm might cause a mass effect. In the case of a large aneurysm, the aneurysm cannot be collapsed for better visualization. Horowitz et al⁵ reported that clipping of large partially coiled aneurysms can be difficult, because the coiled relatively immobile mass makes visualization around the lesion difficult. In our case 6, the AComA aneurysm caused a mass effect, and the small vessels behind the aneurysm could not be observed. This resulted in occlusion of a perforating artery from the AComA by the clip. In a case of partially embolized aneurysm with relatively complex surrounding structures, such as AComA aneurysm with multiple branching arteries and perforators, careful observation around the aneurysm should be necessary. In such cases, removal of the embolized portion of the aneurysm or coil extraction might be required to visualize the surrounding structures. In 3 of our cases, loops of coil herniated into the residual neck and coil extraction with or without aneurysm resection

had to be performed for complete clip closure. Although one or two loops of coil prolapsing into the parent vessel do not cause thrombus, it makes complete clip closure impossible². Guri-an et al² reported that the thrombus surrounding the platinum coils organized into a fibrotic mass within a few weeks after embolization. Therefore, a coil may become incorporated into the vessel wall, and extraction might carry a risk of causing intimal damage^{2,3}. As Horowitz et al⁵ reported, coil extraction might not be necessary if the aneurysm neck is available and clipping is possible without stenosing the parent artery. However, in cases of aneurysms with coil herniation into the residual neck, coil extraction might be needed for complete clip closure. In such situations, the possibility of inducing parent vessel damage should be always taken into consideration³.

Conclusions

Planned two-staged endovascular and surgical treatment may be of benefit in certain cases of ruptured cerebral aneurysms for which total embolization is impossible. Endovascular embolization can be performed in an emergency in the acute stage of SAH for preventing immediate subsequent rupture.

It may also be effective for preventing rerupture during management for vasospasm and direct surgery. However, in some cases of partially embolized aneurysms presenting mass effects or accompanying coil herniation to the neck remnant, it is difficult to clip without coil extraction. In such situations, care should be taken not to damage the parent arteries, and careful observation around the lesion is demanded.

Therefore, as an initial treatment, we should try to embolize the aneurysm completely. However, if this fails and a two-stage treatment is planned, it might be important for the subsequent clipping procedure to leave the aneurysm neck free of coils.

References

- 1 Regli L, Uske A et Al: Endovascular coil placement of compared with surgical clipping for the treatment of unruptured middle cerebral artery aneurysms: a consecutive series. *J Neurosurg* 90: 1025-1030, 1999.
- 2 Gurian JH, Martin NA et Al: Neurosurgical management of cerebral aneurysms following unsuccessful or incomplete endovascular embolization. *J Neurosurg* 83: 843-853, 1995.
- 3 Mizoi K, Yoshimoto T et Al: A pitfall in the surgery of a recurrent aneurysm after coil embolization and its histological observation: technical case report. *Neurosurgery* 39: 165-169, 1996.
- 4 Civit T, Auque J et Al: Aneurysm clipping after endovascular treatment with coils: a report of eight patients. *Neurosurgery* 38: 955-961, 1996.
- 5 Horowitz M, Purdy P et Al: Aneurysm retreatment after Guglielmi detachable coil and nondetachable coil embolization: report of nine cases and review of the literature. *Neurosurgery* 44: 712-720, 1999.
- 6 Manabe H, Fujita S et Al: Rerupture of coil-embolized aneurysm during long-term observation: case report. *J Neurosurg* 88: 1096-1098, 1998.
- 7 Yalamanchili K, Rosenwasser RH et Al: Frequency of cerebral vasospasm in patients treated with endovascular occlusion of intracranial aneurysms. *Am J Neuroradiol* 19: 553-558, 1998.
- 8 Findlay JM, MacDonald RL et Al: Surgical manipulation of primate cerebral arteries in established vasospasm. *J Neurosurg* 75: 425-432, 1991.
- 9 Guglielmi G: A pitfall in the surgery of a recurrent aneurysm after coil embolization and its histological observation: technical case report (correspondence). *Neurosurgery* 40: 1337-1339, 1997.

Motohiro Nomura, M.D.
Department of Neurosurgery
Kanazawa University School of Medicine
13-1 Takaramachi
Kanazawa 920-8641, Japan
E-mail: mnomura@acocom.yu.edu