Expression of interleukin-33 is correlated with poor prognosis of patients with squamous cell carcinoma of the tongue

メタデータ	言語: English 出版者: 公開日: 2017-10-03 キーワード (Ja): キーワード (En): 作成者: Ishikawa, Kazuya, Yagi-Nakanishi, Sayaka, Nakanishi, Yosuke, Kondo, Satoru, Tsuji, Akira, Endo, Kazuhira, Wakisaka, Naohiro, Murono, Shigeyuki, Yoshizaki, Tomokazu メールアドレス: 所属:
URL	http://hdl.handle.net/2297/39686

Elsevier Editorial System(tm) for Auris Nasus Larynx
Manuscript Draft

Manuscript Number: ANL-D-14-00096R1

Title: Expression of interleukin-33 is correlated with poor prognosis in patients with squamous cell carcinoma of the tongue

Article Type: Original Paper

Keywords: interleukin-33, ST2, tongue squamous cell carcinoma, inflammation, mast cell, malignant potential

Corresponding Author: Prof. Tomokazu Yoshizaki, M.D., Ph.D.

Corresponding Author's Institution: Graduate school of Medicine, Kanazawa University

First Author: Kazuya Ishikawa

Order of Authors: Kazuya Ishikawa; Sayaka Yagi-Nakanishi; Yosuke Nakanishi; Satoru Kondo; Akira Tsuji; Kazuhira Endo; Naohiro Wakisaka; Shigeyuki Murono; Tomokazu Yoshizaki

Abstract: Objective: The aim of this study was to clarify the role of IL-33 in tumor progression.
Methods: Surgical specimens from 81 patients with squamous cell carcinoma of the tongue were studied using immunohistochemistry. Primary tumor sections were analyzed for IL-33 and ST2 expression. To examine the influence of IL-33 on the microenvironment of the tumor, we determined the mast cell density (MCD) and microvessel density of the stroma.
Results: Patients with high IL-33 expression had a significantly worse prognosis ($p = 0.004$). IL-33 expression was significantly elevated in patients with local and nodal recurrence ($p = 0.014$ and $p = 0.019$). ST2 expression was also associated with a worse prognosis ($p = 0.024$) and was significantly elevated in patients with nodal recurrence ($p = 0.004$). MCD was associated with worse prognosis ($p = 0.038$) and correlated significantly with IL-33 expression ($r = 0.626$, $p < 0.001$). Micovessels in the stroma were significantly increased in the high IL-33 group ($p < 0.001$).
Conclusion: These data suggest that the IL-33/ST2 axis contributes to tumor aggressiveness and affects the tumor microenvironment. Immunohistochemical evaluation of IL-33 and ST2 is useful for identifying patients at a high risk for poor prognosis.

June 10, 2014

Ken-ichi Nibu,

Editor-in-Chief, *Auris Nasus Larynx*

Dear Professor Nibu

We are grateful for the opportunity to revise our paper 'ANL-D-14-00096' entitled "Expression of interleukin-33 is correlated with poor prognosis in patients with squamous cell carcinoma of the tongue" and the valuable comments of the two reviewers.

We have revised the manuscript according to the comments from reviewers. We added the information for ethical aspect in materials and methods part and altered an equivocal expression about specimens to clearer one. We also examined the relationship of the prognosis of the high IL-33 patients with postoperative adjuvant therapy.

We attach here our revised manuscript, as well as a point-by-point response to the reviewers' comments.

We now hope that our paper will be suitable for publication in *Auris Nasus Larynx* and look forward to hearing from you concerning your editorial decision.

Yours sincerely,

Tomokazu Yoshizaki MD,PhD

Division of Otolaryngology-Head & Neck Surgery, Graduate School of Medical Science, Kanazawa University, Takara-machi 13-1, Kanazawa, Ishikawa 920-8640, Japan

E-mail: tomoy@med.kanazawa-u.ac.jp

Tel: +81-76-265-2413; fax: +81-76-234-4265

Response to the reviewers' comments

We would like to thank all reviewers for their encouraging and constructive comments that have helped us improve the manuscript. We have modified our manuscript 'ANL-D-14-00096' along the lines suggested. Our point-by-point responses are listed below.

Reviewer #1:

This is an interesting, well written report investigating the role of IL-33/ST2 axis in oral cancer. The authors indicate that immunohistochemical evaluation of IL-33/ST2 is useful for identifying patients at a high risk for poor prognosis. The study is well designed and the basic (immunohistochemical) analyses appear to be well done. Although preliminary and does not indicate a direct effect in oral carcinogenesis, the conclusion seems to be sufficient to understand that IL33expression is an useful prognostic marker.

I only have minor comments.

Response

We really appreciate that this reviewer finds our data interesting. We addressed her/his two issues as requested.

1. This study includes immunohistochemical analysis of tissue samples of patients. Therefore, it is to be desired that authors should describe some comments with regard to the ethical aspect.

We agree with the reviewer' opinion. We added the information for ethical aspect to line 105, 106 in materials and methods part.

2. A multivariant analysis is desired to confirm that IL33expression is an independent prognostic factor.

A cox proportional hazards regression analysis of clinical factors, including sex, age, histologic type, T classification, N classification, expression of IL-33, expression of ST2 and MCD was performed. Univariate analyses were done initially, and then clinical factors that were identified as significantly associated with the disease-free survival rate were included in a multivariate analysis.

The univariate analysis demonstrated that IL-33, ST2, and MCD were significant predictors for prognosis. However, there was no significant predictor in the multivariate analysis. We consider that this is because IL-33 expression correlated with ST2 expression and IL-33 expression also correlated with MCD.

A cox proportional hazards regression analysis of prognostic factors associated with the disease-free survival rate

Prognostic factor	*p* value	RR	95% CI
Univariate analysis			
Sex (male versus female)	0.155	0.589	0.284-1.222
Age (≦60 versus >60)	0.331	1.443	0.689-3.024
Histologic type (WD versus MD/PD)	0.508	1.385	0.528-3.634
T classification (T1+2 versus T3+4)	0.749	1.160	0.467-2.880
N classification (pN0 versus pN1-3)	0.568	1.282	0.547-3.008
Expression of IL-33 (high versus low)	0.007 *	3.241	1.383-7.596
Expression of ST2 (high versus low)	0.030 *	2.473	1.094-5.593
MCD (high versus low)	0.045 *	2.242	1.020-4.931
Multivariate analysis			
Expression of IL-33 (high versus low)	0.084	2.499	0.884-7.069
Expression of ST2 (high versus low)	0.608	1.320	0.457-3.811
MCD (high versus low)	0.691	1.219	0.458-3.246

Abbreviations: RR, relative risk; WD, well differentiated; MD, moderatelty differentiated; PD, poorly differentiated

* Significance

Reviewer #2:

Several biomarkers which correlate with prognosis of SCC have been reported in the head and neck region. The authors reported expression of IL-33 in the tongue SCC and its potentials for predicting prognosis of the patients. This information may shed light to this area and is worthy for publication.

Response

We thank the reviewer for this excellent suggestion and finding our data convincing. We answered the questions that were found in reviewer' text.

1. "2.2. Immunohistochemical analysis
The specimens, including the primary tumors, were fixed in 10% formalin solution and embedded in paraffin."
This sentence means that all specimens were not primary lesions, that is tongue carcinoma. If so, were other specimens obtained from lymph node? Show us percentages of specimens from primary lesion. In addition, was there any difference between primary and metastatic lesion?

Sorry for our sentence which caused misunderstanding. We meant that all specimens were the primary tumors. We didn't evaluate the other specimens like lymph node.
We have corrected the sentence at line 121 intelligibly.

2. Concerning LN metastasis, did you estimate an extranodal extension? If so, was that related to high IL-33?

This is a very good point. Although an extranodal extension also weighs on our mind, we did not estimate it in this study. However, most of IL-33 positive patients developed regional LN recurrences or residual diseases. So, we speculate IL-33 might have contributed to extracapsular invasion.

3. Is there any different prognosis among the high IL-33patients with/ without postoperative adjuvant therapy?

To examine the relationship of the prognosis of the high IL-33 patients with postoperative adjuvant therapy, Kaplan−Meier survival analysis was performed and differences between curves were analyzed using the log-rank test. Of the 41 patients assigned to the high IL-33 group, 14 patients underwent postoperative treatment. Although the patients with postoperative treatment tended to have better prognosis than those without postoperative treatment, there was no significant difference between the two ($p = 0.145$).

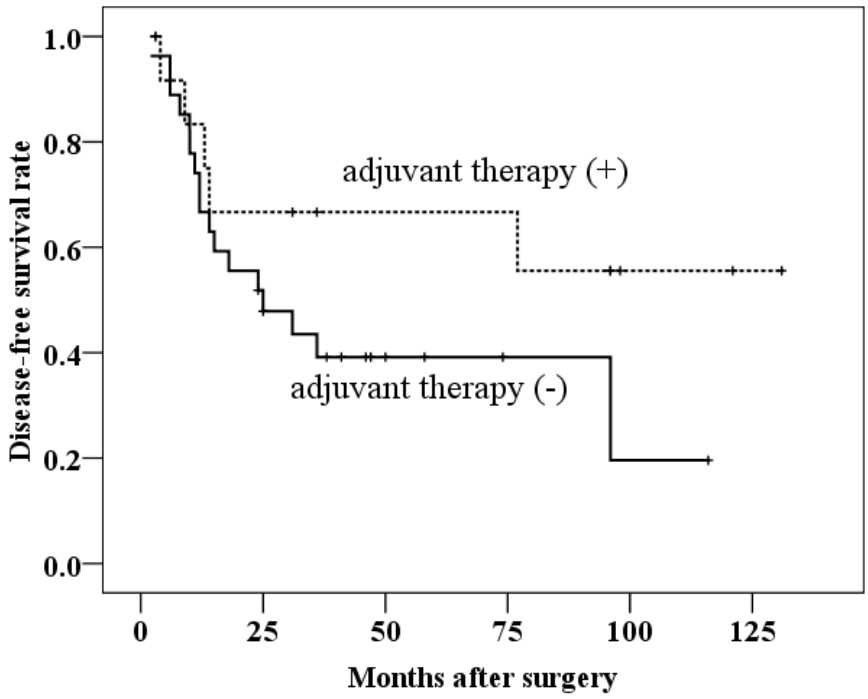

*Title Page, including Author Details

Expression of interleukin-33 is correlated with poor prognosis in patients with squamous cell carcinoma of the tongue

Kazuya Ishikawa [a], Sayaka Yagi-Nakanishi [a], Yosuke Nakanishi [a], Satoru Kondo [a], Akira Tsuji [a], Kazuhira Endo [a], Naohiro Wakisaka [a], Shigeyuki Murono [a], Tomokazu Yoshizaki [a,*]

[a] *Division of Otolaryngology, and Head & Neck Surgery, Graduate School of Medical Science, Kanazawa University, Takara-machi 13-1, Kanazawa, Ishikawa 920-8640, Japan*

* Corresponding author : Division of Otolaryngology, and Head & Neck Surgery, Graduate School of Medical Science, Kanazawa University, Takara-machi 13-1, Kanazawa, Ishikawa 920-8640, Japan. Tel: +81-76-265-2413; fax: +81-76-234-4265

E-mail address: tomoy@med.kanazawa-u.ac.jp (T. Yoshizaki)

Key words: interleukin-33, ST2, tongue squamous cell carcinoma, inflammation, mast cell, malignant potential

Expression of interleukin-33 is correlated with poor prognosis in patients with squamous cell carcinoma of the tongue

Kazuya Ishikawa, Sayaka Yagi-Nakanishi, Yosuke Nakanishi, Satoru Kondo, Akira Tsuji, Kazuhira Endo, Naohiro Wakisaka, Shigeyuki Murono, Tomokazu Yoshizaki

Abstract

Objective: The aim of this study was to clarify the role of IL-33 in tumor progression.

Methods: Surgical specimens from 81 patients with squamous cell carcinoma of the tongue were studied using immunohistochemistry. Primary tumor sections were analyzed for IL-33 and ST2 expression. To examine the influence of IL-33 on the microenvironment of the tumor, we determined the mast cell density (MCD) and microvessel density of the stroma.

Results: Patients with high IL-33 expression had a significantly worse prognosis ($p = 0.004$). IL-33 expression was significantly elevated in patients with local and nodal recurrence ($p = 0.014$ and $p = 0.019$). ST2 expression was also associated with a worse prognosis ($p = 0.024$) and was significantly elevated in patients with nodal recurrence ($p = 0.004$). MCD was associated with worse prognosis ($p = 0.038$) and correlated significantly with IL-33 expression ($r = 0.626$, $p < 0.001$). Micovessels in the stroma were significantly increased in the high IL-33 group ($p < 0.001$).

Conclusion: These data suggest that the IL-33/ST2 axis contributes to tumor aggressiveness and affects the tumor microenvironment. Immunohistochemical evaluation of IL-33 and ST2 is useful for identifying patients at a high risk for poor prognosis.

Key words: interleukin-33, ST2, tongue squamous cell carcinoma, inflammation, mast cell, malignant potential

1. Introduction

Tongue squamous cell carcinoma (SCC) is one of the most common head and neck cancers. Prognosis is associated with clinical stage, particularly nodal status. Therefore, the expression of metastasis-related factors such as matrix metalloproteinases, syndecans, and vascular endothelial growth factor predicts the treatment outcome of patients with tongue SCC [1-4]. Tongue SCC is associated with inflammation in the oral cavity, which is mediated by chronic trauma such as smoking, alcohol consumption, and periodontal disease and is associated with oral carcinogenesis [5]. Moreover, inflammation promotes cancer development and progression through its effects on the tumor microenvironment [6]. Inflammatory mediators and specific cell types influence the migration, invasion, and metastasis of tumor cells [6]. Therefore, efficacious therapies must be developed for targeting inflammation in patients with cancer.

Interleukin (IL)-33 is a member of the IL-1 family and functions as a ligand for ST2, which is a member of the IL-1 receptor family. IL-33 is expressed by many cell types, including epithelial cells, endothelial cells, smooth muscle cells, fibroblasts, and activated macrophages [7]. In contrast, mast cells (MCs), Th2 cells, eosinophils, basophils, epithelial cells, and endothelial cells express ST2 [8-12]. Unlike other members of the IL-1 family, the cleavage site for caspases is located within the IL-1-like domain of IL-33, and the cleavage products are biologically inactive.

Biologically active, full-length IL-33 is released when cells sense inflammatory signals or undergo necrosis. Therefore, IL-33 acts as an endogenous danger signal or “alarmin” [8,13,14]. Binding of extracellular IL-33 to ST2 preferentially induces Th2-type immune responses with concomitant expression of Th2-associated cytokines [7]. It is clear that the potency of IL-33 for activating several immunocytes probably impacts inflammation. For

example, IL-33 is expressed by patients with chronic gastritis, chronic hepatitis, and inflammatory bowel disease [15-17]. Inflammatory diseases increase the risk of developing cancer, suggesting that IL-33 may play an important role in cancer pathogenesis [18,19].

IL-33 affects the phenotype of cell types that express the transmembrane isoform of ST2. The inflammatory component of a neoplasm may include a diverse leukocyte population, and ST2 is expressed on many of these inflammatory cells, including MCs, macrophages, dendritic cells, eosinophils, and neutrophils [8,20]. Among the inflammatory cells in the stroma of the tumor, MCs are important because they secrete cytokines and chemokines, and influence the phenotypes of other cells through these soluble mediators as well as through cell–cell interaction. Moreover, MCs reside in the connective tissue surrounding tumors, and the accumulation of MCs is often associated with poor prognosis [21,22]. IL-33 is a potent activator of MCs and induces their degranulation and maturation, promotes survival, and induces the production of several proinflammatory cytokines [9,23]. Therefore, it is reasonable to assume that IL-33 contributes significantly to the malignant potential of tumor cells through the formation of an inflammatory tumor microenvironment.

We reported the carcinogenic role of activation-induced cytidine deaminase (AID), which is induced by an inflammatory environment [24]. However, the expression of AID does not correlate with the progression of tongue SCC, which diverted our attention to IL-33. Inflammation mediated by tobacco smoking, which is associated with tongue SCC, induces the expression of IL-33/ST2 in mice [25]. In the present study, we determined the expression of IL-33 in patients with tongue SCC using immunohistochemistry and assessed the relationship between the expression of IL-33 and prognosis of tongue SCC. Furthermore, to evaluate the influence of IL-33 on the tumor microenvironment, we determined the density of MCs in the stroma surrounding the tumor.

2. Materials and methods

2.1. Patients and specimens

This study included 81 patients who were diagnosed with tongue SCC. Informed consent was obtained from all patients in accordance with our institutional guidelines. The patient characteristics are presented in Table 1. Their clinical status was determined according to the TNM classification system of the Union Internationale Contre le Cancer [26]. All patients underwent surgery at the Division of Otolaryngology-Head and Neck Surgery, Kanazawa University Hospital between 1982 and 2007. Resection of the primary tongue tumor was performed in all patients, and neck dissection was performed in 53 patients with clinically positive nodes or tumors that were more advanced than stage T2. The 22 patients with positive margins or pathologically positive lymph node metastasis underwent postoperative treatment, including radiotherapy. The mean follow-up period was 50.7 months (median, 41 months; range, 1–131 months). Disease-free survival was calculated from the date of treatment until the time of local recurrence or the detection of metastases, including recurrence in the neck lymph nodes.

2.2. Immunohistochemical analysis

All specimens were the primary tumors. They were fixed in 10% formalin solution and embedded in paraffin. Serial 3-μm-thick sections were cut from each block, dewaxed, and rehydrated. Antigen retrieval was performed by heating slides for 30 min in citrate buffer (pH 6.0) at 90ºC, cooling for 20 min, and washing. Endogenous peroxidase was quenched with methanol and 3% H_2O_2 for 10 min, followed by incubation with Protein Block Serum

(DakoCytomation, Glostrup, Denmark) to decrease nonspecific binding. Then, the sections were incubated overnight at 4ºC with primary antibodies against IL-33 (diluted 1:100, rabbit polyclonal, Medical & Biological Laboratories, Nagoya, Japan), ST2 (diluted 1:100, mouse monoclonal, Medical & Biological Laboratories), mast cell tryptase (diluted 1:1000, mouse monoclonal, Dako), and CD34 (diluted 1:50, mouse monoclonal, Dako). The sections were incubated with secondary antibodies conjugated to a peroxidase-labeled polymer (EnVision™+ system, Dako) at room temperature for 30 min. Immune complexes were detected using 3,3'-diaminobenzidine tetrahydrochloride, and the sections were counterstained with hematoxylin. The specificities of the staining reactions were confirmed using nonimmune serum instead of the primary antibody.

2.3. IL-33 and ST2 expression and mast cell density (MCD)

Two investigators with no prior knowledge of the clinical data assessed the microvessel counts and expression of IL-33, ST2, and tryptase.

Staining results for IL-33 and ST2 were classified by estimating the percentage of tumor cells showing specific immunoreactivity. Two areas with a high density of stained cells were selected in a 40× field, following which the number of immunoreactive cells and the total number of tumor cells were counted in two areas in a 200× field. The percentage of positive cells calculated as an average of two counts was used as the expression score. The antibody against tryptase was used to determine MCD in the stroma surrounding the tumor and was classified by estimating the percentage of tryptase-positive cells in the stroma. The two areas with the highest MCD were identified in a 200× field. Then, the number of tryptase-positive cells and the total number of stromal cells were counted in these areas in a 400× field. To

correlate these results with prognosis, the expression scores and MCD values were divided into high and low groups using median scores as cutoff values.

2.4. Microvessel density (MVD)

MVD was calculated by counting the number of vessels stained with CD-34 according to Weidner et al [27]. Three areas with the highest MVD were selected in a 40× to 100× field. Then, microvessels were counted in the three areas in a 200× field. MVD was calculated as the average of three counts. Any brownish-staining endothelial cell or endothelial cell cluster was considered as a single microvessel.

2.5. Statistical analysis

IBM SPSS Statistics version 19 (IBM, Armonk, New York, USA) was used for data analysis. The clinical characteristics of patients in terms of IL-33 and ST2 expression and MCD were analyzed using Fisher's exact test and the chi-square test. The relationship between IL-33 and ST2 expression and MCD was evaluated using Spearman's rank correlation coefficient. Survival curves were evaluated using the Kaplan–Meier method, and differences between curves were analyzed using the log-rank test. IL-33 expression in relation to MVD was analyzed using the Mann–Whitney U test. A p value of <0.05 was considered statistically significant.

3. Results

3.1. IL-33 and ST2 expression

IL-33 was detected only in the nuclei of normal epithelial cells, and ST2 was observed most frequently, but faintly, in the membrane and cytoplasm of cells in the prickle cell to horny layers (Fig. 1A and 1B). In contrast, IL-33 was detected in the nuclei and cytoplasm of SCC cells (Fig. 1C). ST2 expression was most prominent in the membrane and cytoplasm of the tumor cells (Fig. 1D). IL-33 and ST2 expression were observed in 100% and 95.1% of the samples, respectively. The mean expression scores for IL-33 and ST2 in the tumor cells were 41.59% ± 23.89% and 22.14% ± 19.29%, respectively.

3.2. MCD

MCs were detected by staining with the anti-tryptase antibody in all samples, and they were located in the stroma at the margins of the tumors (Fig. 1E). The mean MCD was 12.54% ± 11.60%.

3.3. Correlation of IL-33 and ST2 expression with MCD

IL-33 expression correlated significantly with ST2 expression ($r = 0.558$, $p < 0.001$, Fig. 2A). IL-33 expression also correlated with MCD ($r = 0.626$, $p < 0.001$, Fig. 2B).

3.4. Association of IL-33 and ST2 expression and MCD with disease-free survival

To evaluate the prognostic value of IL-33 and ST2 expression and MCD in patients with tongue SCC, patients were stratified into high and low groups as described in Methods. The median expression scores for IL-33 and ST2 were 46% and 14%, respectively, and 9% for

MCD. These scores were used as cutoff values. Of the 81 specimens, 41 were assigned to the high group. Kaplan–Meier survival analysis revealed that the prognosis was poorer for the high IL-33 and ST2 groups than for the low IL-33 and ST2 groups ($p = 0.004$ and 0.024, respectively, Fig. 3A and 3B). Similarly, the disease-free survival rate was significantly lower in the high MCD group than in the low MCD group ($p = 0.038$, Fig. 3C).

Furthermore, to examine the relationship of the prognosis of the high IL-33 patients with postoperative adjuvant therapy, Kaplan−Meier survival analysis was performed. Of the 41 patients assigned to the high IL-33 group, 14 patients underwent postoperative radiotherapy. Although the patients with postoperative treatment tended to have better prognosis than those without postoperative treatment, there was no significant difference between the two ($p =$ 0.145 data not shown).

3.5. Relationship between clinicopathological features and expression of IL-33, ST2, and MCD

The relationship between immunohistochemical data and clinicopathological factors of the 81 patients, including age, sex, T classification, N classification, clinical stage, local recurrence, nodal recurrence, and distant metastatic recurrence, was evaluated using Fisher's exact test and the chi-square test (Table 1). Local recurrence was significantly more frequent among patients in the high IL-33 group than among those in the low IL-33 group. IL-33 and ST2 expression and MCD were significantly associated with nodal recurrence. A higher frequency of nodal recurrence associated significantly with the high IL-33, ST2, and MCD groups, but not with the low groups. There were no other significant differences in clinicopathological features between the low and high IL-33, ST2, and MCD groups.

3.6. Relationship between IL-33 expression and MVD

Vascular endothelial cells reacted specifically with the antibody against CD34. The microvessels were detected as scattered structures in the stroma of the tumor (Fig. 1F). MVDs in all patients ranged from 7 to 75 (mean, 34.41 ± 16.46). The correlation between IL-33 expression and MVD is shown in Table 2. MVD was significantly higher in the high IL-33 group than in the low IL-33 group ($p < 0.001$).

Discussion

Little is known about the role of IL-33 in the pathogenesis and progression of carcinomas [18,19]. This is the first study, to our knowledge, that demonstrates IL-33 expression in tongue SCC and suggests its role in the progression of this tumor. We detected the expression of IL-33 and ST2 in patients with tongue SCC by immunohistochemistry and found that the expression of IL-33 was significantly correlated with poor prognosis.

We do not go further for the molecular mechanism which is attributable to the prognostic value of IL-33 in this study, however, one of possible mechanism for IL-33-mediated malignant progression could be an activation of ST2 downstream signal transduction such as nuclear factor-κB (NF-κB). The IL-33/ST2 axis leads to activation of NF-κB [8,20,28], which is a key inducer of innate immunity and inflammation and has emerged as an important endogenous tumor promoter [6,29]. NF-κBactivates the expression of genes encoding inflammatory cytokines, adhesion molecules, enzymes of the prostaglandin-synthesis pathway, inducible nitric oxide synthase, and angiogenic factors. Thus, activation of NF-κB through the IL-33 signaling pathway may cause cancer progression.

Th2-type responses induced by IL-33 may contribute to tumor progression. An induction of IL-33 enhances Th2 immune response and polarizes naïve T cells to produce IL-5 and IL-13 independently of IL-4 [8,20]. High levels of Th2 cytokines are observed in the tumor microenvironment and peripheral blood of patients with certain cancers [30]. Moreover, analysis of ST2-deficient mice demonstrates that the Th2-associated immune response is inhibited in the absence of IL-33/ST2 signaling, leading to delayed induction of mammary tumors and slower tumor growth and progression [31,32].

In addition, IL-33 induces angiogenesis and vasopermeability [33]. Our present study reveals that IL-33 expression strongly correlated with MVD and was significantly associated with local and nodal recurrence, but not clinical stage. These results suggest that IL-33 influences the malignant potential of the tumor through the promotion of angiogenesis and activation of ST2 signaling.

We also demonstrate that IL-33 expression significantly correlated with MCD, suggesting that IL-33 contributes to tumor progression by activating MCs. An induction of IL-33 potently activates the innate immune system by inducing pro-inflammatory cytokines and chemokine production through the activation of MCs. It also induces the degranulation of IgE-primed MCs and enhances their maturation and survival [8,20]. The MCD generally correlates with poor outcome in patients with tongue SCC [34,35]. Furthermore, other studies reveal that IL-33 activates macrophages, dendritic cells, eosinophils, and neutrophils [8,20]. These cells play important roles in enhancing an inflammatory environment that promotes tumor growth in the surrounding tissue [6]. IL-33 may recruit these inflammatory cells to the stroma of the tumor, subsequently enhancing tumor aggressiveness.

In conclusion, the high expression level of IL-33 is a risk factor for poor prognosis in patients with tongue SCC. In the high IL-33 patients, postoperative radiotherapy tended to improve the prognosis. Those patients received postoperative radiotherapy were likely to

have poor prognosis. Therefore, this result suggests that postoperative radiotherapy may be effective in the treatment of the high IL-33 patients with positive margins or pathologically positive lymph node metastasis.

IL-33 and ST2 may represent therapeutic targets for tongue SCC. Although it remains unclear how IL-33/ST2 axis contributes to tumor progression, our findings indicate that the IL-33/ST2 axis promotes the malignant potential of tumor by affecting the tumor as well as its microenvironment. Further investigation is needed to define the role of IL-33 in malignant potential.

Acknowledgement

This study was supported by Japan Society for the Promotion of Science (JSPS) KAKENHI Grant Number 24791760.

Conflict of interest statement

None.

References

[1] Yoshizaki T, Maruyama Y, Sato H, Furukawa M. Expression of tissue inhibitor of matrix metalloproteinase-2 correlates with activation of matrix metalloproteinase-2 and predicts poor prognosis in tongue squamous cell carcinoma. Int J Cancer 2001;95:44-50.

[2] Shimizu Y, Kondo S, Shirai A, Furukawa M, Yoshizaki T. A single nucleotide polymorphism in the matrix metalloproteinase-1 and interleukin-8 gene promoter predicts poor prognosis in tongue cancer. Auris Nasus Larynx 2008;35:381-9.

[3] Endo K, Takino T, Miyamori H, Kinsen H, Yoshizaki T, Furukawa M, et al. Cleavage of syndecan-1 by membrane type matrix metalloproteinase-1 stimulates cell migration. J Biol Chem 2003;278:40764-70.

[4] Hirota K, Wakisaka N, Sawada-Kitamura S, Kondo S, Endo K, Tsuji A, et al. Lymphangiogenesis in regional lymph nodes predicts nodal recurrence in pathological N0 squamous cell carcinoma of the tongue. Histopathology 2012;61:1065-71.

[5] Piemonte ED, Lazos JP, Brunotto M. Relationship between chronic trauma of the oral mucosa, oral potentially malignant disorders and oral cancer. J Oral Pathol Med 2010;39: 513-7.

[6] Mantovani A, Allavena P, Sica A, Balkwill F. Cancer-related inflammation. Nature 2008;454:436-44.

[7] Schmitz J, Owyang A, Oldham E, Song Y, Murphy E, McClanahan TK, et al. IL-33, an interleukin-1-like cytokine that signals via the IL-1 receptor-related protein ST2 and induces T helper type 2-associated cytokines. Immunity 2005;23:479-90.

[8] Liew FY, Pitman NI, Mclnnes IB. Disease-associated functions of IL-33: the new kid in the IL-1 family. Nat Rev Immunol 2010;10:103-10.

[9] Allakhverdi Z, Smith DE, Comeau MR, Delespesse G. Cutting edge: The ST2 ligand IL-33 potently activates and drives maturation of human mast cells. J Immunol 2007;179:2051-4.

[10] Cherry WB, Yoon J, Bartemes KR, Iijima K, Kita H. A novel IL-1 family cytokine, IL-33, potently activates human eosinophils. J Allergy Clin Immunol 2008;121:1484-90.

[11] Kamekura R, Kojima T, Takano K, Go M, Sawada N, Himi T. The role of IL-33 and its receptor ST2 in human nasal epithelium with allergic rhinitis. Clin Exp Allergy 2012;42:218-28.

[12] Aoki S, Hayakawa M, Ozaki H, Takezako N, Obata H, Ibaraki N, et al. ST2 gene expression is proliferation-dependent and its ligand, IL-33, induces inflammatory reaction in endothelial cells. Mol Cell Biochem 2010;335:75-81.

[13] Lamkanfi M, Dixit VM. IL-33 raises alarm. Immunity 2009;31:5-7.

[14] Lüthi AU, Cullen SP, McNeela EA, Duriez PJ, Afonina IS, Sheridan C, et al. Suppression of interleukin-33 bioactivity through proteolysis by apoptotic caspases. Immunity 2009;31:84-98.

[15] Hong SN, Jo S, Jang JH, Choi J, Kim S, Ahn SY, et al. Clinical characteristics and the expression profiles of inflammatory cytokines/cytokine regulatory factors in asymptomatic patients with nodular gastritis. Dig Dis Sci 2012;57:1486-95.

[16] Marvie P, Lisbonne M, L'helgoualc'h A, Rauch M, Turlin B, Preisser L, et al. Interleukin-33 overexpression is associated with liver fibrosis in mice and human. J Cell Mol Med 2010;14:1726-39.

[17] Pastorelli L, Garg RR, Hoang SB, Spina L, Mattioli B, Scarpa M, et al. Epithelial-derived IL-33 and its receptor ST2 are dysregulated in ulcerative colitis and in experimental Th1/Th2 driven enteritis. Proc Natl Acad Sci U S A 2010;107:8017-22.

[18] Sun P, Ben Q, Tu S, Dong W, Qi X, Wu Y. Serum interleukin-33 levels in patients with gastric cancer. Dig Dis Sci 2011;56:3596-601.

[19] Schmieder A, Multhoff G, Radons J. Interleukin-33 acts as a pro-inflammatory cytokine and modulates its receptor gene expression in highly metastatic human pancreatic carcinoma cells. Cytokine 2012;60:514-21.

[20] Miller AM. Role of IL-33 in inflammation and disease. J Inflamm (Lond) 2011;8:22.

[21] Ribatti D, Crivellato E, Roccaro AM, Ria R, Vacca A. Mast cell contribution to angiogenesis related to tumour progression. Clin Exp Allergy 2004;34:1660-4.

[22] Crivellato E, Nico B, Ribatti D. Mast cell contribution to tumor angiogenesis: a clinical approach. Eur Cytokine Netw 2009;20:197-206.

[23] Iikura M, Suto H, Kajiwara N, Oboki K, Ohno T, Okayama Y, et al. IL-33 can promote survival, adhesion and cytokine production in human mast cells. Lab Invest 2007;87:971-8.

[24] Nakanishi Y, Kondo S, Wakisaka N, Tsuji A, Endo K, Murono S, et al. Role of activation-induced cytidine deaminase in the development of oral squamous cell carcinoma. PLoS One 2013;8:e62066.

[25] Qiu C, Li Y, Li M, Li M, Liu X, McSharry C, et al. Anti-interleukin-33 inhibits cigarette smoke-induced lung inflammation in mice. Immunology 2013;138:76-82.

[26] Sobin LH, Wittekind C, editors. TNM classification of malignant tumors. 5th ed. New York, USA: Wiley-Liss; 1997. p. 4-8.

[27] Weidner N, Semple JP, Welch WR, Folkman J. Tumor angiogenesis and metastasis-correlation in invasive breast carcinoma. N Engl J Med 1991;324:1-8.

[28] Milovanovic M, Volarevic V, Radosavljevic G, Jovanovic I, Pejnovic N, Arsenijevic N, et al. IL-33/ST2 axis in inflammation and immunopathology. Immunol Res 2012;52:89-99.

[29] Karin M. Nuclear factor-kappaB in cancer development and progression. Nature 2006;441:431-6.

[30] Hallett MA, Venmar KT, Fingleton B. Cytokine stimulation of epithelial cancer cells: the similar and divergent functions of IL-4 and IL-13. Cancer Res 2012;72:6338-43.

[31] Townsend MJ, Fallon PG, Matthews DJ, Jollin HE, McKenzie AN. T1/ST2-deficient mice demonstrate the importance of T1/ST2 in developing primary T helper cell type 2 responses. J Exp Med 2000;191:1069-76.

[32] Jovanovic I, Radosavljevic G, Mitrovic M, Juranic VL, McKenzie AN, Arsenijevic N, et al. ST2 deletion enhances innate and acquired immunity to murine mammary carcinoma. Eur J immunol 2011;41:1902-12.

[33] Choi YS, Choi HJ, Min JK, Pyun BJ, Maeng YS, Park H, et al. Interleukin-33 induces angiogenesis and vascular permeability through ST2/TRAF6-mediated endothelial nitric oxide production. Blood 2009;114:3117-26.

[34] Alkhabuli JO. Significance of neo-angiogenesis and immune-surveillance cells in squamous cell carcinoma of the tongue. Libyan J Med 2007;2:30-9.

[35] Michailidou EZ, Markopoulos AK, Antoniades DZ. VEGF expression from human dysplastic or malignant oral epithelium may be related to mast cell density and the subsequent angiogenetic phenomena. Int J Oral Maxillofac Surg 2012;41:1467-73.

Figure legends

Figure 1. Immunohistochemical analysis of IL-33 and ST2 expression in normal epithelial and tumor cells (A–D) and tryptase (E) and CD34 (F) expression. (original magnification ×200)

A: IL-33 is detected in the nuclei of normal epithelial cells.

B: ST2 is faintly detected in the membrane and cytoplasm of normal epithelial cells.

C: IL-33 is detected in the nuclei and cytoplasm of tumor cells.

D: Intense staining of ST2 in the membrane and cytoplasm of tumor cells.

E: MCs were detected as dark-brown stained cells using an anti-tryptase antibody. They were also located in the stroma at the tumor margins.

F: CD34 expression in vascular endothelial cells (stained dark brown) in the stroma of the tumor.

Figure 2. Correlation between IL-33 and ST2 expression and MCD in tongue SCC.

A: Correlation between IL-33 and ST2 expression. IL-33 expression correlated significantly with ST2 expression (Spearman's rank correlation coefficient).

B: Correlation between IL-33 expression and MCD. IL-33 expression correlated significantly with MCD.

Figure 3. Kaplan–Meier analysis of disease-free survival rates.

Differences between the curves were analyzed using the log-rank test. Disease-free survival rates in relation to IL-33 expression (A), ST2 expression (B), and MCD (C).

*Manuscript, excluding Author Details
Click here to view linked References

Expression of interleukin-33 is correlated with poor prognosis in patients with squamous cell carcinoma of the tongue

Kazuya Ishikawa, Sayaka Yagi-Nakanishi, Yosuke Nakanishi, Satoru Kondo, Akira Tsuji, Kazuhira Endo, Naohiro Wakisaka, Shigeyuki Murono, Tomokazu Yoshizaki

Abstract

Objective: The aim of this study was to clarify the role of IL-33 in tumor progression.

Methods: Surgical specimens from 81 patients with squamous cell carcinoma of the tongue were studied using immunohistochemistry. Primary tumor sections were analyzed for IL-33 and ST2 expression. To examine the influence of IL-33 on the microenvironment of the tumor, we determined the mast cell density (MCD) and microvessel density of the stroma.

Results: Patients with high IL-33 expression had a significantly worse prognosis ($p = 0.004$). IL-33 expression was significantly elevated in patients with local and nodal recurrence ($p = 0.014$ and $p = 0.019$). ST2 expression was also associated with a worse prognosis ($p = 0.024$) and was significantly elevated in patients with nodal recurrence ($p = 0.004$). MCD was associated with worse prognosis ($p = 0.038$) and correlated significantly with IL-33 expression ($r = 0.626$, $p < 0.001$). Micovessels in the stroma were significantly increased in the high IL-33 group ($p < 0.001$).

Conclusion: These data suggest that the IL-33/ST2 axis contributes to tumor aggressiveness and affects the tumor microenvironment. Immunohistochemical evaluation of IL-33 and ST2 is useful for identifying patients at a high risk for poor prognosis.

Key words: interleukin-33, ST2, tongue squamous cell carcinoma, inflammation, mast cell, malignant potential

1. Introduction

Tongue squamous cell carcinoma (SCC) is one of the most common head and neck cancers. Prognosis is associated with clinical stage, particularly nodal status. Therefore, the expression of metastasis-related factors such as matrix metalloproteinases, syndecans, and vascular endothelial growth factor predicts the treatment outcome of patients with tongue SCC [1-4]. Tongue SCC is associated with inflammation in the oral cavity, which is mediated by chronic trauma such as smoking, alcohol consumption, and periodontal disease and is associated with oral carcinogenesis [5]. Moreover, inflammation promotes cancer development and progression through its effects on the tumor microenvironment [6]. Inflammatory mediators and specific cell types influence the migration, invasion, and metastasis of tumor cells [6]. Therefore, efficacious therapies must be developed for targeting inflammation in patients with cancer.

Interleukin (IL)-33 is a member of the IL-1 family and functions as a ligand for ST2, which is a member of the IL-1 receptor family. IL-33 is expressed by many cell types, including epithelial cells, endothelial cells, smooth muscle cells, fibroblasts, and activated macrophages [7]. In contrast, mast cells (MCs), Th2 cells, eosinophils, basophils, epithelial cells, and endothelial cells express ST2 [8-12]. Unlike other members of the IL-1 family, the cleavage site for caspases is located within the IL-1-like domain of IL-33, and the cleavage products are biologically inactive.

Biologically active, full-length IL-33 is released when cells sense inflammatory signals or undergo necrosis. Therefore, IL-33 acts as an endogenous danger signal or “alarmin” [8,13,14]. Binding of extracellular IL-33 to ST2 preferentially induces Th2-type immune responses with concomitant expression of Th2-associated cytokines [7]. It is clear that the potency of IL-33 for activating several immunocytes probably impacts inflammation. For

example, IL-33 is expressed by patients with chronic gastritis, chronic hepatitis, and inflammatory bowel disease [15-17]. Inflammatory diseases increase the risk of developing cancer, suggesting that IL-33 may play an important role in cancer pathogenesis [18,19].

IL-33 affects the phenotype of cell types that express the transmembrane isoform of ST2. The inflammatory component of a neoplasm may include a diverse leukocyte population, and ST2 is expressed on many of these inflammatory cells, including MCs, macrophages, dendritic cells, eosinophils, and neutrophils [8,20]. Among the inflammatory cells in the stroma of the tumor, MCs are important because they secrete cytokines and chemokines, and influence the phenotypes of other cells through these soluble mediators as well as through cell–cell interaction. Moreover, MCs reside in the connective tissue surrounding tumors, and the accumulation of MCs is often associated with poor prognosis [21,22]. IL-33 is a potent activator of MCs and induces their degranulation and maturation, promotes survival, and induces the production of several proinflammatory cytokines [9,23]. Therefore, it is reasonable to assume that IL-33 contributes significantly to the malignant potential of tumor cells through the formation of an inflammatory tumor microenvironment.

We reported the carcinogenic role of activation-induced cytidine deaminase (AID), which is induced by an inflammatory environment [24]. However, the expression of AID does not correlate with the progression of tongue SCC, which diverted our attention to IL-33. Inflammation mediated by tobacco smoking, which is associated with tongue SCC, induces the expression of IL-33/ST2 in mice [25]. In the present study, we determined the expression of IL-33 in patients with tongue SCC using immunohistochemistry and assessed the relationship between the expression of IL-33 and prognosis of tongue SCC. Furthermore, to evaluate the influence of IL-33 on the tumor microenvironment, we determined the density of MCs in the stroma surrounding the tumor.

2. Materials and methods

2.1. Patients and specimens

This study included 81 patients who were diagnosed with tongue SCC. Informed consent was obtained from all patients in accordance with our institutional guidelines. The patient characteristics are presented in Table 1. Their clinical status was determined according to the TNM classification system of the Union Internationale Contre le Cancer [26]. All patients underwent surgery at the Division of Otolaryngology-Head and Neck Surgery, Kanazawa University Hospital between 1982 and 2007. Resection of the primary tongue tumor was performed in all patients, and neck dissection was performed in 53 patients with clinically positive nodes or tumors that were more advanced than stage T2. The 22 patients with positive margins or pathologically positive lymph node metastasis underwent postoperative treatment, including radiotherapy. The mean follow-up period was 50.7 months (median, 41 months; range, 1–131 months). Disease-free survival was calculated from the date of treatment until the time of local recurrence or the detection of metastases, including recurrence in the neck lymph nodes.

2.2. Immunohistochemical analysis

All specimens were the primary tumors. They were fixed in 10% formalin solution and embedded in paraffin. Serial 3-μm-thick sections were cut from each block, dewaxed, and rehydrated. Antigen retrieval was performed by heating slides for 30 min in citrate buffer (pH 6.0) at 90ºC, cooling for 20 min, and washing. Endogenous peroxidase was quenched with methanol and 3% H_2O_2 for 10 min, followed by incubation with Protein Block Serum

(DakoCytomation, Glostrup, Denmark) to decrease nonspecific binding. Then, the sections were incubated overnight at 4ºC with primary antibodies against IL-33 (diluted 1:100, rabbit polyclonal, Medical & Biological Laboratories, Nagoya, Japan), ST2 (diluted 1:100, mouse monoclonal, Medical & Biological Laboratories), mast cell tryptase (diluted 1:1000, mouse monoclonal, Dako), and CD34 (diluted 1:50, mouse monoclonal, Dako). The sections were incubated with secondary antibodies conjugated to a peroxidase-labeled polymer (EnVision™+ system, Dako) at room temperature for 30 min. Immune complexes were detected using 3,3'-diaminobenzidine tetrahydrochloride, and the sections were counterstained with hematoxylin. The specificities of the staining reactions were confirmed using nonimmune serum instead of the primary antibody.

2.3. IL-33 and ST2 expression and mast cell density (MCD)

Two investigators with no prior knowledge of the clinical data assessed the microvessel counts and expression of IL-33, ST2, and tryptase.

Staining results for IL-33 and ST2 were classified by estimating the percentage of tumor cells showing specific immunoreactivity. Two areas with a high density of stained cells were selected in a 40× field, following which the number of immunoreactive cells and the total number of tumor cells were counted in two areas in a 200× field. The percentage of positive cells calculated as an average of two counts was used as the expression score. The antibody against tryptase was used to determine MCD in the stroma surrounding the tumor and was classified by estimating the percentage of tryptase-positive cells in the stroma. The two areas with the highest MCD were identified in a 200× field. Then, the number of tryptase-positive cells and the total number of stromal cells were counted in these areas in a 400× field. To

correlate these results with prognosis, the expression scores and MCD values were divided into high and low groups using median scores as cutoff values.

2.4. Microvessel density (MVD)

MVD was calculated by counting the number of vessels stained with CD-34 according to Weidner et al [27]. Three areas with the highest MVD were selected in a 40× to 100× field. Then, microvessels were counted in the three areas in a 200× field. MVD was calculated as the average of three counts. Any brownish-staining endothelial cell or endothelial cell cluster was considered as a single microvessel.

2.5. Statistical analysis

IBM SPSS Statistics version 19 (IBM, Armonk, New York, USA) was used for data analysis. The clinical characteristics of patients in terms of IL-33 and ST2 expression and MCD were analyzed using Fisher's exact test and the chi-square test. The relationship between IL-33 and ST2 expression and MCD was evaluated using Spearman's rank correlation coefficient. Survival curves were evaluated using the Kaplan–Meier method, and differences between curves were analyzed using the log-rank test. IL-33 expression in relation to MVD was analyzed using the Mann–Whitney U test. A p value of <0.05 was considered statistically significant.

3. Results

3.1. IL-33 and ST2 expression

IL-33 was detected only in the nuclei of normal epithelial cells, and ST2 was observed most frequently, but faintly, in the membrane and cytoplasm of cells in the prickle cell to horny layers (Fig. 1A and 1B). In contrast, IL-33 was detected in the nuclei and cytoplasm of SCC cells (Fig. 1C). ST2 expression was most prominent in the membrane and cytoplasm of the tumor cells (Fig. 1D). IL-33 and ST2 expression were observed in 100% and 95.1% of the samples, respectively. The mean expression scores for IL-33 and ST2 in the tumor cells were 41.59% ± 23.89% and 22.14% ± 19.29%, respectively.

3.2. MCD

MCs were detected by staining with the anti-tryptase antibody in all samples, and they were located in the stroma at the margins of the tumors (Fig. 1E). The mean MCD was 12.54% ± 11.60%.

3.3. Correlation of IL-33 and ST2 expression with MCD

IL-33 expression correlated significantly with ST2 expression ($r = 0.558$, $p < 0.001$, Fig. 2A). IL-33 expression also correlated with MCD ($r = 0.626$, $p < 0.001$, Fig. 2B).

3.4. Association of IL-33 and ST2 expression and MCD with disease-free survival

To evaluate the prognostic value of IL-33 and ST2 expression and MCD in patients with tongue SCC, patients were stratified into high and low groups as described in Methods. The median expression scores for IL-33 and ST2 were 46% and 14%, respectively, and 9% for

MCD. These scores were used as cutoff values. Of the 81 specimens, 41 were assigned to the high group. Kaplan–Meier survival analysis revealed that the prognosis was poorer for the high IL-33 and ST2 groups than for the low IL-33 and ST2 groups ($p = 0.004$ and 0.024, respectively, Fig. 3A and 3B). Similarly, the disease-free survival rate was significantly lower in the high MCD group than in the low MCD group ($p = 0.038$, Fig. 3C).

Furthermore, to examine the relationship of the prognosis of the high IL-33 patients with postoperative adjuvant therapy, Kaplan–Meier survival analysis was performed. Of the 41 patients assigned to the high IL-33 group, 14 patients underwent postoperative radiotherapy. Although the patients with postoperative treatment tended to have better prognosis than those without postoperative treatment, there was no significant difference between the two ($p = 0.145$ data not shown).

3.5. Relationship between clinicopathological features and expression of IL-33, ST2, and MCD

The relationship between immunohistochemical data and clinicopathological factors of the 81 patients, including age, sex, T classification, N classification, clinical stage, local recurrence, nodal recurrence, and distant metastatic recurrence, was evaluated using Fisher's exact test and the chi-square test (Table 1). Local recurrence was significantly more frequent among patients in the high IL-33 group than among those in the low IL-33 group. IL-33 and ST2 expression and MCD were significantly associated with nodal recurrence. A higher frequency of nodal recurrence associated significantly with the high IL-33, ST2, and MCD groups, but not with the low groups. There were no other significant differences in clinicopathological features between the low and high IL-33, ST2, and MCD groups.

3.6. Relationship between IL-33 expression and MVD

Vascular endothelial cells reacted specifically with the antibody against CD34. The microvessels were detected as scattered structures in the stroma of the tumor (Fig. 1F). MVDs in all patients ranged from 7 to 75 (mean, 34.41 ± 16.46). The correlation between IL-33 expression and MVD is shown in Table 2. MVD was significantly higher in the high IL-33 group than in the low IL-33 group ($p < 0.001$).

Discussion

Little is known about the role of IL-33 in the pathogenesis and progression of carcinomas [18,19]. This is the first study, to our knowledge, that demonstrates IL-33 expression in tongue SCC and suggests its role in the progression of this tumor. We detected the expression of IL-33 and ST2 in patients with tongue SCC by immunohistochemistry and found that the expression of IL-33 was significantly correlated with poor prognosis.

We do not go further for the molecular mechanism which is attributable to the prognostic value of IL-33 in this study, however, one of possible mechanism for IL-33-mediated malignant progression could be an activation of ST2 downstream signal transduction such as nuclear factor-κB (NF-κB). The IL-33/ST2 axis leads to activation of NF-κB [8,20,28], which is a key inducer of innate immunity and inflammation and has emerged as an important endogenous tumor promoter [6,29]. NF-κBactivates the expression of genes encoding inflammatory cytokines, adhesion molecules, enzymes of the prostaglandin-synthesis pathway, inducible nitric oxide synthase, and angiogenic factors. Thus, activation of NF-κB through the IL-33 signaling pathway may cause cancer progression.

Th2-type responses induced by IL-33 may contribute to tumor progression. An induction of IL-33 enhances Th2 immune response and polarizes naïve T cells to produce IL-5 and IL-13 independently of IL-4 [8,20]. High levels of Th2 cytokines are observed in the tumor microenvironment and peripheral blood of patients with certain cancers [30]. Moreover, analysis of ST2-deficient mice demonstrates that the Th2-associated immune response is inhibited in the absence of IL-33/ST2 signaling, leading to delayed induction of mammary tumors and slower tumor growth and progression [31,32].

In addition, IL-33 induces angiogenesis and vasopermeability [33]. Our present study reveals that IL-33 expression strongly correlated with MVD and was significantly associated with local and nodal recurrence, but not clinical stage. These results suggest that IL-33 influences the malignant potential of the tumor through the promotion of angiogenesis and activation of ST2 signaling.

We also demonstrate that IL-33 expression significantly correlated with MCD, suggesting that IL-33 contributes to tumor progression by activating MCs. An induction of IL-33 potently activates the innate immune system by inducing pro-inflammatory cytokines and chemokine production through the activation of MCs. It also induces the degranulation of IgE-primed MCs and enhances their maturation and survival [8,20]. The MCD generally correlates with poor outcome in patients with tongue SCC [34,35]. Furthermore, other studies reveal that IL-33 activates macrophages, dendritic cells, eosinophils, and neutrophils [8,20]. These cells play important roles in enhancing an inflammatory environment that promotes tumor growth in the surrounding tissue [6]. IL-33 may recruit these inflammatory cells to the stroma of the tumor, subsequently enhancing tumor aggressiveness.

In conclusion, the high expression level of IL-33 is a risk factor for poor prognosis in patients with tongue SCC. In the high IL-33 patients, postoperative radiotherapy tended to improve the prognosis. Those patients received postoperative radiotherapy were likely to

have poor prognosis. Therefore, this result suggests that postoperative radiotherapy may be effective in the treatment of the high IL-33 patients with positive margins or pathologically positive lymph node metastasis.

IL-33 and ST2 may represent therapeutic targets for tongue SCC. Although it remains unclear how IL-33/ST2 axis contributes to tumor progression, our findings indicate that the IL-33/ST2 axis promotes the malignant potential of tumor by affecting the tumor as well as its microenvironment. Further investigation is needed to define the role of IL-33 in malignant potential.

Acknowledgement

This study was supported by Japan Society for the Promotion of Science (JSPS) KAKENHI Grant Number 24791760.

Conflict of interest statement

None.

References

[1] Yoshizaki T, Maruyama Y, Sato H, Furukawa M. Expression of tissue inhibitor of matrix metalloproteinase-2 correlates with activation of matrix metalloproteinase-2 and predicts poor prognosis in tongue squamous cell carcinoma. Int J Cancer 2001;95:44-50.

[2] Shimizu Y, Kondo S, Shirai A, Furukawa M, Yoshizaki T. A single nucleotide polymorphism in the matrix metalloproteinase-1 and interleukin-8 gene promoter predicts poor prognosis in tongue cancer. Auris Nasus Larynx 2008;35:381-9.

[3] Endo K, Takino T, Miyamori H, Kinsen H, Yoshizaki T, Furukawa M, et al. Cleavage of syndecan-1 by membrane type matrix metalloproteinase-1 stimulates cell migration. J Biol Chem 2003;278:40764-70.

[4] Hirota K, Wakisaka N, Sawada-Kitamura S, Kondo S, Endo K, Tsuji A, et al. Lymphangiogenesis in regional lymph nodes predicts nodal recurrence in pathological N0 squamous cell carcinoma of the tongue. Histopathology 2012;61:1065-71.

[5] Piemonte ED, Lazos JP, Brunotto M. Relationship between chronic trauma of the oral mucosa, oral potentially malignant disorders and oral cancer. J Oral Pathol Med 2010;39: 513-7.

[6] Mantovani A, Allavena P, Sica A, Balkwill F. Cancer-related inflammation. Nature 2008;454:436-44.

[7] Schmitz J, Owyang A, Oldham E, Song Y, Murphy E, McClanahan TK, et al. IL-33, an interleukin-1-like cytokine that signals via the IL-1 receptor-related protein ST2 and induces T helper type 2-associated cytokines. Immunity 2005;23:479-90.

[8] Liew FY, Pitman NI, Mclnnes IB. Disease-associated functions of IL-33: the new kid in the IL-1 family. Nat Rev Immunol 2010;10:103-10.

[9] Allakhverdi Z, Smith DE, Comeau MR, Delespesse G. Cutting edge: The ST2 ligand IL-33 potently activates and drives maturation of human mast cells. J Immunol 2007;179:2051-4.

[10] Cherry WB, Yoon J, Bartemes KR, Iijima K, Kita H. A novel IL-1 family cytokine, IL-33, potently activates human eosinophils. J Allergy Clin Immunol 2008;121:1484-90.

[11] Kamekura R, Kojima T, Takano K, Go M, Sawada N, Himi T. The role of IL-33 and its receptor ST2 in human nasal epithelium with allergic rhinitis. Clin Exp Allergy 2012;42:218-28.

[12] Aoki S, Hayakawa M, Ozaki H, Takezako N, Obata H, Ibaraki N, et al. ST2 gene expression is proliferation-dependent and its ligand, IL-33, induces inflammatory reaction in endothelial cells. Mol Cell Biochem 2010;335:75-81.

[13] Lamkanfi M, Dixit VM. IL-33 raises alarm. Immunity 2009;31:5-7.

[14] Lüthi AU, Cullen SP, McNeela EA, Duriez PJ, Afonina IS, Sheridan C, et al. Suppression of interleukin-33 bioactivity through proteolysis by apoptotic caspases. Immunity 2009;31:84-98.

[15] Hong SN, Jo S, Jang JH, Choi J, Kim S, Ahn SY, et al. Clinical characteristics and the expression profiles of inflammatory cytokines/cytokine regulatory factors in asymptomatic patients with nodular gastritis. Dig Dis Sci 2012;57:1486-95.

[16] Marvie P, Lisbonne M, L'helgoualc'h A, Rauch M, Turlin B, Preisser L, et al. Interleukin-33 overexpression is associated with liver fibrosis in mice and human. J Cell Mol Med 2010;14:1726-39.

[17] Pastorelli L, Garg RR, Hoang SB, Spina L, Mattioli B, Scarpa M, et al. Epithelial-derived IL-33 and its receptor ST2 are dysregulated in ulcerative colitis and in experimental Th1/Th2 driven enteritis. Proc Natl Acad Sci U S A 2010;107:8017-22.

[18] Sun P, Ben Q, Tu S, Dong W, Qi X, Wu Y. Serum interleukin-33 levels in patients with gastric cancer. Dig Dis Sci 2011;56:3596-601.

[19] Schmieder A, Multhoff G, Radons J. Interleukin-33 acts as a pro-inflammatory cytokine and modulates its receptor gene expression in highly metastatic human pancreatic carcinoma cells. Cytokine 2012;60:514-21.

[20] Miller AM. Role of IL-33 in inflammation and disease. J Inflamm (Lond) 2011;8:22.

[21] Ribatti D, Crivellato E, Roccaro AM, Ria R, Vacca A. Mast cell contribution to angiogenesis related to tumour progression. Clin Exp Allergy 2004;34:1660-4.

[22] Crivellato E, Nico B, Ribatti D. Mast cell contribution to tumor angiogenesis: a clinical approach. Eur Cytokine Netw 2009;20:197-206.

[23] Iikura M, Suto H, Kajiwara N, Oboki K, Ohno T, Okayama Y, et al. IL-33 can promote survival, adhesion and cytokine production in human mast cells. Lab Invest 2007;87:971-8.

[24] Nakanishi Y, Kondo S, Wakisaka N, Tsuji A, Endo K, Murono S, et al. Role of activation-induced cytidine deaminase in the development of oral squamous cell carcinoma. PLoS One 2013;8:e62066.

[25] Qiu C, Li Y, Li M, Li M, Liu X, McSharry C, et al. Anti-interleukin-33 inhibits cigarette smoke-induced lung inflammation in mice. Immunology 2013;138:76-82.

[26] Sobin LH, Wittekind C, editors. TNM classification of malignant tumors. 5th ed. New York, USA: Wiley-Liss; 1997. p. 4-8.

[27] Weidner N, Semple JP, Welch WR, Folkman J. Tumor angiogenesis and metastasis-correlation in invasive breast carcinoma. N Engl J Med 1991;324:1-8.

[28] Milovanovic M, Volarevic V, Radosavljevic G, Jovanovic I, Pejnovic N, Arsenijevic N, et al. IL-33/ST2 axis in inflammation and immunopathology. Immunol Res 2012;52:89-99.

[29] Karin M. Nuclear factor-kappaB in cancer development and progression. Nature 2006;441:431-6.

[30] Hallett MA, Venmar KT, Fingleton B. Cytokine stimulation of epithelial cancer cells: the similar and divergent functions of IL-4 and IL-13. Cancer Res 2012;72:6338-43.

[31] Townsend MJ, Fallon PG, Matthews DJ, Jollin HE, McKenzie AN. T1/ST2-deficient mice demonstrate the importance of T1/ST2 in developing primary T helper cell type 2 responses. J Exp Med 2000;191:1069-76.

[32] Jovanovic I, Radosavljevic G, Mitrovic M, Juranic VL, McKenzie AN, Arsenijevic N, et al. ST2 deletion enhances innate and acquired immunity to murine mammary carcinoma. Eur J immunol 2011;41:1902-12.

[33] Choi YS, Choi HJ, Min JK, Pyun BJ, Maeng YS, Park H, et al. Interleukin-33 induces angiogenesis and vascular permeability through ST2/TRAF6-mediated endothelial nitric oxide production. Blood 2009;114:3117-26.

[34] Alkhabuli JO. Significance of neo-angiogenesis and immune-surveillance cells in squamous cell carcinoma of the tongue. Libyan J Med 2007;2:30-9.

[35] Michailidou EZ, Markopoulos AK, Antoniades DZ. VEGF expression from human dysplastic or malignant oral epithelium may be related to mast cell density and the subsequent angiogenetic phenomena. Int J Oral Maxillofac Surg 2012;41:1467-73.

Figure legends

Figure 1. Immunohistochemical analysis of IL-33 and ST2 expression in normal epithelial and tumor cells (A–D) and tryptase (E) and CD34 (F) expression. (original magnification ×200)

A: IL-33 is detected in the nuclei of normal epithelial cells.

B: ST2 is faintly detected in the membrane and cytoplasm of normal epithelial cells.

C: IL-33 is detected in the nuclei and cytoplasm of tumor cells.

D: Intense staining of ST2 in the membrane and cytoplasm of tumor cells.

E: MCs were detected as dark-brown stained cells using an anti-tryptase antibody. They were also located in the stroma at the tumor margins.

F: CD34 expression in vascular endothelial cells (stained dark brown) in the stroma of the tumor.

Figure 2. Correlation between IL-33 and ST2 expression and MCD in tongue SCC.

A: Correlation between IL-33 and ST2 expression. IL-33 expression correlated significantly with ST2 expression (Spearman's rank correlation coefficient).

B: Correlation between IL-33 expression and MCD. IL-33 expression correlated significantly with MCD.

Figure 3. Kaplan–Meier analysis of disease-free survival rates.

Differences between the curves were analyzed using the log-rank test. Disease-free survival rates in relation to IL-33 expression (A), ST2 expression (B), and MCD (C).

Table 1

Relationship between clinicopathological features and expression of IL-33, ST2, and MCD

Characteristic		Samples	Number of high IL-33 expresssion (%)	*p*	Number of high ST2 expression (%)	*p*	Number of high MCD (%)	*p*
Sex	Male	50	24 (48.0)	0.550	25 (50.0)	0.888	25 (50.0)	0.888
	Femal	31	17 (54.8)		16 (51.6)		16 (51.6)	
Age	≦60	40	17 (42.5)	0.149	20 (50.0)	0.913	21 (52.5)	0.738
	>60	41	24 (58.5)		21 (51.2)		20 (48.8)	
Histologic type	WD	70	37 (52.9)	0.349	37 (52.9)	0.349	36 (51.4)	0.756
	MD/PD	11	4 (36.4)		4 (36.4)		5 (45.5)	
T classification	T1+T2	67	32 (47.8)	0.379	32 (47.8)	0.379	32 (47.8)	0.379
	T3+T4	14	9 (64.3)		9 (64.3)		9 (64.3)	
N classification	pN0	62	32 (51.6)	0.798	34 (54.8)	0.198	35 (56.5)	0.070
	pN1-3	19	9 (47.4)		7 (36.8)		6 (31.6)	
Stage	Ⅰ+Ⅱ	55	25 (45.5)	0.176	26 (47.3)	0.381	27 (49.1)	0.689
	Ⅲ+Ⅳ	26	16 (61.5)		15 (57.7)		14 (53.8)	
Local recurrence	negative	71	32 (45.1)	0.014 *	34 (47.9)	0.312	35 (49.3)	0.737
	positive	10	9 (90.0)		7 (70.0)		6 (60.0)	
Nodal recurrence	negative	61	26 (42.6)	0.019 *	25 (41.0)	0.004 *	25 (41.0)	0.004 *
	positive	20	15 (75.0)		16 (80.0)		16 (80.0)	
Distant metastatic recurrence	negative	78	38 (48.7)	0.241	40 (51.3)	0.616	39 (50.0)	1.000
	positive	3	3 (100.0)		1 (33.3)		2 (66.7)	

Abbreviations: WD, well differentiated; MD, moderatelty differentiated; PD, poorly differentiated

* Significance

Table 2

Relationship between IL-33 expression and MVD

		Number of patients	MVD (mean ± SD)	*p*
IL-33	High	41	43.46 ± 15.694	< 0.001 *
	Low	40	25.13 ± 11.346	

* Significance

Figure 1

Click here to download high resolution image

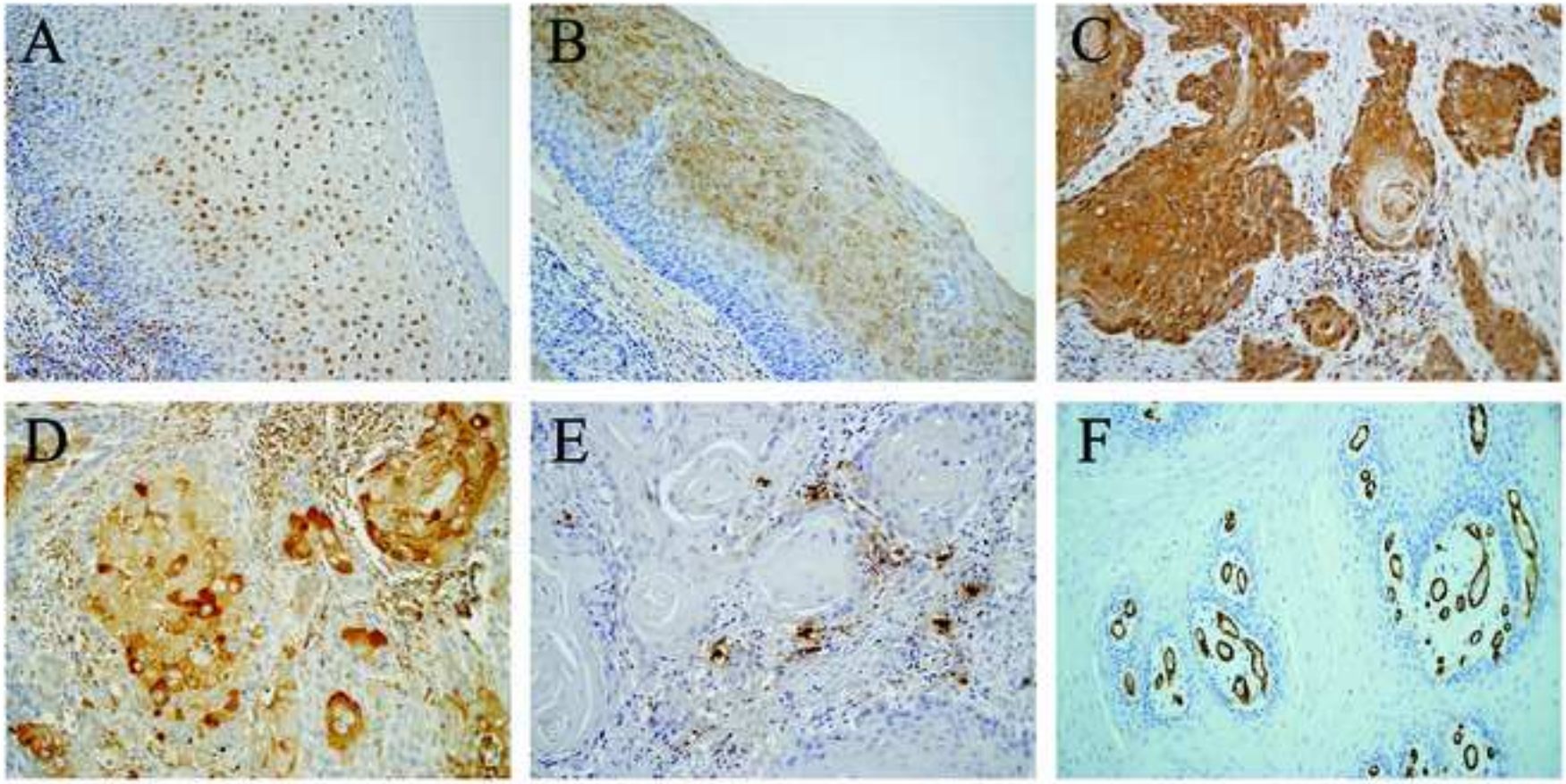

Figure 2
Click here to download high resolution image

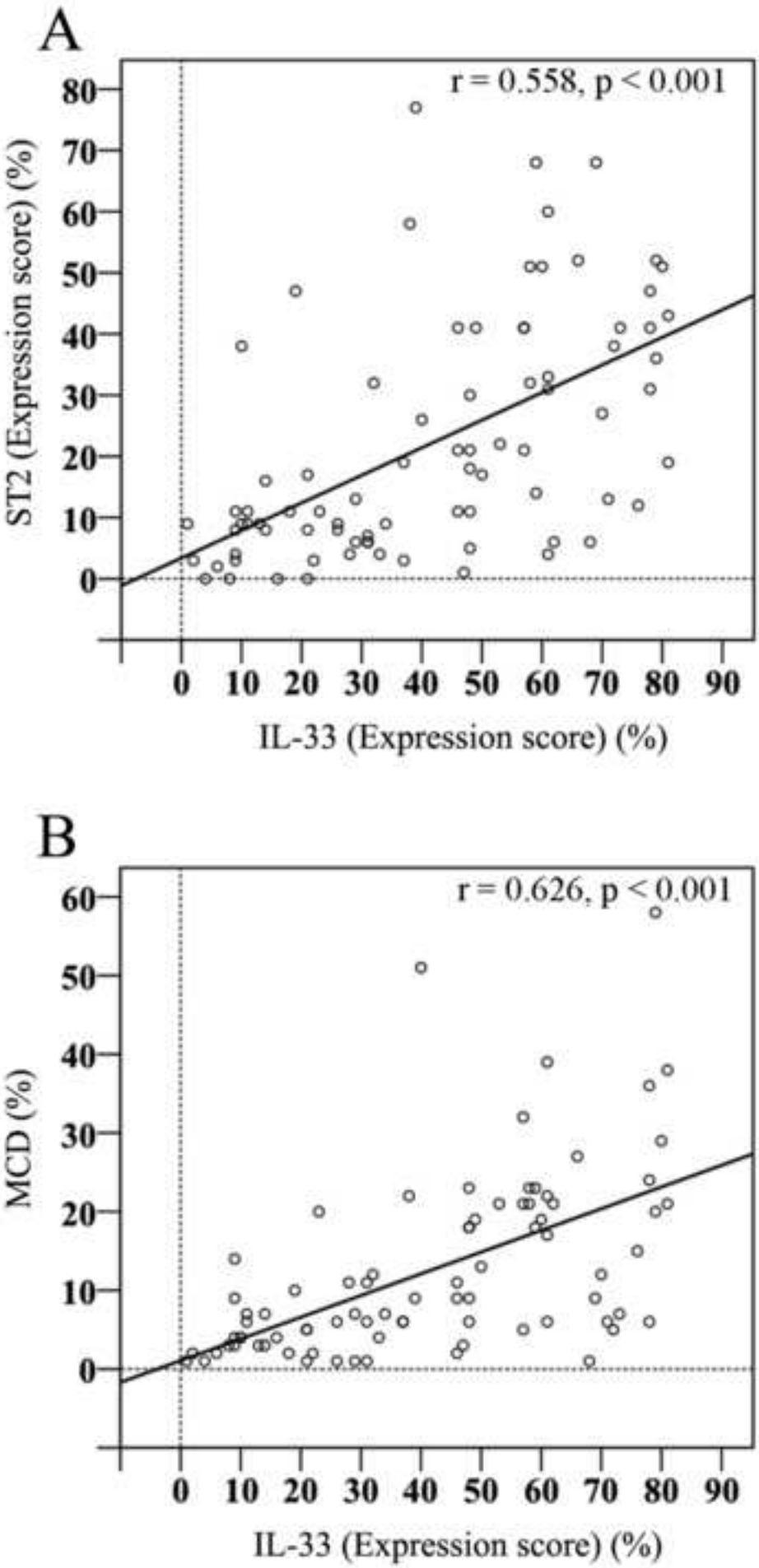

Figure 3
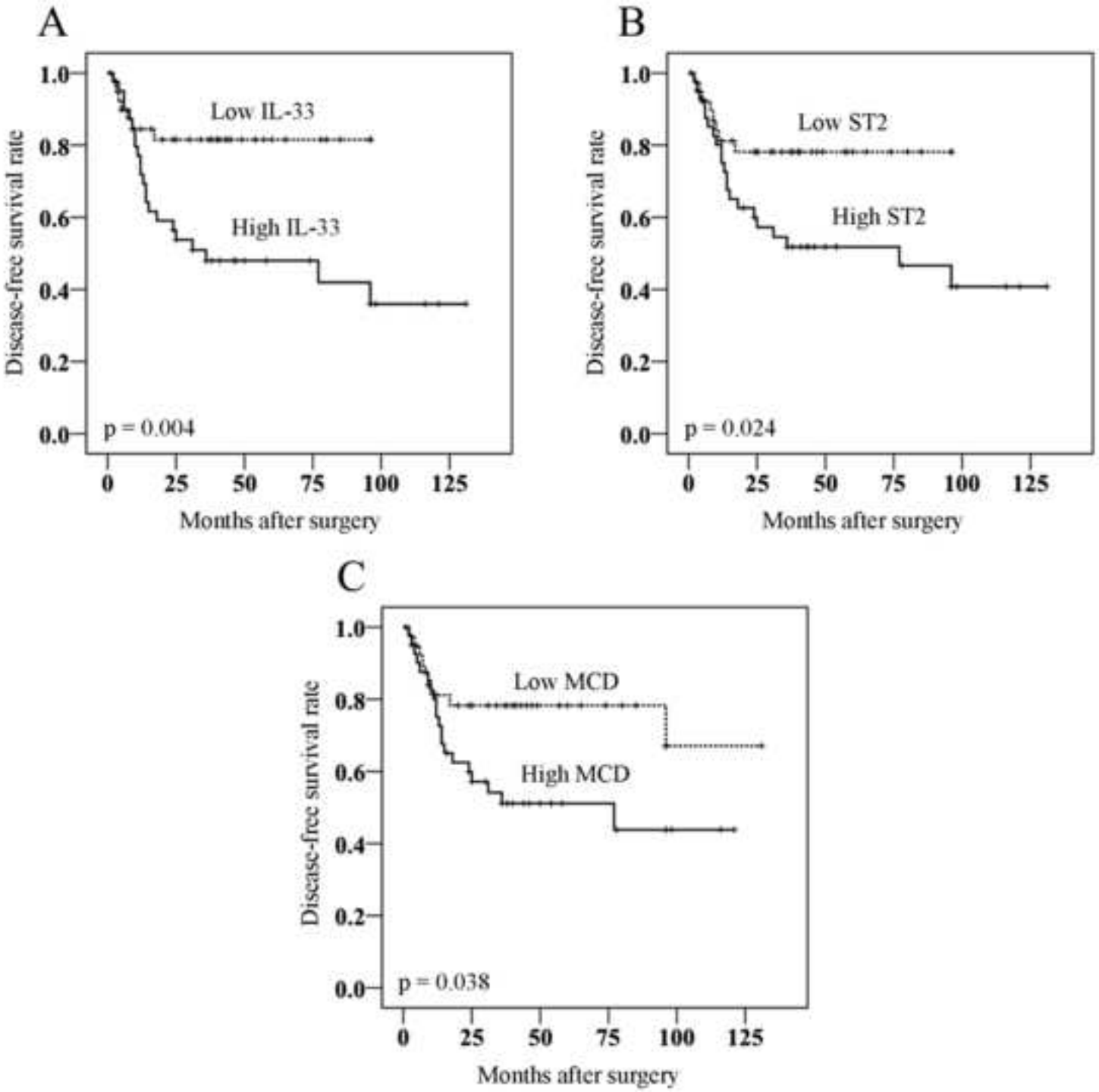
Click here to download high resolution image