

Technique of anatomical single bundle ACL reconstruction with rounded rectangle femoral dilator

メタデータ	言語: eng 出版者: 公開日: 2017-10-03 キーワード (Ja): キーワード (En): 作成者: メールアドレス: 所属:
URL	http://hdl.handle.net/2297/44869

Title: Technique of anatomical single bundle ACL reconstruction with rounded rectangle femoral dilator

Authors:

Junsuke Nakase, M.D., Ph.D., Department of Orthopaedic Surgery, School of Medicine, Kanazawa University, Kanazawa, Japan.

Tatsuhiro Toratani, M.D., Department of Orthopaedic Surgery, School of Medicine, Kanazawa University, Kanazawa, Japan.

Masahiro Kosaka, M.D., Department of Orthopaedic Surgery, School of Medicine, Kanazawa University, Kanazawa, Japan.

Yoshinori Ohashi, M.D., Department of Orthopaedic Surgery, School of Medicine, Kanazawa University, Kanazawa, Japan.

Hitoaki Numata, M.D., Department of Orthopaedic Surgery, School of Medicine, Kanazawa University, Kanazawa, Japan.

Takeshi Oshima, M.D., Department of Orthopaedic Surgery, School of Medicine, Kanazawa University, Kanazawa, Japan.

Yasushi Takata, M.D., Department of Orthopaedic Surgery, School of Medicine, Kanazawa University, Kanazawa, Japan.

Hiroyuki Tsuchiya, M.D., Ph.D., Department of Orthopaedic Surgery, School of Medicine, Kanazawa University, Kanazawa, Japan.

Corresponding author:

Junsuke Nakase

13-1 Takaramachi, Kanazawa 920-8641, Japan

Tel: +81-76-265-2374

Fax: +81-76-234-4261

E-mail: nakase1007@yahoo.co.jp

Introduction

Injury to the anterior cruciate ligament (ACL) is one of the most common sports-related knee injuries, with an annual incidence of 100,000 to 200,000 in the United States ^[1]. Due to the unsatisfactory outcomes of conservative treatments for ACL injuries, ACL reconstruction remains the treatment of choice in most young patients who wish to maintain an active lifestyle. However, clinical studies indicate that non-anatomical ACL graft placement is the most common technical error that subsequently leads to recurrent instability after reconstruction ^[2,3]. Therefore, the anatomical placement of an ACL graft is generally considered critical to the successful clinical outcome of ACL reconstruction ^[4], although this topic remains controversial.

The anatomical double bundle ACL reconstruction technique was first reported in 2004 by Yasuda et al. ^[5]. Since that time, several studies have reported that the anatomical double-bundle techniques provide more stable anterior-posterior translation (as measured using the KT-1000 arthrometer) and restore more rotational stability, compared to the conventional single bundle ACL reconstruction ^[6-8]. However, concerns remain regarding double bundle ACL reconstruction. One concern is the need to drill four independent tunnels, which doubles the risk of incorrect tunnel placement, and several authors have also reported significant tunnel widening after double bundle ACL reconstruction ^[9]. Furthermore, double bundle ACL reconstruction requires longer operative times and creates more extensive bone loss, thereby potentially increasing the difficulty of revision surgery. Therefore, attention has returned to single bundle reconstruction with grafts that are placed at the center of anatomical footprint.

Several recent biomechanical studies have shown that single bundle ACL grafts that are placed in the center of their anatomic insertions can provide nearly normal knee kinematics, which are comparable to double bundle ACL reconstruction ^[10]. In 2010, we began

performing anatomical single bundle ACL reconstruction with a navigation system, and have successfully restored good knee stability for most of our patients. However, some patient who underwent anatomical single bundle ACL reconstruction with a smaller graft (a graft diameter of <8 mm) experienced poor rotational stability, and this result is similar to the report by Mariscalco et al. ^[11]. Therefore, we must improve the operative methods for anatomical single bundle reconstruction. Several anatomical studies have reported that the femoral insertion for the ACL has an oval or semilunar shape ^[12, 13], and we have also realized that the quadrupled semitendinosus and gracilis tendons appear to be oval, rather than circular. Therefore, we have designed and developed an original rounded rectangle tendon diameter tester and dilator for the new anatomical single bundle ACL reconstruction.

The purpose of this study was to present an anatomical single bundle technique that used the original rounded rectangle shaped dilators to create a rounded rectangular femoral tunnel, and to investigate the tunnel's position, using three-dimensional computed tomography (CT) and intraoperative X-p, as well as the incidence of intraoperative complications.

Methods

In this study, all subjects were informed regarding the purpose, procedures, and known risks of this technique, and informed consent was obtained from all subjects. This study's design was reviewed and approved by our institutional ethics review board. Fifty patients were diagnosed with an ACL tear and subsequently underwent ACL reconstruction between July 2013 and March 2015; all procedures were conducted by a single surgeon (J.N.). A diagnosis of an ACL injury was reached based on a history of knee injury and the results of the Lachman and pivot shift tests, as well as a side-to-side difference of ≥ 3 mm when measured using the KT-1000 arthrometer (MEDmetric, San Diego, USA). All patients underwent magnetic resonance imaging (MRI) to confirm the diagnosis of an ACL tear. The inclusion

criteria were a unilateral complete ACL tear and no previous knee ligament surgery, and the exclusion criterion was a multiple ligament injury.

Surgical Technique

Patient positioning

The patient was positioned in the supine position on the operation table. A tourniquet was placed high on the thigh, and distal and lateral supports were placed to keep the knee flexed at an angle of $\geq 90^\circ$.

Graft harvesting

The semitendinosus tendon, with or without the gracilis tendon, was harvested using an open tendon stripper via a 4 cm oblique incision, which was made medial to the tibial tuberosity. When the four-fold semitendinosus graft size was less than 6×9 mm (as measured using a rounded rectangle diameter tester), we harvested the gracilis tendon. To ensure that the graft fit into the rounded rectangular tunnel, the original rounded rectangle measuring device was used to evaluate the graft diameter (Fig. 1).

Femoral tunnel

The femoral tunnel was created before the tibial tunnel via an additional low anteromedial portal, which was created with the knee maintained at 90° of flexion. Using the lateral intercondylar ridge as an anatomical landmark, and taking care not to damage the remnant fibers of the ACL on the femur, a mark was made at the center of the ACL's femoral insertion using a freehand technique and a radiofrequency device at 90° of knee flexion. With the knee in full flexion ($>120^\circ$), a RetroButton Drill Pin (Arthrex, Naples, USA) was inserted via the low anteromedial portal and penetrated the lateral side of the thigh to create a femoral tunnel with a diameter of 3.5 mm. When the wire was placed centrally within the femoral insertion, the femoral tunnel was drilled to a length of 15 mm using a 6.0 mm drill tip and the RetroButton Drill Pin. To create the rounded rectangular aperture, we used the original

rounded rectangle dilators, which are available in various sizes (Fig. 2). The tunnel was dilated according to the graft size, and we then confirmed the rotation angle of the dilator using intraoperative X-p to mimic the ACL insertion (Fig. 3). In all cases, we dilated the full 15 mm of the femoral tunnel.

Tibial tunnel

The tibial tunnel was drilled with a tibial guide set at a 50° angle, and the tip of the aimer was positioned to be 3–4 mm anterior to the posterior border of the anterior horn of the lateral meniscus, and directly anteromedial to the center of the tibial attachment of the ACL. The tunnel was then drilled according to the diameter of the graft with a conventional drill bit.

Graft passage and fixation

The graft was inserted via the tibial tunnel, and was looped over a TightRope (Arthrex, Naples, USA) for femoral fixation. After the button was flipped, the graft was manually pulled backwards and the joint was moved several times through the full range of motion. The other end of the graft was fixed using a Double Spike Plate and screw (Smith and Nephew, Andover, USA), and the initial graft tension was set to 40 N at 20° of knee flexion (Fig. 4).

Evaluating the femoral tunnel position

In all patients, computed tomography was performed at 1 week after the ACL reconstruction to evaluate the femoral tunnel's positioning. We obtained 0.6-mm-thick cross-sectional images (taken perpendicular to the anatomical axis of the femur), the images were used to reconstruct the femur (without any soft tissue) using the AquarisNET (TeraRecon Inc. Foster City, CA, USA) three-dimensional rendering program, and the center of the femoral tunnel was identified on the reconstructed image. According to the quadrant method that was suggested by Bernard ^[14], the center of the tunnel was defined as point A and a rectangle was formed using Blumensaat's line, a parallel line that was tangential to the most inferior margin of the lateral condyle, and two perpendicular lines that were tangential to the

shallowest/deepest subchondral contours of the lateral femoral condyle. Using this rectangle, the following four distances were measured: the distance of the lateral femoral condyle on the sagittal plane along Blumensaat's line (t), the maximum height of the intercondylar notch (h), the distance from point A to the deepest subchondral contour of the lateral femoral condyle (a), and the distance from point A to Blumensaat's line (b). The ratios of a:t and b:h were then expressed as percentages to describe the femoral tunnel's position (Fig. 5).

Evaluating the tibial tunnel position

The tibial tunnel position was evaluated using intraoperative X-p (anterior-posterior and lateral), and we obtained the true anterior-posterior and lateral knee images using intraoperative fluoroscopy. The distance from the medial end of the tibia to the guide pin was set as "m", and the width of the tibia was set as "W". The distance from the anterior edge of the tibia to the guide pin was set as "s", and the anteroposterior diameter was set as "L". The ratios of m:W and s:L were then expressed as percentages to describe the tibial tunnel's position (Fig. 6).

Evaluating the intraoperative complications

After each surgery, the surgeon and colleagues completed a questionnaire evaluating the following intraoperative complications: (1) posterior tunnel wall blowout, (2) damage to the neurovascular structures due to an inferior exit of the guide pin from the lateral thigh, (3) iatrogenic injury to the medial femoral condyle, (4) bending and breakage of the rigid guide pin in the hyper-flexed position, and (6) difficulty of the graft's passage^[15]. The tunnel length was measured intraoperatively using a ruler.

Results

The mean femoral tunnel length was 35.5 ± 3.2 mm (range, 30–40 mm), and all grafts were inserted 15 mm into the femoral tunnels. Only the semitendinosus tendon was harvested in

25 of the 50 patients and the semitendinosus and gracilis tendons were harvested in the 25 remaining patients. The sizes of the femoral and tibial tunnels are listed in Table 1.

Using the positioning ratios that we calculated, the femoral tunnel was located at $25.3 \pm 5.8\%$ from the deepest subchondral contour of the lateral femoral condyle, and at $31.8 \pm 4.3\%$ from Blumensaat's line. The center of the tibial tunnel was located at $40.3 \pm 2.8\%$ from the anterior margin and at $45.6 \pm 4.5\%$ from the medial margin. One patient experienced a partial posterior tunnel wall blowout, although the damage was minimal, and we corrected the graft using the normal technique. No other intraoperative complications were observed.

Discussion

The most important finding of this study was that we did not experience any serious intraoperative complications during anatomical single bundle ACL reconstruction using the rounded rectangle dilator. Furthermore, the femoral and tibial tunnels were located within the anatomical ACL footprint.

The importance of matching the ACL footprints as closely as possible has been reported in several biomechanical studies ^[16, 17]. Therefore, our rationale for developing the rounded rectangle dilators was the ability of the rounded rectangle tunnels to more closely mimic the femoral footprint (compared to the rounded tunnels). In addition, Ho et al. ^[18] and Sastre et al. ^[10] have reported that anatomical single bundle ACL reconstruction and double bundle ACL reconstruction provide very similar stability. Thus, attention has returned to single bundle reconstruction with the graft placed at the center of the anatomical position. In contrast, Araki et al. ^[19] have reported that anatomical double bundle ACL reconstruction provides superior stability (when measured using an electromagnetic system) compared to anatomical single bundle ACL reconstruction. Unfortunately, anatomical single bundle ACL reconstruction using a circular or oval shape cannot increase the size of the femoral tunnel

without causing roof impingement. However, rounded rectangle anatomical single bundle ACL reconstruction can increase the femoral tunnel size without causing roof impingement, depending on the size of the harvested graft. In the future, we hope to create the femoral tunnel based on the native ACL size, rather than the harvested graft size. Interestingly, Iriuchishima et al. ^[20] have reported that the height and area of the femoral intercondylar notch's lateral wall can be a predictor of the native ACL size prior to surgery. Therefore, it may be possible to overcome the size constraints of anatomical single bundle ACL reconstruction if we use rounded rectangle ACL reconstruction. In addition, a drill heats the bone ^[21], while a dilator does not heat the bone and may prevent tunnel widening by compressing the cancellous bone ^[22]. However, further investigation is needed to address these issues.

In this study, the femoral and tibial tunnels were all located within the anatomical ACL footprint. Among the various methods that are used to assess the femoral tunnel position, the quadrant method is the most commonly used, and it assumes that the center of the ACL footprint is located between the anteromedial bundle and the posterolateral bundle. Piefer et al. ^[23] have reported that the center of the ACL footprint is located at 21.5% in the anteromedial bundle and 32.0% in the posterolateral bundle, relative to the deepest subchondral contour of the lateral femoral condyle, compared to 23.1% in the anteromedial bundle and 48.8% in the posterolateral bundle, relative to Blumensaat's line. In the current study, the center of the femoral tunnel was located at 25.3% from the deepest subchondral contour of the lateral femoral condyle and at 31.8% from Blumensaat's line. This result indicates that our femoral tunnels were located slightly posterior and shallower, compared the placement that was reported by Piefer et al. However, this result appears to be reasonable for tendon-bone healing, as the tendon-bone junction is revitalized on the anterior side of the femoral bone tunnel ^[24].

According to Lorenz^[23], the proper position for the center of the anteromedial bundle is at 41% of the tibial sagittal plane and at 48% of tibial coronal plane, while the posterolateral bundle should be placed at 52% of the tibial sagittal plane and at 50% of the tibial coronal plane. In the present study, the center of the tibial tunnel was located at 40.3% from the anterior margin and at 45.6% from the medial margin. However, this position also appears to be reasonable for tendon-bone healing, as the tendon-bone junction is revitalized on the posterolateral side of the tibial bone tunnel^[25].

Lubowitz^[15] has reported several intraoperative complications that may be associated with the anteromedial portal, such as posterior tunnel wall blowout, damage to the neurovascular structures (due to an inferior exit of the guide pin from the lateral thigh), and iatrogenic injury to the medial femoral condyle. In the present study, we only observed one complication, which was a partial posterior tunnel wall blowout. However, the cause appeared to be the low knee flexion angle, and this complication can be avoided by finding the center of the femoral footprint and using $>120^\circ$ of knee flexion during drilling. Unfortunately, one limitation of this technique is that we cannot directly observe the residual posterior wall length during femoral dilation. Therefore, it is important to consider the graft size during drilling.

Anatomical single bundle ACL reconstruction with an “oval” femoral tunnel (i.e., not a rounded rectangle) has recently attracted attention, and several methods have been reported^[21, 26]. However, the oval femoral tunnel has several disadvantages, compared to the rounded rectangle femoral tunnel. For example, the oval femoral tunnel cannot increase the size of the femoral tunnel without roof impingement, and does not restore the flat tendon bone junction, as described by Smigielski^[27]. Therefore, our technique with the rounded rectangle dilator may potentially reduce the graft failure rate of anatomical ACL reconstructions, compared to that of non-anatomical or standard ACL reconstructions.

This study has two important limitations. First, we obtained true anterior-posterior and

lateral knee images using intraoperative fluoroscopy to evaluate the tibial tunnel position. Therefore, it is possible that an error in the rotation may have affected our findings. Second, the variability in the femoral tunnel position was high, compare to the variability for the tibial bone tunnel position. We believe that this variability may be related to our freehand surgical technique and individual differences in the shape of each femur. Nevertheless, further research is needed to determine whether this variability had significant clinical effects.

Conclusion

We did not experience any serious intraoperative complications during anatomical single bundle ACL reconstruction using a rounded rectangle dilator, and the resulting locations of the femoral and tibial tunnels were near the center of ACL foot print. Thus, this technique may facilitate a larger graft in anatomical ACL reconstruction (without risk of impingement), which may help reduce the failure rate of anatomical ACL reconstruction.

References

- [1] Buoncrisiani AM, Tjoumakaris FP, Starman JS, Ferretti M, Fu FH. Anatomic double-bundle anterior cruciate ligament reconstruction. *Arthroscopy* 2006; 22: 1000-6.
- [2] Kamath GV, Redfern JC, Greis PE, Burks RT. Revision anterior cruciate ligament reconstruction. *Am J Sports Med* 2011; 39: 199-217.
- [3] Marchant B, Noyes F, Barber-Westin S, Fleckenstein C. Prevalence of nonanatomical graft placement in a series of failed anterior cruciate ligament reconstruction. *Am J Sports Med* 2010; 38: 1987-96.
- [4] Fu FH, van Eck CF, Tashman S, Irrgang JJ, Moreland MS. Anatomic anterior cruciate ligament reconstruction: a changing paradigm. *Knee Surg Sports Traumatol Arthrosc* 2015; 23: 640-8.
- [5] Yasuda K, Kondo E, Ichiyama H, Kitamura N, Tanabe Y, Tohyama H, Minami A.

Anatomic reconstruction of the anteromedial and posterolateral bundles of the anterior cruciate ligament using hamstring tendon graft. *Arthroscopy* 2004; 20: 1015-25.

[6] Yagi M, Kuroda R, Nagamune K, Yoshiya S, Kurosaka M. Double-bundle ACL reconstruction can improve rotational stability. *Clin Orthop Relat Res* 2007; 454: 100-7.

[7] Colombet P, Robinson J, Christel P, Franceschi JP, Djian P. Using navigation to measure rotation kinematics during ACL reconstruction. *Clin Orthop Relat Res* 2007; 454: 59-65.

[8] Aglietti P, Giron F, Losco M, Cuomo P, Ciardullo A, Mondanelli N. Comparison between single-and double-bundle anterior cruciate ligament reconstruction: a prospective, randomized, single-blinded clinical trial. *Am J Sports Med* 2010; 38: 25-34.

[9] Siebold R. Observations on bone tunnel enlargement after double-bundle anterior cruciate ligament reconstruction. *Arthroscopy* 2007; 13: 291-8.

[10] Sastre S, Popescu D, Nunez M, Pomes J, Tomas X, Peidro L. Double-bundle versus single-bundle ACL reconstruction using the horizontal femoral position: a prospective, randomized study. *Knee Surg Sports Traumatol Arthrosc* 2010; 18: 32-6.

[11] Mariscalco MW, Flanigan DC, Mitchell J, Pedroza AD, Jones MH, Andrish JT, Parker RD, Kaeding CC, Magnussen RA. The influence of hamstring autograft size on patient-reported outcomes and risk of revision after anterior cruciate ligament reconstruction: a Multicenter Orthopaedic Outcomes Network (MOON) Cohort Study. *Arthroscopy* 2013; 29: 1948-53.

[12] Petersen W, Zantop T. Anatomy of the anterior cruciate ligament with regard to its two bundles. *Clin Orthop Relat Res* 2007; 454: 35-47.

[13] Sasaki N, Ishibashi Y, Tsuda E, Yamamoto Y, Maeda S, Mizukami H, Toh S, Yagihashi S, Tonosaki Y. The femoral insertion of the anterior cruciate ligament: discrepancy between macroscopic and histological observations. *Arthroscopy* 2012; 28: 1135-46.

[14] Bernard M, Hertel P, Hornung H, Cierpinski T. Femoral insertion of the ACL.

Radiographic quadrant method. *Am J Knee Surg* 1997; 10: 14-21.

[15] Lubowitz JH. Anteromedial portal technique for the anterior cruciate ligament femoral socket: pitfalls and solutions. *Arthroscopy* 2009; 25: 95-101.

[16] Herbort M, Lenschow S, Fu FH, Petersen W, Zantop T. ACL mismatch reconstructions: influence of different tunnel placement strategies in single-bundle ACL reconstructions on the knee kinematics. *Knee Surg Sports Traumatol Arthrosc*. 2010; 18: 1551-8.

[17] Kato Y, Maeyama A, Lertwanich P, Wang JH, Ingham SJ, Kramer S, Martins CQ, Smolinski P, Fu FH. Biomechanical comparison of different graft positions for single-bundle anterior cruciate ligament reconstruction. *Knee Surg Sports Traumatol Arthrosc* 2013; 21: 816-23.

[18] Ho JY, Gardiner A, Shah V, Steiner ME. Equal kinematics between central anatomic single-bundle and double-bundle anterior cruciate ligament reconstructions. *Arthroscopy*. 2009; 21: 464-72.

[19] Araki D, Kuroda R, Kubo S, Fujita N, Tei K, Nishimoto K, Hoshino Y, Matsushita T, Matsumoto T, Nagamune K, Kurosaka M. A prospective randomized study of anatomical single-bundle versus double-bundle anterior cruciate ligament reconstruction: quantitative evaluation using an electromagnetic measurement system. *Int Orthop* 2011; 35: 439-46.

[20] Iriuchishima T, Shirakura K, Yorifuji H, Aizawa S, Murakami T, Fu FH. ACL footprint size is correlated with the height and area of the lateral wall of femoral intercondylar notch. *Knee Surg Sports Traumatol Arthrosc* 2013; 21: 789-96.

[21] Petersen W, Forkel P, Achtnich A, Metzlaß S, Zantop T. Technique of anatomical footprint reconstruction of the ACL with oval tunnels and medial portal aimers. *Arch Orthop Trauma Surg* 2013; 133: 827-33.

[22] Gokce A, Beyzadeoglu T, Ozyer F, Bekler H, Erdogan F. Does bone impaction technique reduce tunnel enlargement in ACL reconstruction? *Int Orthop* 2009; 33: 407-412.

- [23] Piefer JW, Pflugner TR, Hwang MD, Lubowitz JH. Anterior cruciate ligament femoral footprint anatomy: systematic review of the 21st century literature. *Arthroscopy* 2012; 28: 872-81.
- [24] Nakase J, Kitaoka K, Toratani T, Kosaka M, Ohashi Y, Tsuchiya H. Grafted tendon healing in femoral and tibial tunnels after anterior cruciate ligament reconstruction. *J Orthop Surg (Hong Kong)* 2014; 22: 65-9.
- [25] Lorenz S, Elser F, Mitterer M, Obst T, Imhoff AB. Radiologic evaluation of the insertion sites of the 2 functional bundles of the anterior cruciate ligament using 3-dimensional computed tomography. *Am J Sports Med* 2009; 37: 2368-76.
- [26] Noh JH, Yang BG, Roh YH, Kim SW, Kim W. Anterior cruciate ligament reconstruction using 4-strand hamstring autograft: conventional single-bundle technique versus oval-footprint technique. *Arthroscopy* 2001; 27: 1502-10.
- [27] Smigielski R, Zdanowicz U, Drwięga M, Ciszek B, Ciszewska-Łysoń B, Siebold R. Ribbon like appearance of the midsubstance fibres of the anterior cruciate ligament close to its femoral insertion site: a cadaveric study including 111 knees. *Knee Surg Sports Traumatol Arthrosc* 2014; doi: 10.1007/s00167-014-3146-7.



Fig. 1



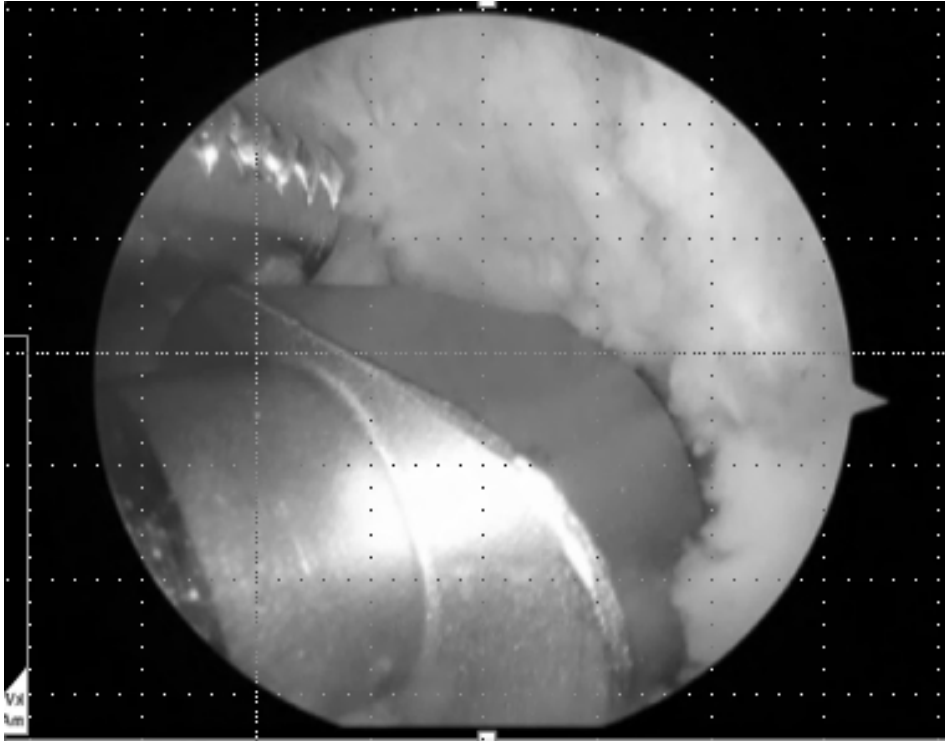


Fig. 2

A



B

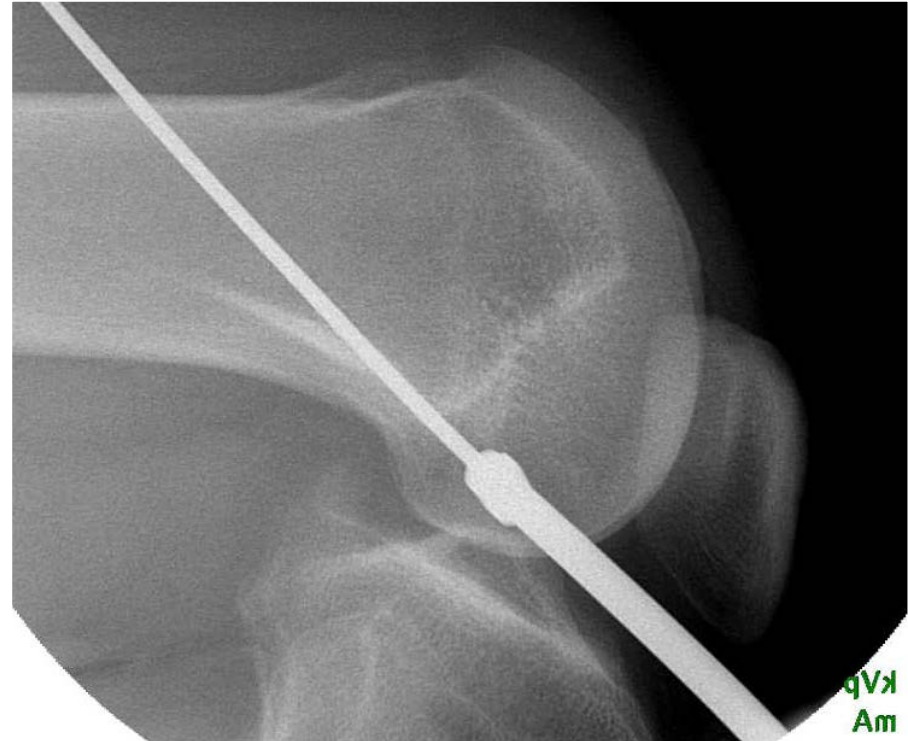
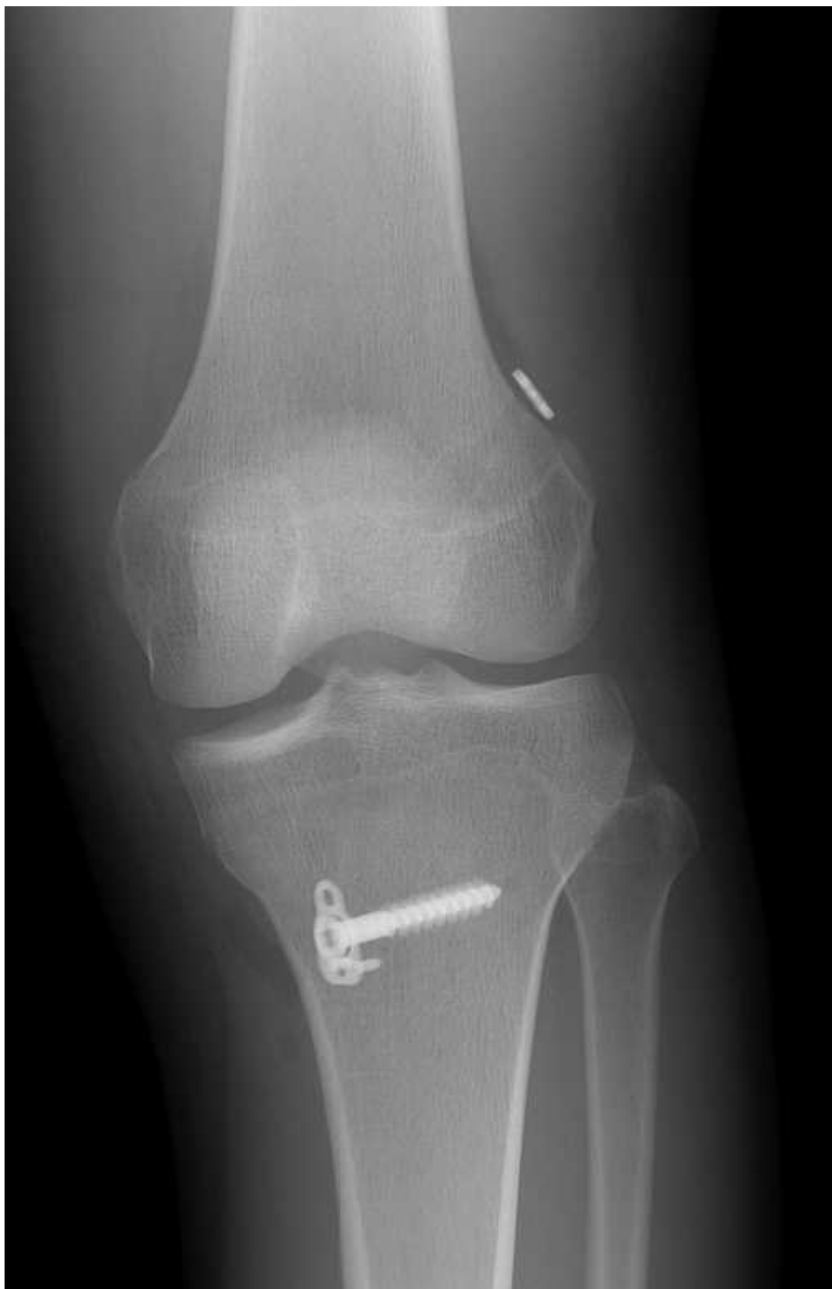
Fig. 3

A



B

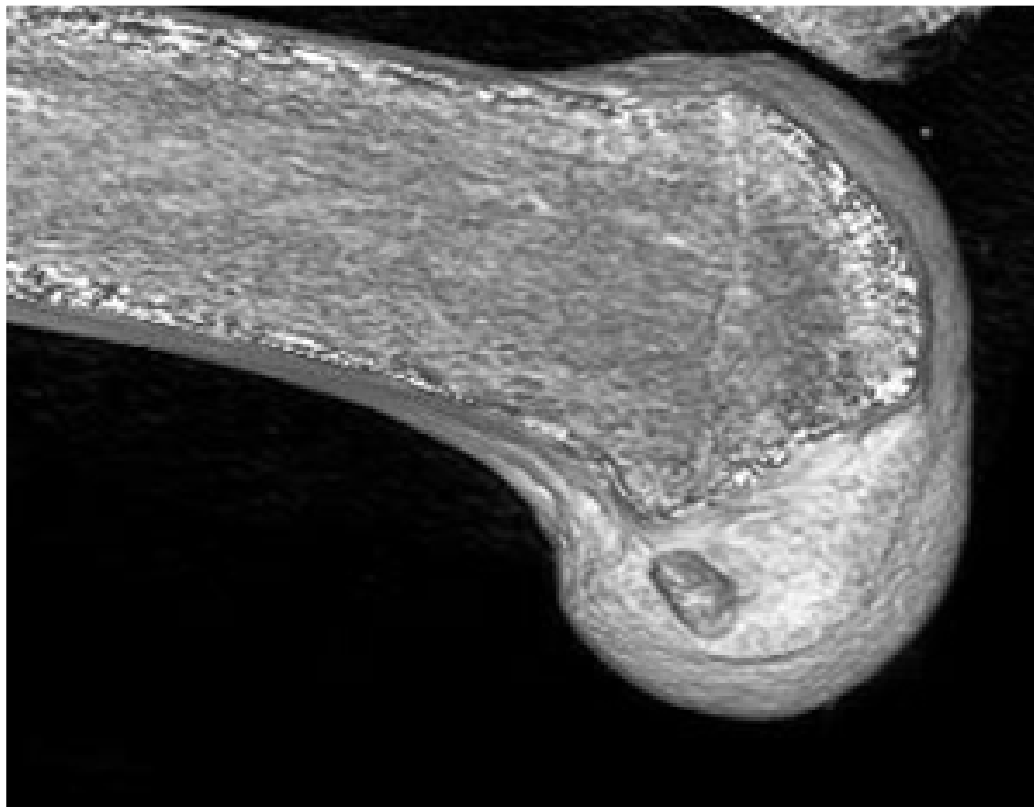


Fig. 4

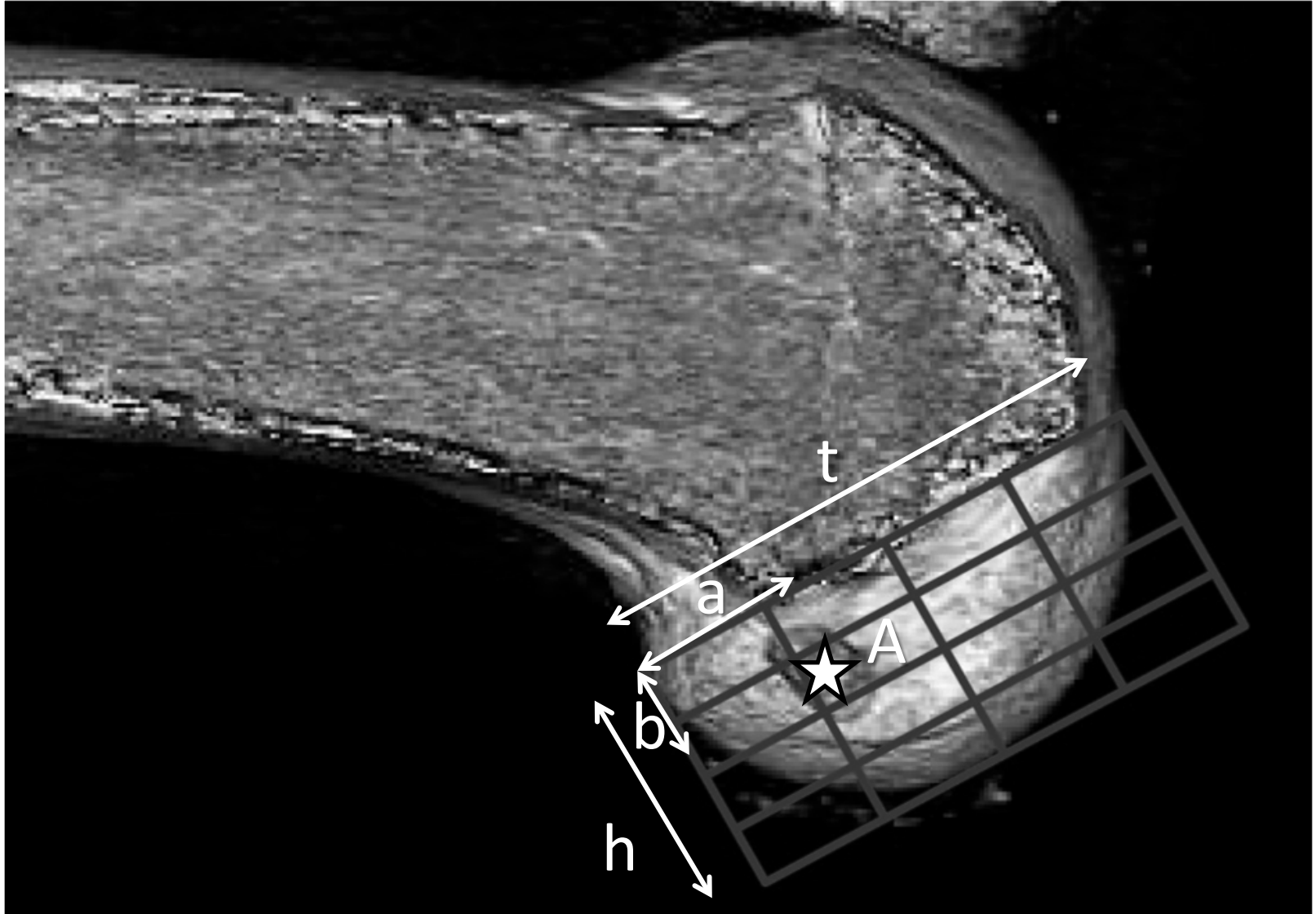


Fig. 5

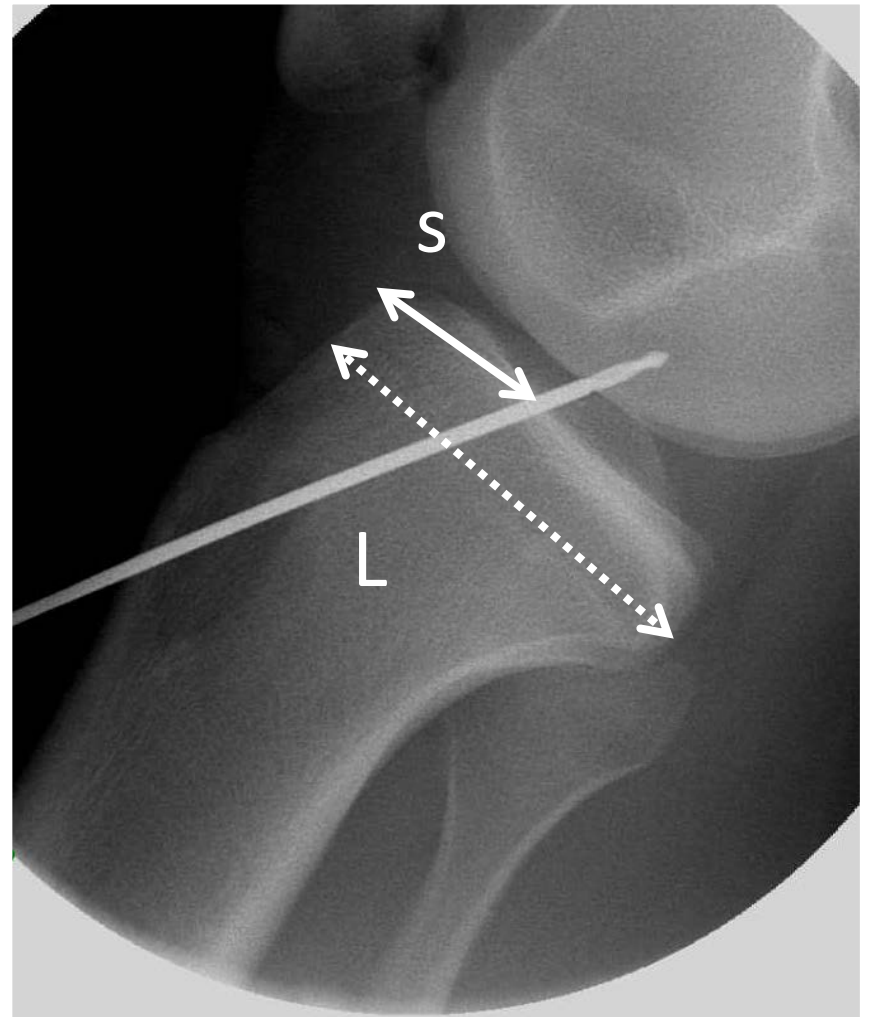
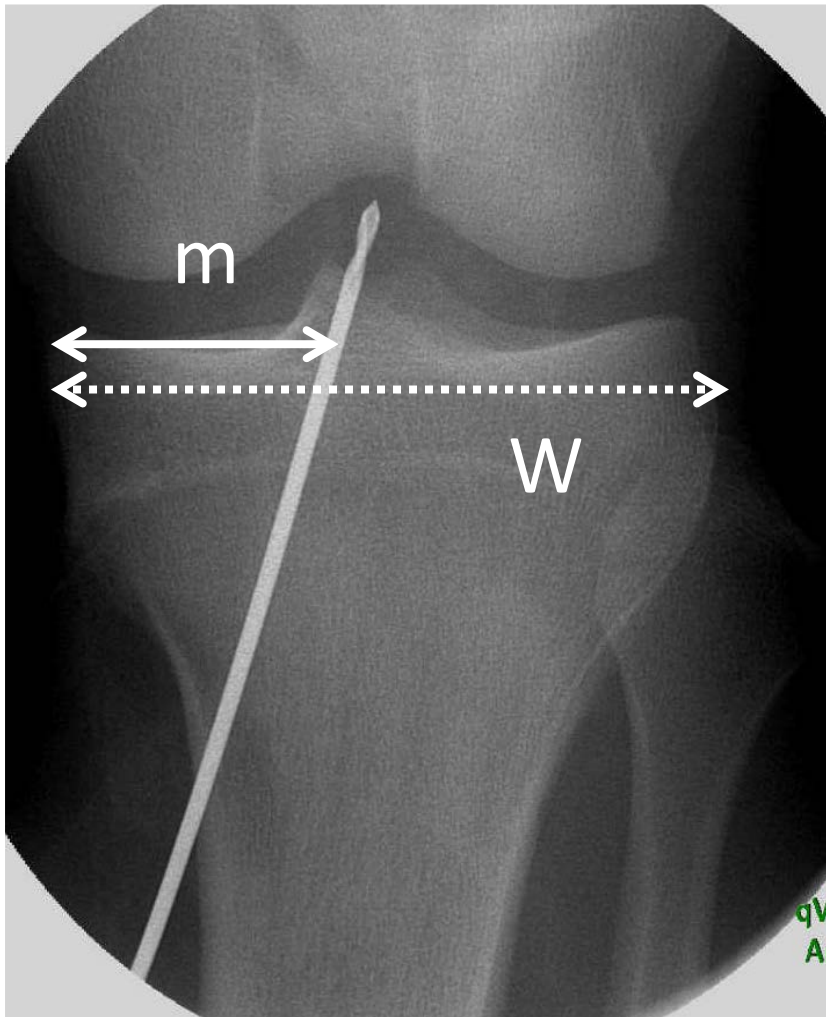


Fig. 6