

# Epstein-Barr virus-associated leukemic lymphoma after allogeneic stem cell transplantation

メタデータ	言語: eng 出版者: 公開日: 2017-10-03 キーワード (Ja): キーワード (En): 作成者: メールアドレス: 所属:
URL	<a href="http://hdl.handle.net/2297/45519">http://hdl.handle.net/2297/45519</a>

Epstein–Barr virus-associated leukemic lymphoma after allogeneic stem cell transplantation

Hiroyuki Takamatsu<sup>1</sup>, Raita Araki<sup>2</sup>, Ryosei Nishimura<sup>2</sup>, Akihiro Yachie<sup>2</sup>, J. Luis Espinoza<sup>1</sup>, Hirokazu Okumura<sup>3</sup>, Takashi Yoshida<sup>3</sup>, Kiyotaka Kuzushima<sup>4</sup> and Shinji Nakao<sup>1</sup>

<sup>1</sup>Cellular Transplantation Biology, Kanazawa University Graduate School of Medical Science, Kanazawa, Japan

<sup>2</sup>Department of Pediatrics, Kanazawa University Graduate School of Medical Science, Kanazawa, Japan

<sup>3</sup>Department of Internal Medicine, Toyama Prefectural Central Hospital, Toyama, Japan

<sup>4</sup> Division of Immunology, Aichi Cancer Center Research Institute, Nagoya, Japan

Corresponding Author: Hiroyuki Takamatsu, MD, PhD

Cellular Transplantation Biology, Kanazawa University Graduate School of Medical Science, 13-1 Takaramachi, Kanazawa, Ishikawa 920-8641, Japan

Telephone: +81-76-265-2276

Fax: +81-76-234-4252

Email: [takamaz@staff.kanazawa-u.ac.jp](mailto:takamaz@staff.kanazawa-u.ac.jp)

Keywords: Epstein-Barr virus, post-transplant lymphoproliferative disease, rituximab, cidofovir, donor lymphocyte infusion

Word count of abstract: 66

Word count of text: 1582

## **ABSTRACT**

Leukemic Epstein–Barr virus (EBV)-associated post-transplant lymphoproliferative diseases (PTLD) following allogeneic hematopoietic stem cell transplantation are extremely rare. We can successfully treat an EBV-associated leukemic lymphoma patient with rituximab, cidofovir, and donor lymphocyte infusion (DLI). In the present case, EBV-specific T cells that were present in the peripheral blood before rituximab administration treatment rapidly increased after DLI in association with a decrease in the EBV-DNA load.

### **1. Why this case is important**

EBV-PTLD following allogeneic hematopoietic stem-cell transplantation presents with serious complications. Among them, leukemic lymphoma is extremely rare but could be fatal, and appropriate treatments are currently unknown. Here we report a successful case of treating EBV-associated leukemic lymphoma with rituximab, cidofovir, and DLI in addition to our previous treatment experience of EBV-associated leukemic lymphoma.

### **2. Case description**

#### **Case 1**

A 34-year-old woman was diagnosed with severe aplastic anemia (AA) in 1997. Although she received anti-thymocyte globulin (ATG) along with cyclosporin (CsA) and androgen therapy, her AA progressed. In 2012, she received an allogeneic bone marrow transplantation (BMT) from an unrelated donor who was an HLA match except

one HLA-DRB1 allele (recipient HLA, A 24:02/33:03, B 48:01/51:01, Cw 08:03/14:02, DRB1\*09:01/09:01; donor HLA, A 24:02/33:03, B 48:01/51:01 Cw 08:03/14:02 DRB1\*09:01/11:01). The conditioning regimen included total-body irradiation (TBI) (2 Gy on day -1), total-lymphoid irradiation (TLI) (3 Gy on day 0), fludarabine (Flu) (30 mg/m<sup>2</sup>/day on days -5, -4, -3, and -2), cyclophosphamide (CY) (25 mg/kg/day on days -5, -4, -3, and -2), and ATG (Thymoglobulin, 2.5 mg/kg/day on day -5 and -4). Prophylaxis for graft-versus-host disease (GVHD) consisted of tacrolimus (from day -1) and short-term methotrexate (5 mg/m<sup>2</sup>/day on days 1, 3, and 6). Both donor and recipient were EBV positive before transplantation. The neutrophil count surpassed 500/ $\mu$ l on day 16 after BMT. She developed a high fever, systemic lymphadenopathy, and hepatosplenomegaly on day 38. The WBC count was 3790/ $\mu$ l with 4% leukemic lymphocytes that were positive for EBV-encoded mRNA, as demonstrated by *in situ* hybridization and donor type cells by chimerism analysis. Flow cytometry (FCM) of peripheral-blood lymphocytes revealed that virtually all B cells expressed CD19<sup>+</sup>, CD20<sup>+</sup> and Ig $\kappa$ . The EBV-DNA copy number was 23970/ml of blood and 48000/ml of serum. EBV clonality was confirmed by Southern blotting using the EBV terminal-repeat probe and an IgH PCR assay. sIL-2R level was 1523 U/ml and anti-EBV antibody titer was as follows: EBV anti-VCA IgG, 80 $\times$ ; EBV anti-VCA IgM, <10 $\times$ ; EBV anti EA-DR IgG, <10 $\times$ ; EBV-anti EBNA, 10 $\times$ . Although a bone-marrow aspiration (BMA) was not performed because of her severe condition on day 38, BMA study showed 11% leukemic lymphocytes in bone marrow on day 40 after rituximab treatment. She was therefore diagnosed as having EBV-associated leukemic lymphoma. Following discontinuation of tacrolimus on day 38, we treated the patient with rituximab (375 mg/m<sup>2</sup>/day on days 38, 42, 47, 54, and 86), cidofovir (5 mg/kg/day on

days 41 and 48), and DLI ( $1 \times 10^6$  CD3<sup>+</sup> cells/kg on day 46), after the approval by the Institutional Review Board of Kanazawa University. No renal impairment was observed after the cidofovir treatment. The blood CD19<sup>+</sup> atypical lymphocyte count decreased to 0/ $\mu$ l on day 48, and her systemic lymphadenopathy resolved. However, the CD8<sup>+</sup> HLA-DR<sup>+</sup> lymphocyte count increased to 10230/ $\mu$ l on day 53. Detection of EBV-specific cytotoxic T cells was performed according to the previous report<sup>1</sup>. The FCM analysis using an HLA-A24 tetramer revealed 1% of the CD8<sup>+</sup> T cells to be EBV-specific cytotoxic T cells, which were markedly increased compared with EBV-specific CD8<sup>+</sup> T cells in pre-BMT blood (0.1%, day -10), post-rituximab treatment blood (0.2%, day 42), and the donor lymphocyte inoculum (0.1%) (Figure 1). Cytomegalovirus (CMV)-specific CD8<sup>+</sup> T cells also increased from 0.1% (pre-transplant) to 1.5% after the DLI. CMV antigenemia that occurred on day 31 was no longer detected after day 56. EBV-DNA in blood decreased from 13860 copies/ml on day 45, to 203 copies/ml on day 52, 204 copies/ml on day 95, and became undetectable on day 116. Grade I (skin stage 1) acute GVHD developed 6 days after DLI but was remitted without additional treatments. No signs of chronic GVHD were observed. Although there is persistent B-cell lymphocytopenia (60–120/ $\mu$ l) with hypogammaglobulinemia (IgG levels 220–470 mg/dl), the patient is alive without relapse of either EBV-PTLD or AA as of September, 2015.

## Case 2

An 18-year-old man was diagnosed with severe B-cell acute lymphoblastic leukemia (B-ALL) in 2007. Although induction chemotherapy according to the JALSG-ALL202U protocol<sup>2</sup> induced a CR, his ALL relapsed during the maintenance

chemotherapy in 2008. A reinduction chemotherapy that consisted of high-dose cytarabine ( $4 \text{ g/m}^2/\text{day} \times 3 \text{ days}$ ), pirarubicin ( $40 \text{ mg/m}^2/\text{day} \times 5 \text{ days}$ ), and etoposide ( $100 \text{ mg/m}^2/\text{day} \times 5 \text{ days}$ ) failed to induce a CR. Because no HLA fully-matched donors were found from either relatives or the Japanese marrow donor program (JMDP), he received an allogeneic peripheral-blood stem-cell transplantation (PBSCT) from his 46-year-old mother who was HLA-two loci mismatched (recipient HLA, A 02:07/11:01, B 46:01/52:01, DRB1\*01:01/09:01; donor HLA, A 02:07/11:01, B 40:01/46:01, DRB1\*09:01/14:05). The conditioning regimen consisted of etoposide ( $30 \text{ mg/m}^2/\text{day}$  on days  $-9$  and  $-8$ ), busulphan ( $3.2 \text{ mg/kg/day}$  on days  $-7$  and  $-6$ ), melphalan ( $70 \text{ mg/m}^2/\text{day}$  on days  $-5$  and  $-4$ ), TBI ( $1 \text{ Gy/day}$  on days  $-4$  and  $-3$ ), and ATG (Thymoglobulin,  $2.5 \text{ mg/kg/day}$  on days  $-3$  and  $-2$ ). Prophylaxis for GVHD consisted of tacrolimus (from day  $-1$ ) and methylprednisolone ( $40 \text{ mg/day}$ , from day 1). The recipient was pre-transplant EBV positive. The neutrophil count surpassed  $500/\mu\text{l}$  on day 10 after PBSCT and the complete hematopoietic donor chimerism was confirmed on day 24. On day 49, atypical lymphocytes ( $118/\mu\text{l}$ , 2% of WBC  $5900/\mu\text{l}$ ) appeared in the peripheral blood. On day 53 he developed a persistent high fever, systemic lymphadenopathy, and splenomegaly; the WBC count was  $2100/\mu\text{l}$  with 11% atypical lymphocytes and chimerism analysis revealed that they were donor type cells. A bone-marrow study was not performed because of his severe condition. The clonality of  $\text{CD19}^+/\text{CD20}^+$  cells of his peripheral blood was confirmed by the predominant Igk expression using FCM. The EBV-DNA copy number was 600,000/ml of blood. He was diagnosed to have EBV-associated leukemic lymphoma, and was treated with DLI on day 53 ( $5 \times 10^5 \text{ CD3}^+ \text{ cells/kg}$ ) and on day 58 ( $1 \times 10^6 \text{ CD3}^+ \text{ cells/kg}$ ) in addition to rituximab ( $375 \text{ mg/m}^2$  on day 57). Tacrolimus was discontinued from day 55. Despite

these treatments, the number of atypical lymphocytes increased to 4082/ $\mu$ l accounting for 13% of WBC. FCM of peripheral blood on day 59 revealed no CD19<sup>+</sup>/CD20<sup>+</sup> cells and an increase in the CD8<sup>+</sup> cell count to 8095/ $\mu$ l. His liver and renal injuries deteriorated and he died of multiple organ failure on day 59. Any symptoms of GVHD were not observed during his clinical course.

### **3. Other similar and contrasting cases in the literature**

Comoli et al reported four cases of CD20<sup>-</sup>/CD19<sup>+</sup> B cells in peripheral blood, accompanied by overt PTLT in 3 patients after haploidentical stem-cell transplantation. The latter cleared PTLT after receiving donor EBV-specific cytotoxic T lymphocytes (CTLs), and persist in remission at a median 30-month follow-up<sup>3</sup>.

### **4. Discussion**

EBV-PTLT is rare, but is considered to be one of the most serious complications after allogeneic stem-cell transplantation. The fatality rate of EBV-PTLT has been reported to be 50%–92%<sup>4-7</sup>. Before the rituximab era, unmanipulated DLI was the only effective treatment for EBV-PTLT, although DLI was not potent enough to cure EBV-PTLT and often induced severe GVHD. The effect of DLI is believed to be mediated by T cells specific to EBV specific epitopes such as EBV-BMLF1, EBV-BRLF1, and EBV-EBNA3A<sup>8</sup>. Although Comoli et al showed that EBV-specific T-cell frequency was restored by EBV-specific CTLs therapy for EBV-PTLT to levels comparable with controls, they evaluated EBV-specific T-cell frequency indirectly using IFN- $\gamma$  secretion from lymphocytes by ELISPOT assay or flow cytometry<sup>3</sup>. This is, to our knowledge, the first report to confirm the increase of EBV-specific cytotoxic T cells

using EBV-tetramers after DLI and rituximab treatment directly. Muramatsu et al reported that EBV-tetramer-positive CD8<sup>+</sup> cells were detected in the peripheral blood of a patient after radiation and rituximab treatment for EBV-PTLD<sup>9</sup>. In our case, EBV-specific T cells that had been present in the peripheral blood before rituximab treatment rapidly increased after DLI in association with a decrease in the EBV-DNA load. This clinical course clearly shows that EBV-specific T cells played a substantial role in eradicating EBV-PTLD.

We experienced four leukemic EBV-PTLD cases (0.5%) among the 797 who received allogeneic stem-cell transplantation (alloSCT) from 1991 to 2013 at our institutes<sup>10, 11</sup> (Table 1). All four patients received ATG-conditioning regimens and it is well known that these regimens induce EBV diseases post-alloSCT due to the level of immunosuppression<sup>12</sup>. Patriarca et al demonstrated that CD4<sup>+</sup> T-cell counts <50/ $\mu$ l at day +30 post-alloSCT were significantly associated with an increased risk of high-load EBV-DNAemia (>10000 copies/ml) in alloSCT patients in whom 68% received ATG in their conditioning regimen<sup>13</sup>. Our case 1 patient's CD4<sup>+</sup> T-cell counts were also < 50/ $\mu$ l at day +30 post-alloSCT. Two of the four patients with leukemic EBV-PTLD were treated with DLI or DLI plus rituximab but did not show treatment response; both died due to progressive disease. In the latter case (Case 2) the delayed rituximab administration might have been the cause of the progressive disease. Because monotherapy with rituximab is reported to rescue 63% patients with PTLD<sup>14</sup>, we expected that rituximab therapy would not be able to cure a fulminant EBV-PTLD as seen in our case even in combination with DLI. Cidofovir, a monophosphate nucleotide analogue of cytosine that inhibits viral DNA polymerase, is effective in treating various kinds of viral infections due to adenovirus<sup>15</sup>, BK virus<sup>16</sup>, and EBV<sup>17-19</sup>. Although the



addition of cidofovir to rituximab-DLI therapy may have helped the patient to overcome such a disastrous condition without obvious adverse effects, there is little evidence to suggest therapeutic efficacy against EBV<sup>14, 20</sup>. It is therefore reasonable to consider EBV-CTL therapy if available to patients who progress under rituximab treatment and DLI<sup>20</sup>.

### **Acknowledgements**

We would like to thank Dr Yoshiyuki Takahashi of Nagoya University for detecting EBV-specific T-cells and Dr Hiroyasu Ogawa of Hyogo College of Medicine for providing us cidofovir. We would also like to express our gratitude to Drs Akiyo Yoshida, Yoshihisa Kumano, Jun Ozaki, and Toshiro Kurokawa of Toyama Prefectural Central Hospital for patients' clinical information.

### **Funding**

None.

### **Competing interests**

None declared.

### **Ethical approval**

Not required.

### **Contributors**

Hiroyuki Takamatsu and Shinji Nakao managed the patient and wrote the manuscript.

Raita Araki, Ryosei Nishimura, Akihiro Yachie and Kiyotaka Kuzushima performed the detection of EBV-specific cytotoxic T-cells, critically revised and finalized the manuscript. J. Luis Espinoza performed the detection of EBV-DNA, critically revised and finalized the manuscript. Hirokazu Okumura and Takashi Yoshida managed the patient, critically revised and finalized the manuscript.

## References

1. Sugaya N, Kimura H, Hara S, Hoshino Y, Kojima S, Morishima T, et al. Quantitative analysis of Epstein-Barr virus (EBV)-specific CD8+ T cells in patients with chronic active EBV infection. *The Journal of infectious diseases*. 2004;190:985-8.
2. Hayakawa F, Sakura T, Yujiri T, Kondo E, Fujimaki K, Sasaki O, et al. Markedly improved outcomes and acceptable toxicity in adolescents and young adults with acute lymphoblastic leukemia following treatment with a pediatric protocol: a phase II study by the Japan Adult Leukemia Study Group. *Blood cancer journal*. 2014;4:e252.
3. Comoli P, Basso S, Zecca M, Pagliara D, Baldanti F, Bernardo ME, et al. Preemptive therapy of EBV-related lymphoproliferative disease after pediatric haploidentical stem cell transplantation. *American journal of transplantation : official journal of the American Society of Transplantation and the American Society of Transplant Surgeons*. 2007;7:1648-55.
4. Ocheni S, Kroeger N, Zabelina T, Sobottka I, Ayuk F, Wolschke C, et al. EBV reactivation and post transplant lymphoproliferative disorders following allogeneic SCT. *Bone marrow transplantation*. 2008;42:181-6.
5. Markasz L, Stuber G, Flaberg E, Jernberg AG, Eksborg S, Olah E, et al. Cytotoxic drug sensitivity of Epstein-Barr virus transformed lymphoblastoid B-cells. *BMC cancer*. 2006;6:265.
6. Bower M. The management of lymphoma in the immunosuppressed patient. *Best practice & research Clinical haematology*. 2002;15:517-32.
7. Sanz J, Arango M, Senent L, Jarque I, Montesinos P, Sempere A, et al. EBV-associated post-transplant lymphoproliferative disorder after umbilical cord blood transplantation in adults with hematological diseases. *Bone marrow transplantation*. 2014;49:397-402.
8. Kuzushima K, Hayashi N, Kudoh A, Akatsuka Y, Tsujimura K, Morishima Y, et al. Tetramer-assisted identification and characterization of epitopes recognized by HLA A\*2402-restricted Epstein-Barr virus-specific CD8+ T cells. *Blood*. 2003;101:1460-8.
9. Muramatsu H, Takahashi Y, Shimoyama Y, Doisaki S, Nishio N, Ito Y, et al. CD20-negative Epstein-Barr virus-associated post-transplant lymphoproliferative disease refractory to rituximab in a patient with severe aplastic anemia. *International journal of hematology*. 2011;93:779-81.
10. Sugimori N, Nakao S, Takamatsu H, Takami A, Ueda M, Shiobara S, et al. -Rejection of an allogeneic bone marrow graft following successful treatment of severe graft-versus-host disease (GVHD). [Rinsho ketsueki] *The Japanese journal of clinical hematology*. 1996;37:134-8.
11. Chuhjo T, Yachie A, Kanegane H, Kimura H, Shiobara S, Nakao S. Epstein-Barr virus (EBV)-associated post-transplantation lymphoproliferative disorder simultaneously affecting both B and T cells after allogeneic bone marrow transplantation. *American journal of hematology*. 2003;72:255-8.

12. Rouse RH, Louis CU, Heslop HE. Epstein-Barr virus lymphoproliferative disease after hematopoietic stem cell transplant. *Current opinion in hematology*. 2014;21:476-81.
13. Patriarca F, Medeot M, Isola M, Battista ML, Sperotto A, Pipan C, et al. Prognostic factors and outcome of Epstein-Barr virus DNAemia in high-risk recipients of allogeneic stem cell transplantation treated with preemptive rituximab. *Transplant infectious disease : an official journal of the Transplantation Society*. 2013;15:259-67.
14. Styczynski J, Einsele H, Gil L, Ljungman P. Outcome of treatment of Epstein-Barr virus-related post-transplant lymphoproliferative disorder in hematopoietic stem cell recipients: a comprehensive review of reported cases. *Transplant infectious disease : an official journal of the Transplantation Society*. 2009;11:383-92.
15. Lugthart G, Oomen MA, Jol-van der Zijde CM, Ball LM, Bresters D, Kollen WJ, et al. The effect of cidofovir on adenovirus plasma DNA levels in stem cell transplantation recipients without T cell reconstitution. *Biology of blood and marrow transplantation : journal of the American Society for Blood and Marrow Transplantation*. 2015;21:293-9.
16. Rascon J, Verkauskas G, Pasauliene R, Zubka V, Bilius V, Rageliene L. Intravesical cidofovir to treat BK virus-associated hemorrhagic cystitis in children after hematopoietic stem cell transplantation. *Pediatric transplantation*. 2015;19:E111-4.
17. Meerbach A, Wutzler P, Hafer R, Zintl F, Gruhn B. Monitoring of Epstein-Barr virus load after hematopoietic stem cell transplantation for early intervention in post-transplant lymphoproliferative disease. *Journal of medical virology*. 2008;80:441-54.
18. Nozzoli C, Bartolozzi B, Guidi S, Orsi A, Vannucchi AM, Leoni F, et al. Epstein-Barr virus-associated post-transplant lymphoproliferative disease with central nervous system involvement after unrelated allogeneic hematopoietic stem cell transplantation. *Leukemia & lymphoma*. 2006;47:167-9.
19. Hanel M, Fiedler F, Thorns C. Anti-CD20 monoclonal antibody (Rituximab) and Cidofovir as successful treatment of an EBV-associated lymphoma with CNS involvement. *Onkologie*. 2001;24:491-4.
20. Heslop HE. How I treat EBV lymphoproliferation. *Blood*. 2009;114:4002-8.

## Figure legend

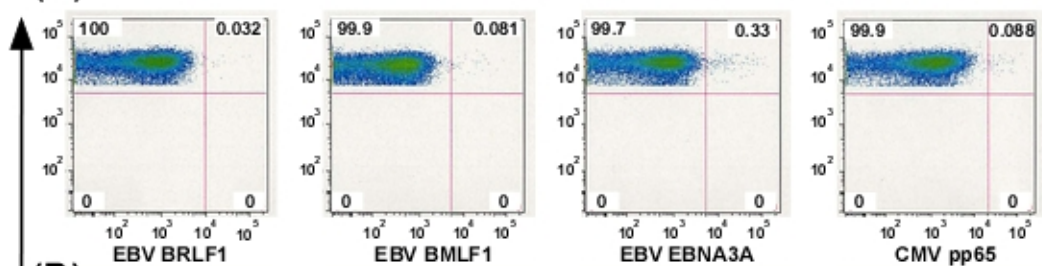
Analysis of EBV specific CD8<sup>+</sup> T cells in peripheral blood. Before bone marrow transplant (day -10) (A), donor lymphocytes inoculum (B), post-rituximab treatment (day 42) (C) and post- DLI (day 53) (D). EBV: Epstein-Barr virus, CMV: cytomegalovirus, DLI: donor lymphocyte infusion

Table 1. Outcome and treatments of the patients with leukemic EBV-PTLD																	
Case	Year of allo- SCT	Age at allo- SCT	Sex	Diagnosis	Conditioning	Stem cell source	Donor	Viral load at onset	Atypical lymphocyte counts at onset (/μl)	Treatments of EBV-PTLD	Acute GVHD	Chronic GVHD	Survival post- leukemic EBV- PTLD (days)	Survival post- allo-SCT (days)	Outcome	Cause of death	Reference
1	2012	34	Female	AA	Flu+CY+ATG+TLI+TBI	BM	MMURD (1 HLA-DR mismatch)	2.4x10 <sup>4</sup> copies/ml of blood	150	Rituximab, DLI, cidofovir	Grade I (skin)	None	1264+	1302+	Alive	NA	Our case
2	2008	18	Male	B-ALL	Mel+iBu+ETP +ATG+TBI	PB	MMRD (1 HLA- B, 1 HLA-DR mismatch)	6x10 <sup>5</sup> copies/ml of blood	230	Rituximab, DLI	None	NA	6	59	Dead	Progression of PTLD	Our case
3	1998	31	Male	AA	CY+ATG+TBI	BM	MMURD (1 HLA-DR mismatch)	1.4x10 <sup>6</sup> copies/μg of DNA	15800	DLI	None	NA	11	56	Dead	Progression of PTLD	(11)
4	1992	38	Female	AML (M2)	CY+Bu→mPSL+ATG	BM	MMRD (1 HLA- DR mismatch)	Not assessed	1800	None	None	NA	8	19	Dead	Development of PTLD, fungal sepsis	(10)

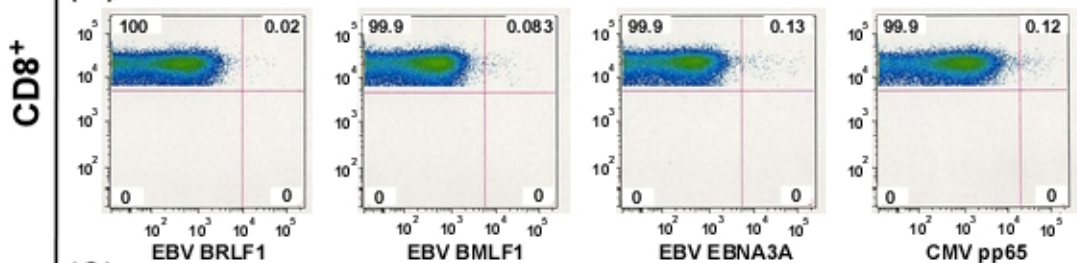
EBV-PTLD: Epstein-Barr virus-associated post-transplant lymphoproliferative diseases, allo-SCT: allogeneic stem cell transplantation, AA: aplastic anemia, B-ALL: B-cell acute lymphoblastic leukemia, AML: acute myeloid leukemia, Flu: fludarabine, CY: cyclophosphamide, ATG: anti-thymocyte globulin, TLI: total lymphoid irradiation, TBI: total body irradiation, Mel: melphalan, iBu: intravenous busulfan, ETP: etoposide, Bu: oral busulfan, mPSL: methylprednisolone, BM: bone marrow, PB: peripheral blood, MMURD: mismatched unrelated donor, MMRD: mismatched related donor, DLI: donor lymphocyte infusion, GVHD: graft-versus-host disease, NA: not applicable.

Figure 1

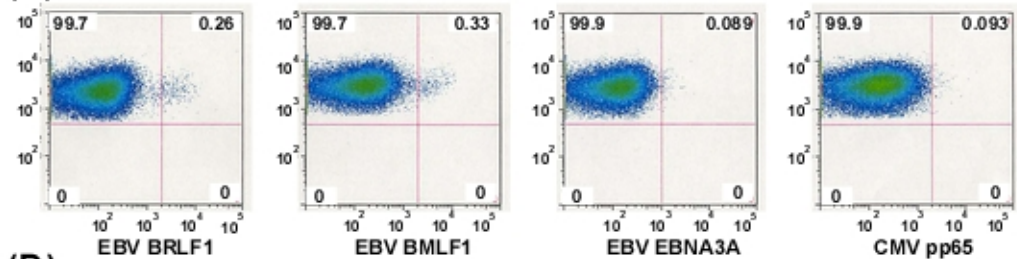
(A)



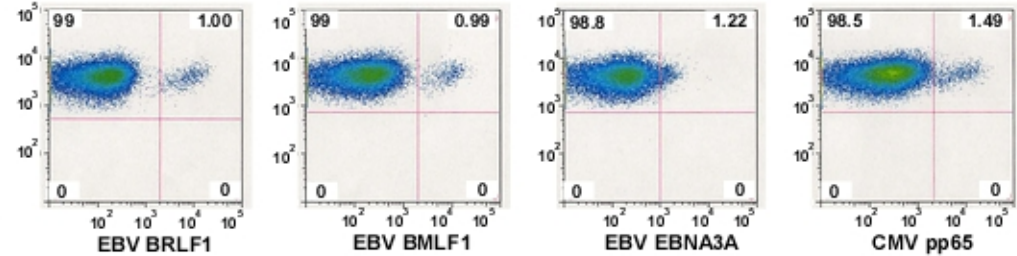
(B)



(C)



(D)



HLA-A\*2402 Tetramer