

Tracheoesophageal Fistula After Long-term Intubation.

メタデータ	言語: eng 出版者: 公開日: 2017-10-03 キーワード (Ja): キーワード (En): 作成者: メールアドレス: 所属:
URL	http://hdl.handle.net/2297/48443

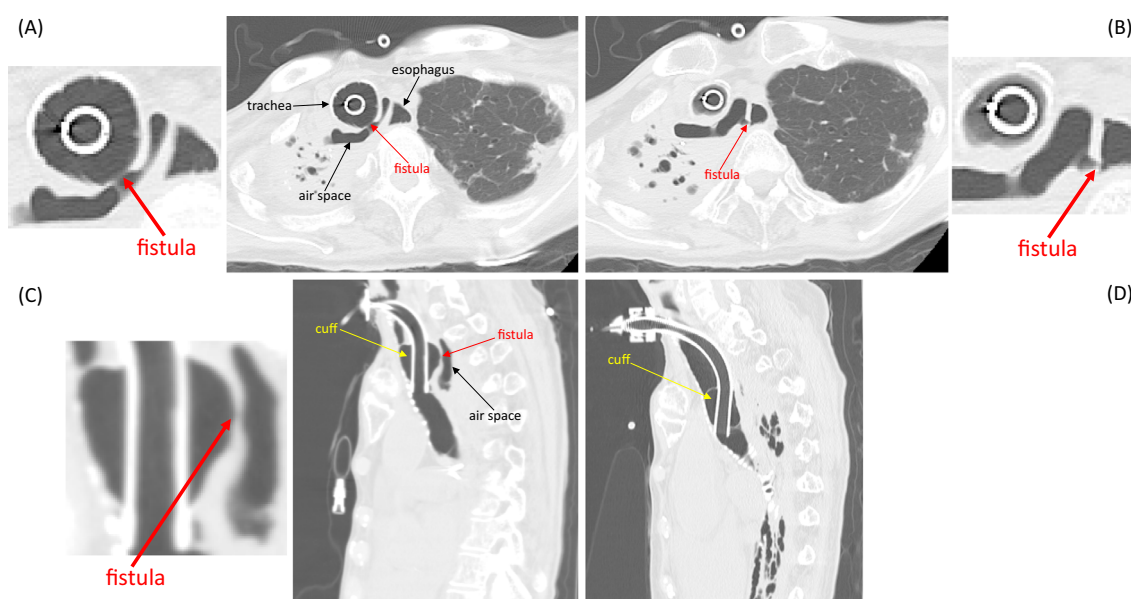
Tracheoesophageal Fistula After Long-term Intubation

Kotaro Oe¹, Tsutomu Araki¹, Kenshi Hayashi² and Masakazu Yamagishi²

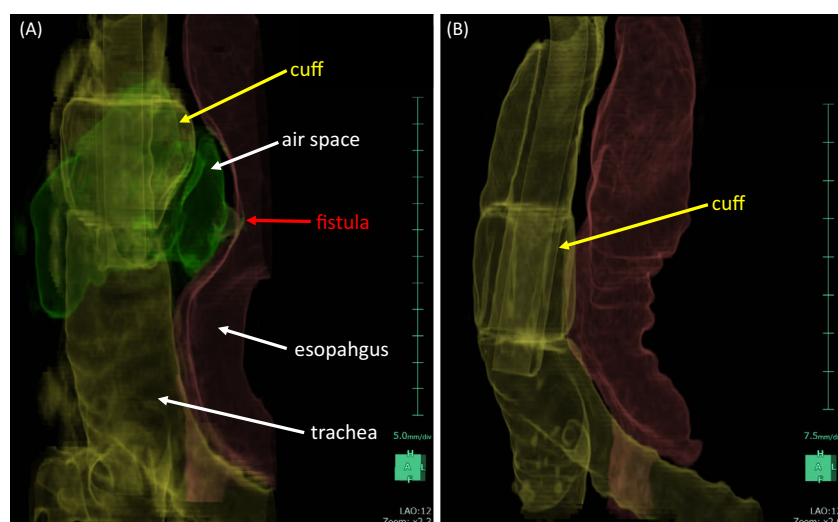
Key words: tracheoesophageal fistula, conservative treatment

(Intern Med 56: 381-382, 2017)

(DOI: 10.2169/internalmedicine.56.7524)



Picture 1.



Picture 2.

¹Division of Internal Medicine, Saiseikai Kanazawa Hospital, Japan and ²Department of Cardiovascular and Internal Medicine, Kanazawa University Graduate School of Medicine, Japan

Received for publication April 5, 2016; Accepted for publication June 19, 2016

Correspondence to Dr. Kotaro Oe, kotaroe316@yahoo.co.jp

A 71-year-old woman was admitted due to respiratory failure following right lower lobectomy for lung cancer. She was intubated, and tracheostomy was performed. At six months after tracheostomy, abdominal distension appeared, and an X-ray showed air retention in the bowels. Computed tomography revealed spaces of air behind the cuff, a fistula between the trachea and air spaces (Picture 1A and C), and a fistula between the air spaces and the esophagus (Picture 1B, 2A) (Picture 1A and B: axial images, Picture 1C and D: sagittal images, Picture 2: three-dimensional reconstruction images). The patient was diagnosed with tracheoesophageal fistula (TEF). Surgical repair could not be performed due to her poor general status. The endotracheal tube was exchanged for a longer type so that the cuff was positioned below the fistula (Picture 1D). The air retention in the bowels resolved, and the TEF disappeared (Picture 2B). TEF did not recur during the follow-up period. TEF is a rare but serious complication in patients with prolonged tracheal intubation (1), and a proper-size endotra-

cheal tube and frequent cuff pressure monitoring are needed to prevent its occurrence. Surgical repair should therefore be considered, but conservative treatment may be adequate in high-risk patients (2).

The authors state that they have no Conflict of Interest (COI).

References

1. Paraschiv M. Tracheoesophageal fistula - a complication of prolonged tracheal intubation. *J Med Life* 7: 516-521, 2014.
2. Lin WY, Chiu YC. Complete healing of tracheoesophageal fistula in a ventilator-dependent patient by conservative treatment. *Respirol Case Rep* 2: 27-29, 2014.

The Internal Medicine is an Open Access article distributed under the Creative Commons Attribution-NonCommercial-NoDerivatives 4.0 International License. To view the details of this license, please visit (<https://creativecommons.org/licenses/by-nc-nd/4.0/>).