

Effects of radiation on spinal dura mater and surrounding tissue in mice

メタデータ	言語: eng 出版者: 公開日: 2017-10-03 キーワード (Ja): キーワード (En): 作成者: メールアドレス: 所属:
URL	http://hdl.handle.net/2297/46421

RESEARCH ARTICLE

Effects of Radiation on Spinal Dura Mater and Surrounding Tissue in Mice

Noriaki Yokogawa^{1*}, Hideki Murakami¹, Satoru Demura¹, Satoshi Kato¹, Katsuhito Yoshioka¹, Miyuki Yamamoto², Shoichi Iseki², Hiroyuki Tsuchiya¹

1 Department of Orthopaedic Surgery, Graduate School of Medical Science, Kanazawa University, 13–1 Takara-machi, Kanazawa, 920–8641, Japan, **2** Department of Histology and Embryology, Graduate School of Medical Science, Kanazawa University, 13–1 Takara-machi, Kanazawa, 920–8641, Japan

* chakkun1981chakkun@yahoo.co.jp



OPEN ACCESS

Citation: Yokogawa N, Murakami H, Demura S, Kato S, Yoshioka K, Yamamoto M, et al. (2015) Effects of Radiation on Spinal Dura Mater and Surrounding Tissue in Mice. PLoS ONE 10(7): e0133806. doi:10.1371/journal.pone.0133806

Editor: Utpal Sen, University of Louisville, UNITED STATES

Received: April 23, 2015

Accepted: July 1, 2015

Published: July 27, 2015

Copyright: © 2015 Yokogawa et al. This is an open access article distributed under the terms of the [Creative Commons Attribution License](https://creativecommons.org/licenses/by/4.0/), which permits unrestricted use, distribution, and reproduction in any medium, provided the original author and source are credited.

Data Availability Statement: All relevant data are within the paper and its Supporting Information files.

Funding: This study was supported by JSPS KAKENHI Grant No. 26462233 to H.M. and N.Y., and a grant-in-aid for research from the Radiation Effects Association to N.Y. The funders had no role in the study design, data collection and analysis, decision to publish, or preparation of the manuscript.

Competing Interests: The authors have declared that no competing interests exist.

Abstract

Purpose

Spinal surgery in a previously irradiated field carries increased risk of perioperative complications, such as delayed wound healing or wound infection. In addition, adhesion around the dura mater is often observed clinically. Therefore, similar to radiation-induced fibrosis—a major late-stage radiation injury in other tissue—epidural fibrosis is anticipated to occur after spinal radiation. In this study, we performed histopathologic assessment of postirradiation changes in the spinal dura mater and peridural tissue in mice.

Materials and Methods

The thoracolumbar transition of ddY mice was irradiated with a single dose of 10 or 20 Gy. After resection of the irradiated spine, occurrence of epidural fibrosis and expression of transforming growth factor beta 1 in the spinal dura mater were evaluated. In addition, microstructures in the spinal dura mater and peridural tissue were assessed using an electron microscope.

Results

In the 20-Gy irradiated mice, epidural fibrosis first occurred around 12 weeks postirradiation, and was observed in all cases from 16 weeks postirradiation. In contrast, epidural fibrosis was not observed in the nonirradiated mice. Compared with the nonirradiated mice, the 10- and 20-Gy irradiated mice had significantly more overexpression of transforming growth factor beta 1 at 1 week postirradiation and in the late stages after irradiation. In microstructural assessment, the arachnoid barrier cell layer was thinned at 12 and 24 weeks postirradiation compared with that in the nonirradiated mice.

Conclusion

In mice, spinal epidural fibrosis develops in the late stages after high-dose irradiation, and overexpression of transforming growth factor beta 1 occurs in a manner similar to that seen in radiation-induced fibrosis in other tissue. Additionally, thinning of the arachnoid barrier

cell layer was observed in the late stages after irradiation. Thus, consideration should be given to the possibility that these phenomena can occur as radiation-induced injuries of the spine.

Introduction

Radiotherapy has been widely used for spinal metastases [1, 2], and is often performed as palliative treatment to improve patient quality of life by alleviating pain, mitigating nerve compression symptoms, and decreasing the likelihood of pathological bone fracture through local tumor control [3–5]. Until recently, presence of spinal metastases was regarded as an end-stage state; however, recent advances in multidisciplinary treatments for various cancers have led to an increase in the number of cases with a longer-term prognosis. Therefore, full consideration must be given to adverse events associated with radiotherapy, especially late-stage radiation injury in long-term survivors. Currently, effective treatments for late-stage radiation injury are lacking, and such injuries may develop into life-threatening complications [6, 7].

Recurrence of pain and nerve compression due to local tumor relapse after radiotherapy is a problem for long-term survivors of spinal metastases. Surgical treatment is often selected in these cases because repeat irradiation bears the risk of radiation myelopathy [8, 9]. However, late-stage radiation injury is associated with perioperative complications, such as delayed wound healing or wound infection [10, 11]. In addition, research at our facility has indicated that dural injury and postoperative cerebrospinal fluid (CSF) leakage, probably due to adhesion around the dura mater, are frequently observed during surgery for spinal tumors after radiotherapy [12]. Therefore, similar to radiation-induced fibrosis—a major late-stage radiation injury in other tissue [13–15]—epidural fibrosis is anticipated to precede dural injury in the spine; however, this has not yet been investigated. In this study, we performed histopathologic assessment of temporal changes in the spinal dura mater and peridural tissue following irradiation in mice, with a focus on epidural fibrosis.

Materials and Methods

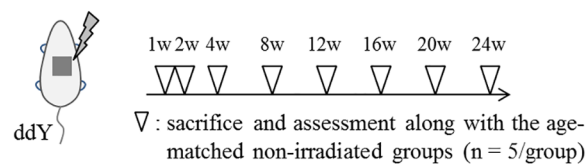
Study design

This study was conducted with approval from the Committee of Animal Care and Experimentation at Kanazawa University (Kanazawa, Japan, AP-122282). All surgeries were performed under sodium pentobarbital anesthesia, and all efforts were made to minimize suffering. Fig 1 shows the experimental protocol. Ten-week-old ddY mice (body mass, 30–32 g) purchased from Japan SLC (Shizuoka, Japan) were randomly allocated into irradiated and nonirradiated groups. The irradiated groups received a single external irradiation dose of 10 or 20 Gy at 150 kV and 20 mA to the thoracolumbar transition using an X-ray irradiation device for small animals (HITACHI MBR-1520R-3, Tokyo, Japan). X-ray irradiation was beamed through 0.5-mm aluminum and 0.5-mm copper filters. After general anesthesia by intraperitoneal administration of pentobarbital (50 mg/kg), the mice were immobilized in the lateral decubitus position and then irradiated under a lead plate containing 20 × 20-mm openings to irradiate the thoracolumbar transition alone. Control mice underwent sham procedures that involved the same anesthesia administration but no irradiation.

Five mice per radiation dose and time point were sacrificed by intraperitoneal administration of pentobarbital (150 mg/kg) at 1, 2, 4, 8, 12, 16, 20, and 24 weeks after irradiation, and perfused with 4% paraformaldehyde buffer solution. Subsequent en-bloc excision of the

1) Histological and immunohistochemical assessment

10 Gy or 20 Gy irradiation
to thoracolumbar transition



2) Microstructural assessment

20 Gy irradiation to
thoracolumbar transition

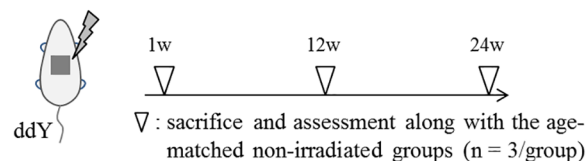


Fig 1. Experimental protocol.

doi:10.1371/journal.pone.0133806.g001

irradiated spines was performed. Interlaminar horizontal sections of the resected specimens were histologically and immunohistochemically assessed along with the age-matched nonirradiated specimens (n = 5/time point) using a BZ-9000 microscope (Keyence, Osaka, Japan).

Additional 3 mice each were sacrificed at 1, 12, and 24 weeks after irradiation with 20 Gy, and perfused with 4% paraformaldehyde buffer solution. The excised spines were placed in fixative for electron microscopy analysis along with the age-matched nonirradiated specimens (n = 3/time point).

Histologic assessment

For histologic assessment, the excised specimens were fixed in Tissue-Tek UFIX (Sakura Fine-tek Japan, Tokyo, Japan) for 3 days, and decalcified with formic acid for 1 week. Then, the specimens were embedded in paraffin and cut into 2- μ m sections for Masson's trichrome staining. Two blinded observers independently scored the epidural fibrosis in accordance with a modified postlaminectomy scar formation score from 0 (no fibrous tissue) to 3 (severe fibrosis) (Table 1) [16]. The mean value of 2 interlaminar sections from each specimen was considered as the mean fibrosis score. Fig 2 shows the representative histology of each grade.

Table 1. Criteria for grading epidural fibrosis.

Grade	Histologic features
0	No fibrous tissue
1	Only thin fibrous bands are observed in the epidural space
2	Continuous fibrosis is observed, but it affects less than two-thirds of the epidural space
3	Fibrosis is large, affecting more than two-thirds of the epidural space, and/or fibrosis extends to the nerve roots

doi:10.1371/journal.pone.0133806.t001

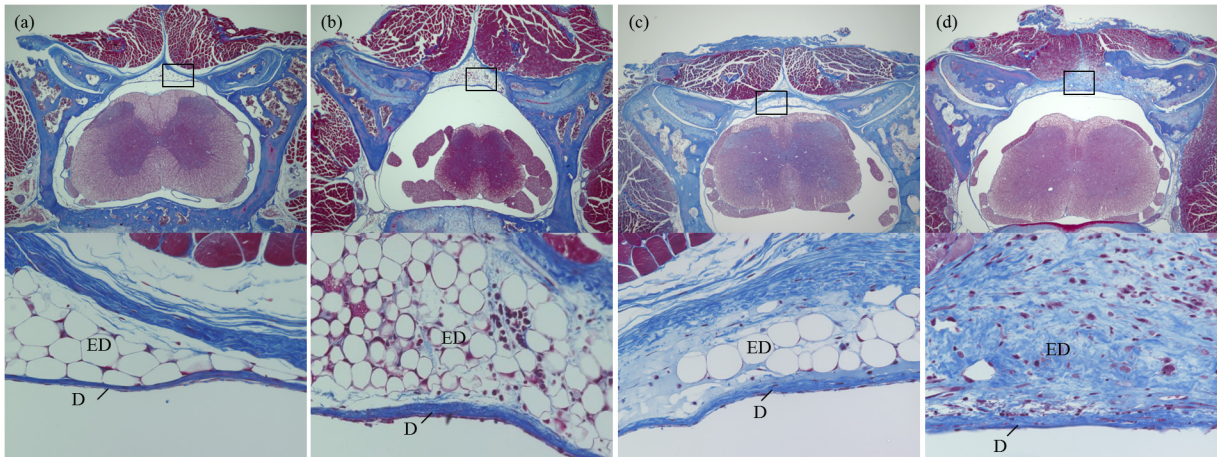


Fig 2. Representative histologic features of radiation-induced epidural fibrosis. (a) Grade 0, no fibrosis. (b) Grade 1, minimum fibrosis. (c) Grade 2, moderate fibrosis. (d) Grade 3, severe fibrosis. (Masson's trichrome stain; above, magnification $\times 40$; below, magnification $\times 400$ objective). Abbreviations: D, dura mater; ED, epidural space.

doi:10.1371/journal.pone.0133806.g002

Immunohistochemical staining

Immunohistochemical staining for TGF- $\beta 1$, which is thought to play a central role in fibrosis formation [17, 18], was performed to assess temporal expression in the dura mater. Sections (2- μm) of paraffin-embedded murine spine were cut, then deparaffinized in xylene and rehydrated via a graded ethanol series. Then, the sections were placed in an antigen-retrieval solution (L.A.B. Solution; PolySciences, Inc., Warrington, PA, USA) for 15 min at room temperature. After rinsing with deionized water, a peroxide-blocking reagent (0.3% hydrogen peroxide) was applied for 10 min at room temperature. After incubation in 5% bovine serum albumin in phosphate-buffered saline (PBS) for 10 min at room temperature, primary anti-TGF- $\beta 1$ rabbit polyclonal antibody raised against the C-terminus of TGF- $\beta 1$ of human origin (sc-146; Santa Cruz Biotechnology, Santa Cruz, CA, USA; 1:300 dilution in PBS; previous validation in [19]) was applied overnight in a humidified chamber at 4°C. Then, the slides were washed in PBS and incubated in the secondary antibody (biotin goat antirabbit Ig, 550358; BD Biosciences, San Jose, CA, USA) for 30 min at room temperature. The slides were then incubated with a streptavidin-horseradish peroxidase (550946; BD Biosciences) for 30 min at room temperature. After rinsing with PBS, peroxidase activity was visualized with 3, 3'-diaminobenzidine staining. Subsequently, the slides were washed 3 times for 10 min each in deionized water and counterstained with Mayer's hematoxylin. As a negative control, primary antibodies were omitted. The rate of TGF- $\beta 1$ -positive cells was graded into 4 easily reproducible subcategories according to the frequency of positively stained cells as a percentage of total cell count: grade 0, no positive cells; grade 1, <30% of cells were positive; grade 2, 30%–59% of cells were positive; and grade 3, $\geq 60\%$ of cells were positive. Fig 3 shows the representative histology of each grade. As with the histologic assessment, 2 blinded observers performed the scoring, and the mean value of 2 interlaminar sections for each specimen was taken as the mean positive TGF- $\beta 1$ score.

Assessment of microstructure using electron microscopy

For electron microscopy assessment, the excised specimens were fixed by immersion in 4% paraformaldehyde buffer solution for 4 h at 4°C, and subsequently decalcified in ethylenediaminetetraacetic acid for 3 to 4 days at 4°C. The tissue blocks were cut into 20- μm sections,

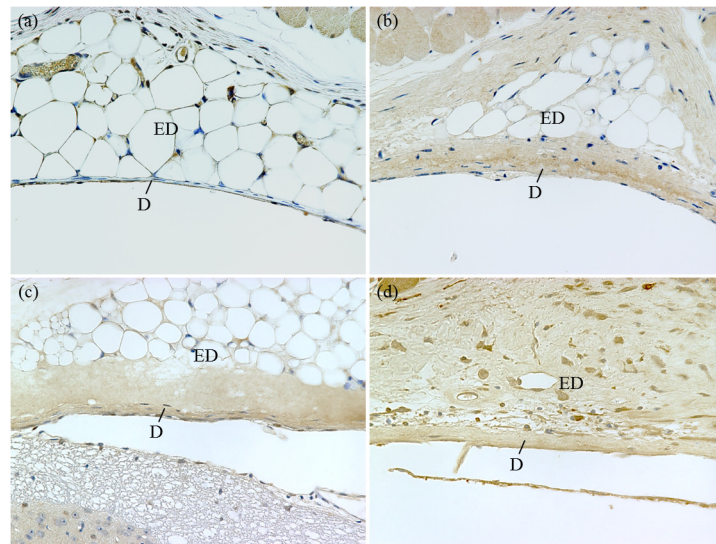


Fig 3. Immunohistochemical staining of TGF- β 1. (a) Grade 0, no positive cells. (b) Grade 1, <30% of cells were positive. (c) Grade 2, 30%–59% of cells were positive. (d) Grade 3, \geq 60% of cells were positive. (magnification $\times 400$ objective). Abbreviations: D, dura mater; ED, epidural space.

doi:10.1371/journal.pone.0133806.g003

fixed with 4% paraformaldehyde and 1% glutaraldehyde buffer solution for 30 min at 4°C, and postfixated with 1% OsO₄ for 30 min at 4°C. Then, the specimens were stained with 2% uranyl acetate for 30 min, dehydrated in a graded ethanol series, and embedded in an epoxy resin based on Glicidether (Selva Feinbiochemica, Heidelberg, Germany). Ultrathin sections (about 70 nm) were prepared using an ultramicrotome, stained with uranyl acetate and lead citrate, and subjected to observation using a JEM-1210 electron microscope (JEOL, Tokyo, Japan).

Statistical analyses

The extent of epidural fibrosis and the frequency of TGF- β 1-positive cells in each group were compared using the 2-tailed Mann-Whitney *U* test. Statistical significance was set at a *P* value of < 0.05. SPSS version 19 (SPSS, Chicago, IL, USA) was used to perform the statistical analyses. All values in the figures indicate means and standard errors.

Results

Epidural fibrosis after irradiation

In the nonirradiated mice, slight thin fibrous bands were observed in a few cases, and there was no certain occurrence of fibrosis. In the 10-Gy irradiated mice, continuous fibrosis was occasionally observed from 16 weeks postirradiation. In the 20-Gy irradiated mice, fibrous bands were observed from around 8 weeks postirradiation, and continuous fibrosis first occurred around 12 weeks; epidural fibrosis was observed in all cases from 16 weeks postirradiation. The extent of epidural fibrosis was significantly higher in the 20-Gy irradiated mice compared with that in the nonirradiated and 10-Gy irradiated mice from 12 weeks postirradiation ($P < 0.05$) (Fig 4).

TGF- β 1 levels

Compared with the nonirradiated mice, the 20-Gy irradiated mice showed significantly more overexpression of TGF- β 1 at 1 week and ≥ 12 weeks postirradiation ($P < 0.05$); the 10-Gy

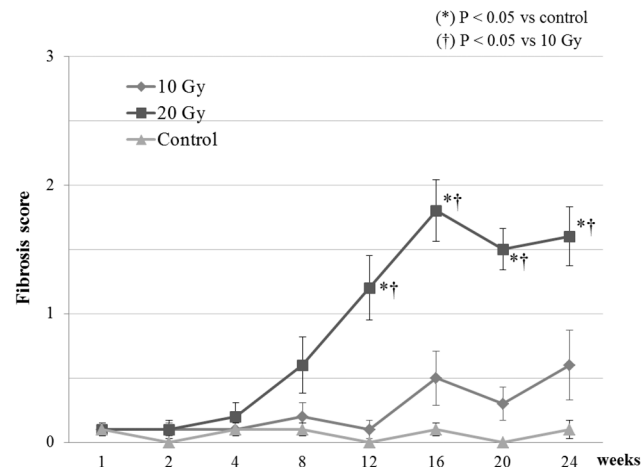


Fig 4. Epidural fibrosis scores of mice with 10 Gy or 20 Gy irradiation and without irradiation. The extent of epidural fibrosis was scored at each indicated time point ($n = 5$ /time point).

doi:10.1371/journal.pone.0133806.g004

irradiated mice showed significantly more overexpression of TGF- β 1 at 1 week and ≥ 16 weeks postirradiation ($P < 0.05$). At 12 weeks postirradiation, the 20-Gy irradiated mice showed significantly more overexpression of TGF- β 1 compared with the 10-Gy irradiated mice (Fig 5).

Microstructure of dura mater and surrounding tissues

There were no prominent changes in the microstructure of the dura mater between the 20-Gy irradiated and nonirradiated mice. On the other hand, the arachnoid barrier cell layer (ABC)—the outermost layer of the arachnoid mater—was enlarged at 1 week postirradiation and thinned at 12 and 24 weeks in the 20-Gy irradiated mice compared with in the nonirradiated mice (Fig 6). These findings were observed in all cases.

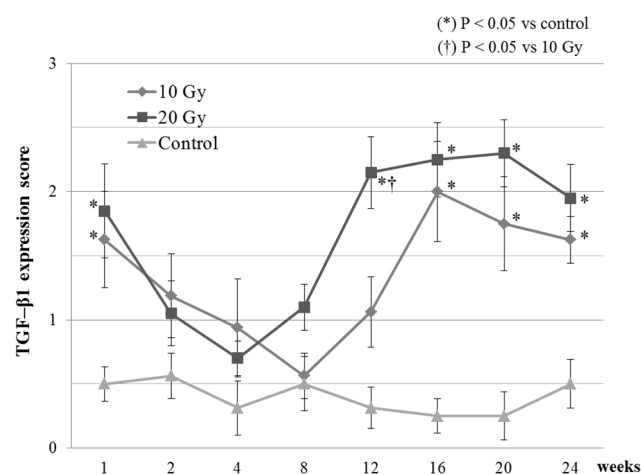


Fig 5. TGF- β 1 expression in the dura mater of mice with 10 Gy or 20 Gy irradiation and without irradiation. The expression of TGF- β 1 was scored at each indicated time point ($n = 5$ /time point).

doi:10.1371/journal.pone.0133806.g005




Fig 6. Microstructure of the dura mater and surrounding tissue. (Above) Nonirradiated mice at (a) 1 week, (b) 12 weeks, and (c) 24 weeks. (Below) 20-Gy irradiated mice at (d) 1 week, (e) 12 weeks, and (f) 24 weeks. (magnification $\times 10,000$). Abbreviations: ABC, arachnoid barrier cell layer; D, dura mater; DBC, dural border cell layer.

doi:10.1371/journal.pone.0133806.g006

Discussion

Radiation injury can be classified into 2 types [20–22]. Early injury occurs predominantly in the acute phase of the inflammatory response, and is characterized by angiogenic disorder and impaired tissue remodeling. On the other hand, late injury is typified by fibrosis and delayed wound healing caused by fibroblast dysfunction. Of these, radiation-induced fibrosis is regarded as a composite tissue reaction consisting of prominent extracellular matrix deposition and abnormal outgrowth of fibroblasts. Various growth factors and cytokines play important roles in this process; among them, TGF- β 1 is thought to play a central role by acting as a master switch in inducing, forming, and maintaining fibrosis [17, 18]. Radiation-induced fibrosis has been reported in various organs, including the skin, lungs, kidneys, liver, and heart [13–15]. However, until now, there have been no reports focusing on the dura mater.

The dura mater is the outermost of the 3 meninges covering the spinal cord. Although there are slight differences in dural structure between humans and animals, it is composed mainly of fibroblasts with many extracellular collagen and elastic fibers, and adjacent fibroadipose tissue with a rich vasculature located in the epidural space [23, 24]. Epidural fibrosis was first described in 1948 as fibrous tissue deposits in the epidural space following posterior spinal surgery [25]. Since then, much research has been conducted, but almost all studies have investigated epidural fibrosis following spinal surgery [26, 27]. Epidural fibrosis is a contributing factor for failed back surgery syndrome [28], and is a strong risk factor for intraoperative dural injury due to severe adhesion [29]; there are currently no effective treatments for epidural fibrosis.

In the present study, we confirmed that epidural fibrosis was induced postirradiation in mice, and, despite the presence of individual differences, fibrosis was observed in all late stages after irradiation with 20 Gy. In addition, our results showed that epidural fibrosis was observed at a lower rate after irradiation with 10 Gy than after irradiation at 20 Gy. This finding is consistent with the findings of past reports in which a higher total dose was more likely to result in late-stage radiation injury [30, 31]. Moreover, overexpression of TGF- β 1 was observed, suggesting a generation mechanism of epidural fibrosis that is similar to that observed in other

tissue. Additionally, there were 2 peaks of overexpression: very early postirradiation and in the late stages after irradiation. This variation pattern of TGF- β 1 expression is similar to a previous study that evaluated mice skin [32] and found that persistent overexpression of TGF- β 1 in the late stages after irradiation is strongly involved in the occurrence of epidural fibrosis.

In clinical studies at our facility, occurrence of intraoperative dural injury was significantly higher at ≥ 12 months postirradiation than at < 12 months [12]. In these cases, epidural fibrosis, as a late-stage radiation injury, could be a major cause of the subsequent dural injury. Therefore, because epidural fibrosis is more likely to occur in the late-stages after high-dose irradiation, surgery under such condition bears an increased risk of intraoperative dural injury associated with peridural adhesion. Moreover, when dural injury is observed during surgery, a primary suture is generally performed to prevent postoperative CSF leakage. This method is sufficient for treating most dural injuries. However, dural injury after irradiation easily develops into postoperative CSF leakage [33, 34]. In such cases, delayed wound healing as a late-stage radiation injury may occur in the dura mater due to radiation-induced cell dysfunction; however, no reports have verified this experimentally.

Another finding of the present study was post-irradiation thinning of the ABC. The ABC is located in the outermost layer of the arachnoid mater, and is formed of cells with tight junctions that are similar to endothelial cells [35]. The ABC has been reported to be strongly involved in meningeal permeability [36]. In addition, irradiation of vessels increases vascular permeability, and is associated with collapse of tight junctions in the vascular endothelial cell layer [37]. Therefore, it is anticipated that meningeal permeability would be increased in association with postirradiation ABC thinning by a similar mechanism. Clinically, postoperative CSF leakage is sometimes experienced despite the absence of dural injury [12]; the possibility that this would be caused by an increase in meningeal permeability due to radiation injury is fully conceivable. In the future, analysis of more samples and experimental verification of increased meningeal permeability associated with ABC thinning is necessary.

Because of the increase in the number of long-term survivors after radiotherapy for spinal metastases, most surgeons will encounter situations in which they will have to perform surgery on patients with a history of radiotherapy. Thus, full consideration should be given to late-stage radiation injury, including epidural fibrosis, and appropriate surgical strategies, meticulous surgical techniques, and measures for preventing serious complications should be employed. Recent studies have found that fibrosis is not untreatable, irreversible dead tissue, as had long been believed [13, 15]. Delanian et al. reported that application of combined pentoxifylline and tocopherol in patients with radiation-induced fibrosis elicited a 70% reduction in fibrotic volume, concomitant with a significant decrease in TGF- β 1 expression [38]. Furthermore, this treatment proved efficacious in reducing fibrotic volume in a clinical randomized controlled trial [39]. In addition, Nishioka et al. reported that administration of a TGF- β -targeted drug before irradiation suppressed the occurrence of fibrosis [40]. Additional experimental research is in progress to evaluate the therapeutic effects of these drugs for epidural fibrosis.

The present study has an important limitation in that there are substantial differences in radiosensitivity between mice and humans [41]. This means that we could not estimate the dose volume and duration that would cause radiation-induced epidural fibrosis in humans. In addition, differences in cellular composition between mouse and human tissue could contribute to differences in molecular response [42]. Moreover, it is necessary to consider interhuman diversity. Strain differences in the radiation response of mice have been reported; for example, extensive fibrosis was observed in C57BL/6 mice, whereas it was almost absent in C3H mice [43]. It was also reported that inbred mice, which have been used extensively for modeling human diseases, are representative of a single individual and would not represent interhuman diversity [44]. In the present study, although closed-colony mice with genetic diversity were

used rather than inbred mice, these too would not represent the full spectrum of interhuman diversity. Therefore, human subject research is indispensable; however, because acquiring dura mater and peridural tissue from the living body is difficult, postmortem research may be necessary.

In summary, this study confirms that epidural fibrosis is induced in the late stages after high-dose irradiation in mice, and that overexpression of TGF- β 1 occurs in a manner similar to radiation-induced fibrosis in other tissue. Additionally, thinning of the ABC was observed in the late stages after irradiation. Thus, consideration should be given to the possibility that these phenomena can occur as radiation-induced injuries of the spine.

Supporting Information

S1 ARRIVE Checklist.
(PDF)

Acknowledgments

The authors thank Ms. Yoko Kasai for her skillful technical assistance.

Author Contributions

Conceived and designed the experiments: NY HM MY. Performed the experiments: NY SD SK KY. Analyzed the data: NY HM. Contributed reagents/materials/analysis tools: NY. Wrote the paper: NY HM YM SI HT.

References

1. Bartels RH, van der Linden YM, van der Graaf WT. Spinal extradural metastasis: review of current treatment options. *CA Cancer J Clin.* 2008; 58: 245–259. doi: [10.3322/CA.2007.0016](https://doi.org/10.3322/CA.2007.0016) PMID: [18354080](https://pubmed.ncbi.nlm.nih.gov/18354080/)
2. Gerszten PC, Mendel E, Yamada Y. Radiotherapy and radiosurgery for metastatic spine disease: what are the options, indications, and outcomes? *Spine (Phila Pa 1976).* 2009; 15: 78–92.
3. Rades D, Abrahm JL. The role of radiotherapy for metastatic epidural spinal cord compression. *Nat Rev Clin Oncol.* 2010; 7: 590–598. doi: [10.1038/nrclinonc.2010.137](https://doi.org/10.1038/nrclinonc.2010.137) PMID: [20808299](https://pubmed.ncbi.nlm.nih.gov/20808299/)
4. Janjan NA. Radiotherapeutic management of spinal metastases. *J Pain Symptom Manage.* 1996; 11: 47–56. PMID: [8815150](https://pubmed.ncbi.nlm.nih.gov/8815150/)
5. Bates T. A review of local radiotherapy in the treatment of bone metastases and cord compression. *Int J Radiat Oncol Biol Phys.* 1992; 23: 217–221. PMID: [1374063](https://pubmed.ncbi.nlm.nih.gov/1374063/)
6. Westbury CB, Yarnold JR. Radiation fibrosis—current clinical and therapeutic perspectives. *Clin Oncol (R Coll Radiol).* 2012; 24: 657–672.
7. Delanian S, Lefaix JL. Current management for late normal tissue injury: radiation-induced fibrosis and necrosis. *Semin Radiat Oncol.* 2007; 17: 99–107. PMID: [17395040](https://pubmed.ncbi.nlm.nih.gov/17395040/)
8. Goldwein JW. Radiation myelopathy; a review. *Med Pediatr Oncol.* 1987; 15: 89–95.
9. Schultheiss TE, Higgins EM, El-Mahdi AM. The latent period in clinical radiation myelopathy. *Int J Radiat Oncol Biol Phys.* 1984; 10: 1109–1115. PMID: [6378847](https://pubmed.ncbi.nlm.nih.gov/6378847/)
10. Ghogawala Z, Mansfield FL, Borges LF. Spinal radiation before surgical decompression adversely affects outcomes of surgery for symptomatic metastatic spinal cord compression. *Spine (Phila Pa 1976).* 2001; 26: 818–824.
11. Demura S, Kawahara N, Murakami H, Nambu K, Kato S, Yoshioka K, et al. Surgical site infection in spinal metastasis: risk factors and countermeasures. *Spine (Phila Pa 1976).* 2009; 34: 635–639.
12. Yokogawa N, Murakami H, Demura S, Kato S, Yoshioka K, Hayashi H, et al. Perioperative complications of total en bloc spondylectomy: adverse effects of preoperative irradiation. *PLoS One.* 2014; 9: e98797. doi: [10.1371/journal.pone.0098797](https://doi.org/10.1371/journal.pone.0098797) PMID: [24893004](https://pubmed.ncbi.nlm.nih.gov/24893004/)
13. Rodemann HP, Bamberg M. Cellular basis of radiation-induced fibrosis. *Radiother Oncol.* 1995; 35: 83–90. PMID: [7569029](https://pubmed.ncbi.nlm.nih.gov/7569029/)

14. Yarnold J, Brotons MC. Pathogenetic mechanisms in radiation fibrosis. *Radiother Oncol*. 2010; 97: 149–161. doi: [10.1016/j.radonc.2010.09.002](https://doi.org/10.1016/j.radonc.2010.09.002) PMID: [20888056](https://pubmed.ncbi.nlm.nih.gov/20888056/)
15. Rubin P, Johnston CJ, Williams JP, McDonald S, Finkelstein JN. A perpetual cascade of cytokines postirradiation leads to pulmonary fibrosis. *Int J Radiat Oncol Biol Phys*. 1995; 33: 99–109. PMID: [7642437](https://pubmed.ncbi.nlm.nih.gov/7642437/)
16. He Y, Revel M, Loty B. A quantitative model of post-laminectomy scar formation. Effects of a nonsteroidal anti-inflammatory drug. *Spine (Phila Pa 1976)*. 1995; 20: 557–563.
17. Martin M, Lefaix J, Delanian S. TGF-beta1 and radiation fibrosis: a master switch and a specific therapeutic target? *Int J Radiat Oncol Biol Phys*. 2000; 47: 277–290. PMID: [10802350](https://pubmed.ncbi.nlm.nih.gov/10802350/)
18. Border WA, Noble NA. Transforming growth factor beta in tissue fibrosis. *N Engl J Med*. 1994; 331: 1286–1292. PMID: [7935686](https://pubmed.ncbi.nlm.nih.gov/7935686/)
19. Mozes MM, Hodics T, Kopp JB. Isoform specificity of commercially-available anti-TGF- β antibodies. *J Immunol Methods*. 1999; 225: 87–93. PMID: [10365785](https://pubmed.ncbi.nlm.nih.gov/10365785/)
20. Dormand EL, Banwell PE, Goodacre TE. Radiotherapy and wound healing. *Int Wound J*. 2005; 2: 112–127. PMID: [16722862](https://pubmed.ncbi.nlm.nih.gov/16722862/)
21. Wang J, Boerma M, Fu Q, Hauer-Jensen M. Radiation responses in skin and connective tissues: effect on wound healing and surgical outcome. *Hernia*. 2006; 10: 502–506. PMID: [17047884](https://pubmed.ncbi.nlm.nih.gov/17047884/)
22. Haubner F, Ohmann E, Pohl F, Strutz J, Gassner HG. Wound healing after radiation therapy: review of the literature. *Radiat Oncol*. 2012; 24: 162.
23. Patin DJ, Eckstein EC, Harum K, Pallares VS. Anatomic and biomechanical properties of human lumbar dura mater. *Anesth Analg*. 1993; 76: 535–540. PMID: [8452262](https://pubmed.ncbi.nlm.nih.gov/8452262/)
24. Andres JD, Reina MA, Prats A. Epidural space and regional anesthesia. *Eur J Pain*. 2009; 3: 55–53.
25. Key JA, Ford LT. Experimental intervertebral-disc lesions. *J Bone Joint Surg Am*. 1948; 30: 621–630.
26. Cauchois J, Ficat C, Girard B. Repeat surgery after disc excision. *Spine (Phila Pa 1976)*. 1978; 3: 256–259.
27. Rönnerberg K, Lind B, Zoega B, Gadeholt-Göthlin G, Halldin K, Gellerstedt M, et al. Peridural scar and its relation to clinical outcome: a randomised study on surgically treated lumbar disc herniation patients. *Eur Spine J*. 2008; 17: 1714–1720. doi: [10.1007/s00586-008-0805-8](https://doi.org/10.1007/s00586-008-0805-8) PMID: [18946688](https://pubmed.ncbi.nlm.nih.gov/18946688/)
28. Siqueira EB, Kranzler LI, Dharkar DD. Fibrosis of the dura mater. A cause of "failed back" syndrome. *Surg Neurol*. 1983; 19: 168–170. PMID: [6845146](https://pubmed.ncbi.nlm.nih.gov/6845146/)
29. Baker GA, Cizik AM, Bransford RJ, Bellabarba C, Konodi MA, Chapman JR, et al. Risk factors for unintended durotomy during spine surgery: a multivariate analysis. *Spine J*. 2012; 12: 121–126. doi: [10.1016/j.spinee.2012.01.012](https://doi.org/10.1016/j.spinee.2012.01.012) PMID: [22342249](https://pubmed.ncbi.nlm.nih.gov/22342249/)
30. Devalia HL, Mansfield L. Radiotherapy and wound healing. *Int Wound J*. 2008; 5: 40–44. PMID: [18081782](https://pubmed.ncbi.nlm.nih.gov/18081782/)
31. Taylor JM, Mendenhall WM, Parsons JT, Lavey RS, et al. The influence of dose and time on wound complications following post-radiation neck dissection. *Int J Radiat Oncol Biol Phys*. 1992; 23: 41–46. PMID: [1572830](https://pubmed.ncbi.nlm.nih.gov/1572830/)
32. Randall K, Coggle JE. Long-term expression of transforming growth factor TGF beta 1 in mouse skin after localized beta-irradiation. *Int J Radiat Biol*. 1996; 70: 351–360. PMID: [8800206](https://pubmed.ncbi.nlm.nih.gov/8800206/)
33. Zide BM, Wisoff JH, Epstein FJ. Closure of extensive and complicated laminectomy wounds. Operative technique. *J Neurosurg*. 1987; 67: 59–64. PMID: [3598673](https://pubmed.ncbi.nlm.nih.gov/3598673/)
34. Couture D, Branch CL Jr. Spinal pseudomeningoceles and cerebrospinal fluid fistulas. *Neurosurg Focus*. 2003; 15: 1–5. PMID: [15376362](https://pubmed.ncbi.nlm.nih.gov/15376362/)
35. Vandenabeele F, Creemers J, Lambrichts I. Ultrastructure of the human spinal arachnoid mater and dura mater. *J Anat*. 1996; 189: 417–430. PMID: [8886963](https://pubmed.ncbi.nlm.nih.gov/8886963/)
36. Bernards CM, Hill HF. Morphine and alfentanil permeability through the spinal dura, arachnoid, and pia mater of dogs and monkeys. *Anesthesiology*. 1990; 73: 1214–1214. PMID: [2248398](https://pubmed.ncbi.nlm.nih.gov/2248398/)
37. Stone HB, Coleman CN, Anscher MS, McBride WH, et al. Effects of radiation on normal tissue: consequences and mechanisms. *Lancet Oncol*. 2003; 4: 529–536. PMID: [12965273](https://pubmed.ncbi.nlm.nih.gov/12965273/)
38. Lefaix JL, Delanian S, Vozenin MC, Leplat JJ, Tricaud Y, Martin M. Striking regression of subcutaneous fibrosis induced by high doses of gamma rays using a combination of pentoxifylline and alpha-tocopherol: an experimental study. *Int J Radiat Oncol Biol Phys*. 1999; 43: 839–487. PMID: [10098440](https://pubmed.ncbi.nlm.nih.gov/10098440/)
39. Delanian S, Porcher R, Balla-Mekias S, Lefaix JL. Randomized, placebo-controlled trial of combined pentoxifylline and tocopherol for regression of superficial radiation-induced fibrosis. *J Clin Oncol*. 2003; 21: 2545–2550. PMID: [12829674](https://pubmed.ncbi.nlm.nih.gov/12829674/)

40. Nishioka A, Ogawa Y, Mima T, Jin YJ, Sonobe H, Kariya S, et al. Histopathologic amelioration of fibro-proliferative change in rat irradiated lung using soluble transforming growth factor-beta (TGF-beta) receptor mediated by adenoviral vector. *Int J Radiat Oncol Biol Phys*. 2004; 58: 1235–1241. PMID: [15001268](#)
41. Dowd SB, Tilson ER. *Practical radiation protection and applied radiobiology*. 2nd ed. Saunders, Philadelphia; 1999.
42. Mestas J, Hughes CC. Of mice and not men: Differences between mouse and human immunology. *J Immunol*. 2004; 172: 2731–2738. PMID: [14978070](#)
43. Sharplin J, Franko AJ. A quantitative histological study of strain-dependent differences in the effects of irradiation on mouse lung during the intermediate and late phases. *Radiat Res*. 1989; 119: 15–31. PMID: [2756106](#)
44. Seok J, Warren HS, Cuenca AG, Mindrinos MN, Baker HV, Xu W, et al. Genomic responses in mouse models poorly mimic human inflammatory diseases. *Proc Natl Acad Sci USA*. 2013; 110: 3507–3512. doi: [10.1073/pnas.1222878110](#) PMID: [23401516](#)