

Minocycline-Induced Pneumonitis with Bilateral Hilar Lymphadenopathy and Pleural Effusion

Takuma BANDO, Masaki FUJIMURA***, Yatsugi NODA, Jin-ichiro HIROSE*,
Goroku OHTA** and Tamotsu MATSUDA***

A 65-year-old man developed respiratory failure with diffuse interstitial shadow, bilateral pleural effusion, and bilateral hilar lymphadenopathy on chest X-ray and CT, after intravenous administration of minocycline. Corticosteroid therapy was effective. The findings from bronchoalveolar lavage (BAL) and transbronchial lung biopsy were compatible with eosinophilic pneumonia. Provocation test supported this diagnosis, but the lymphocyte stimulation test was negative. A review of the literature and the diagnoses of drug-induced pulmonary diseases are discussed.

(Internal Medicine 33: 177-179, 1994)

Key words: drug-induced pulmonary disease, pulmonary infiltrates with eosinophilia, provocation test

Introduction

Minocycline is commonly used for the treatment of various infectious diseases, especially in cases of acute bronchitis or urinary tract infections. But there have been only a few reports about the clinical manifestation of minocycline-induced pulmonary disease. We describe a case of minocycline-induced pulmonary infiltrates with eosinophilia presenting with bilateral pleural effusion and hilar lymphadenopathy who showed a good response to corticosteroid therapy.

Case Report

A 65-year-old man was admitted to our hospital on November 28, 1991 with orthopnea and dry cough. The chest X-ray on admission showed diffuse reticular shadows in the bilateral lung fields with bilateral pleural effusion. Five days before admission, he was intravenously administered minocycline 200 mg and cefotiam 1 g for acute bronchitis. The physical examination revealed temperature of 37.2°C and pulse 120/min, and regular. Chest auscultation revealed late inspiratory fine crackles over bilateral chest. Cervical phlebotasia, pretibial edema, or superficial lymph node swelling were not evident.

The laboratory data on admission were as follows: White cell count was 11,900/ μ l, with 82% neutrophils, 15%

lymphocytes, and 3% monocytes. Eosinophils were not detected. Hemoglobin was 12.4 g/dl with a hematocrit value of 36.5%. Erythrocyte sedimentation rate was 104 mm/hr. C reactive protein was 9.2 mg/dl. Serum protein was 6.5 g/dl with 65% albumin. Serum IgE was 322 IU/ml (normal; less than 250 IU/ml). The liver and renal functions were normal. Electrocardiogram revealed sinus tachycardia. Ultrasonic cardiogram revealed no significant findings such as dilatation of left ventricles, enlargement of inferior vena cava, or pericardial effusion.

Chest X-ray on admission (Fig. 1) showed diffuse reticular shadows in bilateral lung fields with bilateral pleural effusion. Chest CT (Fig. 2) showed diffuse interstitial shadows in bilateral lung fields, bilateral pleural effusion, and bilateral enlargement of hilar lymph nodes. Bronchoalveolar lavage (BAL) and transbronchial lung biopsy were performed. BAL was performed using 150 ml of sterile saline solution (recovery rate; 62%). Differential cell analysis revealed an increase in total cell counts (3.2×10^5 /ml), and 51% macrophages, 1% neutrophils, 42% lymphocytes, and 6% eosinophils. Analysis of lymphocyte subsets revealed the presence of 45.4% CD4+ cells and 33.1% CD8+ (CD4+/CD8+ ratio was 1.4). The biopsied specimens obtained from right middle lobe (S^{4a}) (Fig. 3) showed alveolar septal thickening and infiltration of eosinophils and lymphocytes into the alveoli and alveolar septa. The examination of pleural effusion revealed neutrophil pleurisy; 95% neutrophils and 5%

From the Departments of Internal Medicine, *Radiology and **Pathology, Toyama Rosai Hospital, Uozu and ***the Third Department of Internal Medicine, School of Medicine, Kanazawa University, Kanazawa

Received for publication September 22, 1993; Accepted for publication January 20, 1994

Reprint requests should be addressed to Dr. Takuma Bando, the Third Department of Internal Medicine, School of Medicine, Kanazawa University, 13-1 Takaramachi, Kanazawa 920

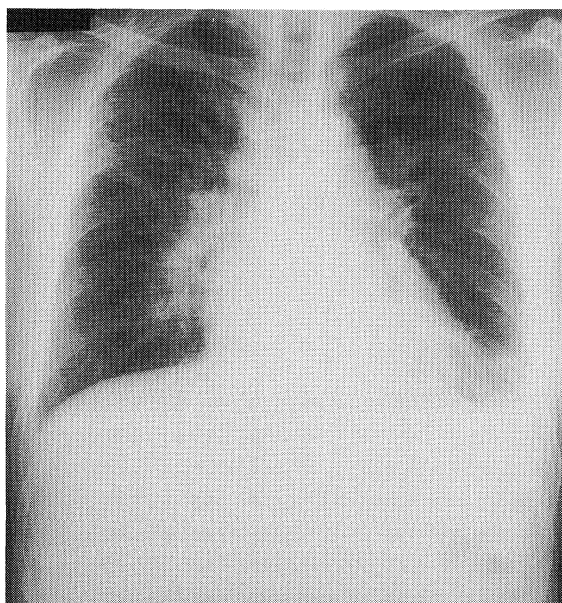


Fig. 1. Chest X-ray on admission shows diffuse reticular shadows in the bilateral lung fields, and hilar lymphadenopathy.

lymphocytes. The result of lymphocyte stimulation test for minocycline or cefotiam was negative.

Ten days after admission, chest X-ray findings and blood gas analysis were recovered only with oxygen therapy; provocation test with minocycline and cefotiam was then performed. Approximately seven hours after the oral administration of minocycline (100 mg), dry cough developed, and peripheral eosinophilia (32%) and a decrease in arterial oxygen pressure (PaO_2 66.4 Torr) were observed. Following corticosteroid therapy (prednisolone 30 mg/day for seven days), these findings completely disappeared. During and after the provocation test, chest X-ray presented no significant findings. The provocation test with cefotiam was negative.

Discussion

Drug-induced pneumonitis occurs with many types of drugs and presents various clinical features (1). Drug-induced pulmonary diseases are classified into two categories; these due to cytotoxic drugs (2) or non-cytotoxic drugs (3). Numerous non-cytotoxic agents are reported to cause drug-induced pulmonary disease, and the list continues to grow (3). Although interstitial pneumonia or fibrosis is a common manifestation of drug-induced pulmonary disease associated with the use of either cytotoxic and non-cytotoxic drugs, there have been few cases which presented with bilateral hilar lymphadenopathy and/or pleural effusion. There have been some reports of interstitial pneumonia induced by antibiotics; they occurred as a result of non-cytotoxic drugs and allergic reaction (2). Almost all of these cases induced by antibiotics occur as pulmonary infiltrates with eosinophilia.

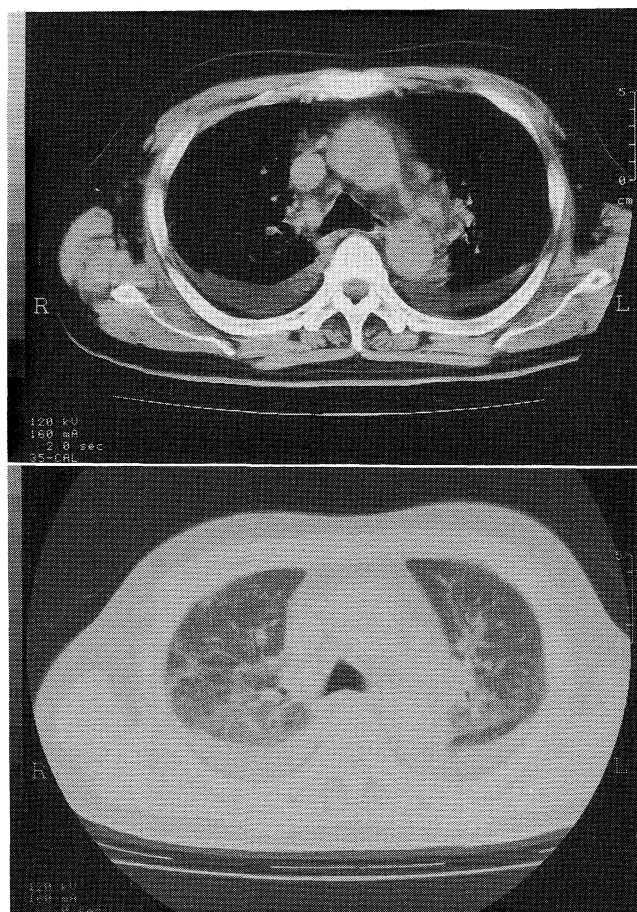


Fig. 2. Chest CT on admission also shows diffuse linear and reticular shadows in the bilateral lung fields, bilateral pleural effusion, and the enlargement of bilateral hilar lymph nodes.

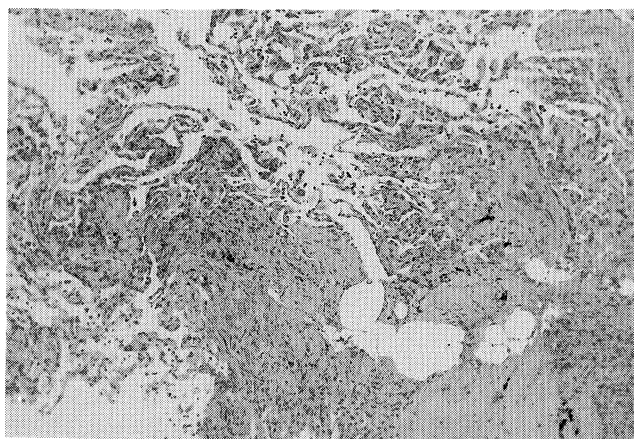


Fig. 3. Biopsied specimens obtained from right middle lobe (S^{4a}) shows septal thickening and infiltration of eosinophils and lymphocytes into the alveolar septa and bronchioles (HE stain, $\times 40$).

Minocycline continues to be one of the most commonly used antibiotics. Although it has been often prescribed for various infectious diseases, such as pneumonia, acute bronchitis, urinary tract infection, there have been only a few reports about minocycline-induced pulmonary disease (4). The present case was diagnosed by the provocation test for minocycline, and the clinical course, pathological findings, and cell-analysis of BAL fluid support the diagnosis. Lymphocyte stimulation test has been reported as a useful and reliable measure for the diagnosis of drug allergy and drug-induced hepatitis (5), but in this case the test for minocycline was negative.

We know of no other cases which presented with bilateral hilar lymphadenopathy and pleurisy induced by minocycline. Bilateral lymphadenopathy is usually seen in sarcoidosis, lymphoma, or viral infection, while bilateral hypersensitivity lymphadenopathy is uncommon, except for cases of anti-convulsants (6, 7). Furthermore, this case presented bilateral neutrophilic pleurisy and it disappeared within several days without any treatment. Although hypersensitivity pleurisy has been rarely reported, acute eosinophilic pneumonia, which is recognized as allergic interstitial pneumonia, sometimes complicates bilateral pleurisy (8). Yokoyama et al (9) reported a case of eosinophilic pneumonia induced by minocycline which presented Kerley B lines as a feature of a positive provocation test. These cases might present pleural effusion or pleural reactive change depending upon the hypersensitivity reaction induced by minocycline.

Recently, it was reported that BAL fluid in the early phase of antigen inhalation contains an increased percent of neutrophils as well as lymphocytes and the increased neutrophils decrease rapidly after admission with cessation of antigen inhalation (10). In contrast, in the chronic or the convalescent phase of hypersensitivity pneumonitis, there is a low percent of neutrophils and prominent increase of lymphocytes and the increased lymphocytes decrease gradually. In this case, pleural effusion observed in the early phase after the administration of minocycline contained an increased level of neutrophils and several days after admission, lymphocytosis was predominant in the BAL fluid. Although the blastogenesis was not detected by the lymphocyte stimulation test for minocycline, the results

of provocation with minocycline, the lymphocytosis in BAL fluid, and lymphocytic alveolitis observed in biopsied specimens suggest that the immunological reactions except for delayed hypersensitivity are important in this patient. Some reports have documented the role of CD8+ T lymphocytes and the interaction of alveolar cells, macrophages and lymphocytes, in minocycline-induced pneumonitis (11, 12). Although the details of the mechanism remain unclear, it is important for us to be aware of such severe complications occurring in patients receiving minocycline. Further, in the diagnosis of minocycline-induced pulmonary disease, the lymphocyte stimulation test is not always reliable, whereas the provocation test is thought to be a safe and sure method.

References

- 1) Rosenow EC III. The spectrum of drug-induced pulmonary disease. *Ann Intern Med* **77**: 977, 1972.
- 2) Cooper JAD Jr, White DA, Matthay RA. Drug-induced pulmonary disease. Part 1: Cytotoxic drugs. *Am Rev Respir Dis* **133**: 321, 1986.
- 3) Cooper JAD Jr, White DA, Matthay RA. Drug-induced pulmonary disease. Part 2: Noncytotoxic drugs. *Am Rev Respir Dis* **133**: 488, 1986.
- 4) Ho D, Tashkin DP, Bein ME, Sharma O. Pulmonary infiltrates with eosinophilia associated with tetracycline. *Chest* **76**: 33, 1979.
- 5) Warrington RJ, Tse KS, Gorski BA, Schwenk R, Sehon AH. Evaluation of isoniazid-associated hepatitis by immunological tests. *Clin Exp Immunol* **32**: 97, 1978.
- 6) Heitzman ER. Lymphadenopathy related to anticonvulsant therapy. *Radiology* **89**: 311, 1967.
- 7) Cullinan SA, Bower GC. Acute pulmonary hypersensitivity to carbamazepine. *Chest* **68**: 580, 1975.
- 8) Editorial. Acute eosinophilic pneumonia. *Lancet* **335**: 947, 1990.
- 9) Yokoyama A, Mizushima Y, Suzuki H, Arai N, Kitagawa M, Yano S. Acute eosinophilic pneumonia induced by minocycline: prominent Kerley B lines as a feature of positive re-challenge test. *Jpn J Med* **29**: 195, 1990.
- 10) Tada S, Kajimoto K, Sugimoto K, et al. The cellular kinetics in BAL fluid of hypersensitivity pneumonitis and pulmonary function. *Jpn J Allergology* **41**: 36, 1992 (in Japanese).
- 11) Kehler RH, Swartz S, Schlueter DP, Bar-Sela S, Fink JN. Immunoregulation in hypersensitivity pneumonitis: phenotypic and functional analyses. *J Immunol* **130**: 766, 1984.
- 12) Guillon JM, Joly P, Autran B, et al. Minocycline induced cell mediated hypersensitivity pneumonitis. *Ann Intern Med* **117**: 476, 1992.