

# Dual-radionuclide simultaneous gastric emptying and bile transit study after gastric surgery with double-tract reconstruction

メタデータ	言語: eng 出版者: 公開日: 2017-10-05 キーワード (Ja): キーワード (En): 作成者: メールアドレス: 所属:
URL	<a href="http://hdl.handle.net/2297/3080">http://hdl.handle.net/2297/3080</a>

## Dual-radionuclide simultaneous gastric emptying and bile transit study after gastric surgery with double-tract reconstruction

Kenichi NAKAJIMA,\* Masaya KAWANO,\* Shinichi KINAMI,\*\* Takashi FUJIMURA,\*\*  
Koichi MIWA\*\* and Norihisa TONAMI\*

*Departments of \*Nuclear Medicine and \*\*Gastroenterologic Surgery, Kanazawa University Hospital*

**Objective:** The physiology of gastrointestinal transfer function after proximal gastrectomy with bypass-tract reconstruction is not well understood. We applied a simultaneous dual-radionuclide method with a hepatobiliary imaging and gastric emptying study to evaluate physiologic alterations occurring after surgery. **Methods:** Nineteen patients with early gastric cancer, including 9 preoperative control patients and 10 who had proximal gastrectomy and double-tract reconstruction surgery were examined by dual-radionuclide hepatobiliary and gastric emptying studies ( $^{99m}\text{Tc}$  PMT and  $^{111}\text{In}$  DTPA). Retention fraction in the stomach at 3 minutes (R3) and 60 minutes (R60) and gastric emptying half-time (GET) were calculated. Bile reflux and mixture of bile and food were also evaluated. **Results:** The retention fractions of R3 and R60 were significantly lower in the double-tract reconstruction group than those in the preoperative group. GET differed significantly between the double-tract and preoperative groups ( $20.7 \text{ min} \pm 7.1 \text{ min}$  and  $36.2 \text{ min} \pm 11.0 \text{ min}$ ,  $p = 0.0018$ ). The mixture of bile and food was not good in the double-tract reconstruction group ( $p = 0.014$  vs. preoperative). Patients with a large residual stomach showed slower initial emptying ( $p = 0.0068$ ) and a better mixture of bile and food ( $p = 0.058$ ) compared to those with a small residual stomach. The bile reflux was not significantly increased after surgery. **Conclusion:** The dual-radionuclide gastrointestinal and hepatobiliary imaging was feasible and could demonstrate characteristic transit patterns of the foods and bile in the double-tract reconstruction procedure. A larger residual stomach, if possible, is desirable to provide better transfer and mixing of bile and foods.

**Key words:** gastric emptying study, gastric cancer, postoperative study, hepatobiliary imaging, dual-radionuclide acquisition

### INTRODUCTION

GASTRIC EMPTYING STUDIES have been used as an accurate means of diagnosing clinically significant gastrointestinal dysfunction despite some technical inaccuracies.<sup>1–3</sup> Because anatomical changes after gastric operation may introduce significant physiologic abnormalities, causing so called post-gastrectomy syndrome, post-gastrectomy patients are considered to be good candidates for radionuclide imaging. Division of vagal innervation, disturbances

in gastric reservoir function, bypass of the pylorus and motility disorders of the residual stomach and intestine may contribute to complex disturbances in the physiology of digestive systems. In addition, passage of bile and mixture with food may also vary from individual to individual depending on the operation procedures. In this regard, hepatobiliary imaging is considered useful, because bile reflux to the stomach and esophagus is problematic, and regulation of bile excretion may be modified after surgery.

Early gastric cancer is a common cancer in Japan and is found during a routine medical check-up of the stomach even without symptoms. In patients who had a gastric cancer in the upper portion, proximal gastrectomy has been considered to be an option in addition to total gastrectomy. A double-tract reconstruction procedure after proximal gastrectomy has been developed as a

Received September 30, 2004, revision accepted December 27, 2004.

For reprint contact: Kenichi Nakajima, M.D., Department of Nuclear Medicine, Kanazawa University Hospital, 13–1, Takaramachi, Kanazawa 920–8641, JAPAN.

E-mail: nakajima@med.kanazawa-u.ac.jp

unique procedure in Japan. The modification of the antrum- or pylorus-preserving procedure was introduced to obtain appropriate retention in the residual stomach and better transfer of foods into the small intestine without reflux to the esophagus.<sup>4</sup> Although the double-tract method has been expected to show the advantage of providing better passage and mixing of digestive juice and bile, it has not been confirmed well without nuclear medicine procedures. In addition, the incidence of bile reflux by this operation procedure should be evaluated.

Thus the purposes of this study were to evaluate (1) the feasibility of a dual-radionuclide study with <sup>99m</sup>Tc labeled *N*-pyridoxyl-5-methyl tryptophan (PMT) and <sup>111</sup>In diethylene triamine pentaacetic acid (DTPA) used as hepatobiliary and food tracers, (2) the passage patterns of bile and food after double-tract reconstruction and emptying of the residual stomach, and (3) the degree of mixing of food and bile with altered gastrointestinal passage after operation.

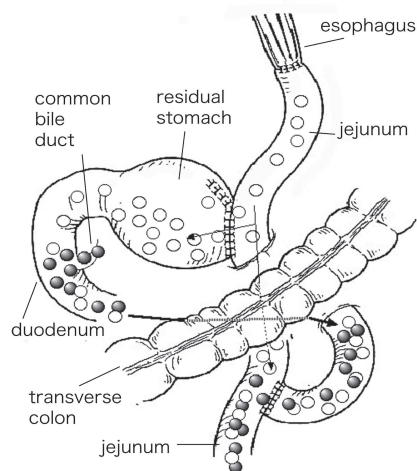
## MATERIALS AND METHODS

### *Patients and operation procedures*

Nineteen patients with early gastric cancer, which is defined as carcinoma confined to the mucosa or submucosa irrespective of lymph node involvement, were examined by dual-radionuclide hepatobiliary and gastric emptying studies. Nine patients were studied as a pre-operative condition group. The post-operative group was consisted of 10 patients with early gastric cancer who had been operated on by proximal gastrectomy and double-tract reconstruction. The interval between the nuclear study and the surgery was  $3.14 \pm 1.70$  (SD) years. The double-tract reconstruction procedure is shown schematically in Figure 1. The jejunal segment was pulled up and anastomosis to the esophagus was performed. Since the proximal portion with gastric cancer was removed, with the pylorus preserved, the residual stomach was anastomosed end-to-side to the jejunum. Finally, jejuno-jejunostomy was performed by end-to-side anastomosis, resulting in double tracts from the residual stomach to the small intestine. Gastric and antral branches of the vagal nerves were dissected in all patients. Using this procedure, a portion of food was intended to pass through the duodenum and partly through the bypass tract, so that the physiologic passage was partly maintained. The size of the residual stomach was divided into large and small based on  $\geq 1/2$  or  $< 1/2$  of the whole stomach, respectively.

### *Radiopharmaceutical and food preparation*

All patients were studied after overnight fasting. For hepatobiliary imaging, 40 MBq of <sup>99m</sup>Tc PMT was intravenously injected. Approximately 14 MBq of <sup>111</sup>In DTPA was mixed into the semi-liquid meal, which was designed for enteral nutrition (Okunos®, Folicafoods Co., Japan; 200 kcal, 200 ml, protein 10.2 g, fat 5.4 g, sugar 28.2 g).



**Fig. 1** The operation procedure of the double-tract reconstruction after proximal gastrectomy. The “double-tract” routes are schematically shown. Foods (open circle) and bile (solid circle) represent the passages and mixture of both tracers, and the arrows indicate movements of foods and bile.

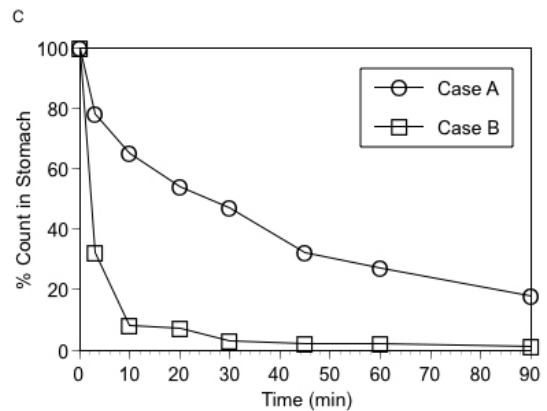
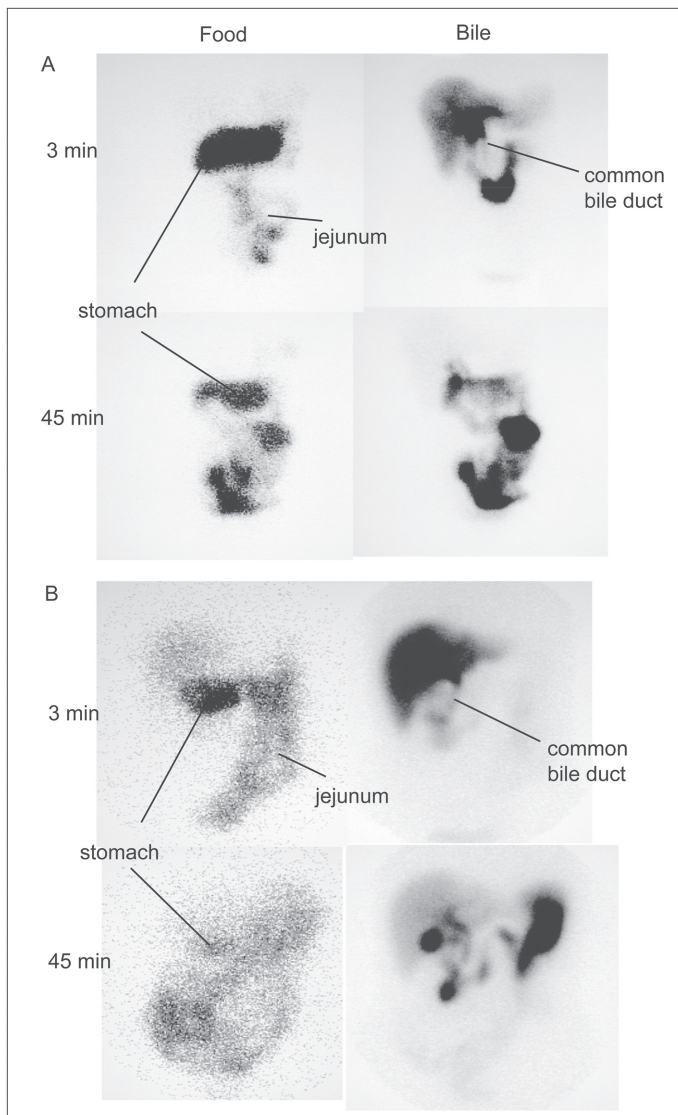
Approximately 15 minutes after injection of <sup>99m</sup>Tc PMT, the bile accumulation in the common bile duct was confirmed by a scintillation camera. The patient was then asked to ingest the meal within 3 minutes. When the bile transit was slow and the common bile duct was not visualized at 15 minutes, the start of ingestion was delayed for 5–15 minutes. Written informed consent was obtained before the nuclear study in all patients.

### *Data acquisition*

A scintillation camera (Orbiter, Siemens, USA) was equipped with a medium-energy collimator to obtain both <sup>111</sup>In and <sup>99m</sup>Tc distribution. Dual-energy acquisition was performed by energy discrimination centered at 140 keV with a 15% window for <sup>99m</sup>Tc, and 247 keV with a 15% window for <sup>111</sup>In. The patients were asked to remain still and relaxed in a sitting position, and dual-energy imaging was performed in the erect position. Anterior images of 256 × 256 pixels were obtained for 120 seconds at 3 minutes (just after ingestion), followed by imaging at 10, 20, 30, 45, 60 and 90 minutes. Thus the initial hepatobiliary image at time point 0 corresponded to the time point of 15 minutes after <sup>99m</sup>Tc PMT injection.

### *Crosstalk fraction*

The degree of crosstalk between <sup>111</sup>In and <sup>99m</sup>Tc was measured using syringes filled with 10 ml of water. The amount of radioactivity was 6.2 MBq for <sup>99m</sup>Tc and 2.2 MBq for <sup>111</sup>In. The energy windows were the same as those for a clinical setting. The crosstalk in the clinical image was measured in 5 patients who had no bile reflux using the location where only one radionuclide was thought to be accumulated. The crosstalk of the <sup>99m</sup>Tc to <sup>111</sup>In window was calculated by a regional count in the center



**Fig. 2** Three- and 45-minute images of foods and bile transit in two patients. (A) A 60-year-old female with large residual stomach (retention at 3 and 60 minutes, 78% and 27%; gastric emptying half-time, 29 min), (B) A 75-year-old female with small residual stomach (retention at 3 and 60 minutes, 32% and 2%; gastric emptying half-time, 11 min). Good mixture of the foods and the bile is observed at 45 minutes in panel A. Passage of the foods, however, precedes the bile at both 3 and 45 minutes in panel B. (C) Time-activity curves in patients A and B. Note gastric emptying half-time (min) of the residual stomach is calculated by mono-exponential fitting from 3 to 60 minutes, and the count at time 0 indicates total count ingested.

of the liver of the initial image by the count of the  $^{111}\text{In}$  window divided by that of the  $^{99\text{m}}\text{Tc}$  window. The crosstalk from the  $^{111}\text{In}$  to  $^{99\text{m}}\text{Tc}$  window was calculated by the regional count in the center of the stomach of the initial image by the count of the  $^{99\text{m}}\text{Tc}$  window divided by that of the  $^{111}\text{In}$  window. In the latter calculation, because the blood-pool activity was seen in the background, the average abdominal regional count from outside of the region of the stomach and intestine was subtracted.

#### Data analysis

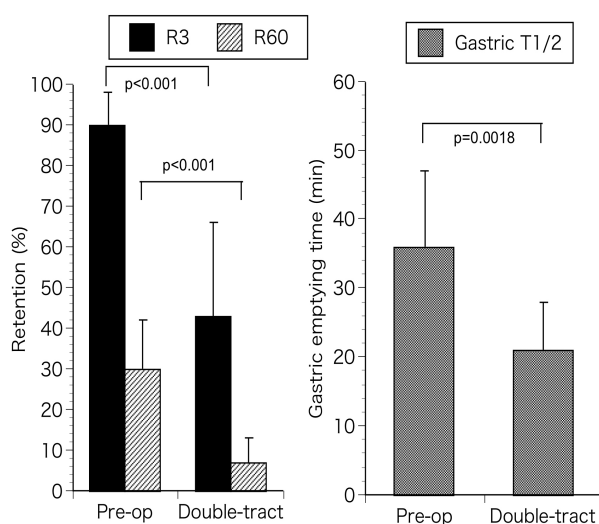
Using a nuclear medicine computer system (ICON P, Siemens, USA), regions of interest (ROIs) were drawn on the stomach and outside of the stomach. Operation records for the reconstruction procedure were referred to for localization of the stomach. The percentage of the count in the stomach divided by the sum of the stomach plus outside of the stomach was calculated. We confirmed that all of the abdominal activity was always included in the field of view. Radioactivity decay with time was not

corrected since we used a percentage of the stomach activity to the whole activity. The time point 0 was always defined as 100%, which was calculated by the sum of the inside and outside of the stomach at 3 minutes. The retention fractions in the stomach at 3 minutes (R3) and 60 minutes (R60) were measured. Since, in the double-tract reconstruction, a fraction of the food passed through the residual stomach and duodenum, and the other fraction entered directly into the small intestine, the parameter of R3 corresponds to the fractions of the physiologic duodenal pathway and shortcut pathway to the jejunum. The half-time (min) of the residual stomach was calculated by mono-exponential fitting from 3 to 60 minutes, using the value of the  $\ln(2)/\text{decay constant}$ . This value was defined as the gastric emptying time (GET). The lag time of food in the stomach just after ingestion was not observed by our study condition. Thus, an early drop in count just after ingestion by direct passage from the esophagus to the jejunal direction was not included for the half-time calculation of the stomach.

**Table 1** Bile transit and relationship to food transit

Group	Control patients	Double-tract operation	p value
Number of patients	9	10	
Bile reflux to residual stomach			
no	5 (56%)	8 (80%)	n.s.
slight	3 (33%)	1 (10%)	
severe	1 (11%)	1 (10%)	
Transit of foods			
normal	8 (89%)	3 (30%)	0.0094
rapid*	1 (11%)	7 (70%)	
Mixture of bile and foods			
good	9 (100%)	5 (50%)	0.014
food preceding	0 (0%)	5 (50%)	
bile preceding	0 (0%)	0 (0%)	

\*defined as R3 < 50% and/or GET < 20 min



**Fig. 3** Retention fractions in the stomach at 3 minutes and 60 minutes (*left*), and at gastric emptying half-time (*right*). Bars denote the standard deviation.

The bile reflux into the residual stomach was visually assessed and classified into no reflux, slight reflux and severe reflux. The mixture of the bile and food was visually evaluated during the 30 to 60 minute period after ingestion, because passage of a portion of the foods preceded the bile just after ingestion in most of the post-operative patients.

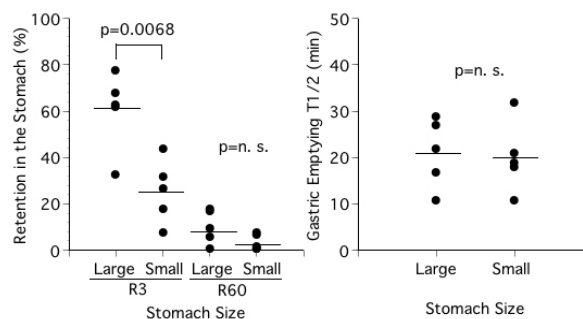
#### Statistics

The data were expressed as an average  $\pm$  standard deviation. Differences in the variances and means were evaluated by F test and student t test. The difference of the contingency table was examined by chi-square test. A p value < 5% was considered significant.

## RESULTS

#### Crosstalk between $^{111}\text{In}$ and $^{99\text{m}}\text{Tc}$

Using 10 ml syringes, the crosstalk fraction of  $^{99\text{m}}\text{Tc}$  in the



**Fig. 4** Comparison of the R3, R60 (*left*) and gastric emptying time (*right*) in patients with a large and small residual stomach. Horizontal lines indicate mean values.

$^{111}\text{In}$  window was 1.2%, and that of  $^{111}\text{In}$  in the  $^{99\text{m}}\text{Tc}$  window was 5.1%. In a clinical study, the liver count of the initial 3-minute image in the  $^{111}\text{In}$  window was only 0.1 count/pixel. Conversely, the stomach was not at all or only faintly observed in the  $^{99\text{m}}\text{Tc}$  window. The background corrected stomach count in the  $^{99\text{m}}\text{Tc}$  window ranged from 3–15% (average 8%). Thus, by observing the shape of the distribution of  $^{111}\text{In}$ -mixed food, the bile reflux was clearly differentiated by the crosstalk from  $^{111}\text{In}$  DTPA.

#### Preoperative versus double-tract reconstruction groups

Typical examples of two patients with normal and rapid gastric emptying time are shown in Figure 2. Time-activity curve patterns of these patients in Figure 2C showed significant differences particularly just after ingestion. Figure 3 shows the differences of R3, R60 and GET between the preoperative and double-tract reconstruction groups. The value of R3, the retention fraction just after ingestion, was significantly lower in the double-tract reconstruction group than in the preoperative group ( $43.3\% \pm 23.4\%$  vs.  $90.4\% \pm 7.9\%$ ,  $p < 0.001$ ). The value of R60, the late retention fraction, was also significantly

lower in the double-tract reconstruction group than in the preoperative group ( $7.1\% \pm 6.4\%$  vs.  $29.6\% \pm 7.1\%$ ,  $p < 0.001$ ). GET differed significantly between the double-tract and preoperative groups ( $20.7 \text{ min} \pm 7.1 \text{ min}$  and  $36.2 \text{ min} \pm 11.0 \text{ min}$ ,  $p = 0.0018$ ). Regarding bile reflux to the stomach, 1 of 9 patients in the preoperative group and 1 of 10 patients in the double-tract group showed significant reflux ( $p = \text{n.s.}$ ) as shown in Table 1. The mixture of food and bile was good in all preoperative patients, but food preceded bile in 5 of 10 patients in the double-tract reconstruction group ( $p = 0.014$ ). When rapid gastric emptying was defined as  $R3 < 50\%$  and/or  $\text{GET} < 20$  minutes, 1 of 9 patients in the preoperative group and 7 of 10 patients in the double-tract group showed a rapid passage pattern ( $p = 0.0094$ ).

When the residual stomach was divided into two groups, namely those with large ( $n = 5$ ) and small sizes ( $n = 5$ ), intervals between operation and nuclear study were  $2.74 \pm 1.28$  years and  $3.54 \pm 2.11$  years, respectively ( $p = \text{n.s.}$ ). The GET did not differ significantly between the two groups ( $21.2 \pm 7.4 \text{ min}$  vs.  $20.2 \pm 7.6 \text{ min}$ ,  $p = \text{n.s.}$ ), and the difference in R60 did not reach statistical significance either ( $10.4\% \pm 7.2\%$ , vs.  $3.8\% \pm 3.4\%$ ,  $p = 0.10$ ,  $\text{n.s.}$ ). However, R3 in the double-tract group was significantly lower in patients with a small residual stomach compared to patients with a large residual stomach ( $25.8\% \pm 13.7\%$  vs.  $60.8\% \pm 16.8\%$ ,  $p = 0.0068$ ), although the number of patients was limited (Fig. 4). The rapid passage pattern of foods was observed more often in the small residual stomach group (5 of 5) than in the large stomach group (2 of 5) ( $p = 0.038$ ). Mixture of foods and bile was good in only 1 of 5 patients with a small residual stomach, but was good in 4 of 5 patients with a large residual stomach ( $p = 0.058$ ). The degree of bile reflux to the residual stomach did not differ significantly between the two groups. Figure 2 shows the difference in the bile and food mixture between two patients with large and small residual stomachs.

## DISCUSSION

Gastric emptying scintigraphy with an intestinal transit study provides noninvasive and quantitative assessment of physiological transit throughout the gastrointestinal tract, and is extremely useful for diagnosing gastrointestinal motor dysfunction.<sup>1-3</sup> This is particularly true for evaluating post-operative changes associated with motility dysfunction. The present study demonstrated gastric emptying of the residual stomach and the fraction of physiologic gastric and intestinal passages. We found also that the residual stomach size was an important factor for the optimal passage of food into the intestine. The physiologic mixture pattern of bile and food in the small intestine could also be evaluated by dual-radionuclide acquisition.

It has been reported that anatomic and physiological

changes introduced by gastric surgery result in postgastrectomy syndromes in approximately 20% of patients. Most of these disorders are caused by operation-induced abnormalities including disturbances in the gastric reservoir function and transport function, division of the vagal innervation and bypass of the pylorus.<sup>5</sup> Another problem is a post-operative change in the bile flow, which is caused by alterations of anatomy and regulation of bile excretion. Bile-induced esophagitis may be present in patients after, for example, total gastrectomy, depending on the operative procedure. Thus, gastrointestinal and hepatobiliary nuclear studies play an important role in the understanding of the pathophysiology in these patients.

### *Feasibility of dual-energy acquisition*

The present study demonstrated the validity of a dual-energy acquisition. Application of the dual-isotope method in the digestive system was originally performed using  $^{99\text{m}}\text{Tc}$  iminodiacetic acid derivative as hepatobiliary imaging and  $^{111}\text{In}$  oxine labeled eggs as the solid food marker for gastric emptying.<sup>1,6</sup> This test was considered to be important for post-gastrectomy patients with chronic post-prandial symptoms, including patients with bile reflux gastritis. However, few studies have attempted dual-energy acquisition, and the validity of a dual-nuclide study has not been well defined technically and clinically. By our acquisition condition, down scatter from the  $^{111}\text{In}$  to  $^{99\text{m}}\text{Tc}$  window is only 5% in the syringe and averages 8% in clinical studies. Although the down scatter from the  $^{111}\text{In}$  activity to hepatobiliary images is not negligible, the very faint stomach activity seen in the hepatobiliary imaging did not interfere with the diagnosis of bile reflux. The calculation of gastric emptying time was not significantly influenced by the crosstalk fraction. Moreover, simultaneous assessment of bile and food is convenient for complete agreement of anatomical location when both images are superimposed. Although a single-isotope two-day method for a bile and food study has been developed using only  $^{99\text{m}}\text{Tc}$ ,<sup>7</sup> differences in each anatomical region may take place on separate days.

### *Operative procedures and evaluation by nuclear methods*

Various surgical procedures have been developed to achieve better physiology of gastrointestinal function and improvement in post-operative quality of life. The procedures include Billroth I and II methods, Roux-en-Y method, and proximal gastrectomy with the double-tract or jejunal interposition method, and radionuclide studies have been used to evaluate gastrointestinal motility disorder.<sup>8-11</sup> Based on gastric emptying studies after total or partial gastrectomy, both slow emptying patterns after vagotomy and rapid emptying patterns that correspond to dumping syndrome have been demonstrated. Emptying of solids after total gastrectomy with pouch reconstruction was also investigated.<sup>12</sup> It was found that dumping was more common in the Roux-en-Y group, and that jejunal pouch

reconstruction after total gastrectomy delays passage of solid food in the upper intestine compared with Roux-en-Y reconstruction.

Antrum- or pylorus-preserving procedures have been developed as a more physiologic procedure and studied by Japanese investigators.<sup>4,13-16</sup> This method was originally designed to provide smooth transfer of foods into the jejunum through the duodenal and bypass tracts.<sup>4</sup> Compared with direct esophago-gastric anastomosis after proximal gastrectomy, the interposed jejunum could prevent esophageal reflux of gastric juice. In addition, slow emptying or stasis of foods in the residual stomach caused by vagotomy may be alleviated by directly shifting a part of food into the jejunum. And our preliminary study has indicated that double-tract reconstruction had several advantages over total gastrectomy, because of easy post-operative endoscopic examination of the residual stomach, and less frequent complication of esophagitis and patients' symptoms.<sup>17</sup> However, physiologic changes in the actual passage have not been evaluated quantitatively. Another study investigated the recovery course of gastric emptying after Billroth I pylorus-preserving pancreatoduodenectomy, and found that gastric emptying was delayed but returned to the preoperative level within 6 months after surgery.<sup>14</sup> Sato et al. compared pylorus-preserving operation procedures by conducting a gastric emptying study.<sup>16</sup> The mean gastric emptying half-time in the upright position after conventional Imanaga pancreatoduodenectomy was significantly shorter than after pylorus-preservation using the Imanaga method.

#### *Bile and food passage and mixing*

Since radiolabeled bile was examined in this study, the timing of delay for food administration was important. We waited for visualization of the common bile duct by observing <sup>99m</sup>Tc PMT distribution, which was usually seen within 15 minutes after intravenous injection, after which the food was given. The timing of food ingestion was delayed when the passage of the bile was slow. Even if the timing of the food ingestion was slightly early or delayed to the optimal time, we could observe changes in the distribution pattern with time. Although non-radioactive bile transit may be present before the arrival of radioactive bile, general transit patterns of the bile and foods could be evaluated without any problem.

It is noteworthy that the rate of retention was correlated to the size of the residual stomach, although it has been reported that there was no preferential passage via the duodenum or jejunum after double-tract reconstruction.<sup>9</sup> In the double-tract reconstruction group, 70% of the patients showed rapid passage of foods either by initial direct passage into the jejunum or rapid gastric emptying. The mixture of food was good in half of the patients. Considering the speed of the passage, we found that the large size of the residual stomach was an important factor for optimal retention and mixing of food and bile. Since

the gastric emptying time of the large and small residual stomachs did not differ significantly in the present study, and vagal nerves were dissected in both conditions, the food passage seems to depend on the gastric reservoir size and the existence of the bypass tract. One study compared biliary and gastrointestinal function after pancreatobiliary surgery, and found that asynchrony of bile and food passage had a significant inverse correlation with recovery of bodyweight.<sup>7</sup>

#### *Limitations*

We could not select true control subjects for this study. However, since the purpose of this study was to evaluate modification of the gastric size, route of passage and innervation, we could compare the changes after this operation procedure with the preoperative condition. Moreover, since all of the gastric cancers were in the early stage, gastric dysmotility was unlikely to have been significantly present in the pre-operative condition. The severity of patients' abdominal symptoms after surgery could not be evaluated quantitatively. Grading or scoring of the symptoms should be desirable in the future studies.

In addition, although we used a semi-liquid enteral nutrition meal because of steady preparation, a solid meal may be preferable to evaluate the physiologic food transit. However, since various types of solid meal have been used and the normal transit time varies significantly, and is also affected by the caloric content of the meal and its composition of total fats, triglycerides and carbohydrates,<sup>18</sup> standardization of the solid meal would be desirable.

The main purpose of this study is not to show directly the superiority of the double-tract method in comparison with various possible surgical procedures. We would like to emphasize that the method is applicable to various post-operative conditions, particularly when routes of digestive tracts are modified as well as when innervation conditions and reservoir function are altered.

## CONCLUSION

In proximal gastrectomy patients with early gastric cancer, post-operative changes of gastric and intestinal passages could be evaluated using a double-tract reconstruction technique. Simultaneous evaluation of bile excretion and mixture with food was feasible using a radionuclide method. A dual-isotope study would be an option to evaluate gastrointestinal physiologic alteration after a specific operation procedure, particularly when the routes of bile and food, innervation and reservoir function are modified.

## REFERENCES

1. Parkman HP, Miller MA, Fisher RS. Role of nuclear medicine in evaluating patients with suspected gastrointestinal motility disorders. *Semin Nucl Med* 1995; 25: 289-305.

2. Chaudhuri TK, Fink S. Gastric emptying in human disease states. *Am J Gastroenterol* 1991; 86: 533–538.
3. Pellegrini CA, Broderick WC, Van Dyke D, Way LW. Diagnosis and treatment of gastric emptying disorders. Clinical usefulness of radionuclide measurements of gastric emptying. *Am J Surg* 1983; 145: 143–151.
4. Aikou T, Natsugoe S, Shimazu H, Nishi M. Antrum preserving double tract method for reconstruction following proximal gastrectomy. *Jpn J Surg* 1988; 18: 114–115.
5. Eagon JC, Miedema BW, Kelly KA. Postgastrectomy syndromes. *Surg Clin North Am* 1992; 72: 445–465.
6. Tolin RD, Malmud LS, Stelzer F, Menin R, Makler PT Jr, Applegate G, et al. Enterogastric reflux in normal subjects and patients with Billroth II gastroenterostomy. Measurement of enterogastric reflux. *Gastroenterology* 1979; 77: 1027–1033.
7. Sato T, Konishi K, Yabushita K, Kimura H, Maeda K, Tsuji M, et al. A new examination for both biliary and gastrointestinal function after pancreatobiliary surgery—single-isotope two-day method. *Hepatogastroenterology* 2000; 47: 140–142.
8. Maes BD, Hiele MI, Geypens BJ, Ghoo YF, Rutgeerts PJ. Gastric emptying of the liquid, solid and oil phase of a meal in normal volunteers and patients with Billroth II gastrojejunostomy. *Eur J Clin Invest* 1998; 28: 197–204.
9. Fujiwara Y, Kusunoki M, Nakagawa K, Tanaka T, Yamamura T, Utsunomiya J. Scintigraphic assessment of double tract reconstruction after total gastrectomy. *Dig Surg* 1998; 15: 404–409.
10. Kotoura Y, Takahashi T, Ishikawa Y, Ashida H, Hashimoto N, Nishioka A, et al. Hepatobiliary and gastrointestinal imaging after pancreaticoduodenectomy—a comparative study on Billroth I and Billroth II reconstructions. *Jpn J Surg* 1990; 20: 294–299.
11. Adachi Y, Katsuta T, Aramaki M, Morimoto A, Shiraishi N, Kitano S. Proximal gastrectomy and gastric tube reconstruction for early cancer of the gastric cardia. *Dig Surg* 1999; 16: 468–470.
12. Iivonen MK, Koskinen MO, Ikonen TJ, Matikainen MJ, Jivonen MK. Emptying of the jejunal pouch and Roux-en-Y limb after total gastrectomy—a randomised, prospective study. *Eur J Surg* 1999; 165: 742–747. Erratum in: *Eur J Surg* 1999; 165: 1104.
13. Nishikawa K, Kawahara H, Yumiba T, Nishida T, Inoue Y, Ito T, et al. Functional characteristics of the pylorus in patients undergoing pylorus—preserving gastrectomy for early gastric cancer. *Surgery* 2002; 131: 613–624.
14. Takeda T, Yoshida J, Tanaka M, Matsunaga H, Yamaguchi K, Chijiwa K. Delayed gastric emptying after Billroth I pylorus-preserving pancreaticoduodenectomy: effect of postoperative time and cisapride. *Ann Surg* 1999; 229: 223–229.
15. Hishinuma S, Ogata Y, Matsui J, Ozawa I. Evaluation of pylorus-preserving pancreaticoduodenectomy with the Imanaga reconstruction by hepatobiliary and gastrointestinal dual scintigraphy. *Br J Surg* 1999; 86: 1306–1311.
16. Sato T, Konishi K, Yabushita K, Kimura H, Maeda K, Tsuji M, et al. Long-term postoperative functional evaluation of pylorus preservation in Imanaga pancreaticoduodenectomy. *Dig Dis Sci* 2000; 45: 1907–1912.
17. Miwa K, Kinami S, Nakagawara K, Bando E, Taniguchi K, Fushida S, et al. The strategy of the surgical treatment towards gastric cancer located in the upper third of the stomach. *Gekachiryō (Surgical Therapy)* 2000; 83: 59–66. [in Japanese]
18. Mariani G, Boni G, Barreca M, Bellini M, Fattori B, AlSharif A, et al. Radionuclide gastroesophageal motor studies. *J Nucl Med* 2004; 45: 1004–1028.