

# Histological examination of frozen autograft treated by liquid nitrogen removed 6 years after implantation

メタデータ	言語: eng 出版者: 公開日: 2017-10-05 キーワード (Ja): キーワード (En): 作成者: メールアドレス: 所属:
URL	<a href="http://hdl.handle.net/2297/10490">http://hdl.handle.net/2297/10490</a>

Histological examination of frozen autograft treated by liquid nitrogen removed 6 years after implantation

YOSHIKAZU TANZAWA<sup>1</sup>, HIROYUKI TSUCHIYA<sup>1</sup>, NORIO YAMAMOTO<sup>1</sup>,  
KENSHI SAKAYAMA<sup>3</sup>, HIROSHI MINATO<sup>2</sup>, KATSURO TOMITA<sup>1</sup>

<sup>1</sup>Department of Orthopaedic Surgery, Kanazawa University School of Medicine, 13-1 Takaramachi, Kanazawa 920-8641, Japan

<sup>2</sup>Department of Pathology, Kanazawa University Hospital, Kanazawa, Japan

<sup>3</sup>Department of Orthopaedic Surgery, Ehime University School of Medicine, Ehime, Japan

Running title: frozen autograft 6 years after surgery

Offprint requests to: H. Tsuchiya, 13-1 Takara-machi, Kanazawa, 920-8641, Japan

丹沢義一 920-8641 金沢市宝町 13-1 金沢大学医学部整形外科医局

TEL: 076-265-2374 FAX: 076-234-4261 E-mail: tangiyama@yahoo.co.jp

## **Introduction**

Various methods are presently used for limb reconstruction of large bone defects following tumor excision. Concerns have arisen regarding the long-term durability of tumor prostheses due to reports of complications such as loosening and breakage. Kawai et al. reported that survival at ten years after massive prosthetic replacement of the distal femur is approximately 50%.<sup>1</sup> In Japan, since allograft is difficult to obtain because of socioreligious reasons and recycling of bone has been widely used. Several methods have been developed to reuse resected bone for reconstruction, including autoclaving,<sup>2</sup> irradiation,<sup>3</sup> pasteurization,<sup>4</sup> and freezing by liquid nitrogen.<sup>5</sup> Ideally, the grafted bone is replaced by a living bone, which then leads to permanent reconstruction. We have used frozen autograft treated by liquid nitrogen, which has a number of advantages for biological reconstruction. In this study, we investigated one frozen autograft that was removed 6 years after surgery due to a worsening gait disturbance from valgus instability of the knee. The purpose of this study was to investigate the fate of the grafted frozen bone.

## **Case report**

The patient was a 19-year-old girl who had presented six years prior with an osteosarcoma in her distal right femur. She was treated with caffeine-potentiated chemotherapy,<sup>6</sup> and which resulted in a clinically complete response. At the first operation, we excised the tumor with an intentional marginal margin.<sup>7</sup> Reconstruction was performed using an osteochondral autograft containing the tumor treated by liquid nitrogen and fixed with an intramedullary nail (Fig. 1a,b). We obtained informed consent from the patient prior to surgery regarding the advantages and disadvantages of this procedure, explaining that the use of an osteochondral graft might produce osteoarthritis in the future, which in turn could require a second operation. Six months after surgery, an additional autogenous cancellous bone graft from the host iliac bone was placed at the medial condyle of the grafted bone in order to augment a bone defect that developed after tumor curettage during the first operation. Sixteen months after surgery, collapse of the medial condyle of the femur was detected, so additional cementation was performed. We thought that this collapse was probably caused by a strength deficiency resulting from our not having utilized enough bone graft material to fill the bone defect after tumor curettage. A second possible cause of collapse in

this case was that the tumor was partly osteolytic. Two years after surgery, a roentgenogram showed bone union at the host-graft junction and no evidence of recurrence of the tumor (Fig.2a). Six years after the first surgery, the valgus deformity of the knee had gradually worsened, and the patient was experiencing gait disturbance due to severe instability of the knee joint without knee brace. A roentgenogram revealed a collapse in the grafted bone and valgus deformity (Fig.2b). We theorized that the valgus deformity was caused by heavy loading that was relatively more concentrated on the lateral condyle due to cement augmentation of the medial condyle. A bone  $^{99m}\text{Tc}$ -scintigram revealed low uptake around the grafted bone two years after the first surgery, but six years after surgery, uptake was seen on the inside of the frozen bone comparable to the host bone (Fig. 3), and we believed that the frozen autograft was revitalized. The reconstruction with the osteochondral autograft treated by liquid nitrogen provided a well-functioning and walkable limb for 6 years. However, a fourth operation was consequently performed to remove frozen bone that had osteomized 2cm distal from the junction. Reconstruction of the distal femoral bone defect was accomplished with a Howmedica Modular Resection System® (HMRS)(Fig.4). Although a surface-type knee arthroplasty for revision was planned in order to use the frozen autograft as bone stock, an adequate size was not available. Therefore, the smallest custom HMRS (extendible prosthesis) was applied and a small part of the frozen autograft was used as bone stock. She had 5cm limb-length discrepancy before surgery. We considered the possible limb-length discrepancy after surgery, so that we chose the extendible prosthesis. We did not extend it finally because the limb shortening after surgery was only 1cm. Intraoperatively, we recognized bone union at the host-graft junction, bleeding from the grafted bone and fibrillation and defect of the articular cartilage. After removal of the prosthesis and cement, the entire extirpated specimen was then embedded in paraffin, sectioned (5  $\mu\text{m}$ ), and the sections were stained with hematoxylin and eosin. Informed consent was obtained from the patient for all data submitted for publication from this case.

## Results

We evaluated whole sections of the frozen autograft (Fig5a, b). No tumor cells were detected in any of the sections. Most parts of the cortex in the diaphysis had osteocytes and microvessels, and fibrovascular tissue was present between the cortex and medullary space (Fig. 5c, x100). The

fibrovascular tissue showed an abundance of vessels, and there appeared to be more osteocytes in the cortex next to this area (Fig. 5d, x200). Surrounding osteocytes embedded in trabeculae of the subchondral bone in the epiphysis were also evident. In addition, many microvessels had invaded the bone, and the marrow was filled with fibrovascular tissue (Fig. 5e, x100). We identified focal microfractures scattered throughout the subchondral bone of the lateral condyle and predominantly fibrous union of these microfractures (Fig. 5f, x100). We were able to identify focal areas where normal chondrocytes were present within the articular surface (Fig. 5g, x100). The joint surface was almost completely covered with fibrous cartilage. A portion of the metaphysis showed osteoblasts and osteoclasts, which could represent bone remodeling (Fig. 5h, x200). From these findings, we recognized the occurrence of new bone formation not only from the cortex but also from the medullary space.

## Discussion

We previously used the autoclaved bone for the reconstruction of bone defects after tumor resection; however, autoclaved bone was deficient in dynamic strength due to the high heat (130°C) necessary for treatment and so was unacceptable as bone replacement material.<sup>2,6,7</sup> In 1999, we began using frozen autograft treated by liquid nitrogen instead of conventional autoclaved bone. The advantages of using frozen autograft are as follows; simplicity, osteoinduction, osteoconduction, a short treatment time, preservation of the cartilage matrix, perfect fit, sufficient biomechanical strength, no contagion, no need for a bone bank, easy attachment of tendons and ligaments and desirable bone stock..<sup>5</sup> Presently, oncologically sterilized autografts, including autoclaved bone, pasteurized bone, and irradiated bone are also in common use, and histological examinations have been performed in each.<sup>8,9</sup> In 2005, Hayashi et al.<sup>10</sup> analyzed a grafted distal femoral autoclaved bone twelve years after surgery. In that case, thin newly formed bone was observed covering parts of the external surface, but most of the autoclaved bone and its bone marrow were dead. In 2005, Hatano et al.<sup>11</sup> examined osteochondral autografts following extracorporeal irradiation and re-implantation to replace bone defects after tumor removal. In three of five cartilage specimens, viable chondrocytes were detected. In addition, three specimens from the subchondral region and a tendon also displayed features of regeneration. In 2004, Kubo et al.<sup>12</sup> evaluated histologically biopsy specimens harvested from pasteurized bone over 3 years after reimplantation. They

reported that the graft cortices remained totally necrotic with empty osseous lacuna, and that deposited seams of woven bone existed focally on the surface of the acellular trabeculae. On the other hand, in 2003, Watanabe et al.<sup>13</sup> reported that histological examination of a pasteurized bone removed nine months after surgery revealed evidence of osteocytes and microvascular migration into the pasteurized cortical bone.

In 2006, Sakayama et al.<sup>14</sup> reported pathological findings of an autograft containing osteosarcoma treated by liquid nitrogen retrieved because the patient died from lung metastases 2 years after implantation. An autopsy showed complete bone union and no local recurrence. Neovascularization in the cortical bone was observed in the whole pathological specimen. That report focused on the short-term appearance of grafted bone, and had no references to osteogenesis. Our report is the first study to evaluate histologically a whole frozen bone resected from a live woman rather than from an autopsy, and which had been viable for 6 years after implantation. In our case, the grafted bone had no tumor cells, and displayed osteocytes and microvessels in all portions of the bone. In addition, the frozen bone displayed newly formed bone in most portions, and osteogenesis was observed next to fibrovascular tissue in particular. We were not able to evaluate the bone union histologically at the junction of the grafted bone and the proximal femur, but were able to confirm good bone fusion during the operation both macroscopically and radiographically<sup>15</sup>.

Bone scintigraphy using a <sup>99m</sup>Tc-biphosphonate compound is a suitable method for assessing bone incorporation of the bone graft. Van Laere et al.<sup>16</sup> observed partial tracer uptake in the graft in 72% of cases at an average of 19.6 months and diffuse uptake indicating complete revascularization in 24% of cases at an average of 31.4 months. Ehara et al.<sup>17</sup> reported the scintigraphic features of the pasteurized bone, and this pattern of change in uptake is similar to that seen in the pasteurized autograft. In the frozen autograft, a rim of increased uptake was first observed on the surface of the cortex as newly formed microvessels became active, and then the uptake gradually got closer to the normal bone as bone incorporation advanced. We believe that the uptake in the graft becomes equal to that in the normal bone at the time when bone incorporation is completed. It has been reported that the uptake in a pasteurized bone five years after operation was not equal to that in the normal bone, and that a significant amount of time is necessary until remodeling is completed.<sup>18</sup> However, in one other case, at 4 years and 6 months

after the operation, the frozen bone showed similar uptake to the normal bone (data not shown), and it was thought to completely replace the normal bone. Thus, in this study, bone remodeling and revitalization occurred in the frozen bone earlier than in other methods.

Watanabe et al.<sup>13</sup> analyzed pasteurized medullary bone, and demonstrated that fibrous tissue migration into the medullary space instead of adipose tissue, and that new bone formation occurred inside or adjacent to this fibrous tissue. These results suggest that the first step in bone formation in pasteurized bone might be the migration of mesenchymal stem cells existing in the continuous normal medullary cavity which may induce the formation of cancellous bone and cortical bone formation from inside. In our case, new bone formation was observed inside or adjacent to fibrovascular tissue, suggesting that the system of bone formation in the frozen autograft had occurred similar to pasteurized bone. In this study, we were able to confirm the presence of normal chondrocytes in the articular surface after completion of liquid nitrogen treatment. This observation is puzzling because previous studies have demonstrated that liquid nitrogen treatment leads to chondrocyte disappearance.<sup>19</sup> Moreover, it is difficult to imagine how chondrocytes could survive after liquid nitrogen treatment and be retained on the surface. Chondrocyte regeneration is a possible theoretical explanation, but the mechanism of regeneration is not clear. However, a more likely source for these new chondrocytes would be synovium-derived stem cells, which are known to have chondrogenic differentiation potency, as they are capable of generating chondrocytes for cartilage repair.<sup>20</sup> However, in 2 other patients with chondrosarcoma, we were able to confirm necrosis of tumor cells in frozen autograft was retrieved 2 months and 5 months after surgery, respectively (data not shown).

Collapse of subchondral bone is a possible complication of osteoarticular autografts for weight-bearing joints. Collapse appears to be more likely to occur when the tumor is large in size or osteolytic. Based on our experience, we believe that augmenting internal fixation with bone cement or calcium phosphate cement as well as with autogenous bone grafts is important when the bone defect is massive and strength deficiency seems more likely to occur. Based on this case, we concluded that frozen autograft may be considered one of the most useful materials for biological reconstructions. We expect its engraftment will engender more vitalization, revascularization and remodeling over the long-term course.

## References

1. Kawai A, Muschler GF, Lane JM, Otis JC, Healy JH. Prosthetic knee replacement after resection of a malignant tumor of the distal part of the femur: medium to longterm results. *J Bone Joint Surg Am* 1998;80-A:636-47.
2. Asada N, Tsuchiya H, Kitaoka K, Mori Y, Tomita K. Massive autoclaved allografts and autografts for limb salvage surgery. A 1-8 year follow-up of 23 patients. *Acta Orthop Scand* 1997;68:392-5.
3. Araki N, Myoui A, Kuratsu S, Hashimoto N, Inoue T, Kudawara I, et al. Intraoperative extracorporeal autogenous irradiated bone grafts in tumor surgery. *Clin Orthop* 1999;368:196-206.
4. Manabe J, Kawaguchi N, Matsumoto S. Pasteurized autogenous bone graft for reconstruction after resection of malignant bone and soft tissue tumors: imaging features. *Semin Musculoskelet Radiol* 2001;5:195-201.
5. Tsuchiya H, Wan SL, Sakayama K, Yamamoto N, Nishida H, Tomita K. Reconstruction using an autograft containing tumour treated by liquid nitrogen. *J Bone Joint Surg Br* 2005;87:218-25.
6. Tsuchiya H, Tomita K, Mori Y, Asada N, Morinaga T, Kitano S, et al. Caffeine-assisted chemotherapy and minimized tumor excision for nonmetastatic osteosarcoma. *Anticancer Res* 1998;18:657-66.
7. Tsuchiya H, Tomita K, Mori Y, Asada N, Yamamoto N. Marginal excision for osteosarcoma with caffeine assisted chemotherapy. *Clin Orthop* 1999;358:27-35.
8. Johnston JO, Harries TJ, Alexander CE, Alexander AH. Limb salvage procedure for neoplasms about the knee by spherocentric total knee arthroplasty and autogenous autoclaved bone grafting. *Clin Orthop* 1983;181:137-45.
9. Yamamoto N, Tsuchiya H, Nojima T, Sumiya H, Tomita K. Histological and radiological analysis of autoclaved bone 2 years after extirpation. *J Orthop Sci* 2003;8:16-9.
10. Hayashi K, Tsuchiya H, Yamamoto N, Minato H, Tomita K. Histological examination of autoclaved bone removed 12 years after it was transplanted. *J Orthop Sci* 2005;10:425-9.
11. Hatano H, Ogose A, Hotta T, Endo N, Umezu H, Morita T. Extracorporeal irradiated autogenous osteochondral graft: a histological study. *J Bone Joint Surg Br* 2005;87:1006-11.
12. Kubo T, Sugita T, Shimose S, Arihiro K, Tanaka H, Nobuto H. et al. Histological findings in a



- human autogenous pasteurized bone graft. *Anticancer Res* 2004;24:1893-6.
13. Watanabe H, Ahmed AR, Shinozaki T, Yanagawa T, Terauchi M, Takagishi K. Reconstruction with autologous pasteurized whole knee joint II : application for osteosarcoma of the proximal tibia. *J Orthop Sci* 2003;8:180-6.
  14. Sakayama K, Tsuchiya H, Fujiubuchi T, Kidani T, Tanji N, Yamamoto H. Pathological findings of an autograft containing osteosarcoma treated by liquid nitrogen retrieved 2years after implantation. *J Orthop Sci* 2006;11:655-6.
  15. Tanzawa Y, Tsuchiya H, Yamamoto N, Yamauchi K, Takeuchi A, Tomita K. Histological examination of frozen autograft removed from the patient of osteosarcoma 6 years after it was transplanted. *Cent. Jpn. J. Orthop. Traumat* 2007;50:9-10 (in Japanese).
  16. Van Laere K, Casier K, Uyttendaele D, Mondelaers W, De Sadeleer C, Simons M, et al. Technetium-99m-MDP scintigraphy and long-term follow-up of treated primary malignant bone tumors. *J Nucl Med* 1998;39:1563-9.
  17. Ehara S, Nishida J, Shiraishi H, Tamakawa Y. Pasteurized intercalary autogenous bone graft: radiographic and scintigraphic features. *Skeletal Radiol* 2000;29:335-9.
  18. Manabe J, Kawaguchi N, Matsumoto S. Limb salvage surgery, pasteurized autogenous bone grafting. *J Jpn Orthop Assoc* 2004;78:146-52 (in Japanese).
  19. Yamamoto N, Tsuchiya H, Tomita. Effects of liquid nitrogen treatment on the proliferation of osteosarcoma and the biomechanical properties of normal bone. *J Orthop Sci* 2003;8:374-80.
  20. Sakaguchi Y, Sekiya I, Yagishita K, Muneta T. Comparison of human stem cells derived from various mesenchymal tissues : Superiority of synovium as a cell source. *Arthritis Rheum* 2005;8:2521-9.

## Figure Legends

### Figure 1

- a.** The distal femur showing the frozen autograft. An intramedullary nail was used for osteosynthesis at the junction of the host and graft bone.
- b.** The osteochondral autograft after freezing by liquid nitrogen.

### Figure 2

- a.** The roentgenogram shows bone union at the junction. Cancellous bone and bone cement were grafted at the medial condyle of the right distal femur.
- b.** The roentgenogram shows severe valgus deformity of the right knee joint.

### Figure 3

- a.** Bone scintigraphy( $Tc^{99m}$ ) revealed a rim of increased uptake on the surface of the cortex, and uptake is poor within the frozen autograft.
- b.** Uptake on the inside of the frozen is comparable to the host bone.

### Figure 4

The frozen autograft was removed and the distal femur was reconstructed using the Howmedica Modular Resection System<sup>®</sup>. The diameter of the femoral and tibial stem are 10mm and the length of the femoral component is 13cm.

### Figure 5

- a.** The frozen autograft was osteomized at 2cm distal from the junction and extirpated(x40). **b.** The extirpated frozen autograft was sliced sagittally, and whole sections were stained with hematoxylin and eosin for evaluation. **c.** Most portions of the cortex in the diaphysis showed osteocytes and microvessels(x100). **d.** Fibrovascular tissue inside the cortex had an abundance of vessels and there seemed to be more osteocytes in the cortex next to this area(x200). **e.** Many osteocytes and microvessels are observed in the trabeculae of the subchondral bone in the epiphysis(x100). **f.** Microfractures were present in the subchondral bone of the lateral condyle, and the spaces between bone fragments were filled with fibrovascular tissue (x100). **g.** Some normal chondrocytes appear in spots in the articular surface. The joint surface was almost covered with fibrous cartilage(x100). **h.** A portion showing osteoblast and osteoclast in the metaphysis. Osteogenesis is evident in the distal femur(x200).

# Figures

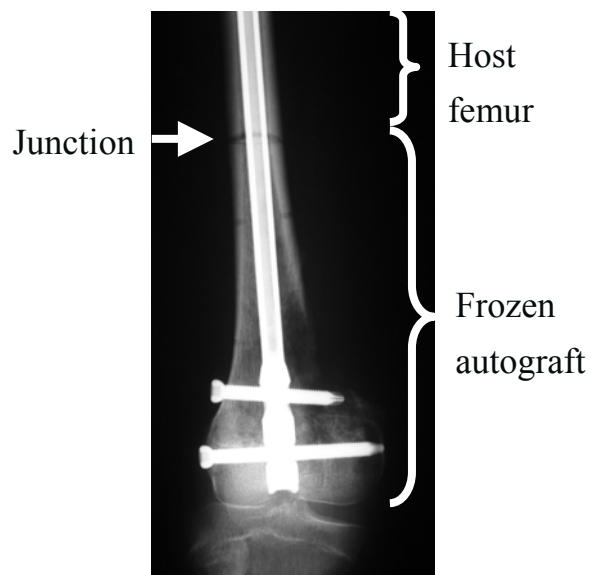


Fig. 1a

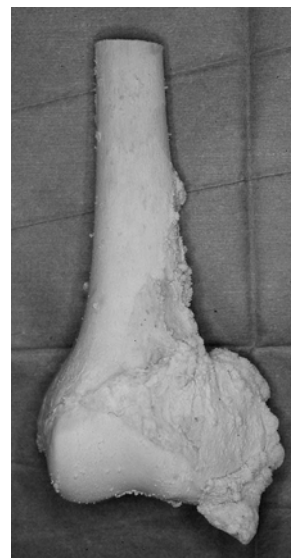

Fig. 1b

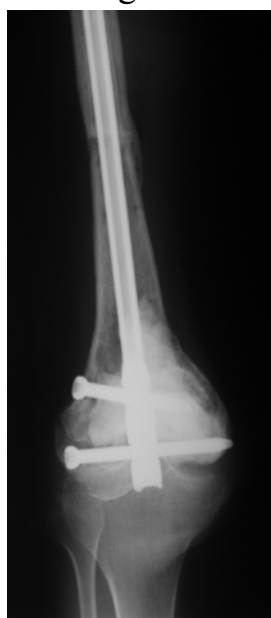

Fig. 2.a

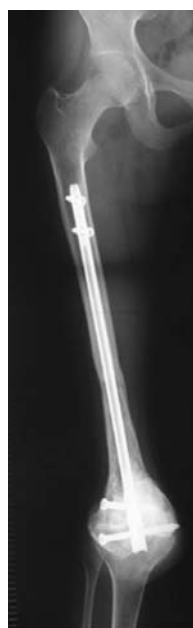

Fig. 2.b

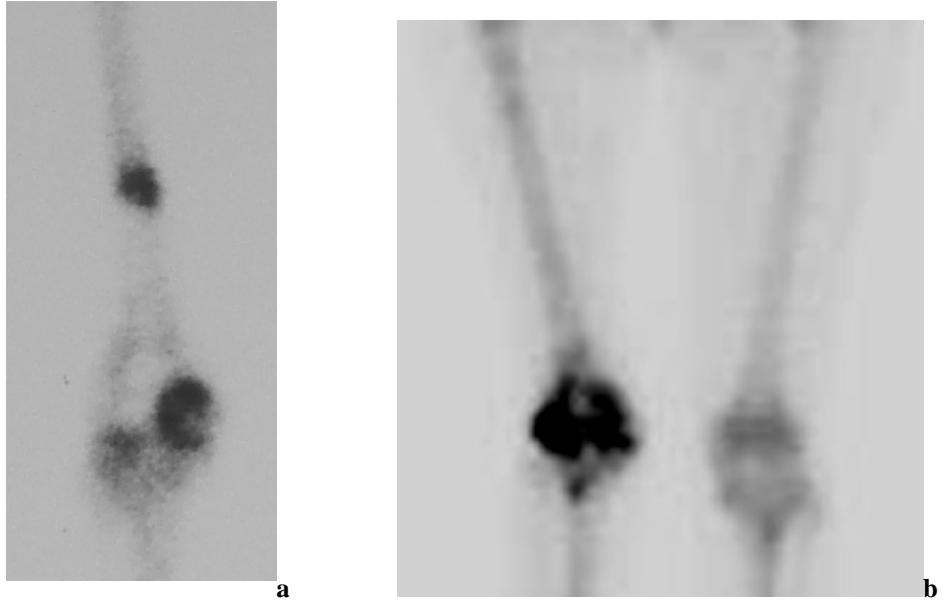



Fig. 3

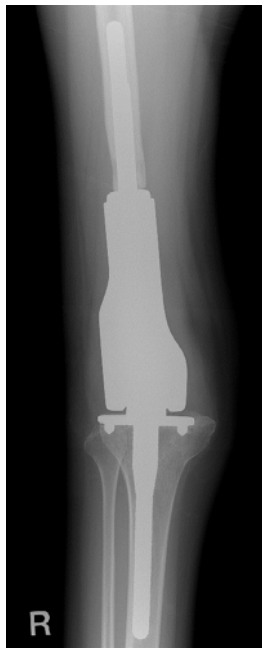
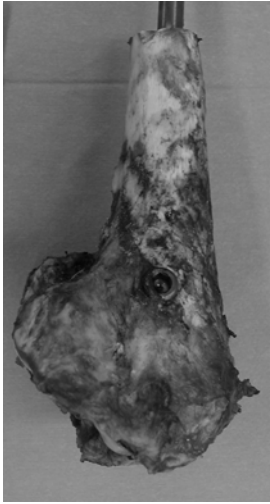


Fig. 4



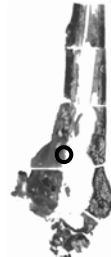
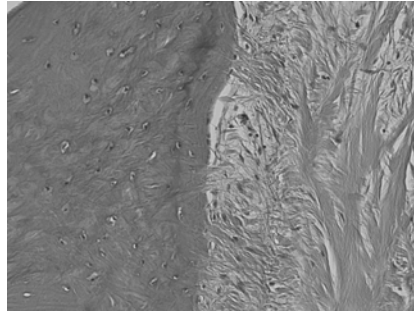
a



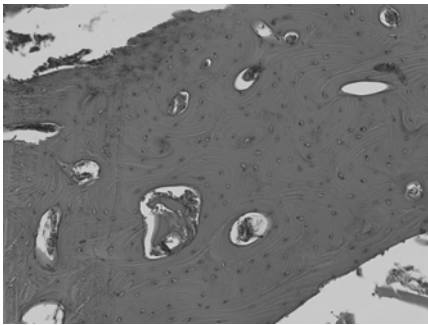
b



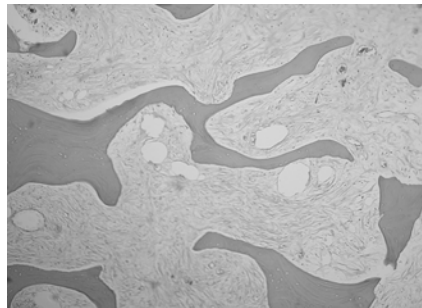
c



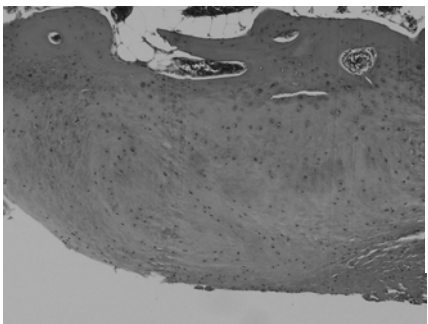
d




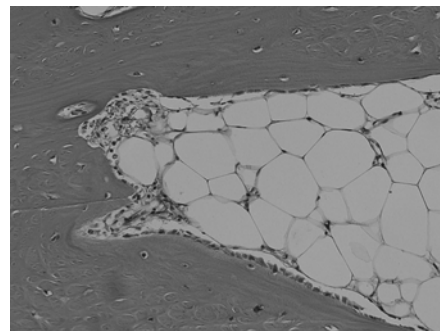
e



f



g



h

**Fig. 5**