Diagnostic utility of 123I-BMIPP imaging in patients with Takotsubo cardiomyopathy

メタデータ	言語: English 出版者: 公開日: 2017-10-05 キーワード (Ja): キーワード (En): 作成者: Matsuo, Shinro, Nakajima, Kenichi, Kinuya, Seigo, Yamagishi, Masakazu メールアドレス: 所属:
URL	http://hdl.handle.net/2297/36518

Diagnostic utility of ^{123}I-BMIPP imaging in patients with Takotsubo cardiomyopathy

Shinro Matsuo (MD, PhD, FJCC)[1], Kenichi Nakajima (MD, PhD, FJCC)[1], Seigo Kinuya (MD, PhD)[1], Masakazu Yamagishi (MD, PhD, FJCC)[2]

[1]Department of Nuclear Medicine, Kanazawa University Hospital, Kanazawa, Japan

[2]Department of Cardiovascular Medicine, Kanazawa University Graduate School of Medical Science, Kanazawa, Japan

Mailing address: Shinro Matsuo, MD, PhD, FJCC, Department of Nuclear Medicine
Kanazawa University Hospital, 13-1 Takara-machi
Kanazawa 920-8641, Japan

E-mail: smatsuo@nmd.m.kanazawa-u.ac.jp

Key words: diagnosis, Takotsubo cardiomyopathy, BMIPP, ischemia, nuclear imaging

Abstract

Objective: Takotsubo cardiomyopathy is a heart syndrome with an acute onset defined by chest symptoms, ST segment elevation on electrocardiograms. Patients with Takotsubo cardiomyopathy are sometimes misdiagnosed as having acute myocardial infarction (AMI). Therefore non-invasive diagnostic method needed to be established for setting up appropriate strategies. The purpose of this study was to detect myocardial metabolic abnormalities and to determine the diagnostic usefulness of ^{123}I-BMIPP imaging in patients with Takotsubo cardiomyopathy. ***Methods and results:*** We examined 16 patients with Takotsubo cardiomyopathy and 12 with AMI in the left anterior descending artery lesion. All patients were studied with resting ^{123}I-BMIPP imaging. Total defect score (TDS) of ^{123}I-BMIPP and perfusion were semi-quantitatively determined with SPECT imaging using a 17-segment 5-point model. TDS of ^{123}I-BMIPP were 4.8±2.7 in patients with Takotsubo cardiomyopathy and 22.4±10.7 in AMI. The ratio of summed BMIPP defect score of non-apical to apical segments in Takotsubo cardiomyopathy was smaller than that of the patients with AMI (0.1±0.1 vs. 1.1±0.7, $p<0.0001$), indicating ^{123}I-BMIPP abnormalities were exclusively observed in apical area. The ratio of summed perfusion defect scores of non-apical to apical segments in Takotsubo cardiomyopathy did not differ significantly from that of AMI (0.52±0.6 vs. 0.57±0.3, p=NS). Summed BMIPP defect score in apical area of Takotsubo cardiomyopathy was larger than that of perfusion defect score (3.9±2.7 vs. 1.8±1.8, p=0.04). ***Conclusion:*** Impaired metabolic metabolism exclusively in apical region was observed by ^{123}I-BMIPP SPECT images in Takotsubo cardiomyopathy. These typical metabolic SPECT features of the disease can be utilized on differential diagnosis of Takotsubo cardiomyopathy.

Introduction

Recent reports have described a reversible left ventricular dysfunction with symptoms similar to those of acute myocardial infarction but without coronary artery lesions even during the acute phase with ST segment elevation [1-2]. This dysfunction, known as 'Takotsubo cardiomyopathy' (transient left ventricular apical ballooning), characteristically resolves within a few weeks [3-4]. The Japanese word "Takotsubo" means an octopus fishing pot with a round bottom and a narrow neck. Patients with Takotsubo cardiomyopathy are sometimes misdiagnosed as having acute myocardial infarction (AMI) of left anterior descending (LAD) coronary artery [5-7]. Coronary angiography is conducted to exclude coronary artery disease [8]. Noninvasive diagnostic method is needed to set up appropriate strategies in patients with Takotsubo cardiomyopathy. Furthermore its origin and detailed clinical features of this disease remain unknown [9].

Myocardial fatty acid metabolic imaging with ^{123}I-beta-methy-iodophenyl pentadecanoic acid (BMIPP) has been used for the evaluation of various cardiac diseases such as ischemic heart disease [10-11], dilated or hypertrophic cardiomyopathies [12]. Several reports showed that ^{123}I-BMIPP was superior to perfusion imaging for detecting myocardial damage of patients with ischemic heart disease or cardiomyopathy [12-13]. However, few studies have reported in detail on the diagnosis and the metabolism in Takotsubo cardiomyopathy in comparison with AMI [14-15].

We analyzed clinical and radionuclide imaging data, including metabolic imaging in patients with Takotsubo cardiomyopathy in an attempt to detect myocardial metabolic abnormalities and to determine the diagnostic usefulness of ^{123}I-BMIPP imaging in patients with Takotsubo cardiomyopathy.

Methods

Patient Characteristics

The subjects included 16 patients with Takotsubo cardiomyopathy and 12 patients with AMI of LAD. All patients admitted to our hospital and underwent ^{123}I-BMIPP scintigraphy during hospitalization. Study subjects had Takotsubo-like left ventricular dysfunction, and were hospitalized at our university hospital. All patients were clinically diagnosed with Takotsubo-like left ventricular (LV) dysfunction according to the

following criteria: (1) LV wall motion abnormality mainly at the apex, (2) sudden occurrence of heart failure. (3) absence of coronary artery disease on coronary angiography, (4) complete normalization of the LV dysfunction within a few weeks [13]. For comparison, the subjects include the patients with AMI who admitted to hospital with a diagnosis of the first anterior AMI. Each patient successfully underwent percutaneous coronary intervention and obtained good coronary flow. All of the patients had culprit lesions in the proximal LAD, and only patients with single-vessel were enrolled in this study.

The study was summarized retrospectively and was approved by our institutional ethics committee.

^{123}I-BMIPP Imaging

^{123}I-BMIPP at a dose of 111 MBq was injected slowly through the antecubital vein at rest after a 3-hour fast. The SPECT data was obtained approximately 20 minutes after injection. A wide field-of-view dual-head detector camera (Symbia T6, Siemens Co. Tokyo, Japan) equipped with a low-medium-energy, general-purpose collimator without X-ray-based attenuation correction [16]. Thirty-two images were obtained for 40 seconds in each 6˚ interval. Image reconstruction was performed with a nuclear medicine computer system (Siemens Co. Tokyo, Japan) by means of a filtered back-projection algorithm without attenuation correction. Short-axis, the vertical long-axis, and the horizontal long-axis slices, each 6 mm thick were reconstructed.

Myocardial perfusion Imaging

Myocardial perfusion study was performed at rest using 740MBq of ^{99m}Tc-labelled sestamibi or tetrofosmin. Electrocardiography-gated SPECT images were acquired with a 64x64 matrix, 6˚ step and 360˚ rotation.

Data Analysis:

Segmental uptake of ^{123}I-BMIPP was quantified using semi-quantitative scores by QPS software (Cedars Sinai Medical Center, LA, USA) and was confirmed by two experienced nuclear cardiologists. A 17-segment model of left ventricle was used with a 5-point scale (0= normal uptake, 1 = mildly-reduced uptake, 2 = moderately-reduced uptake, 3 = severely-reduced uptake and 4 = no uptake) (Figure1). The sum of 17

segments was defined as total defect score (TDS). BMIPP TDS were calculated by adding the scores of 17 segments on the ^{123}I-BMIPP rest images, reflecting the severity of impaired fatty acid metabolism. The perfusion TDS was similarly calculated for perfusion studies, reflecting the severity of impaired myocardial perfusion. Apical summed defect score was defined as summed score of segments 13-17, and non-apical summed defect score as summed score of segments 1-12. A mismatch score between perfusion and ^{123}I-BMIPP was calculated by subtracting perfusion TDS from BMIPP TDS. A mismatch between perfusion and BMIPP was defined to exist when mismatch score is 2 or more.

Statistical analysis

All values are presented as mean values ± standard deviation. To examine differences between groups, t-test and non-parametric analysis as Wilcoxon/Kruskal-Wallis test were used to compare the two data and p values of less than 0.05 were considered to be significant.

Results

Clinical characteristics

Table 1 shows the clinical characteristics of the study subjects with Takotsubo cardiomyopathy and AMI. Clinical features on admission in patients with Takotsubo cardiomyopathy were as follows. In a group of 16 patients with Takotsubo cardiomyopathy, 8 were men and the mean age of the group was 72±3 years, ranged in age from 55 to 85 years old. In 12 patients with AMI, 8 were men and the mean age was 67±3 years, ranged from 44 to 91 years old. Plasma levels of peak creatinine phosphokinase on admission in patients with Takotsubo cardiomyopathy were 261±337 IU/L, and 2116±1861 IU/L in AMI. The BMIPP studies were performed 11.1±2.1 days from admission in patients with Takotsubo cardiomyopathy and 14.6±2.5 days in patients with AMI.

^{123}I-BMIPP SPECT images

BMIPP TDS in patients with Takotsubo cardiomyopathy was 4.8±2.7, and 22.4±10.7 in AMI. ^{123}I-BMIPP defect score of the 17 segments of left ventricle in patients with Takotsubo cardiomyopathy and AMI are shown in Table 2.

Figure 2 depicts polar map of BMIPP and perfusion imaging, and coronary angiogram in a case of a 66 year-old male patient with Takotsubo cardiomyopathy.

Apical summed defect score were 3.9±2.7 in Takotsubo cardiomyopathy, and 10.8±5 in AMI (Table 2). Non-apical summed defect scores were 1.1±2.1 in Takotsubo cardiomyopathy, and 11.7±7.1 in AMI. BMIPP summed defect score of apical and non-apical segments were compared and the ratio of BMIPP non-apical segment to apical segment was calculated. The ratio of apical and non-apical summed BMIPP defect score of Takotsubo cardiomyopathy was smaller than that of the patients with AMI (0.1±0.1 vs. 1.0±0.1, $p<0.0001$) (Figure 3). ^{123}I-BMIPP showed reduced uptake exclusively in the apical segments of the myocardium, indicating impairment of metabolic abnormalities in patients with Takotsubo cardiomyopathy.

^{99m}Tc perfusion images

^{99m}Tc perfusion SPECT imaging was performed in 13 out of 16 subjects with Takotsubo cardiomyopathy and all 12 patients with AMI. The interval between two studies was 3.7 ±3.7 days and 3.2 ±2.3 days in patients with Takotsubo cardiomyopathy, and AMI, respectively. The perfusion TDS in patients with Takotsubo cardiomyopathy was significantly lower than in those with AMI (2.6±2.9 vs. 13.3±9.2, $p<0.0001$). No significant difference was observed in perfusion summed defect score between apical area and non-apical area in Takotsubo cardiomyopathy (1.8±1.8 vs. 0.9±1.4, p=NS) and in AMI (8.7±5.2 vs. 4.7±4.5, p=NS). The ratio of summed perfusion defect scores of apical and non-apical segment scores of Takotsubo cardiomyopathy did not differ significantly from that of AMI (0.52±0.6 vs. 0.57±0.3, p=NS) (Figure 4).

Comparison of perfusion SPECT data between Takotsubo cardiomyopathy and AMI in 17 segments of left ventricle is shown in Table 3. BMIPP defect score in apical area of Takotsubo cardiomyopathy was larger than that of perfusion defect score (3.9±2.7 vs. 1.8±1.8, p=0.04). The mismatch between perfusion and ^{123}I-BMIPP was larger in patients with AMI than in those with Takotsubo cardiomyopathy (9.1±7.5 vs. 2.7±1.5 in patients who underwent both BMIPP and perfusion, p=0.006). Figure 4 shows the location of the mismatched area between BMIPP and perfusion scan in patients with Takotsubo cardiomyopathy and AMI in 17 segments of left ventricle. Six mismatched areas (^{123}I-BMIPP defect larger than perfusion defect) were observed in patients with Takotsubo cardiomyopathy and 50 mismatched areas in AMI. In patients

with Takotsubo cardiomyopathy, mismatch between perfusion and ^{123}I-BMIPP were observed exclusively in the apical lesion, including apical lateral, apical inferior and apex. In patients with AMI, a mismatch in the apical segment was observed in 12 out of 50 segments (24%).

Discussion

Our study shows the characteristics of regional pattern of metabolic abnormalities in patients with Takotsubo cardiomyopathy differs from that of acute myocardial infarction. Metabolic abnormalities in Takotsubo cardiomyopathy are found exclusively in the apical portion, which is clearly different from the defects on myocardial perfusion scan. Such information of cardiac metabolic ^{123}I-BMIPP imaging can be used to detect myocardial injury and be used as an important tool to diagnose the disease.

Previous reports described that Takotsubo cardiomyopathy resembles an acute myocardial infarction [17-19]. About 1% of all suspected AMI were diagnosed as Takotsubo cardiomyopathy [2, 14]. Since electrocardiographic abnormalities resemble AMI, the patients with Takotsubo cardiomyopathy are sometimes misdiagnosed. Therefore the diagnosis of Takotsubo cardiomyopathy continues to be a challenge, and evaluation of the severity of the disease by metabolic imaging has not been fully established.

Fatty acid metabolism and Ischemic Heart Disease

Ischemia may cause a reduction of fatty acid utilization and shift from fatty acid to glucose utilization in the myocardium. ^{123}I-BMIPP is metabolized in the myocardium and its metabolism is closely related to myocardial carbohydrate utilization. Therefore we assumed that the metabolic abnormalities were detected on the cellular level or as a microcirculation abnormality on ^{123}I-BMIPP imaging. In ischemic heart disease Tamaki et al. first described that discordant ^{123}I-BMIPP uptake less than thallium uptake in 17 of 28 patients with myocardial infarction [10]. Such discordant ^{123}I-BMIPP uptake was observed more often in areas of acute than chronic myocardial infarction (59% at <4 weeks versus 31% at >4weeks after onset), and more often in areas supplied by revascularized arteries than in areas supplied by non-revascularized arteries (74% versus 28%). Recent study showed that the perfusion-metabolism information could improve the risk stratification of the patients with coronary artery disease [20].

One of the major applications of ^{123}I-BMIPP SPECT is to the diagnosis of acute coronary syndrome in the use of emergency department practice. The imaging could add incremental diagnostic value to the initial clinical information. Kawai et al.

reported a sensitivity of ^{123}I-BMIPP imaging of 74% to detect obstructive coronary stenosis or provocative spasm, when it was performed within 3 days of symptoms [21]. In addition cardiac metabolic abnormalities were seen in many patients with coronary spasm, and the imaging could be used to monitor the response to treatment [22]. These findings were confirmed by multicenter study in United State [23]. This noninvasive scintigraphic method is widely applied to diagnosing acute coronary syndrome and might represent the most suitable approach to investigate cardiac metabolism especially in the early period on admission without any risk of the examination itself. These microvascular circulation abnormalities could be detected by metabolic ^{123}I-BMIPP imaging in the resting state. Reduced coronary flow is sometimes observed after emergency angiography without coronary stenosis, which is termed as no-reflow phenomenon. Therefore coronary spasm including epicardial coronary artery and coronary micro-vessels cannot be ruled out as one of the mechanism of causing myocardial ischemia [24]. Less ^{123}I-BMIPP uptake than perfusion is called "mismatched myocardium", which indicates the presence of ischemic and jeopardized myocardium [25]. The combined imaging with ^{123}I-BMIPP and perfusion may be used to identify high-risk subjects among patients with chest pain syndrome [21].

Fatty acid metabolism in Takotsubo cardiomyopathy

^{123}I-BMIPP in this study of patients with Takotsubo cardiomyopathy showed reduced uptake in the apical segment of the myocardium, indicating impairment of fatty acid metabolism in non-infarcted myocardium. Our study showed mismatched area in sub-acute phase in Takotsubo cardiomyopathy in accordance with previous reports [13, 14]. The mismatch may indicate jeopardized but viable myocardium, reflecting transient ischemic damage or metabolically stunned myocardium. The area of metabolic abnormality in the apical segment was relatively smaller than that of AMI in LAD lesion. There are few reports on the fatty acid metabolism of Takotsubo cardiomyopathy. Kuritsu et al. reported that time course of myocardial perfusion and fatty acid metabolism in patients with Takotsubo-like left ventricular dysfunction [13, 14]. Mismatched area observed in the acute phase of the disease, was similar finding to stunned myocardium. Ito et al. reported myocardial metabolic abnormality combined with other nuclear tracers, which resembled with that of AMI, suggesting stunned myocardium or impaired microcirculation as a causative mechanism of Takotsubo

cardiomyopathy [13]. Regional semi-quantitative analysis in this study reveals that the cardiac metabolic abnormalities detected by ^{123}I-BMIPP imaging are only in the apical area, which is one of the typical metabolic SPECT features of Takotsubo cardiomyopathy.

Although the pathogenesis of Takotsubo cardiomyopathy is undetermined, multivessel spasm, coronary microvascular dysfunction or catecholamine toxicity after a severe emotional trigger, surgical or medical procedure has been proposed to explain the provocative pathophysiology of Takotsubo cardiomyopathy [26-29]. Recent studies reported that coronary spasm was observed in about 28.6% of the patients with Takotsubo cardiomyopathy [30]. Increased sympathetic tone from mental stress possibly causes microvascular spasm, and induce coagulation, formation and dissolution of fibrin. Recurrence occurs in about 11.4% of patients with Takotsubo cardiomyopathy during 4-year observation with no evidence of coronary progression [31]. Apical metabolic abnormalities may in part be explained by a metabolic disorder in the myocardium subsequent to a catecholamine surge or microvascular spasm. With hypothesis of metabolic stunned myocardium as a causative mechanism of Takotsubo cardiomyopathy, BMIPP imaging seems to be one of the most specific diagnostic techniques.

^{18}F-fluorodeoxyglucose (FDG) positron emission tomography (PET) study on glucose-loaded method can measure glucose utilization in the myocardium. Recent ^{18}F-FDG-PET study showed reduced apical uptake in patients with Takotsubo cardiomyopathy, which is similar result of the patients with myocardial infarction [32-34]. The studies suggested that the glucose metabolism was suppressed especially in apical segment of stunned myocardium, suggesting preserved oxygen metabolism [35].

Diagnostic value of ^{123}I-BMIPP SPECT

We assume that the present study provides us a clue to differentiate diagnosis in the early time of admission between Takotsubo cardiomyopathy and acute coronary syndrome, since Takotsubo cardiomyopathy could be recognized by the characteristics of metabolic abnormalities associated with ischemic memory. Previous reports suggested that abnormalities in resting perfusion imaging in sub-acute phase were not obvious [36]. Our study showed the metabolic abnormality was larger than that of perfusion. Therefore metabolic imaging with ^{123}I-BMIPP would be a better indicator of myocardial damage than perfusion study. Stress myocardial perfusion scintigraphy with

exercise and/or vasodilatory drugs may help diagnose and stratify risk in patients with chest pain. However stress test is not suitable or recommend for the patients with chest pain and unstable angina. The addition of ^{123}I-BMIPP imaging information to the initial available clinical data provides incremental value for the early diagnosis of Takotsubo cardiomyopathy, potentially allowing determination of the presence or absence of Takotsubo cardiomyopathy to be made much earlier in the evaluation process [37]. ^{123}I-BMIPP imaging might be able to predict therapeutic effects and set up appropriate strategies in patients with suspected acute coronary syndrome or Takotsubo cardiomyopathy.

Limitation of our study

The present study had several limitations. First this was a single-center retrospective observational study. Second, small number of patients investigated requires further intensive studies to confirm its usefulness in determining the prognosis in Takotsubo cardiomyopathy. Third, the different days of BMIPP acquisition from the admission between Takotsubo cardiomyopathy and AMI may affect the size of mismatched area. Fourth, we did not perform repeated ^{123}I-BMIPP study. Although beta-blocker and calcium channel blocker may prevent stress-induced cardiac dysfunction [38, 39], a usefulness to assess the response to therapy needs to be evaluated in further study.

Conclusion

Metabolic abnormality exclusively in the apical region was observed in Takotsubo cardiomyopathy. These results demonstrate that cardiac metabolic ^{123}I-BMIPP imaging can detect myocardial injury and may be used as a tool to diagnose the disease. These typical metabolic SPECT features of the disease can be utilized on differential diagnosis and evaluating the severity or the risk on Takotsubo cardiomyopathy.

Acknowledgment: This study was supported by JSPS Grants-in-Aid for Scientific Research (C) in Japan (grant number 23591755). The authors appreciate the staff of the departments of nuclear medicine, including Hiroshi Wakabayashi, Minoru Tobisaka, and the staff of cardiovascular medicine for contributing clinical medicine, and the nursing team of Kanazawa University Hospital.

Conflict of interest: Dr. Matsuo has a financial support from Nihon Medi-Physics, Co.Ltd (Tokyo, Japan) for this study.

REFERENCE

1 Iga K, Hori K, Kitaguchi K, Matsumura T, Gen H, Tomonaga G, et al. Transient segmental asynergy of the left ventricle of patients with various clinical manifestations possibly unrelated to the coronary artery disease. *Jpn Circ J* 1991; 55:1061-7.

2 Kawai S, Suzuki H, Yamaguchi H, Tanaka K, Sawada H, Aizawa T,et al. Ampulla cardiomyopathy ('Takotusbo' cardiomyopathy)—reversible left ventricular dysfunction: with ST segment elevation. *Jpn Circ J* 2000;64:156–159.

3 Abe Y, Kondo M. Apical ballooning of the left ventricle: a distinct entity? *Heart* 2003; 89:974–976.

4 Desmet WJ, Adriaenssens BF, Dens JA. Apical ballooning of the left ventricle: first series in white patients. *Heart* 2003;89:1027–1031.

5 Tsuchihashi K, Ueshima K, Uchida T, Oh-mura N, Kimura K, Owa M, et al. Trancient left ventricular apical ballooning without coronary stenosis: a novel heart syndrome mimicking acute myocardial infarction. *J Am Coll Cardiol* 2001; 38:11-18.

6 Kurisu S, Sato H, Kawagoe T, Ishihara M, Shimatani Y, Nishioka K, et al. Tako-tsubo-like left ventricular dysfunction with ST-segment elevation: a novel cardiac syndrome mimicking acute myocardial infarction. *Am Heart J* 2002; 143: 448–455.

7 Pavin D, Le Breton H, Daubert C. Human stress cardiomyopathy mimicking acute myocardial syndrome. *Heart* 1997;78:509–511.

8 Abe Y, Kondo M, Matsuoka R, Araki M, Dohyama K, Tanio H. Assessment of clinical features in transient left ventricular apical ballooning. *J Am Coll Cardiol* 2003; 41:737–742.

9 Yasu T, Tone K, Kubo N, Saito M. Transient mid-ventricular ballooning cardiomyopathy:a new entity of Takotsubo cardiomyopathy. *Int J Cardiol* 2006; 110: 100–101.

10 Tamaki N, Kawamoto M, Yonekura Y, Fujibayashi Y, Takahashi N, Konishi J, et al. Regional metabolic abnormality in relation to perfusion and wall motion in patients with myocardial infarction:assessment with emission tomography using an iodinated branched fatty acid analog. *J Nucl Med* 1992; 33: 659–67.

11 Matsuo S, Nakajima K, Yamashina S, Sakata K, Momose M, Hashimoto J, et al. Characterization of Japanese standards for myocardial sympathetic and metabolic imaging in comparison with perfusion imaging. *Ann Nucl Med* 2009; 23: 517-22.

12 Matsuo S, Nakamura Y, Takahashi M, Mistunami K, Kinoshita M. Myocardial

metabolic abnormalities in hypertrophic cardiomyopathy assessed by iodine-123-labeled beta-methyl-branched fatty acid myocardial scintigraphy and its relation to exercise-induced ischemia. *Jpn Circ J* 1998; 62:167-172.

13 Kurisu S, Inoue I, Kawagoe T, Ishihara M, Shimatani Y, Nishioka K, et al. Myocardial perfusion and fatty acid metabolism in patients with tako-tsubo-like left ventricular dysfunction. *J Am Coll Cardiol* 2003; 41:743–748.

14 Kurisu S, Kihara Y. Tako-tsubo cardiomyopathy: clinical presentation and underlying mechanism. *J Cardiol* 2012; 60: 429-37.

15 Ito K, Sugihara H, Kinoshita N, Azuma A, Matsubara H. Assessment of Takotsubo cardiomyopathy (transient left ventricular apical ballooning) using 99mTc-tetrofosmin, 123I-BMIPP, 123I-MIBG and 99mTc-PYP myocardial SPECT. *Ann Nucl Med* 2005;19:435-45.

16 Matsuo S, Nakajima K, Okuda K, Kinuya S. The relationship between stress-induced myocardial ischemia and coronary artery atherosclerosis measured by hybrid SPECT/CT camera. *Ann Nucl Med* 2011;25:650-6.

17 Kume T, Akasaka T, Kawamoto T, Yoshitani H, Watanabe N, Neishi Y, et al. Assessment of coronary microcirculation in patients with takotsubo-like left ventricular dysfunction. Circ J 2005; 69:934–939.

18 Elesber A, Lerman A, Bybee KA, Murphy JG, Barsness G, Singh M, et al. Myocardial perfusion in apical ballooning syndrome correlate of myocardial injury. *Am Heart J* 2006; 152:e469–e413.

19 Hurst RT, Askew JW, Reuss CS, Lee RW, Sweeney JP, Fortuin FD, et al. Transient midventricular ballooning syndrome: a new variant. *J Am Coll Cardiol* 2006; 48: 579–583.

20 Nakata T, Hashimoto A, Matsuki T, Yoshinaga K, Tsukamoto K, Tamaki N. Prognostic value of automated SPECT scoring system for coronary artery disease in stress myocardial perfusion and fatty acid metabolism imaging. *Int J Cardiovasc Imaging* 2013 29:253-62.

21 Kawai Y, Tsukamoto E, Nozaki Y, Morita K, Sakurai M, Tamaki N. Significance of reduced uptake of iodinated fatty acid analogue for the evaluation of patients with acute chest pain. *J Am Coll Cardiol* 2001;38:1888-94.

22 Nakajima K, Shimizu K, Taki J, Uetani Y, Konishi S, Tonami N, et al. Utility of iodine-123-BMIPP in the diagnosis and follow-up of vasospastic angina. *J Nucl Med*

1995; 36:1934-40.
23 Kontos MC, Dilsizian V, Weiland F, DePuey G, Mahmarian JJ, Iskandrian AE, et al. Iodofiltic acid I 123 (BMIPP) fatty acid imaging improves initial diagnosis in emergency department patients with suspected acute coronary syndromes: a multicenter trial. *J Am Coll Cardiol* 2010 20; 56: 290-9.
24 Dote K, Sato H, Tateishi H, Uchida T, Ishihara M. Myocardial stunning due to simultaneous multivessel coronary spasms: a review of 5 cases. *J Cardiol* 1991; 21: 203-14.
25 Fukuzawa S, Ozawa S, Shimada K, Sugioka J, Inagaki M. Prognostic values of perfusion-metabolic mismatch in Tl-201 and BMIPP scintigraphic imaging in patients with chronic coronary artery disease and left ventricular dysfunction undergoing revascularization. *Ann Nucl Med* 2002; 16: 109-15.
26 Nanda AS, Feldman A, Liang CS. Acute reversal of pheochromocytomainduced catecholamine cardiomyopathy. *Clin Cardiol* 1995; 18: 421–423.
27 Sharkey SW, Lesser JR, Zenovich AG, Maron MS, Lindberg J, Longe TF, et al. Acute and reversible cardiomyopathy provoked by stress in women from the United States. *Circulation* 2005; 111: 472–479.
28 Wittstein IS, Thiemann DR, Lima JA, Baughman KL, Schulman SP, Gerstenblith G, et al. Neurohumoral features of myocardial stunning due to sudden emotional stress. *N Engl J Med* 2005; 352:539–548.
29 Lacy CR, Contrada RJ, Robbins ML, Tannenbaum AK, Moreyra AE, Chelton S, et al. Coronary vasoconstriction induced by mental stress (simulated public speaking). *Am J Cardiol* 1995; 75: 503–505.
30 Gianni M, Dentali F, Grandi AM, Sumner G, Hiralal R, Lonn E. Apical ballooning syndrome or takotsubo cardiomyopathy: a systematic review. *Eur Heart J* 2006 ; 27:1523-9.
31 Elesber AA, Prasad A, Lennon RJ, Wright RS, Lerman A, Rihal CS. Four-year recurrence rate and prognosis of the apical ballooning syndrome. *J Am Coll Cardiol* 2007; 50:448-52.
32 Bybee KA, Murphy J, Prasad A, Wright RS, Lerman A, Rihal CS, Chareonthaitawee P. Acute impairment of regional myocardial glucose uptake in the apical ballooning (takotsubo) syndrome. *J Nucl Cardiol* 2006; 13: 244–250.
33 Obunai K, Misra D, Van Tosh A, Bergmann SR. Metabolic evidence of

myocardial stunning in takotsubo cardiomyopathy: a positron emission tomography study. *J Nucl Cardiol* 2005; 12: 742–744.

34 Egert S, Nguyen N, Schwaiger M. Contribution of alpha-adrenergic and beta-adrenergic stimulation to ischemia-induced glucose transporter (GLUT) 4 and GLUT1 translocation in the isolated perfused rat heart. *Circ Res* 1999; 84: 1407–1415.

35 Fukuoka Y, Nakano A, Uzui H, Amaya N, Ishida K, Arakawa K, et al. Reverse blood flow-glucose metabolism mismatch indicates preserved oxygen metabolism in patients with revascularised myocardial infarction. *Eur J Nucl Med Mol Imaging* 2013 40: 1155-62.

36 Ito K, Sugihara H, Katof S, Azuma A, Nakagawa M. Assessment of Takostubo (ampulla) cardiomyopathy using 99mTc-tetrofosmin myocardial SPECT – comparison with acute coronary syndrome. *Ann Nucl Med* 2003; 17: 155-122.

37 Moroi M, Tamaki N, Nishimura M, Haze K, Nishimura T, Kusano E, et al. Association between abnormal fatty acid metabolism and cardiac-derived death among patients undergoing hemodialysis: results from a cohort study in Japan. *Am J kidney Dis* 2013; 61: 466-475.

38 Ishikura F, Takano Y, Ueyama T. Acute effects of beta-blocker with intrinsic sympathomimetic activity on stress-induced cardiac dysfunction in rats. *J Cardiol* 2012; 60: 470-4.

39 Takano Y, Ueyama T, Ishikura F. Azelnidipine, unique calcium channel blocker could prevent stress-induced cardiac dysfunction like α·β blocker. *J Cardiol* 2012; 60: 18-22.

Legends for illustrations

Fig 1 Left ventricular segmentation. Diagramatic presentation of a circumferential polar plot of 17 segment model of left ventricle: 1, basal anterior; 2, basal anteroseptal; 3, basal inferoseptal; 4, basal inferior; 5, basal inferolateral; 6, basal anterolateral; 7, mid anterior; 8, mid anteroseptal; 9, mid inferoseptal; 10, mid inferior; 11, mid inferolateral; 12, mid anterolateral; 13, apical anterior; 14, apical septal; 15, apical inferior; 16, apical lateral; 17, apex.

Fig. 2 Cardiac SPECT image using ^{123}I-BMIPP (upper left) and ^{99m}Tc-sestamibi (MIBI) (upper right) in a 66 year-old male patient with Takotsubo cardiomyopathy. Discordant ^{123}I-BMIPP uptake less than perfusion uptake in the apex is shown. Yellow arrow shows decreased uptake of BMIPP in apical area.
In the acute phase left ventriculography showed apical akinesis and basal normokinesis (ED, end-diastole; ES, end-systole). Coronary angiography revealed no stenotic legion (RCA, right coronary artery; LCA, left coronary artery).

Fig. 3 Comparison of defect score between apical and non-apical segments in Takotsubo cardiomyopathy or AMI. A: The ratio of BMIPP summed defect score of non-apical segments to apical segments is shown. B: The ratio of perfusion defect score of non-apical segments to the apical segments is shown. Green bar and blue bars are mean value and standard deviation, respectively.

Fig. 4 Location of mismatched area between ^{123}I-BMIPP and perfusion scan in patients with Takotsubo cardiomyopathy (a) and AMI (b) and. Mismatched segments were observed in exclusively in apical area in Takotsubo cardiomyopathy.

Table 1 Characteristics of study subjects.

	Takotsubo cardiomyopathy n=16	AMI n=12	p
Age (years)	72±3	67±3	NS
Male gender	8 (50%)	8 (67%)	NS
Coronary risk factors			
Hypertension	7 (44%)	5 (42%)	NS
Diabetes mellitus	2 (13%)	3 (19%)	NS
Dyslipidemia	1 (6%)	6 (50%)	0.005
Current smoking	4 (25%)	5 (42%)	NS
Peak CPK (IU/L)	261±337	2116±1861	0.0006
Cardiac Medications			
Aspirin	1 (6%)	5 (42%)	0.002
Beta-blocker	3 (19%)	4 (33%)	NS
ACEIs or ARB	4 (25%)	5 (42%)	NS
Nitrates	1 (6%)	0 (0%)	NS
Any of the above	9 (56%)	7 (58%)	NS

AMI, acute myocardial infarction; NS, not significant; ACEI, angiotensin converting enzyme inhibitor; ARB, angiotensin II receptor blocker; CPK, creatinine phosphokinase

Table 2 Comparison of ^{123}I-BMIPP SPECT defect between Takotsubo cardiomyopathy and AMI of left anterior descending coronary artery in 17 segments of left ventricle.

	Takotsubo Cardiomyopathy	AMI	p
Non-apical area	1.1±2.1	11.7±7.1	<0.0001
1, basal anterior	0.1±0.3	1.2±0.3	0.008
2, basal anteroseptal	0.1±0.3	1.2±0.3	0.02
3, basal inferoseptal	0.1±0.3	1.1±0.3	0.02
4, basal inferior	0.0±0.1	0.3±0.2	NS
5, basal inferolateral	0.0±0.0	0.0±0.0	NS
6, basal anterolateral	0.0±0.04	0.1±0.1	NS
7, mid anterior	0.1±0.2	2.8±0.2	<0.0001
8, mid anteroseptal	0.1±0.2	2.8±0.2	<0.0001
9, mid inferoseptal	0.1±0.2	1.0±0.2	0.002
10, mid inferior	0.1±0.1	0.4±0.2	0.2
11, mid inferolateral	0.2±0.2	0.3±0.2	NS
12, mid anterolateral	0.0±0.2	0.7±0.2	0.04
Apical area	3.9±2.7	10.8±4.9	<0.0001
13, apical anterior	0.4±0.2	3.0±0.2	<0.0001
14, apical septal	0.5±0.2	2.8±0.3	<0.0001
15, apical inferior	0.6±0.3	0.8±0.3	NS
16, apical lateral	0.8±0.3	1.1±0.4	NS
17, apex	1.6±0.8	3.0±0.3	0.0002
BMIPP total defect score	4.8±2.7	22.4±10.7	<0.0001

AMI, acute myocardial infarction; NS, not significant.

Table 3 Comparison of perfusion defect score between Takotsubo cardiomyopathy and AMI of left anterior descending coronary artery in 17 segments of left ventricle.

	Takotsubo Cardiomyopathy	AMI	p
Non-apical area	0.9±1.4	4.7±4.5	0.002
1, basal anterior	0.0±0.2	0.6±0.2	0.03
2, basal anteroseptal	0.07±0.2	0.3±0.2	NS
3, basal inferoseptal	0.0±0.06	0.08±0.06	NS
4, basal inferior	0.08±0.06	0.0±0.06	NS
5, basal inferolateral	0.0±0.0	0.0±0.0	NS
6, basal anterolateral	0.0±0.0	0.0±0.0	NS
7, mid anterior	0.08±0.2	1.4±0.3	0.0008
8, mid anteroseptal	0.15±0.2	1.0±0.2	0.02
9, mid inferoseptal	0.08±0.1	0.25±0.1	NS
10, mid inferior	0.31±0.1	0.17±0.1	NS
11, mid inferolateral	0.08±0.07	0.08±0.08	NS
12, mid anterolateral	0.08±0.3	0.75±0.3	NS
Apical area	1.8±1.8	8.7±5.2	0.0005
13, apical anterior	0.23±0.3	2.3±0.3	0.0005
14, apical septal	0.23±0.3	1.7±0.3	0.003
15, apical inferior	0.23±0.2	0.8±0.2	0.06
16, apical lateral	0.23±0.3	1.5±0.3	0.001
17, apex	0.77±0.3	2.5±0.3	0.001
Perfusion total defect score	2.6±2.9	13.3±9.2	<0.0001

AMI, acute myocardial infarction; NS, not significant.

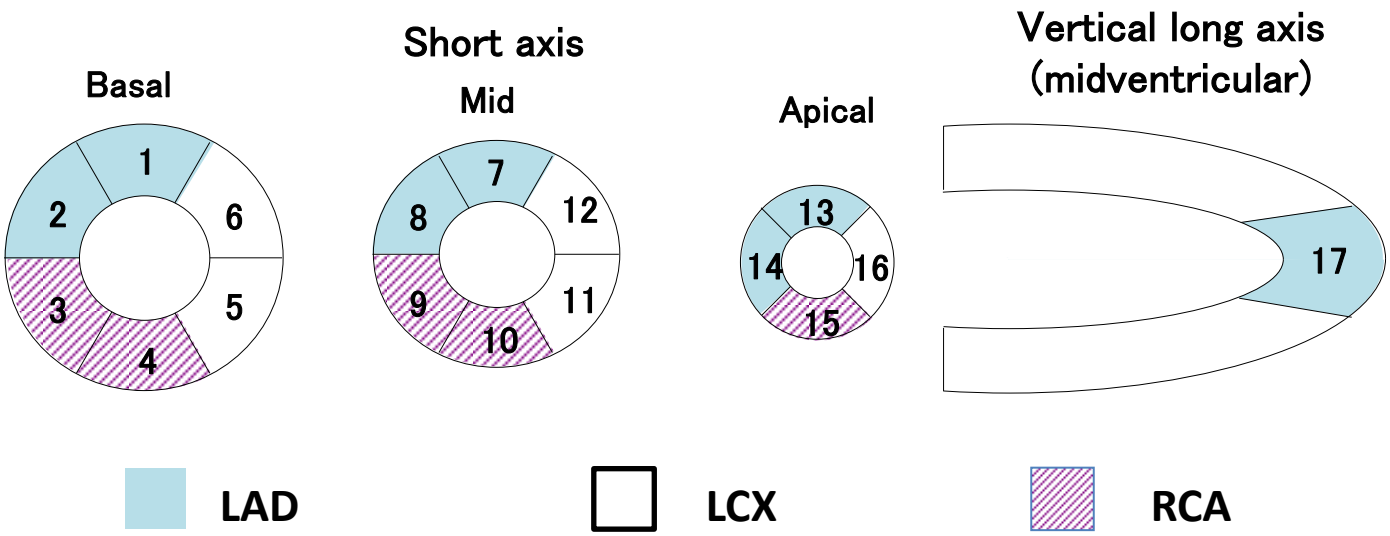
Short axis
Basal
Mid
Apical
Vertical long axis
(midventricular)
1
2
3
4
5
6
7
8
9
10
11
12
13
14
15
16
17
LAD
LCX
RCA

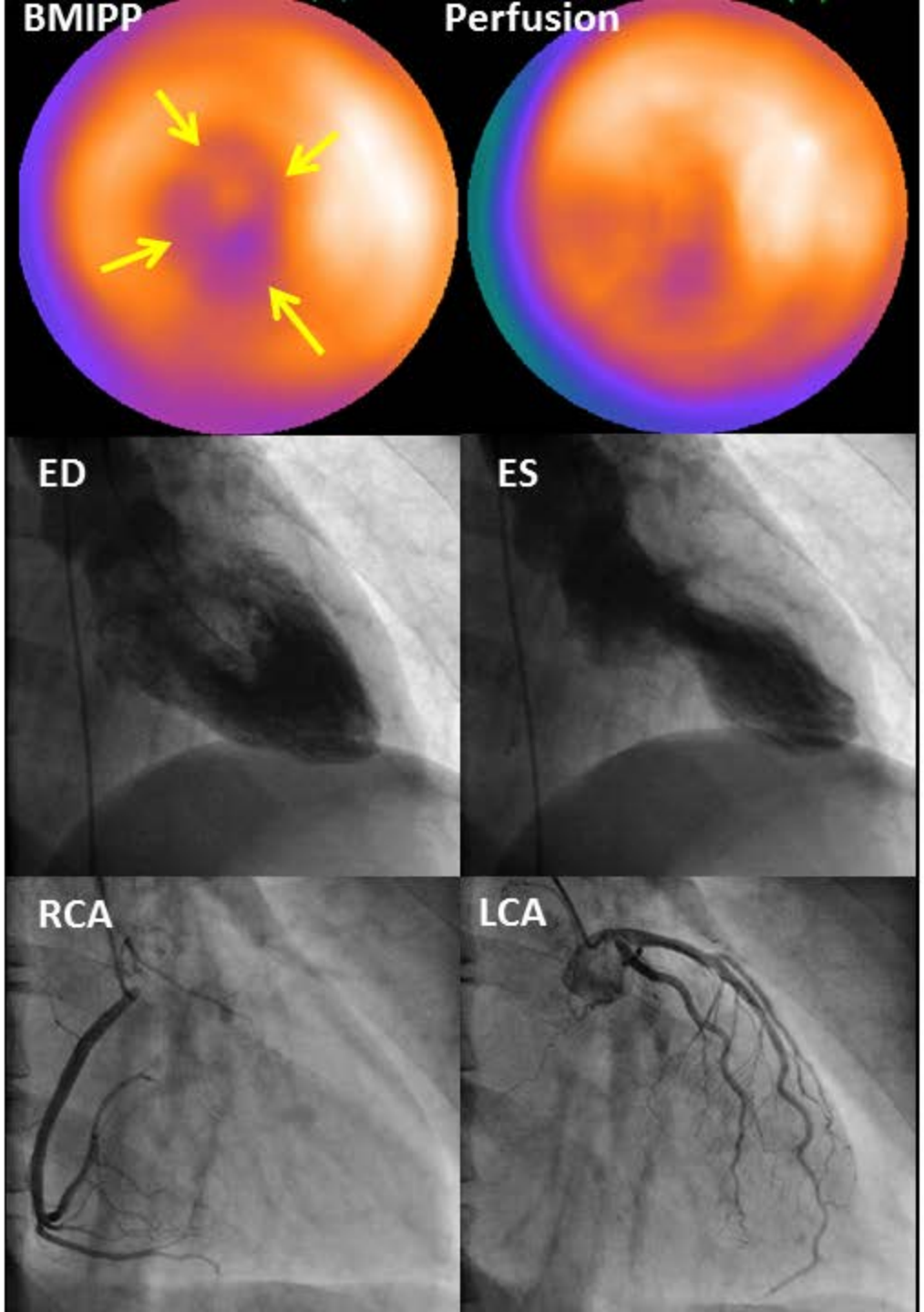
BMIPP
Perfusion
ED
ES
RCA
LCA

A. I-123 BMIPP

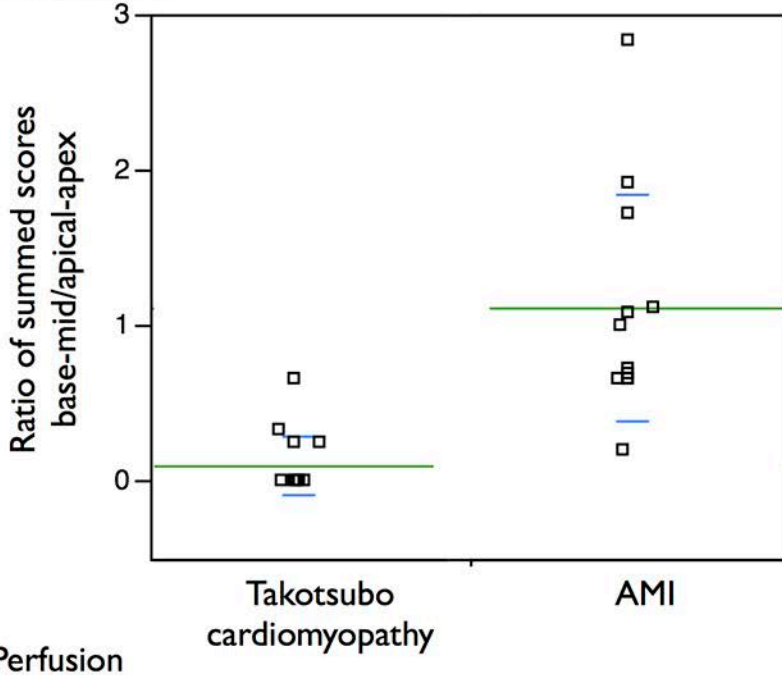

B. Perfusion

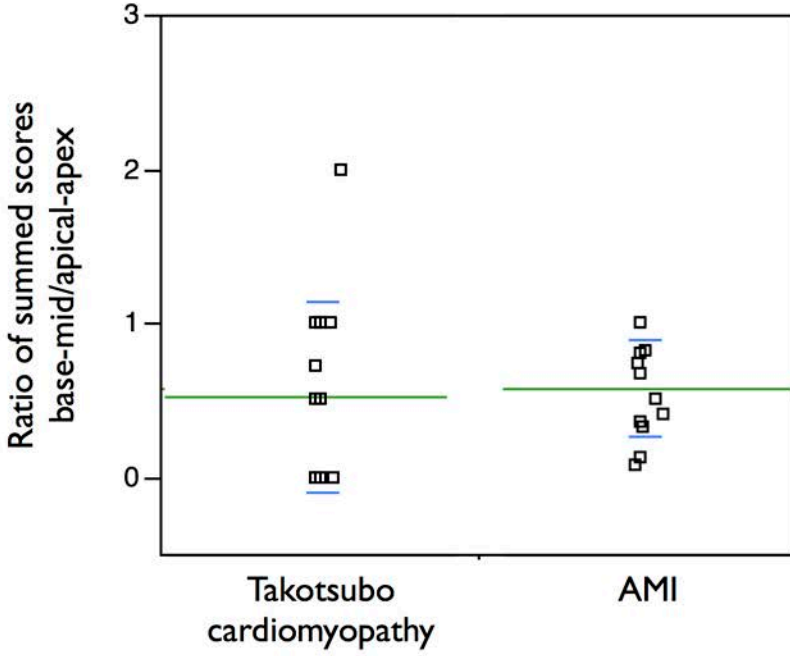

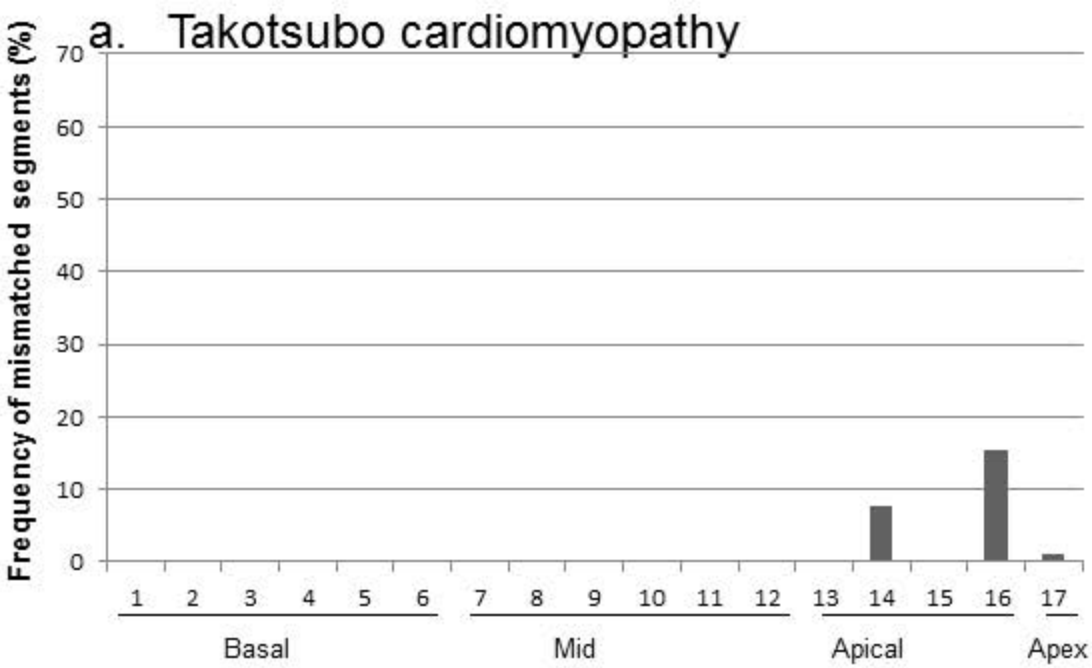
a. Takotsubo cardiomyopathy
Frequency of mismatched segments (%)
70
60
50
40
30
20
10
0
1 2 3 4 5 6 7 8 9 10 11 12 13 14 15 16 17
Basal
Mid
Apical
Apex

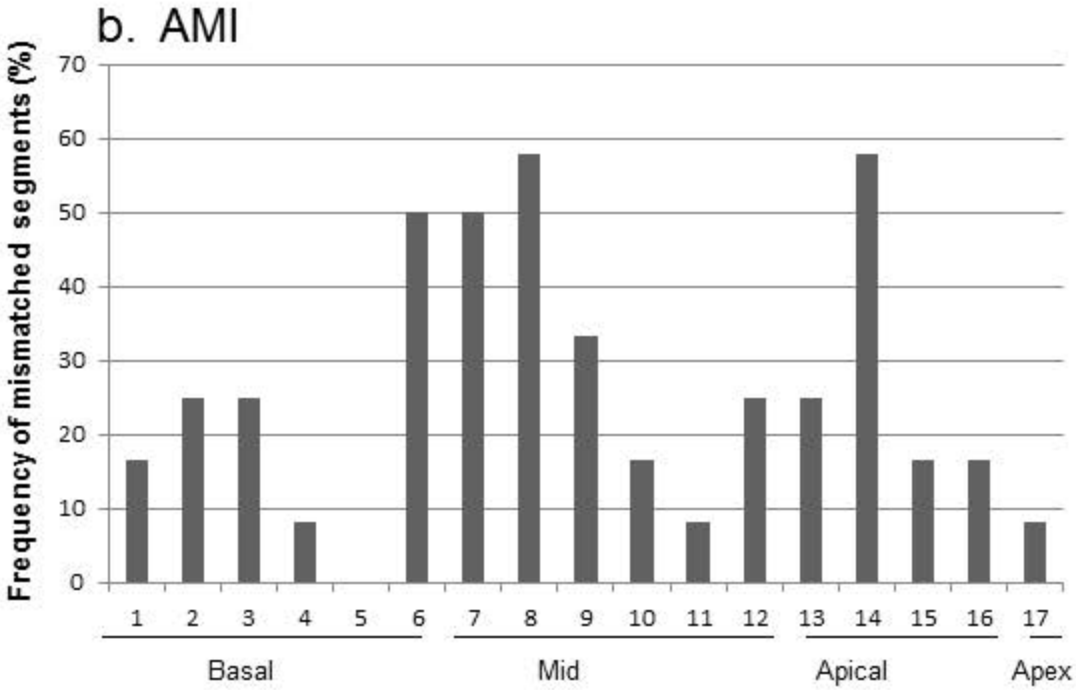
b. AMI
Frequency of mismatched segments (%)
70
60
50
40
30
20
10
0
1 2 3 4 5 6 7 8 9 10 11 12 13 14 15 16 17
Basal
Mid
Apical
Apex