

Clonal expansion of Epstein-Barr virus (EBV)-infected  $\gamma$   $\delta$  T cells in patients with chronic active EBV disease and hydroa vacciniforme-like eruptions

メタデータ	言語: eng 出版者: 公開日: 2017-10-05 キーワード (Ja): キーワード (En): 作成者: メールアドレス: 所属:
URL	<a href="http://hdl.handle.net/2297/32464">http://hdl.handle.net/2297/32464</a>

# **Clonal expansion of Epstein-Barr virus (EBV)-infected $\gamma\delta$ T cells in patients with chronic active EBV disease and hydroa vacciniforme-like eruptions**

**Taizo Wada,<sup>1</sup> Akiko Toga,<sup>1</sup> Yasuhisa Sakakibara,<sup>1</sup> Tomoko Toma,<sup>1</sup> Minoru Hasegawa,<sup>2</sup> Kazuhiko Takehara,<sup>2</sup> Tomonari Shigemura,<sup>3</sup> Kazunaga Agematsu,<sup>4</sup> and Akihiro Yachie<sup>1</sup>**

## **Institutional affiliations:**

<sup>1</sup>Department of Pediatrics and <sup>2</sup>Department of Dermatology, School of Medicine, Institute of Medical, Pharmaceutical and Health Sciences, Kanazawa University, Kanazawa; <sup>3</sup>Department of Pediatrics and <sup>4</sup>Department of Infection and Host Defense, Shinshu University School of Medicine, Matsumoto; and <sup>5</sup>Division of Infectious Disease, Immunology, and Allergy, Saitama Children's Medical Center, Saitama, Japan.

**Correspondence to:** Taizo Wada, MD, PhD  
Department of Pediatrics, School of Medicine,  
Institute of Medical, Pharmaceutical and Health Sciences,  
Kanazawa University  
13-1 Takaramachi, Kanazawa 920-8641, Japan  
Phone: +81-76-265-2313  
Fax: +81-76-262-1866  
E-mail: taizo@staff.kanazawa-u.ac.jp

**Running head:** Clonal expansion of EBV-infected  $\gamma\delta$  T cells

## Abstract

Chronic active Epstein-Barr virus (EBV) disease (CAEBV) is a systemic EBV-positive lymphoproliferative disorder characterized by fever, lymphadenopathy, and splenomegaly. Patients with CAEBV may present with cutaneous symptoms including hypersensitivity to mosquito bites and hydroa vacciniforme (HV)-like eruptions. HV is a rare photodermatosis characterized by vesicles and crust formation after exposure to sunlight, with onset in childhood, and is associated with latent EBV infection. While  $\gamma\delta$  T cells have been recently demonstrated to be the major EBV-infected cell population in HV, the immunophenotypic features of EBV-infected  $\gamma\delta$  T cells in CAEBV with HV-like eruptions or HV remain largely undetermined. Herein we describe 3 patients with CAEBV whose  $\gamma\delta$  T cells were found to be the major cellular target of EBV. HV-like eruptions were observed in two of them. A clonally expanded subpopulation of  $\gamma\delta$  T cells that were highly activated and T-cell receptor V $\gamma$ 9- and V $\delta$ 2-positive cells was demonstrated in all patients. We also showed that the clonally expanded  $\gamma\delta$  T cells infiltrated into the HV-like eruptions in one patient from whom skin biopsy specimens were available. These results suggest the pathogenetic roles of clonally expanded  $\gamma\delta$  T cells infected by EBV in patients with CAEBV and HV-like eruptions.

**Keywords:** Epstein-Barr virus, clonal proliferation,  $\gamma\delta$  T cells, hydroa vacciniforme

## Introduction

Epstein Barr virus (EBV) is a herpes virus that is ubiquitous in the human population. Primary EBV infection occasionally causes infectious mononucleosis that is an acute and usually benign self-limited disease [1]. The target of EBV infection is primarily B lymphocytes. However, EBV infection has also been etiologically associated with various malignancies and lymphoproliferative disorders including chronic active EBV infection (CAEBV), in which monoclonal or oligoclonal proliferation of EBV-infected T or natural killer (NK) cells may play important roles in disease development [2]. CAEBV is characterized by persistent or recurrent infectious mononucleosis-like symptoms such as fever, lymphadenopathy and hepatosplenomegaly, and by extremely high viral loads in peripheral blood [3]. Patients with CAEBV may also suffer from cutaneous lesions including hypersensitivity to mosquito bites or hydroa vacciniforme (HV)-like eruptions. Based on the cellular targets of EBV, CAEBV can be divided into T-cell type and NK-cell type infections [4]. T-cell type CAEBV is further subdivided into CD4<sup>+</sup>, CD8<sup>+</sup>, and  $\gamma\delta$  T cell-type infections.

HV is a rare photosensitivity disorder characterized by vesicle, crust and scar formation on sun-exposed areas with onset in childhood. Although the origin of this condition remains unknown, HV resolves spontaneously by adulthood in most cases [5]. However, there also have been severe cases accompanied by systemic manifestations including fever, lymphadenopathy and liver dysfunction. These patients may progress to cutaneous T-cell lymphoma [6]. Accumulating evidence has suggested that both typical and severe HV are associated with latent EBV infection [7-9]. In addition,  $\gamma\delta$  T cells have

recently been demonstrated to be the major cellular target of EBV infection in HV [10-12]. However, the immunophenotypic features of EBV-infected  $\gamma\delta$  T cells and their involvement in skin lesions in CAEBV and/or HV are not fully understood. In this report, we describe 3 patients with CAEBV whose  $\gamma\delta$  T cells were predominantly infected by EBV, and show their selective activation, clonal expansion, and recruitment to HV skin lesions.

## Materials and Methods

### Patients

We evaluated 3 Japanese patients with  $\gamma\delta$  T cell-type CAEBV. The clinical and immunological data of patient 1 have been reported elsewhere [13]. Patient 2 was a 10-year-old girl who had frequent episodes of fever, stomatitis, and liver dysfunction since the age of 4 years. She had mild hepatosplenomegaly. The copy numbers of the EBV genome were found to be extremely high in the peripheral blood at the age of 9 years ( $1.2 \times 10^5$  copies/ $\mu\text{g}$  DNA). There was no history of hypersensitivity to mosquito bites and HV in this patient. Patient 3 was a 14-year-old female who developed vesiculopapules on sun-exposed skin at the age of 4 years. A diagnosis of HV was made at the age of 5 years, when skin biopsy specimens exhibited the presence of EBV genome. The EBV viral loads in the peripheral blood were in the range of  $3.5 \times 10^3$  to  $5.4 \times 10^4$  copies/ $\mu\text{g}$  DNA. Despite the absence of hepatosplenomegaly or lymphadenopathy, her clinical history was remarkable for occasional febrile episodes and frequent severe gingivitis in addition to HV. Approval for the study was obtained from the Human Research Committee of Kanazawa University Graduate School of Medical Science, and informed consent was provided according to the Declaration of Helsinki.

### Cell preparations and *in situ* hybridization for EBV-encoded small RNA1 (EBER-1)

Peripheral blood mononuclear cells (PBMCs) were isolated by Ficoll-Hypaque gradient centrifugation from patients and controls. Peripheral blood lymphocytes (PBLs) were prepared from PBMCs by depletion of monocytes using anti-CD14 monoclonal

antibody (mAb)-coated magnetic beads. CD4<sup>+</sup> T, CD8<sup>+</sup> T, CD19<sup>+</sup> B, and CD56<sup>+</sup> NK cells were then purified by positive selection from PBLs using mAb-coated magnetic beads [14]. To obtain  $\gamma\delta$  T cells, PBLs were stained with biotin-conjugated anti-T-cell receptor (TCR)  $\gamma\delta$  mAb, followed by incubation with streptavidin-coated magnetic beads (all from Becton Dickinson, San Diego, CA). The purity of the isolated  $\gamma\delta$ , CD4<sup>+</sup>, and CD8<sup>+</sup> T cells from patient 2 was 95.6, 98.6, and 97.8%, respectively, as determined by flow cytometric analysis. The purity of the isolated  $\gamma\delta$  T, CD4<sup>+</sup> T, CD8<sup>+</sup> T, CD19<sup>+</sup> B, and CD56<sup>+</sup> NK cells from patient 3 was 98.2, 98.4, 94.7, 96.2, and 92.8%, respectively. *In situ* hybridization for EBER-1 was performed as described previously [14].

### **Flow cytometry**

Expression of V $\delta$  chains and human leukocyte antigen (HLA)-DR was evaluated on  $\gamma\delta$  T cells using a FACSCalibur flow cytometer with CellQuest software (BD Bioscience, Tokyo, Japan) [14]. The following mAbs were used: fluorescein isothiocyanate-conjugated anti-TCR V $\delta$ 1 (Thermo Scientific, Rockford, IL), anti-TCR V $\delta$ 2 (Immunotech, Marseille, France), anti-TCR Pan  $\gamma\delta$  (Immunotech), and phycoerythrin-labeled anti-HLA-DR (Becton Dickinson).

### **Analysis of TCR V $\delta$ and V $\gamma$ mRNA**

Complementarity determining region 3 (CDR3) spectratyping was performed as described previously, with minor modifications [15, 16]. Briefly, each fragment of TCR V $\delta$  and V $\gamma$  was amplified from cDNA obtained from PBMCs with one of 3 V $\delta$ -specific or 3 V $\gamma$ -specific primers, respectively. Thirty-five or 30 cycles of amplification (94°C for

45 sec, 60°C for 45 sec, and 72°C for 45 sec) were used, and the polymerase chain reaction (PCR) products were then subjected to run-off reactions using a nested 6-fluorescein phosphoramidite-labelled C $\delta$  or C $\gamma$  primer, respectively. The size distribution of each of the fluorescent PCR products was determined as described previously [17]. Quantitative reverse-transcription (RT)-PCR of TCR V $\delta$ 2 was performed on an ABI 7700 Sequence Detection System (Applied Biosystems, Foster City, CA) using the SYBR GreenER qPCR SuperMix for ABI Prism (Invitrogen, Carlsbad, CA) [14]. We used  $\beta$ -actin as the reference gene. The PCR products of V $\delta$ 2 cDNA were subcloned with a TOPO TA cloning kit (Invitrogen) and subcloned PCR products were sequenced using the ABI Prism BigDye Terminator Cycle Sequencing Kit on an ABI 3100 automated sequencer (Applied Biosystems).

### **Analysis of TCR V $\delta$ genomic sequences in skin**

TCR- $\delta$  gene rearrangements were detected by family-specific multiplex PCR, as described previously [18]. Genomic DNA extracted from paraffin-embedded skin biopsy specimens with DEXPAT (Takara Bio Inc., Shiga, Japan) was subjected to PCR amplification using 6 TCR V $\delta$ -specific forward primers and 4 TCR J $\delta$ -specific reverse primers that could detect all major D $\delta$ (D)J $\delta$  rearrangements. PCR products were then subcloned and sequenced.



## Results

### Ectopic EBV infection of $\gamma\delta$ T cells

To determine which populations of lymphocytes were infected with EBV, *in situ* hybridization for EBER-1 was performed on samples isolated from the patients. As shown in Fig. 1,  $\gamma\delta$  T cells were found to account for the majority of EBER-1<sup>+</sup> cells, with negligible EBER-1 identified in CD4<sup>+</sup> T, CD8<sup>+</sup> T, CD19<sup>+</sup> B, and CD56<sup>+</sup> NK cells in all cases. Immunophenotypic analysis of lymphocyte subsets exhibited markedly increased percentages of  $\gamma\delta$  T cells in their peripheral blood (Fig. 2A). More than 80% of those  $\gamma\delta$  T cells expressed the activation marker HLA-DR, which is generally negative in normal  $\gamma\delta$  T cells (Fig. 2B). The ratio of CD4<sup>+</sup> to CD8<sup>+</sup> T cells and the percentage expression of CD45RO<sup>+</sup> memory marker in CD4<sup>+</sup> and CD8<sup>+</sup> T cells were normal in all patients (data not shown).

### Clonal expansion of V $\gamma$ 9<sup>+</sup> V $\delta$ 2<sup>+</sup> $\gamma\delta$ T cells

We next analyzed the diversity of the TCR V $\delta$  repertoire in  $\gamma\delta$  T cells from the patients using V $\delta$ -specific mAbs and CDR3 spectratyping. Flow cytometric analysis clearly demonstrated a massive expansion of TCR V $\delta$ 2<sup>+</sup> cells among the  $\gamma\delta$  T cells from these patients (Fig. 2A). In age-matched controls, CDR3 spectratyping of the TCR V $\delta$ 1,  $\delta$ 2, and  $\delta$ 3 segments exhibited a Gaussian curve reflecting the polyclonal V $\delta$  repertoire (Fig. 3A). Although all 3 V $\delta$  segments were amplified from the patients' cDNA, preferential usage of TCR V $\delta$ 2 was seen on their gel images in the patients compared with controls (data not shown). Quantitative RT-PCR analysis showed that the levels of

V $\delta$ 2 mRNA in PBMCs from the patients were much higher than those in PBMCs from controls (Fig. 3B). CDR3 spectratyping of their TCR V $\delta$ 2 segments exhibited a single peak, whereas their V $\delta$ 1 and V $\delta$ 3 segments exhibited polyclonal peaks (Fig. 3A). The junctional amino acid sequence of their TCR V $\delta$ 2 segments also exhibited monoclonal profiles (Table 1). The clonally expanded  $\gamma\delta$  T cells of patients 1, 2 and 3 were V $\delta$ 2-J $\delta$ 2<sup>+</sup>, V $\delta$ 2-J $\delta$ 1<sup>+</sup>, V $\delta$ 2-J $\delta$ 3<sup>+</sup> cells, respectively. We also analyzed mRNA of TCR V $\gamma$ 1, V $\gamma$ 4 and V $\gamma$ 9. Similar to those found in TCR V $\delta$ 2, the patients' TCR V $\gamma$ 9 segments were preferentially amplified (data not shown), and showed monoclonal profiles (Fig. 3C). Consistent with these monoclonal TCR V $\delta$ 2 and V $\gamma$ 9 patterns, Southern blot analysis of EBV terminal repeats showed monoclonal EBV in the peripheral blood from all patients (data not shown).

### **Skin infiltration of V $\delta$ 2<sup>+</sup> $\gamma\delta$ T cells**

The availability of skin biopsy specimens from patient 1 offered us the unique opportunity to investigate whether the clonally expanded  $\gamma\delta$  T cells existed in the HV-like eruptions. Although the V $\delta$  clones obtained from her skin lesion included only V $\delta$ 2, the V $\delta$ 2 segments exhibited a couple of different J $\delta$ . Of note, we were able to show that one of those V $\delta$ 2 clones were identical to that of the clonally expanded V $\delta$ 2-J $\delta$ 2<sup>+</sup>  $\gamma\delta$  T cells in the peripheral blood (Fig. 4, Table 1). These results suggested that EBV-infected V $\delta$ 2<sup>+</sup>  $\gamma\delta$  T cells infiltrated into the skin lesion.

## Discussion

HV has been recently reported to be pathogenically associated with chronic latent EBV infection [7-9]. It is also known that patients with CAEBV may present with various cutaneous manifestations including HV-like eruptions [3]. CAEBV patients with HV-like eruptions sometimes develop cutaneous T-cell lymphoma that is defined as HV-like lymphoma in the 2008 World Health Organization classification of lymphoid neoplasms [19]. This condition is increasingly being described in children and adolescents from Asia or Latin America [19]. In these diseases, the EBV-infection is usually thought to occur in T or NK cells, however, precise immunophenotyping and clonality of those cells remains to be elucidated [7-9].

In the present study, we demonstrated ectopic EBV infection of  $\gamma\delta$  T cells and increased subpopulations of  $\gamma\delta$  T cells in the peripheral blood in 3 patients with CAEBV. Interestingly, two of them showed HV-like eruptions. These results were in agreement with recent studies that demonstrated associations between HV and increased numbers of EBV-infected  $\gamma\delta$  T cells [10-12]. In addition, we found that circulating  $\gamma\delta$  T cells were in a highly-activated state in our patients. In normal individuals,  $\gamma\delta$  T cells usually comprise a small proportion of the circulating lymphocyte population. Expansion of the  $\gamma\delta$  T-cell subset has been also documented in the context of various infections including *Mycobacterium* and cytomegalovirus [20]. However, selective activation and expansion of  $\gamma\delta$  T cells may provide us with clinical clues to suspect ectopic EBV infection of  $\gamma\delta$  T cells in children suffering from HV or lymphoproliferative disease. Further investigations are necessary to clarify the major cellular targets of EBV infection and to understand the

pathophysiological link between ectopic EBV infection and the clinical manifestations of the disease.

There was clear evidence of clonal expansion of  $V\gamma 9^+ V\delta 2^+$   $\gamma\delta$  T cells in our patients. We assume that the EBV infection predominantly targeted  $V\gamma 9^+ V\delta 2^+$   $\gamma\delta$  T cells and expanded clonally in the patients. Human  $\gamma\delta$  T cells exhibit a restricted repertoire using a limited set of  $V\gamma$  and  $V\delta$  gene elements compared with  $\alpha\beta$  T cells. There are only 6 functional  $V\gamma$  and 8 functional  $V\delta$  genes in human [21]. At birth, the repertoire of  $\gamma\delta$  T cells in cord blood is broad with no apparent restriction [22]. However, the initially small subset of  $V\gamma 9^+ V\delta 2^+$  cells has been shown to gradually increase with age, resulting in a high frequency of polyclonal  $V\gamma 9^+ V\delta 2^+$  cells in adult peripheral blood [23]. Although careful interpretation of the results of monotypic  $V\gamma 9/V\delta 2$  domain expression is needed, in our cases the predominance of  $V\gamma 9^+ V\delta 2^+$   $\gamma\delta$  T cell was not likely to be age-dependent. The absolute counts of  $V\delta 2^+$   $\gamma\delta$  T cells, as well as the  $V\delta 2$  mRNA levels, in PBMCs were strikingly elevated in our young patients. CDR3 spectratyping of their  $V\delta 2$  segments showed monoclonal peaks that were confirmed by sequence analysis. In addition, Southern blot analysis of EBV terminal repeats indicated monoclonal EBV infection. On the other hand, studies of T cell lines established from 3 patients with nasal T-cell lymphoma or CAEBV have also indicated preferential expansion of EBV-infected  $V\gamma 9/V\delta 2$   $\gamma\delta$  T cells [24]. However, these and our results are insufficient to allow us to draw any conclusion regarding higher susceptibility to EBV infection of  $V\gamma 9^+ V\delta 2^+$   $\gamma\delta$  T cells compared with other  $\gamma\delta$  T cells. Frequent identification of EBV-infected  $V\gamma 9^+ V\delta 2^+$   $\gamma\delta$  T cells could simply be due to a higher percentage of  $V\gamma 9/V\delta 2$   $\gamma\delta$  T cells at the time of infection. The mechanism underlying the ectopic infection also remains elusive.

In patient 1, we have previously demonstrated that approximately 25% of the cells infiltrating into the HV-like eruptions were EBV positive by *in situ* hybridization for EBER-1, and that about 30% of the infiltrating cells appeared to be CD3<sup>+</sup> CD4<sup>-</sup> CD8<sup>-</sup> T cells by immunohistochemical analysis [13]. However, the presence of EBV-infected  $\gamma\delta$  T cells in the skin could not be confirmed because of the lack of a suitable anti-TCR  $\gamma\delta$  antibody for paraffin-embedded tissues. In the present study, our molecular analysis clearly demonstrated the skin infiltration of V $\delta$ 2<sup>+</sup>  $\gamma\delta$  T cells, which were identical to the clonally expanded V $\delta$ 2<sup>+</sup>  $\gamma\delta$  T cells in the peripheral blood and were thus infected by EBV in this patient. In normal individuals,  $\gamma\delta$  T cells take residence mainly in epithelial tissues, such as skin, and represent the major T-cell population there, and modulate epithelial homeostasis through their cytokine secretion and cytolytic properties [25]. It is well known that skin lesions of HV can be induced by repeated ultraviolet exposure [26]. Studies in a murine model for drug-induced cutaneous lupus erythematosus demonstrated that ultraviolet might enhance the function of skin  $\gamma\delta$  T cells that were involved in skin lesions [27]. Therefore, EBV-infected  $\gamma\delta$  T cells may play an important role in the skin lesions of HV. Additional investigation will be required to assess whether the presence of EBV-infected  $\gamma\delta$  T cells in the skin lesions results from ectopic EBV infection into skin-resident  $\gamma\delta$  T cells or migration of EBV-infected  $\gamma\delta$  T cells from peripheral blood after sun exposures.

In summary, our studies demonstrate clonal expansion of EBV-infected  $\gamma\delta$  T cells in  $\gamma\delta$  T cell-type CAEBV, further support the association between EBV-infected  $\gamma\delta$  T cells and HV, and provide the basis for characterization of EBV-infected cells to better understand pathogenesis of EBV-associated lymphoproliferative disorders.



## **Acknowledgments**

The authors declare that they have no conflict of interest. We thank Ms Harumi Matsukawa and Ms. Shizu Kouraba for their excellent technical assistance. This work was supported by a grant from Takeda Science Foundation, Osaka; a Grant-in-Aid for Scientific Research from the Ministry of Education, Culture, Sports, Science and Technology of Japan; and a grant from the Ministry of Health, Labour, and Welfare of Japan, Tokyo.

## References

1. Hislop AD, Taylor GS, Sauce D, Rickinson AB. Cellular responses to viral infection in humans: lessons from Epstein-Barr virus. *Annu Rev Immunol* 2007; **25**:587-617.
2. Cohen JI, Kimura H, Nakamura S, Ko YH, Jaffe ES. Epstein-Barr virus-associated lymphoproliferative disease in non-immunocompromised hosts: a status report and summary of an international meeting, 8-9 September 2008. *Ann Oncol* 2009; **20**:1472-82.
3. Okano M, Kawa K, Kimura H, Yachie A, Wakiguchi H, Maeda A, Imai S, Ohga S, Kanegane H, Tsuchiya S, Morio T, Mori M, Yokota S, Imashuku S. Proposed guidelines for diagnosing chronic active Epstein-Barr virus infection. *Am J Hematol* 2005; **80**:64-9.
4. Kimura H, Hoshino Y, Hara S, Sugaya N, Kawada J, Shibata Y, Kojima S, Nagasaka T, Kuzushima K, Morishima T. Differences between T cell-type and natural killer cell-type chronic active Epstein-Barr virus infection. *J Infect Dis* 2005; **191**:531-9.
5. Gupta G, Man I, Kemmett D. Hydroa vacciniforme: A clinical and follow-up study of 17 cases. *J Am Acad Dermatol* 2000; **42**:208-13.
6. Chen HH, Hsiao CH, Chiu HC. Hydroa vacciniforme-like primary cutaneous CD8-positive T-cell lymphoma. *Br J Dermatol* 2002; **147**:587-91.
7. Iwatsuki K, Xu Z, Takata M, Iguchi M, Ohtsuka M, Akiba H, Mitsunashi Y, Takenoshita H, Sugiuchi R, Tagami H, Kaneko F. The association of latent



- Epstein-Barr virus infection with hydroa vacciniforme. *Br J Dermatol* 1999; **140**:715-21.
8. Cho KH, Lee SH, Kim CW, Jeon YK, Kwon IH, Cho YJ, Lee SK, Suh DH, Chung JH, Yoon TY, Lee SJ. Epstein-Barr virus-associated lymphoproliferative lesions presenting as a hydroa vacciniforme-like eruption: an analysis of six cases. *Br J Dermatol* 2004; **151**:372-80.
  9. Iwatsuki K, Satoh M, Yamamoto T, Oono T, Morizane S, Ohtsuka M, Xu ZG, Suzuki D, Tsuji K. Pathogenic link between hydroa vacciniforme and Epstein-Barr virus-associated hematologic disorders. *Arch Dermatol* 2006; **142**:587-95.
  10. Kimura H, Miyake K, Yamauchi Y, Nishiyama K, Iwata S, Iwatsuki K, Gotoh K, Kojima S, Ito Y, Nishiyama Y. Identification of Epstein-Barr virus (EBV)-infected lymphocyte subtypes by flow cytometric in situ hybridization in EBV-associated lymphoproliferative diseases. *J Infect Dis* 2009; **200**:1078-87.
  11. Kimura H, Ito Y, Kawabe S, Gotoh K, Takahashi Y, Kojima S, Naoe T, Esaki S, Kikuta A, Sawada A, Kawa K, Ohshima K, Nakamura S. EBV-associated T/NK-cell lymphoproliferative diseases in nonimmunocompromised hosts: prospective analysis of 108 cases. *Blood* 2012; **119**:673-86.
  12. Hirai Y, Yamamoto T, Kimura H, Ito Y, Tsuji K, Miyake T, Morizane S, Suzuki D, Fujii K, Iwatsuki K. Hydroa Vacciniforme Is Associated with Increased Numbers of Epstein-Barr Virus-Infected gammadeltaT Cells. *J Invest Dermatol* 2012; **132**:1401-8.
  13. Tanaka C, Hasegawa M, Fujimoto M, Iwatsuki K, Yamamoto T, Yamada K, Kawa K, Saikawa Y, Toga A, Mase S, Wada T, Takehara K, Yachie A.

- Phenotypic analysis in a case of hydroa vacciniforme-like eruptions associated with chronic active Epstein-Barr virus disease of gammadelta T cells. *Br J Dermatol* 2012; **166**:216-8.
14. Toga A, Wada T, Sakakibara Y, Mase S, Araki R, Tone Y, Toma T, Kurokawa T, Yanagisawa R, Tamura K, Nishida N, Taneichi H, Kanegane H, Yachie A. Clinical significance of clonal expansion and CD5 down-regulation in Epstein-Barr Virus (EBV)-infected CD8+ T lymphocytes in EBV-associated hemophagocytic lymphohistiocytosis. *J Infect Dis* 2010; **201**:1923-32.
  15. de Villartay JP, Lim A, Al-Mousa H, Dupont S, Dechanet-Merville J, Coumou-Gatbois E, Gougeon ML, Lemainque A, Eidenschenk C, Jouanguy E, Abel L, Casanova JL, Fischer A, Le Deist F. A novel immunodeficiency associated with hypomorphic RAG1 mutations and CMV infection. *J Clin Invest* 2005; **115**:3291-9.
  16. Ehl S, Schwarz K, Enders A, Duffner U, Pannicke U, Kuhr J, Mascart F, Schmitt-Graeff A, Niemeyer C, Fisch P. A variant of SCID with specific immune responses and predominance of gamma delta T cells. *J Clin Invest* 2005; **115**:3140-8.
  17. Wada T, Schurman SH, Otsu M, Garabedian EK, Ochs HD, Nelson DL, Candotti F. Somatic mosaicism in Wiskott--Aldrich syndrome suggests in vivo reversion by a DNA slippage mechanism. *Proc Natl Acad Sci U S A* 2001; **98**:8697-702.
  18. van Dongen JJ, Langerak AW, Bruggemann M, Evans PA, Hummel M, Lavender FL, Delabesse E, Davi F, Schuurin E, Garcia-Sanz R, van Krieken JH, Droese J, Gonzalez D, Bastard C, White HE, Spaargaren M, Gonzalez M, Parreira A, Smith

- JL, Morgan GJ, Kneba M, Macintyre EA. Design and standardization of PCR primers and protocols for detection of clonal immunoglobulin and T-cell receptor gene recombinations in suspect lymphoproliferations: report of the BIOMED-2 Concerted Action BMH4-CT98-3936. *Leukemia* 2003; **17**:2257-317.
19. Quintanilla-Martinez L KH, Jaffe ES. EBV-positive T-cell lymphoproliferative disorders of childhood. Geneva, Switzerland: World Health Organization, 2008.
  20. Dechanet J, Merville P, Lim A, Retiere C, Pitard V, Lafarge X, Michelson S, Méric C, Hallet MM, Kourilsky P, Potaux L, Bonneville M, Moreau JF. Implication of gammadelta T cells in the human immune response to cytomegalovirus. *J Clin Invest* 1999; **103**:1437-49.
  21. O'Brien RL, Roark CL, Jin N, Aydintug MK, French JD, Chain JL, Wands JM, Johnston M, Born WK. gammadelta T-cell receptors: functional correlations. *Immunol Rev* 2007; **215**:77-88.
  22. Morita CT, Parker CM, Brenner MB, Band H. TCR usage and functional capabilities of human gamma delta T cells at birth. *J Immunol* 1994; **153**:3979-88.
  23. Parker CM, Groh V, Band H, Porcelli SA, Morita C, Fabbi M, Glass D, Strominger JL, Brenner MB. Evidence for extrathymic changes in the T cell receptor gamma/delta repertoire. *J Exp Med* 1990; **171**:1597-612.
  24. Oyoshi MK, Nagata H, Kimura N, Zhang Y, Demachi A, Hara T, Kanegane H, Matsuo Y, Yamaguchi T, Morio T, Hirano A, Shimizu N, Yamamoto K. Preferential expansion of Vgamma9-JgammaP/Vdelta2-Jdelta3 gammadelta T cells in nasal T-cell lymphoma and chronic active Epstein-Barr virus infection. *Am J Pathol* 2003; **162**:1629-38.

25. Komori HK, Meehan TF, Havran WL. Epithelial and mucosal gamma delta T cells. *Curr Opin Immunol* 2006; **18**:534-8.
26. Verneuil L, Gouarin S, Comoiz F, Agbalika F, Creveuil C, Varna M, Vabret A, Janin A, Leroy D. Epstein-Barr virus involvement in the pathogenesis of hydroa vacciniforme: an assessment of seven adult patients with long-term follow-up. *Br J Dermatol* 2010; **163**:174-82.
27. Yoshimasu T, Nishide T, Seo N, Hiroi A, Ohtani T, Uede K, Furukawa F. Susceptibility of T cell receptor-alpha chain knock-out mice to ultraviolet B light and fluorouracil: a novel model for drug-induced cutaneous lupus erythematosus. *Clin Exp Immunol* 2004; **136**:245-54.



**Table 1. Junctional amino acid sequences of  $\gamma\delta$  T cells**

	DV	N-D-N	DJ	Frequency	
<b>PBMCs, V<math>\delta</math>2</b>					
Control	YCACD	SLNRGTSRD	TDKLIFGKGTRVTVEPR	1/18	
	YCACD	TVGGPD	YTDKLIFGKGTRVTVEPR	1/18	
	YCACDT	GFGGILS	SWDTRQMFFGTGIKLFVEPR	1/18	
	YCACD	SLGDTPP	YTDKLIFGKGTRVTVEPR	1/18	
	YCACDT	VGGVPES	YTDKLIFGKGTRVTVEPR	1/18	
	YCAC	EPLGGGY	YTDKLIFGKGTRVTVEPR	1/18	
	YCACDT	LQ	YTDKLIFGKGTRVTVEPR	1/18	
	YCACD	TVRGSVLGDTL	TDKLIFGKGTRVTVEPR	1/18	
	YCACD	IWGNA	DKLIFGKGTRVTVEPR	1/18	
	YCACD	ILGTGA	DKLIFGKGTRVTVEPR	1/18	
	YCAC	VGLGAH	DKLIFGKGTRVTVEPR	1/18	
	YCACDT	VELGDPTV	TDKLIFGKGTRVTVEPR	1/18	
	YCACD	PVGVT	YTDKLIFGKGTRVTVEPR	1/18	
	YCACD	FILTRGIS	KLIFGKGTRVTVEPR	1/18	
	YCACD	PLRTGGHS	DKLIFGKGTRVTVEPR	1/18	
	YCACD	TAGRA	YTDKLIFGKGTRVTVEPR	1/18	
	YCAC	VPLGNH	DKLIFGKGTRVTVEPR	1/18	
	YCACD	LLGDDEGY	KLIFGKGTRVTVEPR	1/18	
	Patient 1	YCACD	ILGD	MTAQLFFGKGTQLIVEPG	24/24
	Patient 2	YCACD	SLTGGF	TDKLIFGKGTRVTVEPR	25/27
YCACD		SLAGGF	TDKLIFGKGTRVTVEPR	1/27	
YCACG		SLTGGF	TDKLIFGKGTRVTVEPR	1/27	
Patient 3	YCACD	TGGYA	SWDTRQMFFGTGIKLFVEPR	27/30	
	YCACD	TGGYA	SWDARQMFFGTGIKLFVEPR	1/30	
	YCACD	TGGYA	SWDTRQMLFGTGIKLFVEPR	1/30	
	YCACD	TGGYA	SWDTRQMFIGTGIKLFVEPR	1/30	
<b>Skin, V<math>\delta</math>2-J<math>\delta</math>2</b>					
Patient 1	YCACD	ILGD	MTAQLFFGKGTQLIVE	12/12	

## **Figure Legends**

### **Figure 1. Characterization of EBV-infected cells**

(A) Detection of EBER-1<sup>+</sup> cells in  $\gamma\delta$  T cells from patient 3. (B-D) Frequency of EBV-infected cells. The percentage of EBER-1<sup>+</sup> cells within the patients' lymphocyte subsets are shown in patient 1 (b), patient 2 (c), and patient 3 (d).

### **Figure 2. Immunophenotype of $\gamma\delta$ T cells**

(A) Expression profiles of T-cell receptor (TCR) V $\delta$  subfamilies. Peripheral blood samples were stained with mAbs for anti-TCR V $\delta$ 1 or anti-TCR V $\delta$ 2 together anti-TCR Pan  $\gamma\delta$  mAb. The percentage of cells was analyzed by flow cytometry and expressed with respect to the total lymphocyte population. (B) Activation status of  $\gamma\delta$  T cells. Expression of HLA-DR was evaluated in  $\gamma\delta$  T cells.

### **Figure 3. CDR3 spectratyping and TCR V $\delta$ 2 mRNA copies**

(A) CDR3 size distribution of TCR V $\delta$ . Each TCR V $\delta$  fragment was amplified from the cDNA with specific primers. The size distribution of the polymerase chain reaction (PCR) products was determined by an automated sequencer and GeneScan software. (B) TCR V $\delta$ 2 mRNA was determined by real-time quantitative RT-PCR. Data was normalized to  $\beta$ -actin expression and represent the mean ( $\pm$  standard deviation) of 3 independent experiments. (C) CDR3 size distribution of TCR V $\gamma$ . Each TCR V $\gamma$  fragment was amplified from the cDNA with specific primers.

**Figure 4. TCR V $\delta$  genomic sequences in the skin lesion from patient 1**

(A) Each TCR V $\delta$  fragment was amplified from skin DNA with one of 6 TCR V $\delta$ -specific forward primers and a combination of 4 TCR J $\delta$ -specific reverse primers. (B) Each TCR J $\delta$  fragment was amplified with the TCR V $\delta$ 2-specific forward primer and one of 4 TCR J $\delta$ -specific reverse primers. Lane M, 100-bp molecular marker.



Figure 1

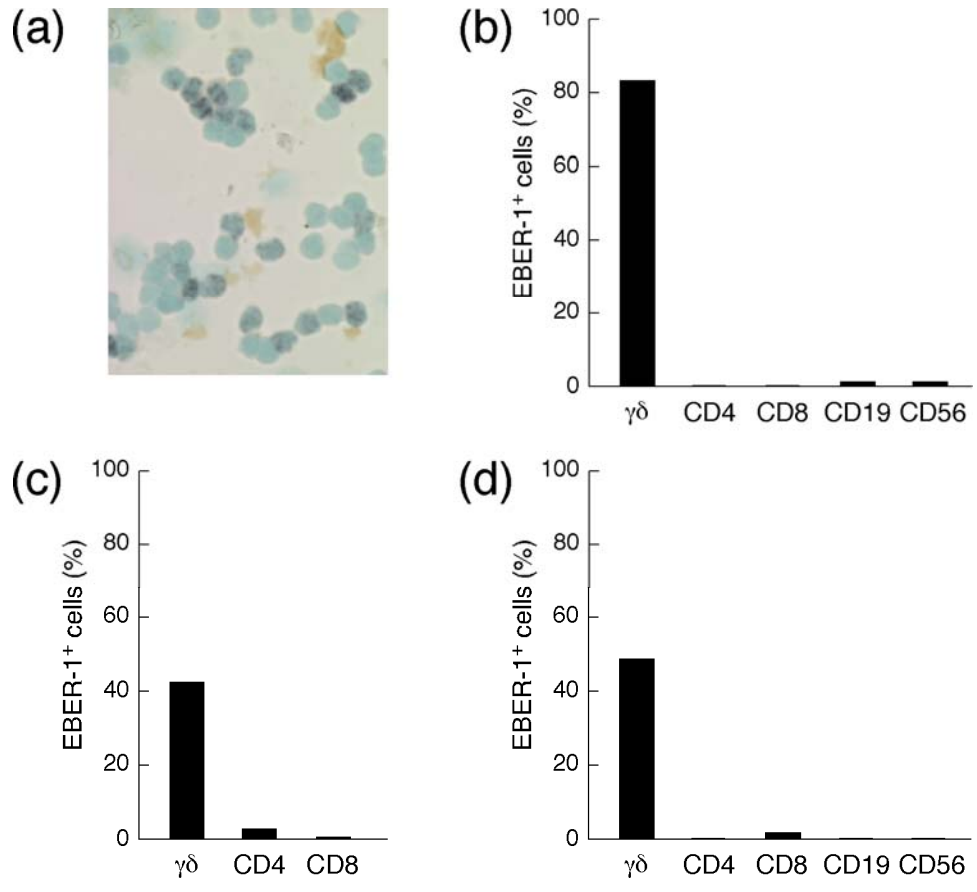


Figure 2

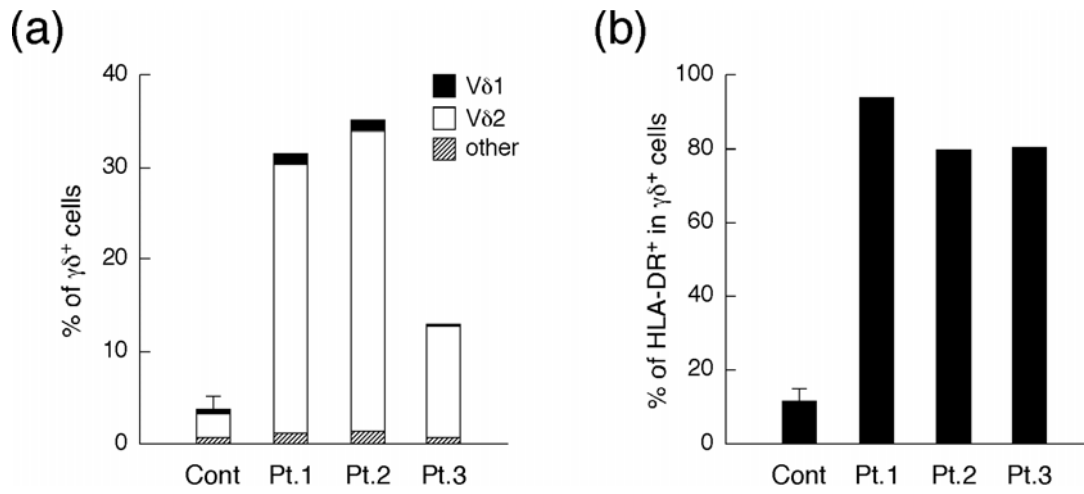


Figure 3

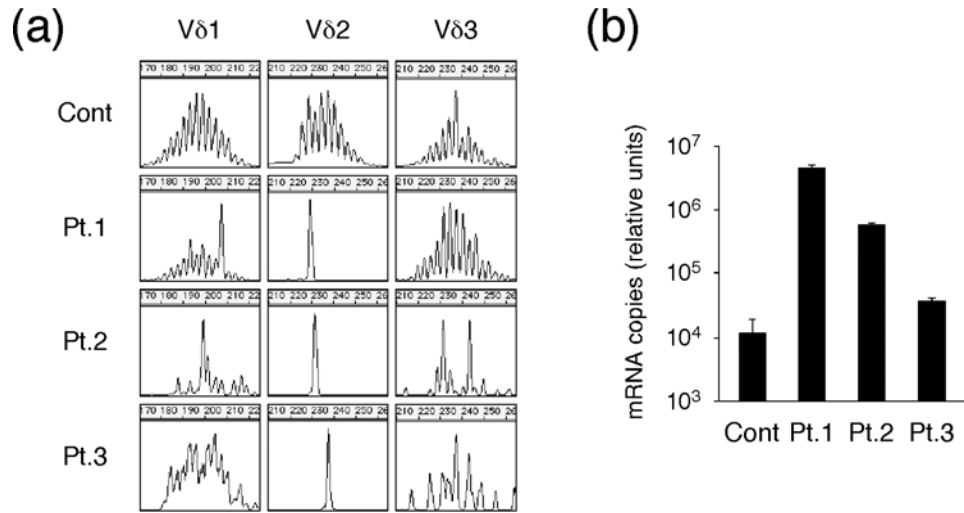


Figure 4

