# Inclusion body myositis with granuloma formation in muscle tissue


| メタデータ | 言語: English<br>出版者:<br>公開日: 2017-10-05<br>キーワード (Ja):<br>キーワード (En):<br>作成者: Sakai, Kenji, Ikeda, Yoshihisa, Ishida, Chiho, Matsumoto, Yasuko, Ono, Kenjiro, Iwasa, Kazuo, Yamada, Masahito<br>メールアドレス:<br>所属: |
| --- | --- |
| URL | http://hdl.handle.net/2297/43019 |

# Inclusion body myositis with granuloma formation in muscle tissue

Kenji Sakai [a], Yoshihisa Ikeda [a,b], Chiho Ishida [a,b], Yasuko Matsumoto [a,c], Kenjiro Ono [a], Kazuo Iwasa [a], Masahito Yamada [a]

[a] Department of Neurology and Neurobiology of Aging, Kanazawa University Graduate School of Medical Sciences, Kanazawa, Japan

[b] Department of Neurology, National Hospital Organization Iou Hospital, Kanazawa, Japan

[c] Department of Neurology, Ishikawa Prefectural Central Hospital, Kanazawa, Japan

Correspondence to: Dr Kenji Sakai
Department of Neurology and Neurobiology of Ageing, Kanazawa University
Graduate School of Medical Science
13-1 Takara-machi, Kanazawa 920-8640, Japan
Fax: +81-76-234-4253
Phone: +81-76-265-2292
E-mail: ksakai@med.kanazawa-u.ac.jp

Conflicts of interest

None

Author contributions

Dr. Sakai: study concept and design, analysis and interpretation of data, statistical analysis, drafting/revising the manuscript. Dr. Ikeda, Dr. Ishida, Dr. Mastumoto and Dr. Ono: clinical data collection, pathological examination of muscle tissues, and revising the manuscript. Dr. Iwasa: collection and interpretation of data, pathological examination, drafting/revising the manuscript. Dr. Yamada: drafting/revising the manuscript, study supervision.

Funding source

This work was not supported by any grant.

**Abstract**

Inclusion body myositis is a form of inflammatory myopathy. We identified 4 cases of inclusion body myositis showing granuloma formation in muscle tissue and aimed to assess the features of this atypical form of the inclusion body myositis.

We retrospectively reviewed consecutive patients who satisfied European Neuromuscular Centre IBM Research Diagnostic Criteria 2011. Then, we assessed clinical profiles and pathological findings in patients with inclusion body myositis with granuloma and compared these findings with those of typical inclusion body myositis without granuloma.

We identified 15 patients with inclusion body myositis. Four patients showed granuloma formation in muscle tissue in addition to typical pathological features of inclusion body myositis. Granulomas comprised a mixture of inflammatory cells, such as macrophages, epithelioid histiocytic cells, and lymphocytes. One patient was found to have mediastinal granulomatous lymphadenopathy; however, the evidence in other patients was insufficient for a diagnosis of systemic sarcoidosis. There were no significant differences between groups with and without granuloma regarding clinical manifestations, laboratory

findings, response to immunomodulating therapies, or myopathological profiles.

We established a new form of inclusion body myositis showing granuloma formation in muscle tissue. Inclusion body myositis and granuloma formation could have identical pathomechanisms concerning dysregulation of autophagy.

(198 words)

Key words: inclusion body myositis; granuloma; rimmed vacuole; autophagy

**Abbreviations**

COX, cytochrome C oxidase; ENMC, the European Neuromuscular Centre; GM, granulomatous myositis; HE, hematoxylin and eosin; HLA, human leukocyte antigen; IBM, inclusion body myositis; IVIg, intravenous immunoglobulin; TLR, toll-like receptor

## 1. Introduction

Inclusion body myositis (IBM) is a type of inflammatory myopathy characterized by T lymphocyte infiltration around muscle fibers and the presence of rimmed vacuoles [1]. In comparison to other types of inflammatory myopathy, including polymyositis and dermatomyositis, patients with IBM demonstrate an unfavorable response to immunosuppressive therapy [1]. The pathomechanisms of IBM remain uncertain. Inflammatory processes and degenerative mechanisms are both responsible for the development of this muscular disorder.

Granulomas are pathological structures comprising giant cells, macrophage-like epithelioid cells, and lymphocytes. The most common condition associated with non-caseating granuloma formation in muscle tissues is sarcoidosis

followed by foreign-body reactions and infectious conditions; however, granulomatous myositis (GM) is a type of inflammatory myopathy containing granulomas without any evidence of systemic sarcoidosis despite intensive clinical investigations [2].

Although there are several reported cases that presented features of both IBM and sarcoidosis [3-5], the relationship between IBM and granuloma formation remains to be clarified. In this study, we identified 4 patients with IBM showing granuloma formation in muscle tissues. Somewhat surprisingly, granulomas were confined to skeletal muscle in 3 patients. This study aimed to elucidate the features of IBM with granuloma by comparing these features with the clinical and histopathological features of patients with typical IBM.

## 2. Materials and methods

### *2.1 Patients*

We retrospectively reviewed consecutive patients who underwent an open muscle biopsy in our hospital and were referred to our department for pathological diagnosis of muscle biopsies between 2003 and 2013. We selected IBM patients who satisfied

the European Neuromuscular Centre (ENMC) IBM Research Diagnostic Criteria 2011 [6], and applied the classification as follows: clinicopathologically defined IBM, clinically defined IBM, and probable IBM.

Medical records were retrospectively reviewed for age at diagnosis, sex, sites of initial weakness, and duration from onset to diagnosis. The following laboratory features determined at the time of diagnosis were obtained: the levels of serum creatine kinase, lactate dehydrogenase, aldolase, and myoglobin; levels of plasma C-reactive protein; and erythrocyte sedimentation rate. In addition, we examined the presence of serum autoantibodies suggestive of other collagen disorders, hepatitis B antigens, and hepatitis C antibodies.

Special attention was paid to patients showing granulomas in muscle to exclude the possibility of systemic sarcoidosis. A clinical diagnosis of sarcoidosis could be made on the basis of clinical, laboratory, and radiological features in addition to evidence of non-caseating granulomas in tissues. Moreover, it is essential to exclude alternative diseases [7]. In terms of clinical presentation, pulmonary symptoms and abnormal chest radiographs including bilateral hilar lymphadenopathy are common; however, rarely patients may show only extrapulmonary manifestations

[7.] Granulomatous myositis is a type of myositis characterized by granuloma formation in muscle tissue, variable response to immunosuppressive therapies, and no evidence of systemic sarcoidosis [2]. Although it is uncertain whether GM is a limited form of systemic sarcoidosis, not all patients with GM develop symptoms of sarcoidosis [8]. To avoid making a diagnosis of sarcoidosis, the patients with IBM showing granuloma underwent intensive examinations, which included ophthalmological examinations, chest radiographs, and whole body examinations. Other disorders which might cause granulomatous myositis, such as tuberculosis infection, lymphoma, intestinal inflammatory disease, myasthenia gravis, foreign-body reaction, cryofibrinogenemia, and primary biliary cirrhosis [2], were excluded carefully by performing radiological and clinical investigations.

Most patients received immunosuppressive therapy as follows: corticosteroids (prednisone and methylpredonisolone), immunosuppressive drugs, and intravenous immunoglobulin (IVIg). The results of these treatments were examined by retrospectively reviewing the medical records.

Written informed consent to participate in this study was obtained from the patients. The study protocol was approved by the medical ethics committee of

Kanazawa University.

*2.2 Pathological examinations*

Muscle biopsies were performed in all patients. All samples were obtained by open biopsies and divided into several blocks. Some specimens were immediately frozen in isopentane cooled with liquid nitrogen and stored at -80˚C until the experiments. Serial 6-μm-thick cryostat sections were cut and stained with hematoxylin and eosin (HE), modified Gomori trichrome, NADH-tetrazolium, Congo Red, and cytochrome C oxidase (COX). The remaining samples were fixed with 10% buffered formalin. Pathological examinations were also performed on 5-μm-thick sections of paraffin embedded blocks using HE and Congo Red.

Selected formalin-fixed sections were immunostained with antibodies against phosphorylated neurofilaments (SMI-31; Covance, Emeryville, CA; 1:500), amyloid β protein (4G8; Covance; 1:5000), ubiquitin (Dako, Glöstrup, Denmark; 1:8000), macrophages (CD68; Dako; 1:100), T lymphocytes (CD3; Dako; 1:20), B lymphocytes (CD20; Dako; 1:50), helper T lymphocytes (CD4; Dako; 1:400), and cytotoxic T lymphocytes (CD8; Dako; 1:20) using appropriate antigen retrieval

methods. Immunohistochemistry using antibodies against human leukocyte antigen-I (HLA-I; Dako; 1:200) and HLA-II (Dako, 1:100) was performed on frozen sections. The EnVision system (Dako) was used for these immunolabeling studies. Peroxidase labeling was visualized with diaminobenzidine as the chromogen.

Granulomas were defined as collections of inflammatory cells in which more than 60% of the inflammatory cells were macrophages or epithelioid histiocytic cells, as judged by HE or specific macrophage marker staining (CD68). The presence of Langerhans-type or histiocytic giant cells was unnecessary to be judged as granulomas [9]. We paid special attention to exclude necrotic regions to avoid including caseating granulomas [9].

*2.3 Case classification*

With reference to the pathological features of IBM (endomysial inflammatory infiltrates; rimmed vacuoles; protein accumulation; and upregulation of HLA class I around muscle fibers), we made a clinicopathological diagnosis of IBM [6]. Patients who demonstrated only these features were designated as typical IBM without granuloma group. Patients showing granuloma formation in addition to typical IBM

clinicopathologic characteristics were categorized into the IBM with granuloma group.

*2.4 Statistical analysis*

Differences in age at disease onset and in the results of laboratory tests between the typical IBM without granuloma group and the IBM with granuloma group were assessed using a Mann-Whitney *U* test. Sex, diagnosis classification of IBM, initial weakness, and pathological findings were assessed using chi-square test and Fisher's exact probability test. Statistical significance was defined as $p < 0.05$. Statistical analyses were performed using SPSS version 22 (IBM, Armonk, NY).

## 3. Results

*3.1 Clinical profiles*

A total of 307 patients with myopathy were analyzed in our department during the study period. Fifteen patients satisfied the clinical diagnostic criteria of IBM [6]. Five patients were categorized as clinicopathologically defined IBM. Four and 6 patients were categorized as clinically defined IBM and probable IBM, respectively.

Granuloma formation in muscle tissues was noted in 4 patients. In these patients, one patient met the criteria for clinicopathologically defined IBM, whereas 2 and 1 patients were categorized as clinically defined IBM and probable IBM, respectively.

Regarding IBM patients with granuloma, clinical features are summarized in Table 1. One patient (patient 4) experienced dysphagia. One patient (patient 3) showed lymphadenopathy with non-caseating granulomas in the mandibular region and mediastinum; however, clinical features suggesting sarcoidosis, such as bilateral hilar lymphadenopathy on chest radiography, erythema nodosum, uveitis, and maculopapular skin lesions, were absent. Other patients had none of the above clinical or laboratory findings considered suggestive of sarcoidosis. Several simultaneous diseases were observed in patients 2, 3 and 4 including hematological diseases and autoimmune disorders. Patient 2 received a diagnosis of Sjögren syndrome and myelodysplastic syndrome. Diagnosis of thyroiditis was given in patients 3 and 4. Patient 3 have also suffered from interstitial pneumonitis. All patients received several immunomodulating treatments, including oral prednisone, methylpredonisolone pulse therapy, IVIg, and oral administration of tacrolimus. No improvements were observed after the treatments.

A comparison of clinical manifestations and laboratory findings between the typical IBM without granuloma group and IBM with granuloma group are summarized in Table 2. There were no significant differences regarding the clinical profile between these groups. Several patients in the typical IBM without granuloma group were also positive for anti-nuclear antibody, anti-mitochondrial antibody, anti Ro/SS-A antibody, and exhibited a combined infection with hepatitis B virus and hepatitis C virus. Although patients with typical IBM received immunomodulating treatments, such as oral prednisone, IVIg, and immunosuppressants, all patients showed progression of muscular weakness regardless of the treatments administered. Additionally, 2 patients were observed but were not treated apart from physical rehabilitation and exhibited slowly progressive muscular weakness.

*3.2 Pathological findings*

The quadriceps femoris muscle was the most frequently biopsied muscle in this series; however, 3 patients underwent a biopsy of the biceps brachii muscle. The tibialis anterior muscle and semimembranous muscle were selected in 3 patients.

All patients demonstrated pathological features typical of IBM, including

many necrotic and regenerating fibers alongside CD8-positive T lymphocytes, mononuclear cell infiltration, a variable amount of rimmed vacuoles, positive HLA-I expression and protein accumulation in vacuoles (Figs 1A-C; Table 3). Several cases demonstrated small amount of COX-deficient fibers. In addition to theses typical structures as IBM, several granulomas were detected in the muscle tissues of the IBM with granuloma group (Figs 1A, D, E, 2A). The granulomas comprised a mixture of inflammatory cells, such as epithelioid histiocytic cells surrounded by lymphocytes. These epithelioid cells showed macrophage-like features and were CD68 positive (Figs 2A-C). No apparent multinucleated cells were observed in any patient. Most of the lymphocytes around epithelioid cells were CD4-positive cells consistent with typical granulomas (Figs 2C-F) [10]. As regards the myopathological findings except for the presence of granuloma, there were no significant differences between the two groups (Table 3).

## 4. Discussion

We identified IBM with granuloma formation in the muscle tissues of 4 (27%) of 15 consecutive patients who underwent muscle examinations. All patients met current

clinocopathological diagnostic criteria for IBM [6, 11]. Although mediastinal lymph node granulomas were histologically demonstrated in patient 3, other patients demonstrated granuloma formation confined to muscle tissues as determined by intensive examinations. Hence, no patients received a diagnosis of sarcoidosis because of inadequate evidence.

Granulomas are structures associated with reaction to a foreign environment [2]. There are several reports of patients with GM showing the following features: myositis with granuloma, no evidence of sarcoidosis, and a good response to immunotherapy [2, 9]. Somewhat interestingly, some GM patients mimicked IBM in clinical characteristics; however, these cases showed no pathological features consistent with IBM, such as rimmed vacuole, amyloid deposition or abnormal protein accumulation in muscle fiber [12]. In a large muscle biopsy series, 12 cases (0.4%) of 2985 specimens were identified as having granulomatous inflammation [8]. It is well known that some patients with sarcoidosis demonstrate asymptomatic granuloma formation in muscle; however, microscopic criteria for the differentiation of sarcoid lesions from other granulomatous myopathies are still lacking[10]. The relationship between GM and the limited lesions of sarcoidosis in muscle remains unknown.

It is uncertain whether granuloma formation in patients with the typical clinicopathologic characteristics of IBM is a coincidence or not. There are several case reports showing a combination of sarcoidosis and IBM [3, 5]. Clinical manifestations related to sarcoidosis preceded IBM in all reported cases. The authors of the above mentioned cases assumed that sarcoidosis was responsible for inducing IBM under uncertain circumstances [3, 5]. We presume that IBM and granuloma might share a similar pathogenesis on account of the following reasons. Firstly, our cases of IBM with granuloma formation were indistinguishable from typical IBM in terms of the clinicopathologic profiles, including clinical manifestations, pathological findings, and an unfavorable response to therapy (Tables 2 and 3), suggesting that IBM with granuloma could be a form of IBM. Secondly, inflammatory and degenerative mechanisms in IBM closely interrelate with each other [13]. A mouse model of IBM showing augmenting amyloid β protein in skeletal muscle demonstrated inclusion bodies and inflammatory infiltrates [14]. Abnormal protein accumulation in muscle fiber is a typical pathological feature of IBM patients. Deposited proteins acknowledged as foreign bodies against immune systems might develop granuloma formation. Finally, IBM and granuloma could share the same pathomechanistic

background. Sarcoidosis and IBM are Th1-mediated immune diseases [7, 15]. Toll-like receptors (TLRs) are pattern-recognition receptors of the innate immune system that recognize conserved microbial motifs [16], and are involved in autophagy [17]. Mechanisms involving autophagy dysregulation are observed in IBM [18]. TLRs are also associated with inflammation in idiopathic inflammatory myopathies including IBM [16, 18]. Toll-like receptor 2 (TLR2), a member of the TLR family, is associated with activation of granulomatous inflammation in sarcoidosis [19]. Furthermore, autophagy-related genes may contribute to granuloma formation [20].

In conclusion, we established a new form of IBM showing granuloma formation. Our results suggest that IBM with granuloma is identical to typical IBM in terms of the clinicopathological profile and an unfavorable response to immunomodulating therapies. We presume that IBM and granuloma formation could share similar pathomechanisms in terms of autophagy dysregulation. Further cases are necessary to clarify in detail the significance of granulomas in patients with IBM.

(2,074 words)

**Acknowledgements**

The authors thank Yumiko Kakuda and Yukari Yamaguchi for their excellent technical assistance.

**References**

1. Mikol J, Engel AG. Inclusion body myositis, in: Engel AG, Franzini-Armstrong C (Eds.), Myology, 3rd ed., McGraw-Hill, New York, 2004, pp. 1367–88.

2. Prieto-González S, Grau JM. Diagnosis and classification of granulomatous myositis. Autoimmun Rev 2014;13:372–4.

3. Danon MJ, Perurena OH, Ronan S, et al. Inclusion body myositis associated with systemic sarcoidosis. Can J Neurol Sci 1986;13:334–6.

4. Mhiri C, Gherardi R. Inclusion body myositis in French patients. A clinicopathological evaluation. Neuropathol App Neurobiol 1990;16:333–44.

5. Vattemi G, Tonin P, Marini M, et al. Sarcoidosis and inclusion body myositis. Rheumatology 2008;28:1433–5.

6. Rose MR, ENMC IBM Working Group. 188th ENMC international workshop: inclusion body myositis, 2–4 December 2011, Naarden, the Netherlands. Neuromuscul Disord 2013;23:1044–55.

7. Valeyre D, Prasse A, Nunes H, et al. Sarcoidosis. Lancet 2014;383:1155–67.

8. Prayson RA. Granulomatous myositis. Clinicopathologic study of 12 cases. Am J Clin Pathol 1999;112:63–8.

9. Le Roux K, Streichenberger N, Vial C, et al. Granulomatous myositis: a clinical study of thirteen cases. Muscle Nerve 2007;35:171–7.

10. Banker BQ, Engel AG. Other inflammatory myopathies. in: Engel AG, Franzini-Armstrong C (Eds.), Myology, 3rd ed., McGraw-Hill, New York, 2004, pp. 1445–72.

11. Lloyd TE, Mammen AL, Amato AA, et al. Evaluation and construction of diagnostic criteria for inclusion body myositis. Neurology 2014;83:426-33.

12. Larue S, Maisonobe T, Benveniste O, et al. Distal muscle involvement in granulomatous myositis can mimic inclusion body myositis. J Neurol Neurosurg Psychiatry 2011;82:674–7.

13. Benveniste O, Stenzel W, Hilton-Jones D, Sandri M, Boyer O, van Engelen BGM. Amyloid deposits and inflammatory infiltrates in sporadic inclusion body myositis: the inflammatory egg comes before the degenerative chicken. Acta Neuropathol 2015;129:611–24.

14. Kitagawa M, Green KM, Caccamo A, LaFerla FM. Genetically augmenting Aβ42 levels in skeletal muscle exacerbates inclusion body myositis-like pathology and motor deficits in transgenic mice. Am J Pathol 2006;168:1986–97.

15. De Paepe B, De Keyzer K, Martin J, et al. Alpha-chemokine receptors CXCR1–3 and their ligands in idiopathic inflammatory myopathies. Acta Neuropathol 2005;109:576–82.

16. Brunn A, Zornbac K, Hans VH, et al. Toll-like receptors promote inflammation in idiopathic inflammatory myopathies. J Neuropathol Exp Neurol 2012;71:855–67.

17. Delgado MA, Elmaoued RA, Davis AS, et al. Toll-like receptors control autophagy. EMBO J 2008;27:1110–21.

18. Cappelletti C, Galbardi B, Kapetis D, et al. Autophagy, inflammation and innate immunity in inflammatory myopathies. PloS One 2014;9:e111490.

19. Chen ES, Song Z, Willett MH, et al. Serum amyloid A regulates granulomatous inflammation in sarcoidosis through Toll-like receptor-2. Am J Respir Crit Care Med 2010;181:360–73.

20. Brinar M, Vermeire S, Cleynen I, et al. Genetic variants in autophagy-related genes and granuloma formation in a cohort of surgically treated Crohn's disease patients. J Crohns Colitis 2012;6:43–50.

**Figure captions**

Figure 1. Muscle biopsy findings in patients with inclusion body myositis (IBM) with granuloma. Severe myopathic changes showing variations in fiber size, and infiltration of adipose tissue with granuloma formation (A). Typical myopathologic features of IBM, including mononuclear cell infiltration in the endomysium with scattered rimmed vacuoles (B, C). Granulomas comprising epithelioid cells surrounded by lymphocytes in the endomysium (D, E). A from patient 1; B-D from patient 2; E from patient 4. A, D, E hematoxylin and eosin stain; B, C modified Gomori-trichrome stain. Bars 100 μm for A, 50 μm for B-E.

Figure 2. Immunohistochemical profiles of the granuloma in patient 3. Granuloma formation (A) was observed in muscle tissue comprising CD68-positive epithelioid cells (B), CD3- (C) and CD4-positive (D) T lymphocytes. CD8-positive T lymphocytes were less numerous than CD4-positive cells (E). Few CD20-positive B lymphocytes were identified (F). A hematoxylin and eosin stain. Bars = 100 μm.

Table 1. Profiles of patients with inclusion body myositis with granuloma formation

| | Patient 1 | Patient 2 | Patient 3 | Patient 4 |
|---|---|---|---|---|
| Age (onset; years) | 51 | 59 | 56 | 67 |
| Sex | Female | Male | Male | Female |
| Diagnosis classification | Clinically defined | Probable | Clinicopathologically defined | Clinically defined |
| Duration until diagnosis (months) | 72 | 30 | 192 | 28 |
| Granulomas in other organs | None | None | Lymph nodes | None |
| Laboratory results | | | | |
| CK (IU/L) | 1765 | 385 | 1447 | 246 |
| LDH (IU/L) | 575 | 294 | 582 | 244 |
| Aldolase (IU/L) | 16 | N.E. | 22 | 6 |
| Myoglobin (ng/ml) | N.E. | 464.7 | 300 | 139.1 |
| CRP (mg/dl) | 0 | 0.2 | 0.2 | 0 |
| ESR (mm; 1 hour) | 16 | 25 | 12 | 31 |
| Other disorders | None | Sjögren syndrome, MDS | IP, thyroiditis | Thyroiditis |
| Therapy | Corticosteroids | Corticosteroids | Corticosteroids, IVIg, TAC | Corticosteroids, TAC |
| Response | No | No | No | No |

CK, creatine kinase; CRP, C-reactive protein; ESR, erythrocyte sedimentation rate; IP,

interstitial pneumonitis; IVIg, intravenous immunoglobulin; LDH, lactate dehydrogenase ; MDS, myelodysplastic syndrome; N.E., not examined; TAC, tacrolimus

Table 2. Clinical features of patients with inclusion body myositis (IBM) with and without granuloma formation

| | Total | Typical IBM without granuloma | IBM with granuloma | *p* value* |
|---|---|---|---|---|
| | n = 15 | n = 11 | n = 4 | |
| Age at diagnosis (median years with range) | 62 (51–84) | 70 (51–84) | 58 (51–67) | *p* = 0.169 |
| Male/female | 9/6 | 7/4 | 2/2 | *p* = 0.538 |
| Diagnosis classification of IBM | | | | |
| Clinicopathologically defined | 5 | 4 | 1 | *p* = 0.464 |
| Clinically defined | 4 | 2 | 2 | |
| Probable | 6 | 5 | 1 | |
| Initial weakness | | | | |
| Oral | 0 | 0 | 0 | *p* = 0.637 |
| Arm | 3 | 2 | 1 | |
| Leg | 12 | 9 | 3 | |
| Duration until diagnosis (median months with range) | 48 (12–192) | 48 (12–84) | 51 (28–192) | *p* = 0.395 |
| Laboratory results (median with range) | | | | |
| CK (IU/L) | 491 (186–1765) | 491 (186–1469) | 916 (246–1765) | *p* = 0.601 |

| | Total | Typical IBM without granuloma | IBM with granuloma | *p* value* |
|---|---|---|---|---|
| LDH (IU/L) | 288 (166–582) | 279 (166–370) | 435 (244-582) | *p* = 0.192 |
| Aldolase (IU/L) | 10 (3–22) | 9 (3–17) | 16 (6–22) | *p* = 0.309 |
| Myoglobin (ng/ml) | 360 (67–563) | 419 (67–563) | 300 (139-465) | *p* = 0.732 |
| CRP (mg/dl) | 0.14 (0–0.6) | 0.14 (0.01–0.6) | 0.1 (0-0.2) | *p* = 0.390 |
| ESR (mm/hour) | 25 (12–64) | 25 (13–64) | 21 (12-31) | *p* = 0.286 |

IBM, inclusion body myositis; CK, creatine kinase; CRP, C-reactive protein; ESR, erythrocyte sedimentation rate; LDH, lactate dehydrogenase

* *p* value was assessed between the typical IBM group and the IBM with granuloma group.

Table 3. Pathological features of the muscles of patients with inclusion body myositis (IBM) with and without granuloma formation

| | Total<br><br>n = 15 | Typical IBM without granuloma<br>n = 11 | IBM with granuloma<br>n = 4 | *p* value* |
|---|---|---|---|---|
| Biopsied muscle | Biceps brachialis 3<br>Quadriceps 8<br>Tibialis anterior 2<br>Semimembranous 1 | Biceps brachialis 2<br>Quadriceps 6<br>Tibialis anterior 2 | Biceps brachialis 1<br>Quadriceps 2<br>Semimembranous 1 | |
| Inflammatory cell infiltration | 11/15 | 7/11 | 4/4 | $p = 0.242$ |
| Rimmed vacuole | 15/15 | 11/11 | 4/4 | –† |
| Congo Red-positive structures | 1/15 | 0/11 | 1/4 | $p = 0.267$ |
| COX-deficient fibers | 5/15 | 4/11 | 1/4 | $p = 0.593$ |
| Aβ-positive inclusions‡ | 6/13 | 4/10 | 2/3 | $p = 0.437$ |
| Ubiquitin-positive inclusions‡ | 10/13 | 8/10 | 2/3 | $p = 0.580$ |
| HLA-I positive | 13/15 | 9/11 | 4/4 | $p = 0.524$ |
| HLA-II positive | 5/15 | 3/11 | 2/4 | $p = 0.459$ |

Aβ, amyloid β protein; COX, cytochrome C oxidase; HLA, human leukocyte antigen;

IBM, inclusion body myositis

* *p* value was assessed between the typical IBM group and the IBM with granuloma group.

† *p* value was not able to be calculated.

‡ Paraffin-embedded sections were unavailable for one case in both groups.

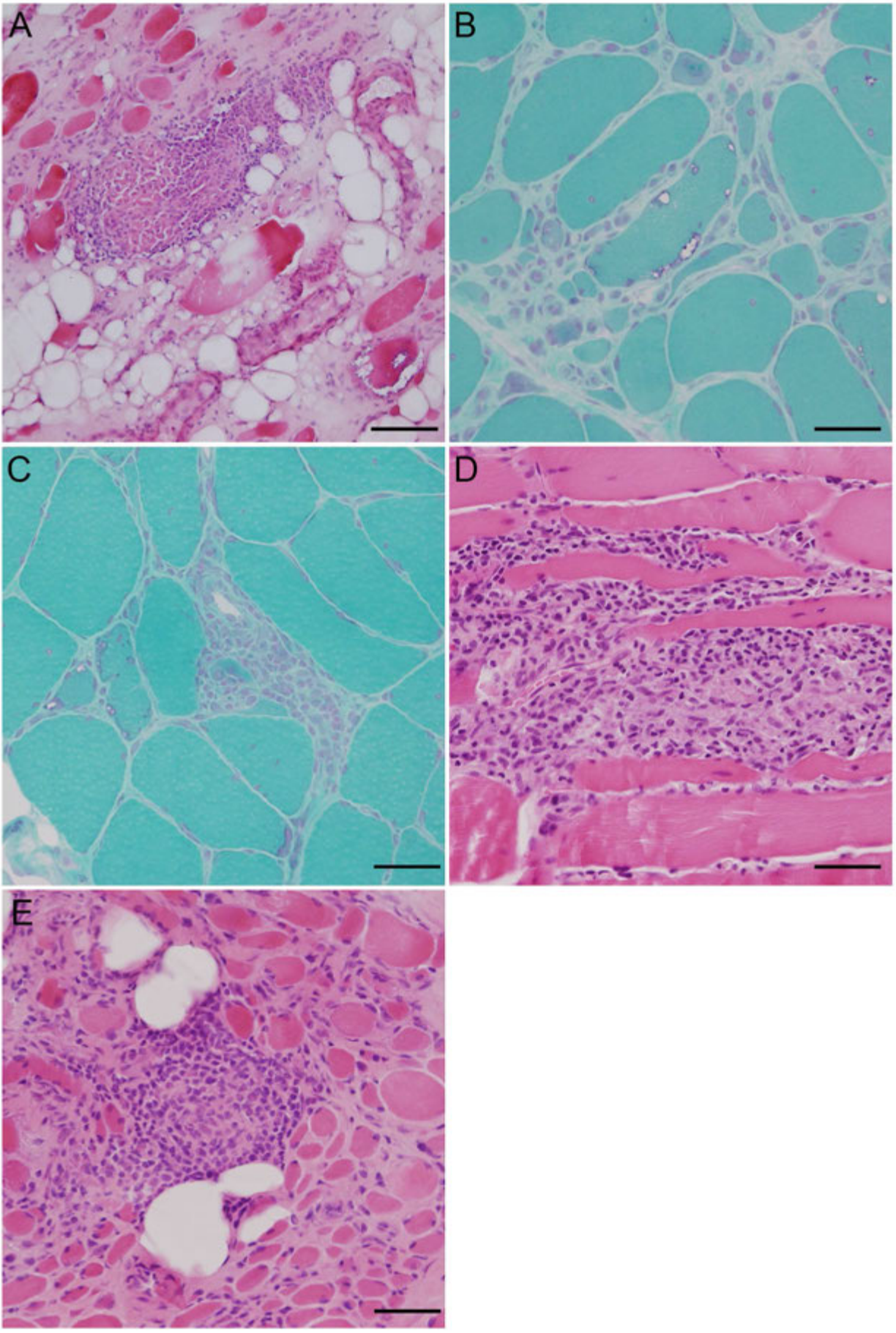
A
B
C
D
E

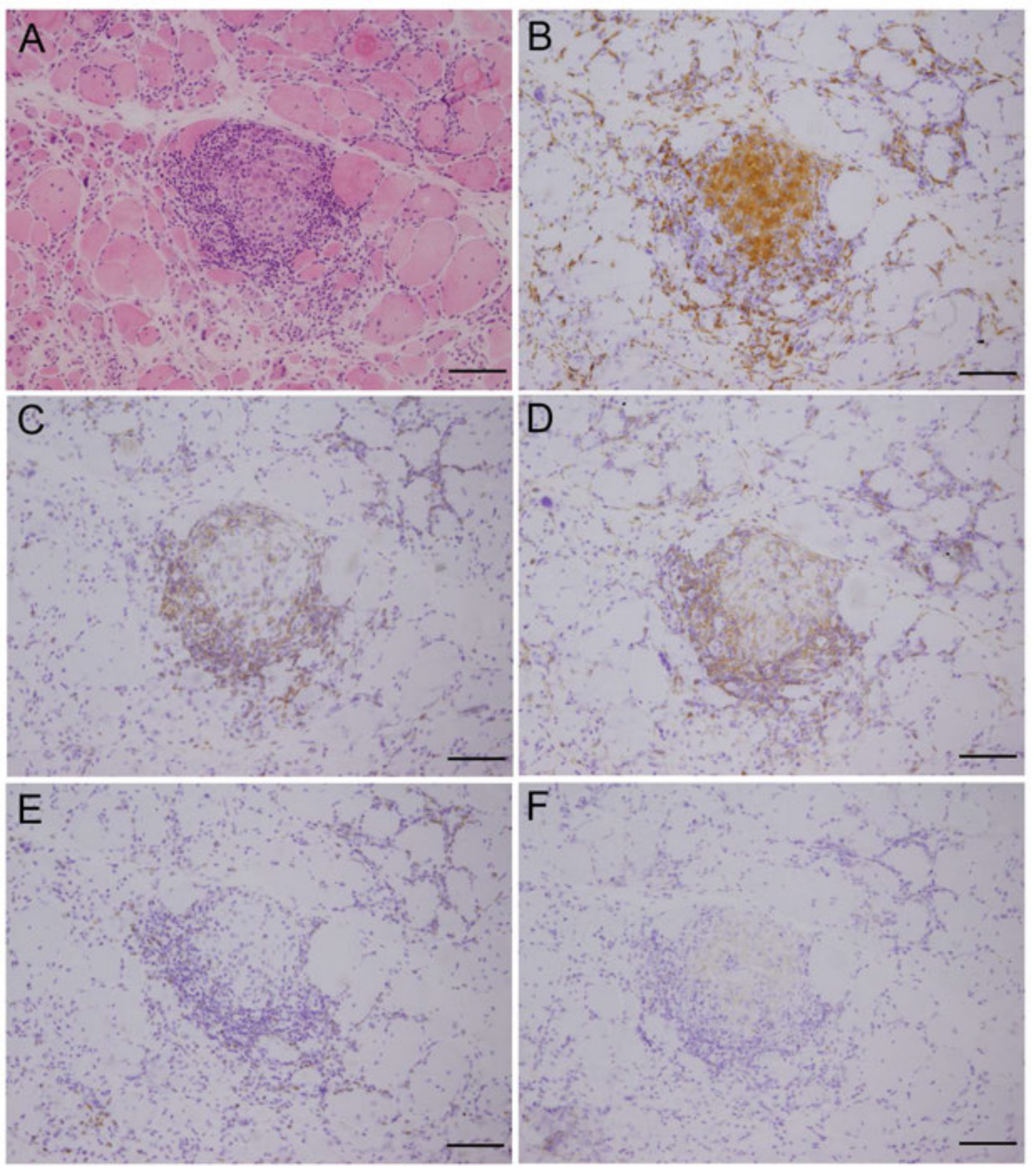
A
B
C
D
E
F