I-131 uptake in a thymic cyst

メタデータ	言語: English 出版者: 公開日: 2017-10-05 キーワード (Ja): キーワード (En): 作成者: Kayano, Daiki, Michigishi, Takatoshi, Ichiyanagi, Kenji, Inaki, Anri, Kinuya, Seigo メールアドレス: 所属:
URL	http://hdl.handle.net/2297/24295

I-131 Uptake in Thymic Cyst

Daiki Kayano, M.D., Ph.D.
Takatoshi Michigishi, M.D., Ph.D.
Kenji Ichiyanagi, M.D., Ph.D.
Anri Inaki, M.D.
Seigo Kinuya, M.D., Ph.D.

Daiki Kayano, Anri Inaki, Seigo Kinuya: Department of Nuclear Medicine, Kanazawa University Hospital, Kanazawa, Ishikawa, Japan
Takatoshi Michigishi: Department of Internal Medicine, Nanto Central Hospital, Nanto, Toyama, Japan
Kenji Ichiyanagi: Department of Nuclear Medicine, Takaoka City Hospital, Takaoka, Toyama, Japan

Reprint: Daiki Kayano, Department of Nuclear Medicine, Kanazawa University Hospital, 13-1 Takara-machi, Kanazawa, Ishikawa, 920-8641, Japan

Abbreviated title: I-131 Uptake in Thymic Cyst

Corresponding auther: Daiki Kayano, Department of Nuclear Medicine, Kanazawa University Hospital, 13-1 Takara-machi, Kanazawa, Ishikawa, 920-8641, Japan
telephone number: 81-76-265-2333
facsimile number: 81-76-234-4257
e-mail: kayano@nmd.m.kanazawa-u.ac.jp

Abstract:
A 61-year old woman after total thyroidectomy for papillary thyroid cancer underwent I-131 therapy. Focal uptake was seen in the chest on whole body imaging. SPECT/CT delineated I-131 accumulation in an iso-dense mediastinal lesion which was histologically diagnosed as thymic cyst. I-131 uptake in thymic cyst has never been reported and should be included in the gamut of false positive entities of I-131 scintigraphy.
Key Words: I-131, thymic cyst, thyroid cancer

REFERENCES:

1. Csaba G, Kiss J, Nagy SU. Comparative studies on the 125 I uptake of the thyroid and thymus. Experientia. 1973;29:357-8.

2. Jackson GL, Graham WP, 3rd, Flickinger FW, et al. Thymus accumulation of radioactive iodine. Pa Med. 1979;82:37-8.

3. Michigishi T, Mizukami Y, Shuke N, et al. Visualization of the thymus with therapeutic doses of radioiodine in patients with thyroid cancer. Eur J Nucl Med. 1993;20:75-9.

4. Muratet JP, Giraud P. Thymus accumulation of I-131 after therapeutic dose for thyroid carcinoma. Clin Nucl Med. 1996;21:736-7.

5. Vermiglio F, Baudin E, Travagli JP, et al. Iodine concentration by the thymus in thyroid carcinoma. J Nucl Med. 1996;37:1830-1.

6. Salvatori M, Saletnich I, Rufini V, et al. Unusual false-positive radioiodine whole-body scans in patients with differentiated thyroid carcinoma. Clin Nucl Med. 1997;22:380-4.

7. Agriantonis DJ, Hall L, Wilson MA. Pitfalls of I-131 whole body scan interpretation: bronchogenic cyst and mucinous cystadenoma. Clin Nucl Med. 2008;33:325-7.

8. Francese C, Schlumberger M, Travagli JP, et al. Iodine 131 uptake in a pleuropericardial cyst: case report of a false-positive radioiodine total body scan result in a patient with a thyroid cancer. Eur J Nucl Med. 1991;18:779-80.

Legend:

A 61-year old woman who had undergone total thyroidectomy for papillary thyroid cancer received I-131 therapy under the withdrawal of thyroxine replacement. Thyroglobulin was negative with negative thyroglobulin antibody on the day of I-131 administration. On anterior whole body image obtained on the third day after ingestion of 100mCi I-131, two intense foci in the neck (closed arrows) and focal uptake in the chest (open arrow) are seen (A). The former is likely to demonstrate thyroglossal duct and thyroid remnant. SPECT/CT reveals that the latter is corresponding to an iso-dense mediastinal lesion which is surgically resected later (B: CT, C: SPECT, D: SPECT/CT, open arrows). Pathological examinations show thymic cortex

sparsely existed in the wall of cystic component, resulting in the diagnosis of thymic cyst (E). The lesion contains neither thyroid tissues nor metastatic foci of thyroid cancer. Considering that rat thymus glands accumulate I-131[1,2], thymic cortex in the cyst wall is speculated to have accumulated I-131 in this particular case.

I-131 scintigraphy is a useful method in the detection of thyroid remnants and metastatic lesions for patients with papillary and follicular thyroid cancer who have undergone total thyroidectomy. However, false positive I-131 accumulations are often seen in cases of body secretions, pathologic exudates, inflammations and nonthyroidal neoplasms. Thymic cyst as well as thymic hyperplasia[3-6], bronchogenic cyst[7] and pleuropericardial cyst[8] can cause false positive imaging of mediastinal I-131 uptake. It is necessary to recognize various types of false positive I-131 uptakes in order to prevent unnecessary therapy.

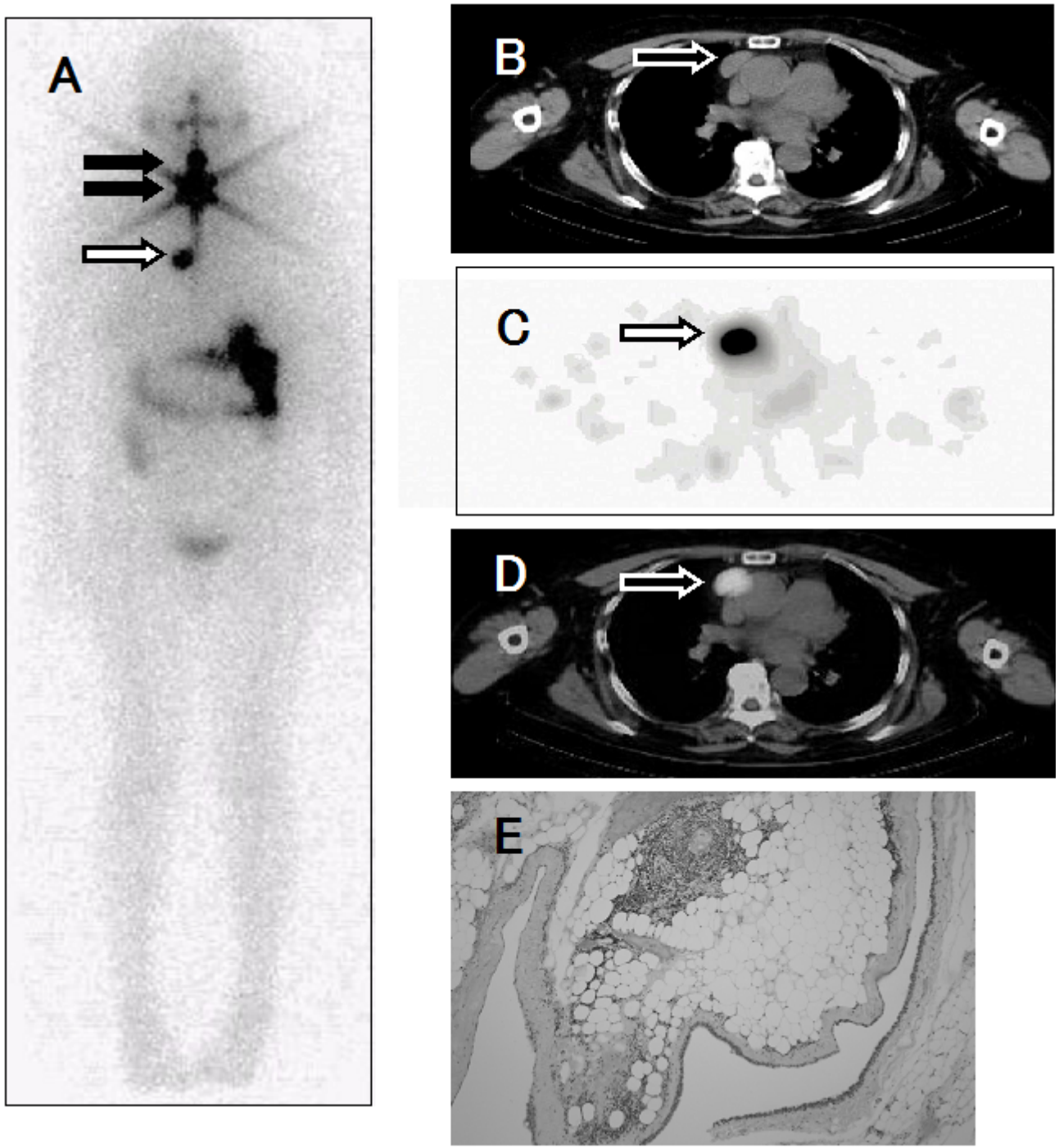
A
B
C
D
E