

# Intracranial extension of meibomian gland carcinoma with pagetoid changes

メタデータ	言語: eng 出版者: 公開日: 2017-10-05 キーワード (Ja): キーワード (En): 作成者: メールアドレス: 所属:
URL	<a href="http://hdl.handle.net/2297/17156">http://hdl.handle.net/2297/17156</a>

## **Case Report; Journal of Clinical Neuroscience**

### **Intracranial extension of meibomian gland carcinoma with pagetoid changes**

Yasuhiko Hayashi, Hiroshi Shima, Daisuke Kita, Masashi Kinoshita, Yuya

Yoshida, Mitsuhiro Hasegawa, Jun-ichiro Hamada

Department of Neurosurgery, Graduate School of Medical Science

Kanazawa University, Japan

**A running title: Intracranial extension of meibomian gland carcinoma**

KEY WORDS; meibomian gland carcinoma, skull destruction,  
intracranial extension, metastasis

Corresponding author: Yasuhiko Hayashi, M.D.

Department of Neurosurgery, Graduate School of Medical Science

Kanazawa University

13-1, Takara-machi, Kanazawa, 920-8641, Japan

Telephone: +81-76-265-2384, Fax: +81-76-234-4262

e-mail: [yahayashi@ns.m.kanazawa-u.ac.jp](mailto:yahayashi@ns.m.kanazawa-u.ac.jp)

## **Abstract**

This 41-year-old man presented with exophthalmos and loss in visual acuity. Neuroradiological study showed a large mass from the intraorbital region to the frontal lobe; it also involved the middle cranial- and infratemporal fossa, and was accompanied by skull destruction. The tumor was almost totally removed. The histological diagnosis was sebaceous carcinoma with pagetoid changes. Despite surgery and local irradiation, intracranial metastases were recognized one year later and he underwent total removal and whole-brain irradiation. Although multiple lung metastases were detected one year after the 2<sup>nd</sup> operation, 3 years after the surgery, he is free of intracranial recurrence. Sebaceous carcinomas of meibomian gland origin with pagetoid changes are a distinct, highly aggressive clinical entity. Early diagnosis and appropriate treatment are essential to improve the prognosis of patients with meibomian gland carcinoma with intracranial extension.

## 1. Introduction

Meibomian gland carcinomas of the eyelid are rare adnexal epithelial tumors and although local recurrence and lymph node metastasis are common, metastasis from skin tumors is not.<sup>1-3</sup> Among meibomian gland carcinomas, 32% recurred and 6% extended orbitally.<sup>4</sup> To date, only 2 patients with intracranial progression have been reported. We encountered a patient with highly aggressive meibomian gland carcinoma from the eyelid with intracranial and intraorbital progression.

Among the morphological features of sebaceous carcinomas of the meibomian gland, pagetoid involvement is important.<sup>3,4</sup> We posit that in our patient extensive pagetoid spread in the epithelium was a major contributor to its aggressive behavior.

## **2. Case Report**

This 41-year-old man presented with exophthalmos, visual acuity loss and restricted left-eye movement. He also manifested painless swelling of the left frontal region and the left upper eyelid was reddish. No lesions were found in the skin or conjunctiva. A computed tomography (CT) scan revealed an iso-dense mass extending from the orbital roof to the frontal convexity (Fig.1A,B). On gadolinium-enhanced T1- and T2-weighted magnetic resonance imaging (MRI), the signal from the mass was iso-intense (Fig. 1C-E).

At surgical exploration, the frontal and temporal bone around the area of skull destruction was drilled out to the base of the middle cranial fossa to expose the intact dura mater. The exposed firm tumor was located in the extradural space and involved peripheral tissue. Internal decompression of the tumor revealed an embedded fibrous round core seen as an iso-intense mass on T1- and T2-weighted images. The tumor broke through the periorbita and invaded the intraconus space from the lateral side of the superior rectal muscle without involvement of extraocular muscles. It extended from the parasellar region to

the temporal base and infratemporal fossa, and was excised with a high-output cavitation ultrasonic surgical aspirator. Because there was strong tumor attachment to the upper eyelid, it was thought to be the primary site. We considered gross total resection with microsurgical procedures to have been successful.

Microscopic examination showed that many of the tumor cells were undifferentiated, invasive and mitotic. We noted irregular lobular formations with fibrous septa and extensive pagetoid involvement of the epithelium (Fig. 2). The presence of vacuolated cytoplasm suggested sebaceous differentiation.

Postoperatively, his exophthalmos and eyeball movement were improved. We delivered 60-Gy local irradiation. One year later we detected local recurrence and metastasis at the dura of the left frontal parasagittal region (Fig.3A,B). He refused orbital exenteration. We removed both tumors as a palliative procedure and delivered 40-Gy whole-brain irradiation. One year after the 2<sup>nd</sup> operation, multiple lung metastases were found (Fig.3C). Histological study of needle biopsy specimens returned results identical to those

of the previously obtained surgical specimens and he received chemotherapy.

There has been no intracranial recurrence in the course of 3 years after his 2<sup>nd</sup> operation.

### 3. Discussion

The intracranial extension of meibomian gland carcinoma is extremely rare and only 2 cases have been reported to-date.<sup>4</sup> One was an autopsy case with tumor extension to the trigeminal ganglia and metastasis to the cerebellum.<sup>5</sup> In the other case, the tumor invaded the frontal bone and adjacent dura.<sup>2</sup>

In the course of malignant changes of the sebaceous gland, normal cell maturation is replaced by undifferentiated cells. The tumor cells are pleomorphic with round or polyhedral nuclei, prominent nucleoli, and vacuolated cytoplasm. Sebaceous carcinoma with pagetoid involvement is associated with a higher mortality rate,<sup>3</sup> among patients with- and without pagetoid involvement it was approximately 50% and 10%, respectively.<sup>1</sup>

Pagetoid spread is of diagnostic and prognostic significance, rendering this tumor a distinct and highly aggressive clinical entity.<sup>6</sup> Although our patient did not manifest pagetoid spread to the skin or conjunctiva, it is commonly seen in sebaceous carcinoma and is usually found in the conjunctiva. Among 3 patients with sebaceous carcinomas with intracranial extension, including ours, 2



manifested pagetoid changes. We posit that this change is reflective of the aggressive behavior, intracranial extension with skull destruction, recurrence and distal metastasis from these tumors.

Among malignant eyelid tumors reported in Western countries, sebaceous cell carcinoma is rare. On the other hand, it is one of the most common malignant eyelid tumors among Asian populations where it is almost as common as basal cell carcinoma.<sup>7-9</sup> Jahaqirdar et al.<sup>2</sup> reported that 80-90% of eyelid malignancies in Caucasians were basal cell carcinoma and patients with basal cell carcinoma had a better prognosis. Because the mortality rate among patients with sebaceous cell carcinoma is high, these cancers should be treated aggressively.<sup>10</sup> There is also an association of sebaceous cell carcinoma with the inherited (autosomal dominant) Muir-Torre syndrome, where multiple visceral tumors, mainly colon cancer, may arise.<sup>11</sup> Wang et al.<sup>12</sup> suggested that inactivation of the fragile histidine triad tumor suppressor gene or inactivation of the mismatch-repair system resulting in microsatellite instability may contribute to the development of Muir-Torre syndrome.<sup>12</sup>

Currently, the only effective therapy for sebaceous carcinoma of meibomian gland origin is radical surgery.<sup>2,3,13</sup> Orbital exenteration has been recommended if there is clinical and neuroradiological evidence of intraorbital extension.<sup>1,3,5</sup> Because our patient rejected this course we delivered, additional irradiation although there is no consensus regarding this treatment modality as adjuvant therapy. In some cases, irradiation was thought to be effective although pathologic studies disclosed extensive irradiation-induced degenerative changes.<sup>3,4,14</sup> While the effective treatment of patients with intracranial extension from meibomian gland carcinoma remains difficult and their prognosis poor, a reduction in the tumor mortality rate requires early recognition and appropriate aggressive treatment.<sup>2,3</sup>

## References

1. Rao NA, Hidayat AA, McLean IW et al., Sebaceous carcinomas of the ocular adnexa: A clinicopathologic study of 104 cases, with five years follow-up data. Hum Pathol 13(1982), pp.113-122.
2. Colak A, Akkurt C, Ozcan OE et al., Intracranial extension of meibomian gland carcinoma. J Clin Neuroophthalmol 11(1991), pp.39-42.
3. Doxanes TM and Green RW, Sebaceous gland carcinoma. Review of 40 cases. Arch Ophthalmol 102(1984), pp.245-249.
4. Ginsburg J, Present status of meibomian gland carcinoma. Arch Ophthalmol 73(1965)73, pp.271-277.
5. Bryant J, Meibomian gland carcinoma seeding intracranial soft tissues. Hum Pathol 8(1977), pp.455-457.
6. Russell WG, Page DL, Hough JA et al., Sebaceous carcinoma of meibomian gland origin. The diagnostic importance of pagetoid spread of neoplastic cells. Am J Clin Pathol 73(1980), pp.504-511.
7. Demirci H, Nelson CC, Shields CL et al., Eyelid sebaceous carcinoma

associated with Muir-Torre syndrome in two cases. *Ophthal Plast Reconstr Surg*

23(2007), pp.77-79

8. Holbach LM, von Moller A, Decker C et al., Loss of fragile histidine triad (FHIT)

expression and microsatellite instability in periocular sebaceous carcinoma in

patients with Muir-Torre syndrome. *Am J Ophthalmol* 134(2002), pp.147-148

9. Jahaqirdar SS, Thakre TP, Kale SM et al. A clinicopathological study of eyelid

malignancies from central India. *Indian J Ophthalmol* 55(2007), pp109-112

10. Pornpanich K, Chindasub P. Eyelid tumors in Siriraj Hospital from 2000-2004.

*J Med Assoc Thai* 88(2005), ppS11-14

11. Takamura H, Yamashita H. Clinicopathological analysis of malignant tumor

cases at Yamagata University Hospital: Statistical comparison of tumor

incidence in Japan and in other countries. *Jpn J Ophthalmol* 49(2005),

pp349-354

12. Wang JK, Liao SL, Jou JR et al., Malignant eyelid tumours in Taiwan. *Eye*

17(2003), pp216-220

13. Khalil MK and Lorenzetti HD, Sebaceous gland carcinoma of the lid. *Can J*

Ophthalmol 15(1990), pp.117-121.

14. Ide CH, Ridings GR, Yamashita T et al., Radiotherapy of a recurrent adenocarcinoma of the meibomian gland. Arch Ophthalmol 79(1968), pp.540-544.

## Figure Legends

### Figure 1

Preoperative plain- **(A)** and bone-window CT **(B)** scan showing an isodense mass with extension into the intraorbital and intracranial space (arrow). **C.** Preoperative T1-weighted MRI without contrast enhancement showed an isointense mass invading the intraorbital and intracranial space and skull destruction. **D.** T2-weighted MRI showing an isointense mass that included a small round isointense mass with a hypointense rim. **E.** Contrast-enhanced T1-weighted MRI showing enhancement of the tumor. During surgery we found that the unenhanced, round, iso-intense area was a fibrous mass embedded in the tumor.

### Figure 2

Photomicrographs of the surgical specimen. **A.** The diagnosis of sebaceous carcinoma of the meibomian gland was confirmed histologically. Many tumor cells were undifferentiated, invasive and mitotic. Note the irregular lobular formations with fibrous septa (H&E, original magnification x100). **B.** The tumor

cells showed typical pagetoid involvement in the epithelium with vacuolated cytoplasm, suggestive of sebaceous differentiation (H&E, original magnification x 400).

### **Figure 3**

**A.** Contrast-enhanced, fat-suppressed MRI obtained one year after the 1<sup>st</sup> operation. There is local tumor recurrence in the left frontal region (arrow). **B.** Contrast-enhanced T1-weighted MRI revealed remote intracranial tumor recurrence in the dura of the left frontal parasagittal region. **C.** Chest X-ray performed one year after the 2<sup>nd</sup> operation disclosed bilateral multiple lung metastases.

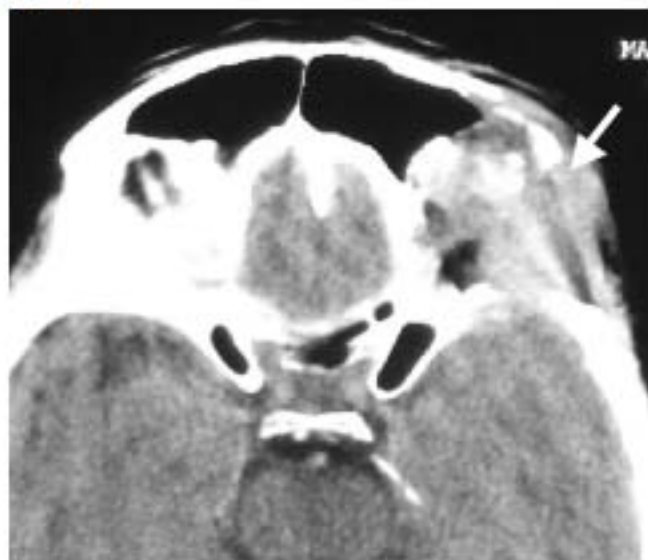
### **Abbreviations:**

CT: computed tomography, MRI: magnetic resonance imaging

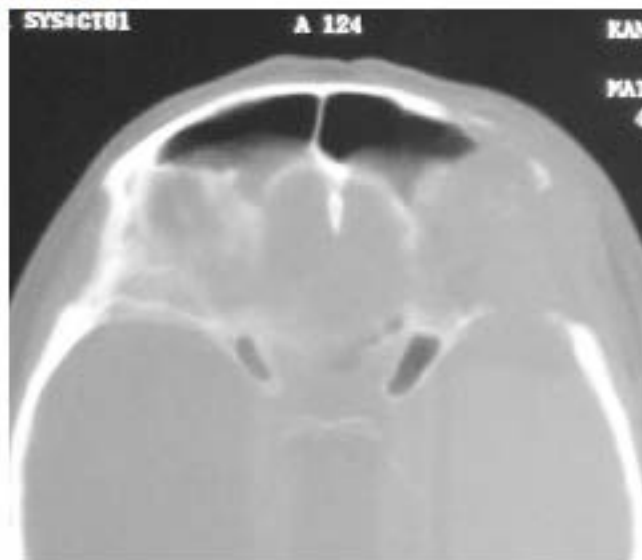
Figure 1

Yasuhiko Hayashi ↑

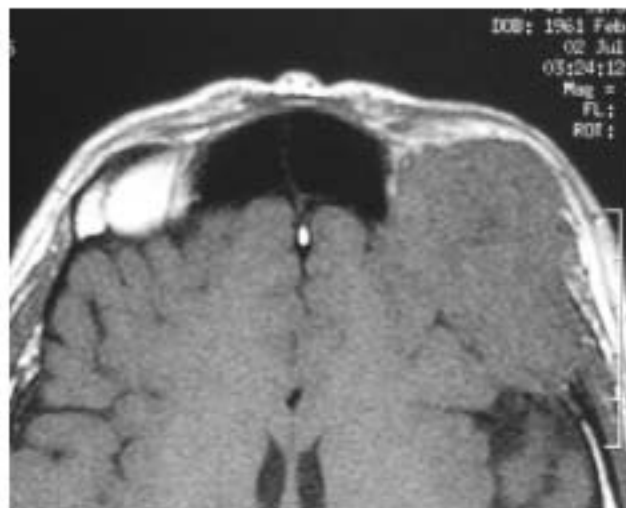
(A)



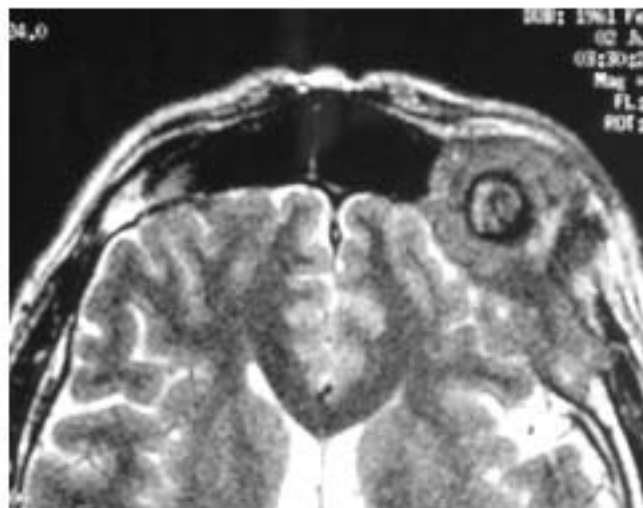
(B)



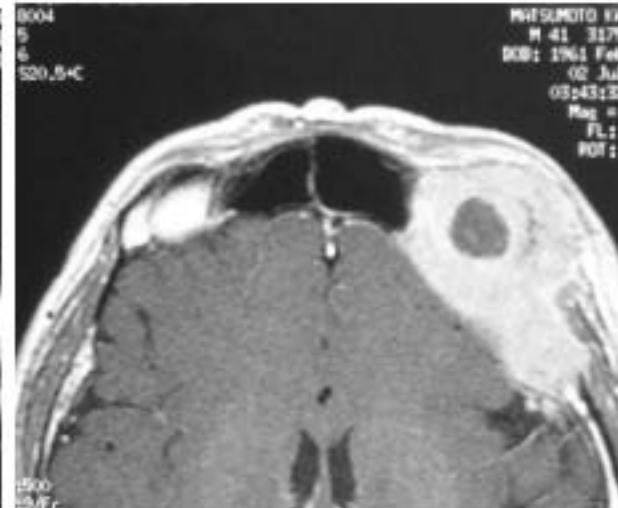(C)



(D)



(E)

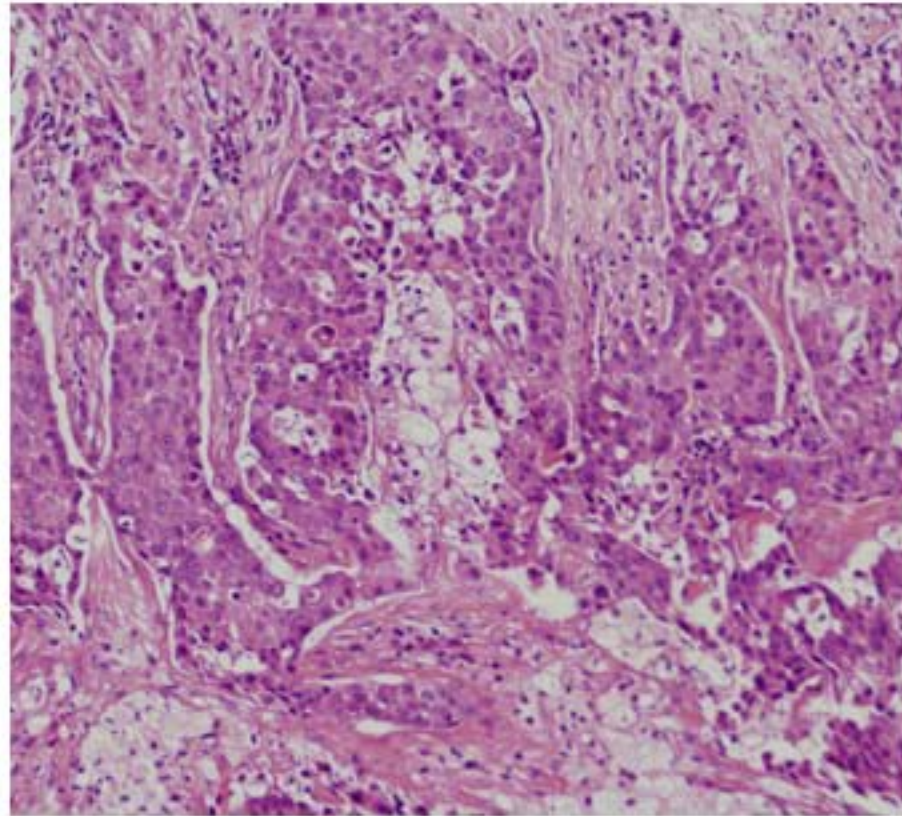




# Figure 2

Yasuhiko Hayashi ↑

**(A)**



**(B)**

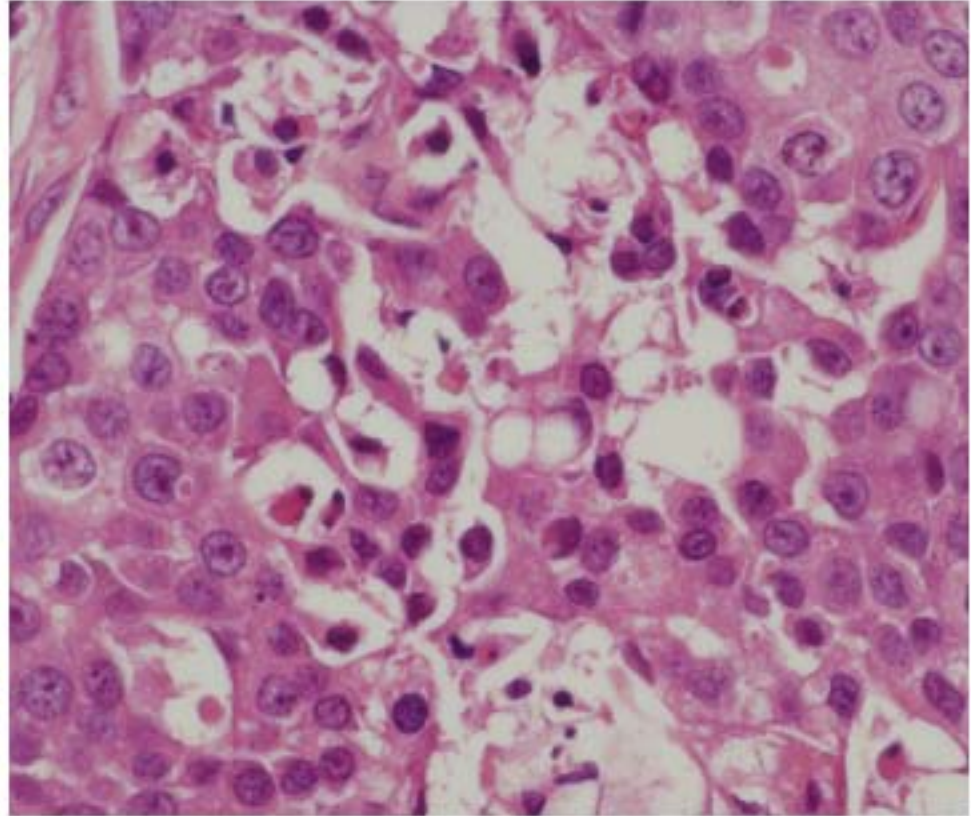
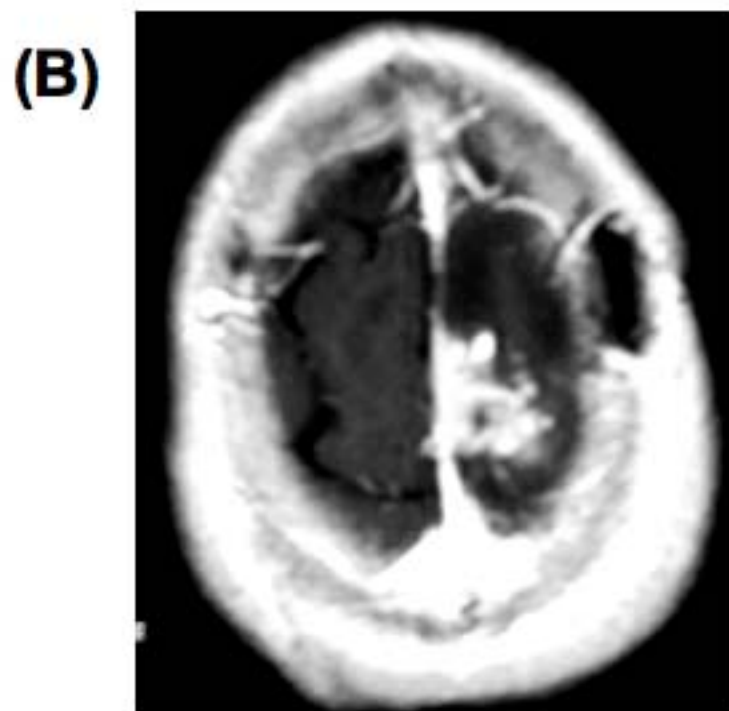
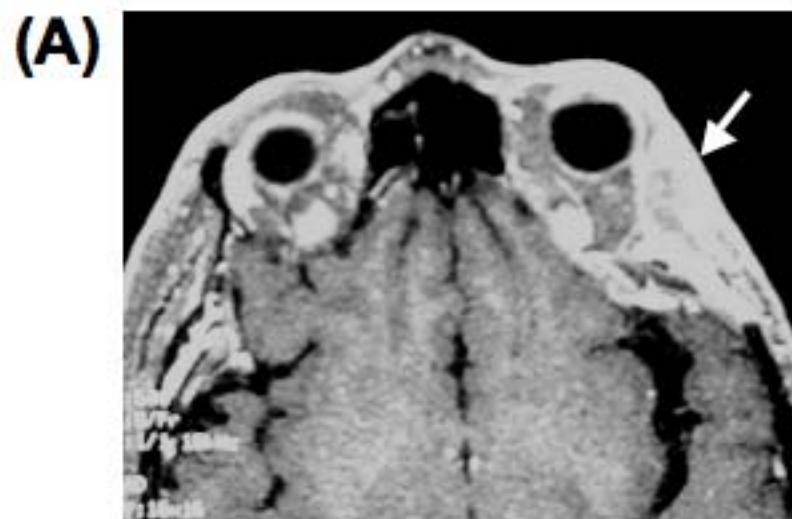


Figure 3



(C)

