



Thyroidectomy Using Pure Natural Orifice Transluminal Endoscopic Surgery in a Porcine Model

*Kanae Nitta, *Norihiko Ishikawa, *Masahiko Kawaguchi, †Akishi Ooi,
and *Go Watanabe

**Department of General and Cardiothoracic Surgery, Kanazawa University; and †Department of Cellular Transplantation Biology, Kanazawa University, Kanazawa, Japan*

Abstract: Surgical procedures for thyroid disease that provide cosmetically acceptable results are in demand. Natural orifice transluminal endoscopic surgery (NOTES) is performed through natural orifices and thus avoids incision of the body wall. This study aimed to develop an incision-free surgical procedure for thyroid lobectomy using pure NOTES with an oral approach. In six pig carcasses, an incision was made between the mandible and subcutaneous tissue under direct vision. After subcutaneous dissection and identification of the hyoid bone, the operative field was developed under endoscopic view. After the thyrohyoid membrane was identified, dissection was continued along the thyroid cartilage until the cricoid

cartilage was identified and the thyroid isthmus was reached. An original retractor was inserted between dissected tissues to lift and fix the carcass. The thyroid gland was successfully removed through the incision. Similar macroscopic and histological findings were observed on the normal and treated sides, with no damage to the recurrent laryngeal nerves. The times required for securing the operative field and thyroidectomy improved with each operation. This study suggests the feasibility and safety of using pure NOTES for thyroidectomy through a subcutaneous route with an original retractor. **Key Words:** Natural orifice transluminal endoscopic surgery—Thyroidectomy—Endoscopic surgery—Oral approach.

The option of using natural orifice transluminal endoscopic surgery (NOTES) as a minimally invasive surgical technique emerged after the study by Kalloo et al. reporting transgastric intraperitoneal observations in a porcine model in 2004 (1). The feasibility of NOTES has since been investigated in various animal studies. At an academic conference in 2005, Reddy and colleagues reported the clinical application of NOTES in transgastric appendectomy. The same year, the American Society of Gastrointestinal Endoscopy and the Society of American Gastrointestinal and Endoscopic Surgeons jointly established the Natural Orifice Surgery Consortium for Assessment and Research as an organization committed to

promoting research activities on NOTES (2,3). This procedure is performed through natural orifices, such as the mouth, vagina, and anus, and does not require incision of the body wall. This method thus offers multiple advantages, including cosmetic benefits, reduced postoperative pain, prevention of wound-related complications such as infection and incisional hernia, and reduced surgical stress.

Among patients with thyroid diseases, surgical procedures that provide cosmetically acceptable results are in demand, as the skin incision performed in thyroid surgery leaves a scar in the neck area. Since endoscopic thyroidectomy was first described by Hüscher et al. in 1997 (4), various endoscopic thyroidectomy procedures have been reported (5–8). However, a small incision is still required in endoscopic surgery to allow for retrieval of resected specimens. The objective of this study was to develop an incision-free surgical procedure for thyroid lobectomy through an oral approach using pure NOTES.

doi:10.1111/aor.12398

Received April 2014; revised July 2014.

Address correspondence and reprint requests to Dr. Kanae Nitta, Department of General and Cardiothoracic Surgery, Kanazawa University, 13-1 Takaramachi, Kanazawa, Ishikawa 920-8641, Japan. E-mail: attin7nitta@gmail.com

MATERIALS AND METHODS

In a preliminary study to explore an oral approach to the thyroid gland, an access route from the sublingual cavity was considered (Fig. 1A). A pig was placed in the supine position, its tongue was lifted, and an incision was made in the tongue base under direct vision, followed by dissection of the genioglossus muscle. The initial plan was to continue dissection until the hyoid bone was reached and then advance the endoscope along the thyrohyoid membrane to reach the thyroid gland; however, this approach proved to be impossible due to the lack of landmarks in the oral cavity and difficulty maintaining the proper orientation. Even though carbon dioxide gas was used to secure a sufficient working space, the attempt still failed.

In our main study (Fig. 1B), six pig carcasses were used. Each pig was fixed in the supine position with the mouth kept open. A direct-view endoscope (0° , 12-mm-diameter optical view tube; A4884A, Olympus, Tokyo, Japan) was used. For tissue dissection and thyroidectomy, regular endoscopic forceps (Maryland dissecting forceps, 5 mm; Endo Clinch II, Olympus) and an ultrasonic coagulating and cutting device (SonoSurg, Olympus) were used. To access the thyroid gland from the oral cavity, an incision was made between the mandible and subcutaneous tissue

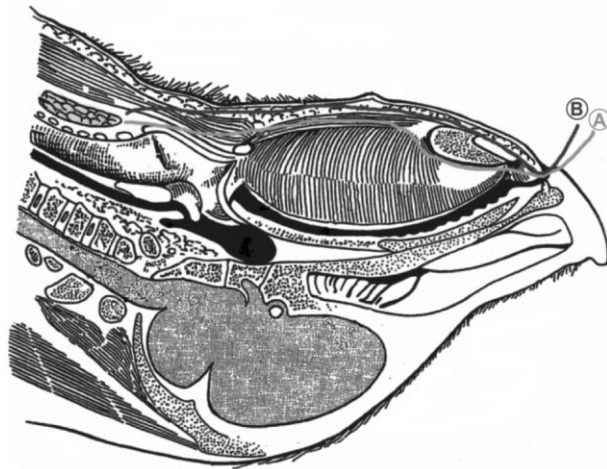


FIG. 1. (A) In the preliminary study, the tongue was lifted and an incision made in the tongue base under direct vision, followed by dissection of the genioglossus muscle until the hyoid bone was reached. Dissection was continued along the thyrohyoid membrane until the thyroid gland was reached. (B) In the main study, an incision was made between the mandible and subcutaneous tissue under direct vision. After subcutaneous dissection and identification of the hyoid bone, the operative field was developed under endoscopic vision. After identification of the thyrohyoid membrane, dissection was continued along the thyroid cartilage until the cricoid cartilage was identified and the thyroid isthmus was reached.

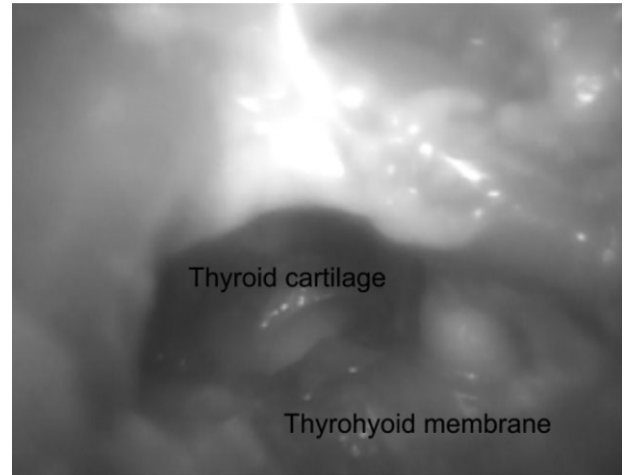


FIG. 2. After identification of the hyoid bone, the thyrohyoid membrane was opened to expose the thyroid cartilage.

under direct vision. After subcutaneous dissection and identification of the hyoid bone, the operative field was developed under endoscopic view. After the thyrohyoid membrane was identified, dissection was continued along the thyroid cartilage until the cricoid cartilage was identified (Fig. 2) and the thyroid isthmus reached (Fig. 3). A lifting method using an original retractor was used to secure sufficient working space. A dedicated retractor was inserted between the dissected tissues to lift and fix the carcass (Fig. 4). The times required for securing the operative field, thyroidectomy, wound closure, and the complete operation were recorded. Wound closure was performed under direct vision using an absorbable suture (3-0 Vicryl; Johnson & Johnson, New Brunswick, NJ, USA). As part of a

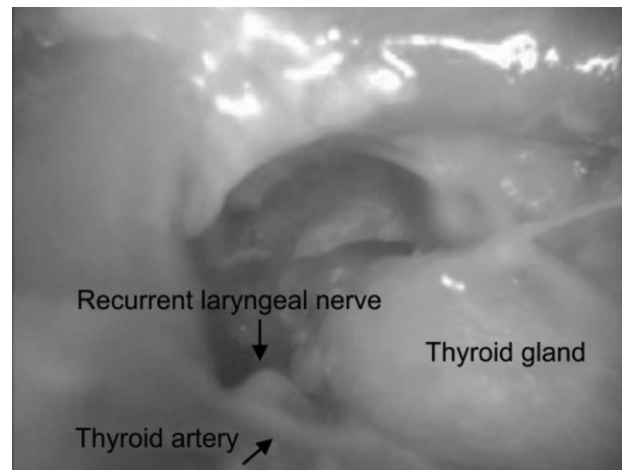


FIG. 3. Dissection was continued along the thyroid cartilage until the thyroid isthmus was reached.

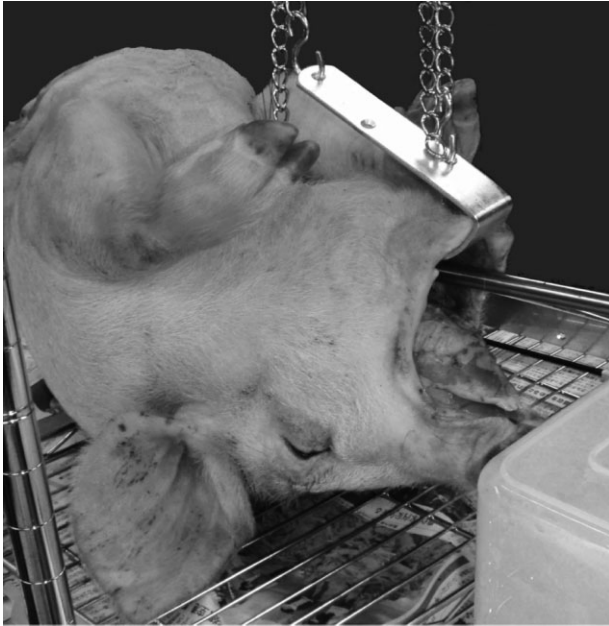

FIG. 4. A lifting method using an original retractor. A retractor designed for pigs with staggered holes was connected to chains with S-shape hooks and was lifted at two points, thus stabilizing the retractor.

safety assessment, the presence or absence of any intraoperative complications or damage to organs or the recurrent laryngeal nerve was checked after the operation by cutting and opening the neck skin and excising the recurrent laryngeal nerves on both sides for pathological examination.

RESULTS

The times required for securing the operative field, thyroidectomy, wound closure, and the complete operation are summarized in Table 1. The mean times required for securing the operative field, thyroidectomy, and wound closure were 52.7 (range 46–55), 26.3 (range 23–36), and 4 (range 3–5) min, respectively; the average operation time was 83 (range 74–101) min. The times required for securing the operative field and thyroidectomy decreased slightly as the number of surgeries increased. In the fourth surgery, the distance between the mouth and thyroid gland was longer than that in the other pigs, requiring more time to secure the operative field. In addition, increased difficulty in developing the operative field increased the time required for the thyroidectomy. With respect to the time required for wound closure, no significant difference was found between the surgeries due to the relatively consistent size of incisions made in this procedure.

The thyroid gland was successfully removed through an incision made between the mandible and

subcutaneous tissue, into which the retractor was inserted. The incision made in the oral cavity could be easily closed under direct vision. No damage to blood vessels or surrounding organs was detected during postoperative examination performed by cutting and opening the neck skin. Recurrent laryngeal nerves from both sides were collected from pigs in which the thyroid lobectomy was completed using NOTES and subjected to pathological examination. Similar macroscopic and histological findings were observed on the normal and treated sides, with no surgery-induced damage observed in the recurrent laryngeal nerves.

DISCUSSION

Using pig carcasses, the present study demonstrated that a sufficient working space was easily secured using an approach through an incision made between the mandible and subcutaneous tissue and by lifting the carcass with an original retractor. No damage to the surrounding organs or the recurrent laryngeal nerve, which are known complications of thyroid surgery, was identified, suggesting the safety and feasibility of this procedure for thyroidectomy using oral NOTES.

The technical key points of NOTES include access to the target organ, closure of the access route wound, and infection control. The first clinical application of transvaginal cholecystectomy was reported by Marescaux et al. from France in 2007 as an approach to the appendix and gallbladder in the abdominal cavity (9). This procedure was performed via hybrid NOTES with the aid of a single 2 mm trocar. The first clinical application of transgastric intraperitoneal observation was reported by Hazey et al. in 2008 (10). These authors developed a new NOTES procedure in which subcutaneous dissection is made and the target organ approached from the oral cavity instead of the transluminal approach used in the conventional procedure.

TABLE 1. Times required for securing the operative field, thyroidectomy, wound closure, and the complete operation

Case	Securing operative field (min)	Thyroidectomy (min)	Wound closure (min)	Total operation time (min)
1	55	26	5	86
2	52	23	5	80
3	46	24	4	74
4	62	36	3	101
5	51	25	3	79
6	50	24	4	78
Mean	52.7	26.3	4.0	83.0

Our preliminary experiments demonstrated that the oral approach from the sublingual cavity was not feasible. Attempting a sublingual approach, we made an incision in the sublingual cavity and dissected the surrounding tissue toward the thyroid gland. However, the presence of the thick genioglossus and the lack of landmarks in the oral cavity made it difficult to maintain anatomical orientation. The mouth of a pig is elongated and thus could not be fully opened; the dentition also limited the development of the operative field and the handling of instruments. The sublingual approach is also associated with an increased risk of damage to the sublingual gland, submandibular gland, and sublingual artery/vein located deep in the genioglossus muscle.

The subcutaneous approach to thyroid surgery is associated with a lower risk of damaging vital organs and provides safe access to the thyroid gland. However, because the surgical field is developed along the skin and muscles in this procedure, identifying an ideal point of insertion of the endoscope into the muscle layer proved difficult. The endoscope was inserted into the muscle layer from a site beyond the mandible in order to identify the hyoid bone from the midline of the digastric muscle. After the thyroid cartilage was identified along the thyrohyoid membrane, dissection continued until the thyroid isthmus was reached. The thyroid artery/vein and recurrent laryngeal nerve were not always identifiable at this point. After the thyroid isthmus was identified, careful dissection along the sides of the thyroid gland enabled the thyroid artery to be identified on the medial side of the thyroid gland and the inferior thyroid artery and recurrent laryngeal nerve on the lateral side.

In the preliminary experiment, we were unable to secure a sufficient working space using insufflation. After the hyoid bone was identified, the operative field was secured using an endoscope. However, the presence of hard, dense subcutaneous tissue prevented the insertion of a port to a sufficient depth. Insufflation with carbon dioxide gas was also attempted, but we could not achieve sufficient insufflation pressure due to leakage of gas at the port insertion site, and a sufficient working space could not be secured. As an alternative to insufflation, a method using a lifting device has been reported for securing a working space in endoscopic surgery and robotic surgery (11). The disadvantages associated with insufflation with carbon dioxide gas include subcutaneous emphysema, difficulty maintaining tightness at the port insertion site, and risk of other complications such as hypercapnia, respiratory acidosis, and air embolism (12). In contrast, the lifting

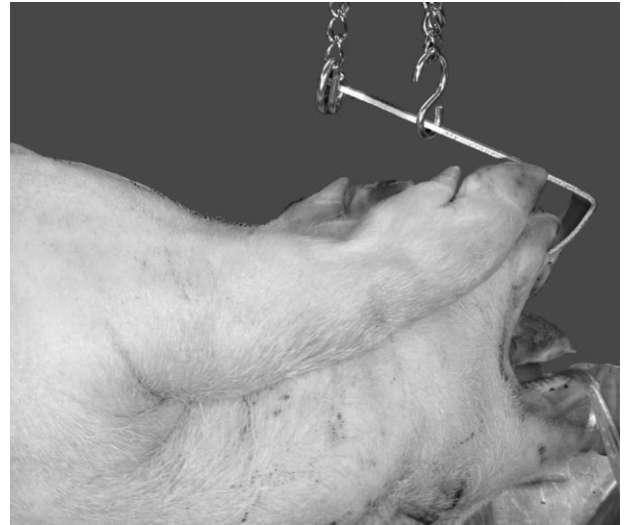


FIG. 5. When a sufficient operative field could not be obtained even with the original long retractor, a silk suture was placed through the skin on the ventral aspect to lift the skin so that a deep operative field could be secured.

method using a retractor provides a sufficient working space for thyroidectomy, making it possible to secure an optimal operative field by repositioning the retractor, even in a deep field. Since the distance between the lower jaw skin and the thyroid gland in a pig can be as long as 25–30-cm, in some pigs, the thyroid gland could not be reached by repositioning a retractor alone. In such cases, a working space was secured by placing a silk suture through the skin to lift it, following the video-assisted neck surgery method described by Shimizu et al. (13); the thyroidectomy could then be successfully completed (Fig. 5).

In NOTES, a flexible endoscope is inserted through a natural orifice and advanced into the body cavity through an incision made on the lumen wall. In the preliminary experiment, it was difficult to maintain the direction of the advancing camera with a flexible endoscope. We therefore decided to use a rigid endoscope in the present procedure. However, a flexible endoscope may be more useful than a rigid one in dissecting the lateral side of the thyroid gland and identifying the recurrent laryngeal nerve.

NOTES can also facilitate the closure of an organ incision made to approach a target abdominal organ. An incision made during transvaginal procedures can be closed under direct vision using gynecological surgical techniques. Various procedures have been reported for closing an incision made during transgastric NOTES. Bergstrom et al. used a suturing device that uses suture thread with a T-bar for closure of a perforated duodenal ulcer, hemostasis of a bleeding gastric ulcer, and repair of an anastomotic

leak at the site of gastrojejunostomy (14). The bracebar, developed by Olympus for endoscopic suturing, has been tested in esophageal anastomosis (15). In an oral approach, as performed in the present experiment, wound closure can be achieved by manual direct suturing under direct vision, and wound infection can be managed easily.

Several issues remain to be addressed before pure NOTES can be applied to thyroid surgery in a clinical setting. One of these issues involves the anatomical differences between humans and pigs. The shorter distance between the mandible and thyroid gland and softer subcutaneous tissue in humans makes it easier to secure a working space with a muscle retractor and allows for better handling of instruments. This approach in human subjects allows for surgical intervention without having to disturb the intubation tube. However, as the neck will have to be bent backward, it might be difficult to perform this procedure in patients with a history of cervical spondylosis. Pathological examination revealed no damage to the recurrent laryngeal nerve in the present experiment. Future studies using live pigs will permit a more detailed assessment of damage to the recurrent laryngeal nerve based on movement of the vocal cords. The risk of postoperative complications such as wound infection could not be examined in the present study due to the use of dead animals.

CONCLUSIONS

Surgical procedures that provide cosmetically acceptable results are in demand. This study suggests the feasibility and safety of using pure natural orifice transluminal endoscopic surgery for thyroidectomy through a subcutaneous route with the use of an original retractor. As the next step toward clinical application of this method, additional studies are needed to apply pure NOTES to live pigs.

Author contributions: N. Ishikawa and G. Watanabe contributed to study design, supervised the study, and wrote the first draft of the manuscript. K. Nitta collected samples, analyzed and interpreted the data, and critically reviewed the manuscript. M. Kawaguchi and A. Ooi analyzed and

interpreted data and critically reviewed the manuscript. K. Nitta contributed to study design, analyzed and interpreted data, and finalized the manuscript.

Conflict of Interest: None.

REFERENCES

1. Kalloo AN, Singh VK, Jagannath SB, et al. Flexible transgastric peritoneoscopy: a novel approach to diagnostic and therapeutic interventions in the peritoneal cavity. *Gastrointest Endosc* 2004;60:114–7.
2. Bowman DE. ASGE/SAGES Working Group on Natural Orifice Transluminal Endoscopic Surgery. White Paper. October 2005. *Gastrointest Endosc* 2006;63:199–203.
3. Rattner D, Kalloo A. ASGE/SAGES Working Group on Natural Orifice Transluminal Endoscopic Surgery. White Paper. October 2005. *Surg Endosc* 2006;20:329–33.
4. Hüscher CS, Chiodini S, Napolitano C, Recher A. Endoscopic right thyroid lobectomy. *Surg Endosc* 1997;11:877.
5. Jeong JJ, Kang SW, Yun JS, et al. Comparative study of endoscopic thyroidectomy versus conventional open thyroidectomy in papillary thyroid microcarcinoma (PTMC) patients. *J Surg Oncol* 2009;100:477–80.
6. Ujiki MB, Sturgeon C, Denham D, Yip L, Angelos P. Minimally invasive video-assisted thyroidectomy for follicular neoplasm: is there an advantage over conventional thyroidectomy? *Ann Surg Oncol* 2006;13:182–6.
7. Shin S, Chung WY, Jeong JJ, Kang SW, Oh YJ. Analgesic efficacy of bilateral superficial cervical plexus block in robot-assisted endoscopic thyroidectomy using a transaxillary approach. *World J Surg* 2012;36:2831–7.
8. Shimizu K, Kitagawa W, Akasu H, Tanaka S. Video-assisted endoscopic endocrine neck surgery with a benefit of cosmesis: a new technique using a totally gasless anterior neck skin lifting method. *J Nippon Med Sch* 2002;69:2–3.
9. Marescaux J, Dallemagne B, Perretta S, Wattiez A, Mutter D, Coumaros D. Surgery without scars: report of transluminal cholecystectomy in a human being. *Arch Surg* 2007;142:823–6.
10. Hazeley JW, Narula VK, Renton DB, et al. Natural-orifice transgastric endoscopic peritoneoscopy in humans: initial clinical trial. *Surg Endosc* 2008;22:16–20.
11. Chen D, Ding K, Guo K, Hong H. Gasless single incision endoscopic thyroidectomy. *JSLs* 2012;16:60–4.
12. Kang SW, Jeong JJ, Yun JS, et al. Gasless endoscopic thyroidectomy using trans-axillary approach: surgical outcome of 581 patients. *Endocr J* 2009;56:361–9.
13. Shimizu K, Kitagawa W, Akasu H, Hatori N, Hirai K, Tanaka S. Video-assisted endoscopic thyroid and parathyroid surgery using a gasless method of anterior neck skin lifting: a review of 130 cases. *Surg Today* 2002;32:862–8.
14. Bergstrom M, Swain P, Park PO. Early clinical experience with a new flexible endoscopic suturing method for natural orifice transluminal endoscopic surgery and intraluminal endoscopy (with videos). *Gastrointest Endosc* 2008;67:528–33.
15. Ishimaru T, Iwanaka T, Hatanaka A, Kawashima H, Terawaki K. Transluminal esophageal anastomosis for natural orifice transluminal endoscopic surgery: an ex vivo feasibility study. *J Laparoendosc Adv Surg Tech A* 2012;22:724–9.