

Original research article

**Evolving technology**

**A new fluorescent anatomic pulmonary segmentectomy using PDD endoscope system<sup>TM</sup> and vitamin B2: evaluation in a clinical setting using living animal**

Masahiro Ohsima, Ryuichi Waseda, Nobuhiro Tanaka, Hideyuki Ueda, Akishi Ooi,

Isao Matsumoto

Department of General and Cardiothoracic Surgery, Kanazawa University

13-1 Takaramachi, Kanazawa, Ishikawa

Sources of Funding: No

Conflicts of Interest: No

**Word count:** 2572words

**Corresponding author:** Ryuichi Waseda

[Tel: +81-76-265-2355](tel:+81-76-265-2355)

Fax: +81-76-238-2222

E-mail: [wryuichi0119@gmail.com](mailto:wryuichi0119@gmail.com)

**Abstract (236 words)**

**Objective:** Identification of intersegmental planes is essential for successful anatomic pulmonary segmentectomy. We have previously reported a novel fluorescence technique using a photodynamic diagnosis endoscope system and vitamin B2 for identification of intersegmental planes in *ex vivo* experiments. In the present study, we investigated this technique in *in vivo* porcine lungs.

**Methods:** Cranial segmentectomy in the cranial lobe of the right lung was performed in 6 pigs using the fluorescence technique. After identification of the cranial segmental bronchus, a fluorescent substance was injected via bronchoscopy. The fluorescent segment was observed using a photodynamic diagnosis endoscope system, and the identified intersegmental plane was cut using electric cautery. The operative data collected were the rates of accurate identification of the pulmonary segment and perioperative complications. The duration and light intensity of fluorescence of the target segment were recorded to provide an objective measurement of success.

**Results:** In all procedures, it was possible to identify the target segment by its yellow-green fluorescence. The rate of accurate identification of the pulmonary segment was 100%. The fluorescence continued for more than 1 hour with adequate light intensity. No perioperative complications were encountered. No unexpected injuries of

the major segmental bronchi or vessels occurred. Hemorrhage and air leakage from the transected intersegmental plane were negligible.

**Conclusions:** The fluorescence technique involving vitamin B2 and a photodynamic diagnosis endoscope system enabled accurate and safe identification of the pulmonary segment in *in vivo* porcine lung.

### **Ultramini abstract**

We previously developed a novel fluorescence technique using a photodynamic diagnosis endoscope system and vitamin B2 to identify pulmonary segments in *ex vivo* lung. The accuracy and safety of this technique was proved in *in vivo* pig experimentation as potentially valid in the clinical situation.

## **Introduction**

Recently, with increased prevalence of small-sized non-small-cell lung carcinoma (NSCLC) or limited lung function, the demand for anatomical pulmonary segmentectomy is increasing in the treatment of primary lung cancer<sup>1,2</sup>.

Anatomical pulmonary segmentectomy requires accurate identification of pulmonary segments for 2 major reasons: complete resection of the target lesion and avoidance of perioperative complications such as intraoperative bleeding and postoperative air leakage and atelectasis, particularly with the use of only electric cautery to cut segmental borders. In other words, identification of intersegmental planes is essential for successful anatomic pulmonary segmentectomy. However, identification is often difficult without any imaging method. Various methods have been reported for identifying intersegmental planes<sup>3-6</sup>. However, all of these methods have considerable disadvantages.

The ideal method for identification of intersegmental planes should allow accurate and clear identification not only on the lung surface but also inside the lung parenchyma, as well as be easy and safe, and applicable in various surgical approaches and lung conditions. We aimed to develop an ideal method by using a commercial photodynamic diagnosis (PDD) endoscope system and vitamin B2 to establish a novel

fluorescence technique for identification of intersegmental planes<sup>7</sup>. Important features of our technique are (1) clear and accurate detection of intersegmental planes due to strong yellow-green fluorescence and (2) safety of vitamin B2. In our previous study, we reported this accuracy and clarity in *ex vivo* pig lungs. For the purpose of introducing this technique into human clinical practice, it is necessary to identify potential problems of this technique in *in vivo* lungs and to improve it.

## **Methods**

### *Our novel fluorescence technique*

The details of our fluorescence technique have been reported previously<sup>7</sup>. Briefly, our technique requires 2 key instruments, a PDD endoscope system and vitamin B2 solution. The PDD endoscope system consists of a D-Light<sup>TM</sup> system as the excitation light source and a TRICAM<sup>TM</sup> camera as the fluorescence-sensing imaging device (KARL STORZ GmbH and Co., Tuttlingen, Germany). The D-Light<sup>TM</sup> system emits light of wavelength 375–450 nm (near ultraviolet). The TRICAM<sup>TM</sup> camera is capable of fluorescence imaging, and the wavelength-dependent sensitivity is modified to achieve greater sensitivity to fluorescence than that of a standard camera. Vitamin B2 is ideal as a fluorescence substance because it is water-soluble, non-allergic, and nontoxic<sup>9</sup>. It emits a strong yellow-green fluorescence when exposed to light with a

wavelength of approximately 400 nm. In this study, flavin adenine dinucleotide (FAD) sodium (Fladd injection, Taiho Pharmaceutical Co., Ltd., Tokyo, Japan) was used as vitamin B2.

#### *Cranial segmentectomy in pig lungs*

Six adult pigs (body weight, 30 kg) were anesthetized with intramuscular injection of ketamine (10 mg/kg; Sankyo Co., Ltd., Tokyo, Japan). After a standard endobronchial tube (24 Fr; Fuji Systems Co., Tokyo, Japan) was introduced via tracheostomy, maintenance anesthesia was performed with inhalation of sevoflurane and intravenous injection of vecuronium. Single-lung ventilation was achieved with a blocker (COOPDECH<sup>®</sup>, Daiken iki Co., Osaka, Japan).

The details of pig lung anatomy have been reported previously<sup>11</sup>. Briefly, the right pig lung consists of cranial, middle, caudal, and accessory lobes. In this study, cranial segmentectomy was performed in the right cranial lobe; this procedure was considered similar to a typical segmentectomy such as that of S6. In the right cranial lobe, the cranial segment has 1 intersegmental plane adjacent to the caudal segment.

The surgical procedure was performed with right thoracotomy and single-lung ventilation. Segmental bronchi and vessels in the cranial lobe were exposed and identified. After cutting the identified cranial segmental artery, a thin bronchoscope was

inserted into the identified segmental bronchus leading to the cranial segment, followed by ligation of the root of the bronchus (Figure 1A). Vitamin B2 solution diluted with saline was injected slowly and steadily through the bronchoscope (Figure 1B). The concentration of FAD sodium was 0.4 mg/mL. Subsequently, the fluorescent segment was observed using the PDD endoscope system. After sufficient solution had been injected such that the fluorescence was observed in the peripheral lung parenchyma, the bronchoscope was removed and the bronchus was ligated. After this fluorescence had been observed and recorded for 1 h, the lung parenchyma was cut along the identified intersegmental plane by using electric cautery. The ligated segmental bronchus was cut last, and cranial segmentectomy was completed. Afterwards, the remaining caudal segment was inflated, and postoperative air leakage was evaluated.

All pigs were sacrificed with intravenous injection of potassium chloride. All experimental procedures were performed in accordance with the Principles of Laboratory Animal Care formulated by the National Society for Medical Research, and the Guide for the Care and Use of Laboratory Animals prepared by the Institute of Laboratory Animal Resources of the National Research Council, published by the National Academy Press, revised in 2010.

*Additional experiment to evaluate safety of vitamin B2*

To confirm the safety of injecting vitamin B2 solution into the airway in living animals, 100 mL vitamin B2 solution was injected via bronchoscopy into the right lung of 3 live pigs under general anesthesia. The pigs were monitored for complications for 2 weeks after injection, and sacrificed to evaluate macroscopic and microscopic findings of the lung.

#### *Data collection and measurements*

The operative data collected were the rates of accurate identification of pulmonary segments and perioperative complications. Identification of the pulmonary segment was considered successful if it allowed for complete transection of the intersegmental plane without injuries to the adjacent segmental vessels and bronchi. Therefore, the numbers of unexpected vascular and bronchial injuries were recorded. The surgical time, blood loss during the transection, and postoperative air leakage from the remaining caudal segment were also recorded. The air leakage was graded from 0 to 3 according to the Maccharini scale as follows: 0, no leakage; 1, single bubbles; 2, stream of bubbles; and 3, coalesced bubbles<sup>12</sup>. The quantity and injection duration of injected vitamin B2 solution in each procedure were recorded. The duration and light intensity of florescence in the target segment were also measured to provide a quantitative measure of success. The light intensity of florescence was measured at

15-minute intervals after injection for 1 hour by using the image-analysis software U11437 (HAMAMATSU, Hamamatsu, Japan). The light intensity of the adjacent segments was also measured for comparative purposes.

#### *Statistical analysis*

All data are expressed as mean  $\pm$  standard deviation. Comparative analyses were performed by Mann-Whitney *U* tests with StatView software (SAS Institute, Cary, NC, USA). Values of  $P < 0.05$  were considered statistically significant.

#### **Results**

All 6 cranial segmentectomies were performed successfully. In all procedures, it was possible to identify the target segment by the strong yellow-green fluorescence, both on the lung surface and inside the lung parenchyma.

The operative findings of the procedure are shown in Figure 2 and in the short videoclip (available online). The right cranial lobe consists of a cranial and caudal segment. Fluorescence imaging revealed the intersegmental line clearly in both the ventral and dorsal aspect without overexpansion of the target segment (Figure 2A, 2B). After 1 h, the fluorescence was as intense as that immediately after injection (Figure 2C). During transection of the intersegmental plane, the fluorescent intersegmental plane was easily recognizable, even inside the lung parenchyma (Figure 4D).

Transection of the intersegmental plane was completed using electric cautery without injury to the major segmental bronchi or vessel. Cutting along the fluorescent plane allowed the segmental bronchus to be identified (Figures 2E, 2F). Even after transection of the lung parenchyma, fluorescence of the target segment continued without attenuation of light intensity. The cranial segmental bronchus was finally cut, and cranial segmentectomy was completed.

After the resections, all the remaining caudal segments expanded well (Figure 3A). In the evaluation of postoperative air leakage with water, 5 cases were Maccharini Grade 0, and only 1 case had small air leaks (Maccharini Grade 1) (Figure 3B).

The rate of accurate identification of the pulmonary segment was 100%. The mean quantity of injected vitamin B2 solution into the cranial segment was  $57.2 \pm 9.5$  mL over  $313.1 \pm 40.9$  s. No occurrences of unexpected injuries to the segmental bronchi or vessels or of incorrect identification of the target segment were observed. The mean time of transection of the intersegmental plane was  $13.2 \pm 1.6$  min, and the mean blood loss was  $4.0 \pm 1.1$  g. These operative data are summarized in Table 1.

The light intensity of the target fluorescent segments was  $209.8 \pm 12.8$  immediately after injection,  $214.6 \pm 10.1$  at 15 min,  $219.0 \pm 9.8$  at 30 min, and  $223.4 \pm 9.4$  at 1 h. For the adjacent non-fluorescent segments, the measured light intensity was

59.1  $\pm$  9.6 immediately after injection, 62.2  $\pm$  10.3 at 15 min, 63.7  $\pm$  9.4 at 30 min, and 66.5  $\pm$  9.7 at 1 h. At each measurement from injection until 1 h after injection, the light intensity of the target fluorescent segment was significantly stronger than that of the adjacent non-fluorescent segments (Figure 4).

Regarding the additional experiment, no complications were observed for 2 weeks after injection of 100 mL vitamin B2 solution into the right lung. Further, there were no abnormal findings in the macroscopic and microscopic evaluations of the injected lung.

## **Discussion**

In this study, we developed our previously reported novel fluorescence technique using a PDD endoscope system and vitamin B2 for clinical application, and evaluated the efficacy and safety of this technique in *in vivo* pig lungs. This technique enabled clear identification of the target pulmonary segment and accurate and easy performance of segmentectomy in *in vivo* pig lungs.

Pulmonary segmentectomy is technically more complex than pulmonary lobectomy, because it requires three-dimensional knowledge of the relevant bronchovascular relationships and the possible anomalies of the vascular branches. Furthermore, identification of the intersegmental plane is essential to perform

segmentectomy—but difficult without an imaging method. The most common method used is the air inflation–deflation technique<sup>3,4</sup>. Although this technique makes it easy to identify the intersegmental plane on the lung surface, it may be difficult to identify the intersegmental plane inside the lung parenchyma when cutting the segment. In addition, clear detection of the intersegmental plains with this air technique may be problematic in abnormal lungs with severe emphysema or fibrosis. Moreover, during video-assisted thoracoscopic surgery (VATS) or minimal-access open surgery, an inflated lung may obstruct exposure and limit visualization of the target segment. An important feature of our technique is that it allows very clear identification of the intersegmental plane owing to the strong fluorescent signal. The strong yellow-green fluorescence clearly indicated the intersegmental planes, not only on the surface of the lung but also inside the lung parenchyma. In addition, relatively little vitamin B2 solution was needed, thereby avoiding overexpansion of the target segment.

Regarding other approaches to segmental identification, several dye methods using indocyanine green (ICG) have been reported<sup>5,6</sup>. Misaki and colleagues reported a novel method for the identifications of adjacent lung segments with infrared thoracoscopy<sup>5</sup>. After ligation of the corresponding pulmonary artery of the target segment, ICG was administered intravenously during infrared thoracoscopy. This

technique can be used to identify the intersegmental line without lung inflation; thus, obstruction of the surgical field and the influence of emphysema may be minimized. However, the duration of intravascular ICG visualization is too short to perform segmentectomy, and a large amount of ICG may be required in complicated segmentectomies. Furthermore, anatomic segmentectomy is ideally guided by the segmental bronchus, which is the most reliable landmark of a segment because of its rare anomaly. Oh and colleagues used transbronchial injection of ICG similar to our technique<sup>6</sup>. This technique is simple and may overcome certain disadvantages of the previous method. However, a serious difficulty remains—ICG poses risks of allergy and tissue toxicity. Thus, ICG cannot be used in patients who have an iodine allergy, and undiluted or high-concentration ICG can induce mucosal inflammation and epithelial injury<sup>11</sup>. The situation is markedly different with vitamin B2 as the fluorescence substance. Vitamin B2 is a water-soluble vitamin. It has theoretically no risk of allergic reaction or tissue toxicity; further, it is maintained at a constant level in major organs, and any excess is eliminated in the urine<sup>9</sup>. We also confirmed the safety of injecting vitamin B2 into the lung in living pigs as an additional experiment in this study. After a large amount of vitamin B2 was injected into the lung, no adverse events or pathological changes were found.

The main focus of this study was to evaluate the efficacy and accuracy of our fluorescence technique in *in vivo* lungs. As mentioned above, we evaluated previously the efficacy and accuracy of our technique in *ex vivo* pig models. Namely, adequate light intensity and long duration of fluorescence were confirmed in lungs without circulation, ventilation, and temperature. In this study, we could confirm that the strong light intensity and long duration of fluorescence in *in vivo* lungs matched those in *ex vivo* lungs, and were adequate to allow performance of all types of pulmonary segmentectomy. Moreover, with our technique, blood loss during the transection and postoperative air leakage from transected planes were minimal. Inaccurate transection of the intersegmental plane leads to increased hemorrhage and air leakage; thus, the accuracy of our identified planes was confirmed clinically.

Another important focus of this study was to improve our fluorescence technique for application in the clinical situation. We injected vitamin B2 solution into the target segment bronchoscopically, without any needle punctures or catheter insertions into the target bronchus in the surgical field. Incorrect puncture or injection into segmental vessels, especially veins, leads to complications such as bleeding and air embolism. The bronchoscopic injection of vitamin B2 is not only a simple and easy method, but also a safe method. Moreover, many virtual navigation tools for

bronchoscopy have been developed in recent years, which may be helpful for our technique. This study led to improved safety and advancements in our fluorescence technique, which was previously shown to accurately and clearly identify intersegmental planes. Therefore, it might be an ideal method for identification of intersegmental planes.

The first limitation of the present study was that we used pig and not human subjects. Therefore, there is no assurance that the same results would be observed in humans. However, we have already begun our clinical trial of this technique, and have obtained favorable results. Second, our technique requires transbronchial injection of vitamin B2 solution. We should consider collateral connections such as Kohn pores and Lambert canals, as well as the unfavorable effects of abnormal lungs such as those with emphysema or fibrosis, in human clinical practice. These factors may impair clear and precise identification of the intersegmental plane by fluorescence. However, these unfavorable effects may be minimal in this technique compared with the air inflation–deflation technique, because, as a liquid, the vitamin B2 solution disperses less readily than does air. From a technical aspect, slow and low-pressure injection of vitamin B2 may minimize the effects. Furthermore, as another approach in abnormal lungs, we modified our fluorescence technique by introducing vitamin B2 into lung

perfusion without bronchial injection. We have already begun to examine this modified technique in experimental study.

In conclusion, this fluorescence technique involving a PDD endoscope system and vitamin B2 allowed identification of the pulmonary segment in *in vivo* pig lung. The advantages of this technique are clarity and safety, both of which are important in clinical practice. This technique could be applicable for various procedures in general thoracic surgery, for example, sentinel lymph node detection and marking of small lung nodules<sup>13</sup>.

**Disclosures**

Masahiro Ohsima, Ryuichi Waseda, Isao Matsumoto have no conflicts of interest or financial ties to disclose.

## References

1. Okada M, Koike T, Higashiyama M, Yamato Y, Kodama K, Tsubota N. Radical sublobar resection for small-sized non-small cell lung cancer: a multicenter study. *J Thorac Cardiovasc Surg.* 2006;132:769-75.
2. Keenan RJ, Landreneau RJ, Maley RH Jr, Singh D, Macherey R, Bartley S, et al. Segmental resection spares pulmonary function in patients with stage I lung cancer. *Ann Thorac Surg.* 2004;78:228-33.
3. Tsubota N. An improved method for distinguishing the intersegmental plane of the lung. *Surg Today.* 2000;30:963-4.
4. Okada M, Mimura T, Ikegaki J, Katoh H, Itoh H, Tsubota N. A novel video-assisted anatomic segmentectomy technique: Selective segmental inflation via bronchifiberoptic jet followed by cautery cutting. *J Thorac Cardiovasc Surg.* 2007;133:753-8.
5. Oh S, Suzuki K, Miyasaka Y, Matsunaga T, Tsuchima Y, Takamochi K. New technique for lung segmentectomy using indocyanine green injection. *Ann Thorac Surg.* 2013;95:2188-90.
6. Misaki N, Chang SS, Igai H, Tarumi S, Gotoh M, Yokomise H. New clinically applicable method for visualizing adjacent lung segments using an infrared

- thoracoscopy system. *J Thorac Cardiovasc Surg.* 2010;140:752-6.
7. Waseda R, Oda M, Matsumoto I, Takizawa M, Suzuki M, Ohshima M, et al. A novel fluorescence technique for identification of the pulmonary segments by using the photodynamic diagnosis endoscope system: An experimental study in ex vivo porcine lung. *J Thorac Cardiovasc Surg.* 2013;146:222-7
  8. Misaki N, Chang SS, Igai H, Tarumi S, Gotoh M, Yokomise H. New clinically applicable method for visualizing adjacent lung segments using an infrared thoracoscopy system. *J Thorac Cardiovasc Surg.* 2010;140:752-6.
  9. Konings EJ. Water-soluble vitamins. *J AOAC Int.* 2006; 89:285-8.
  10. Price N, Gottfried MR, Clary E, Lawson DC, Baillie J, Mergener K, et al. Safety and efficacy of India ink and indocyanine green as colonic tattooing agents. *Gastrointest Endosc.* 2000;51:438-42.
  11. Nakakuki S. Bronchial tree, lobular division and blood vessels of the pig lung. *J Vet Med Sci.* 1994;56:685-9.
  12. Macchiarini P, Wain J, Almy S, Darteville P. Experimental and clinical evaluation of a new synthetic, absorbable sealant to reduce air leaks in thoracic operations. *J Thorac Cardiovasc Surg* 1999;117:751-758.
  13. Matsumoto I, Ohta Y, Waseda R, Masaya T, Oda M, Watanabe G. Vitamin B2 as a

tracer for intraoperative pulmonary sentinel node navigation surgery. *Anticancer*

*Res.* 2010; 30: 4109-14.

## **Figure legends**

Fig.1: Injection of vitamin B2

A. Identified and encircled cranial segmental bronchus. B. Fluorescence of vitamin B2.

Fig. 2: Segmentectomy in the right cranial lobe

A–E. Fluorescence imaging. F. Normal light imaging.

Fig. 3: Findings after cranial segmentectomy

A. Inflation of caudal segment. B. Water-sealed test of air leakage.

Fig. 4: Comparison of light intensity between the fluorescent and adjacent non-fluorescent segments measured at 15-min intervals from immediately after injection until 1 h after injection.

## **Abbreviations and Acronyms**

VATS: video-assisted thoracic surgery

PDD: photodynamic diagnosis

FAD: flavin adenine dinucleotide

ICG: indocyanine green

## Cranial segmentectomy (n = 6)

---

Identification rate (%)	100
Complications	0
Bronchial injury	0
Vessel injury	0
Blood loss during transection (g)	4.1 $\pm$ 1.1
Air leakage	Grade 0: 5, Grade 1: 1 *

\*Graded by the Maccharini scale

Table 1


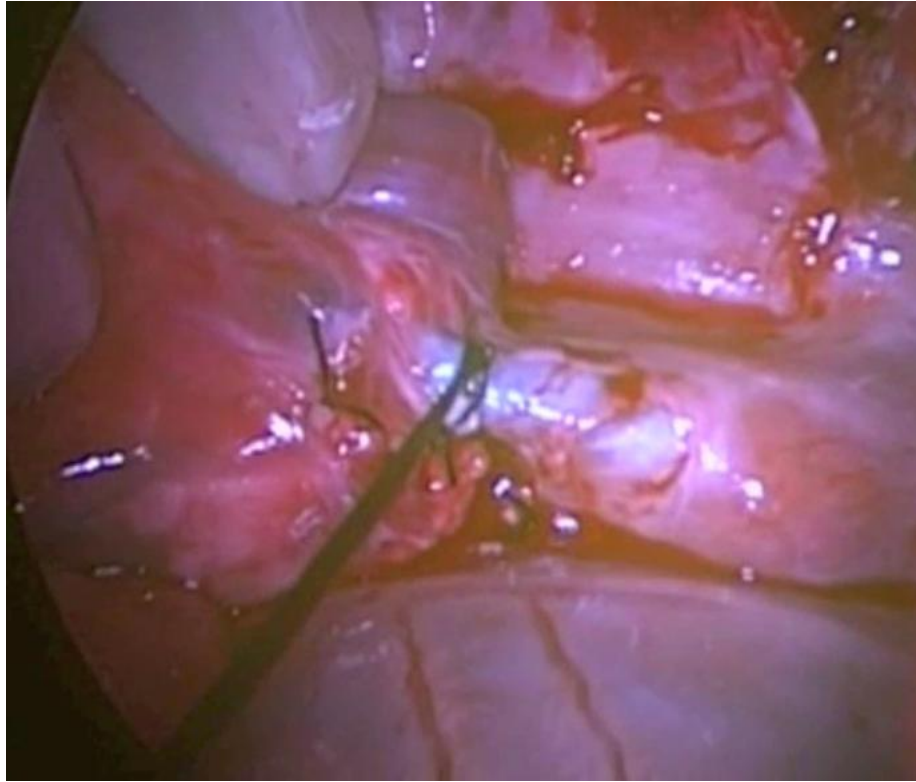


Figure 1    A    |    B

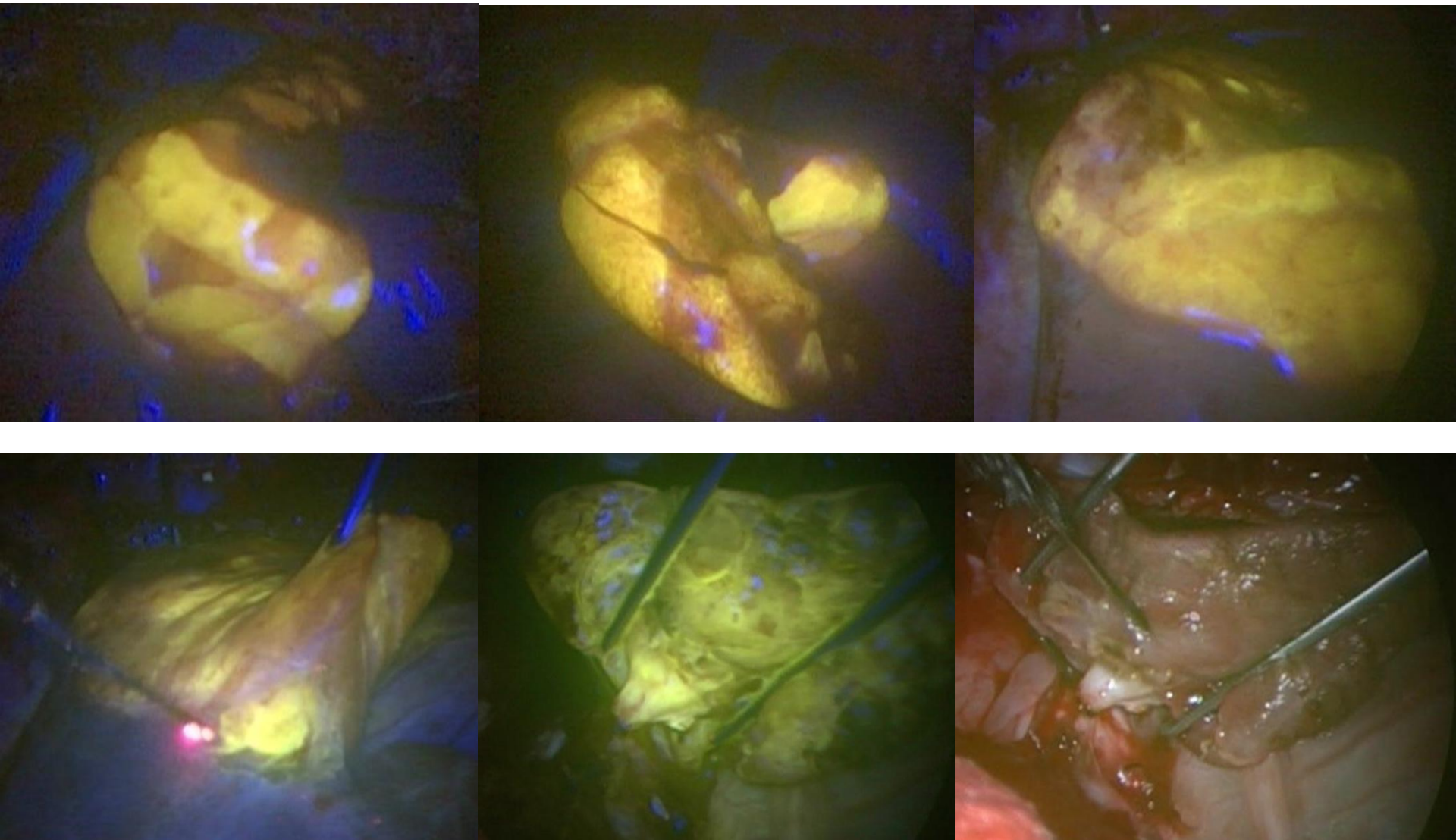


Figure 2

A	B	C
D	E	F

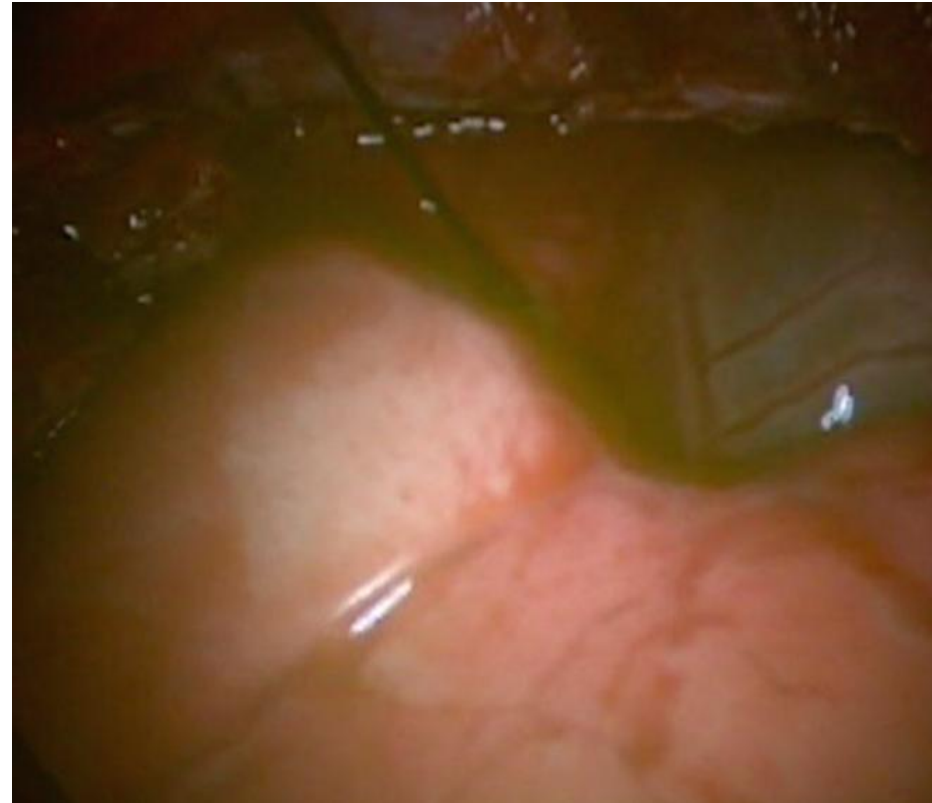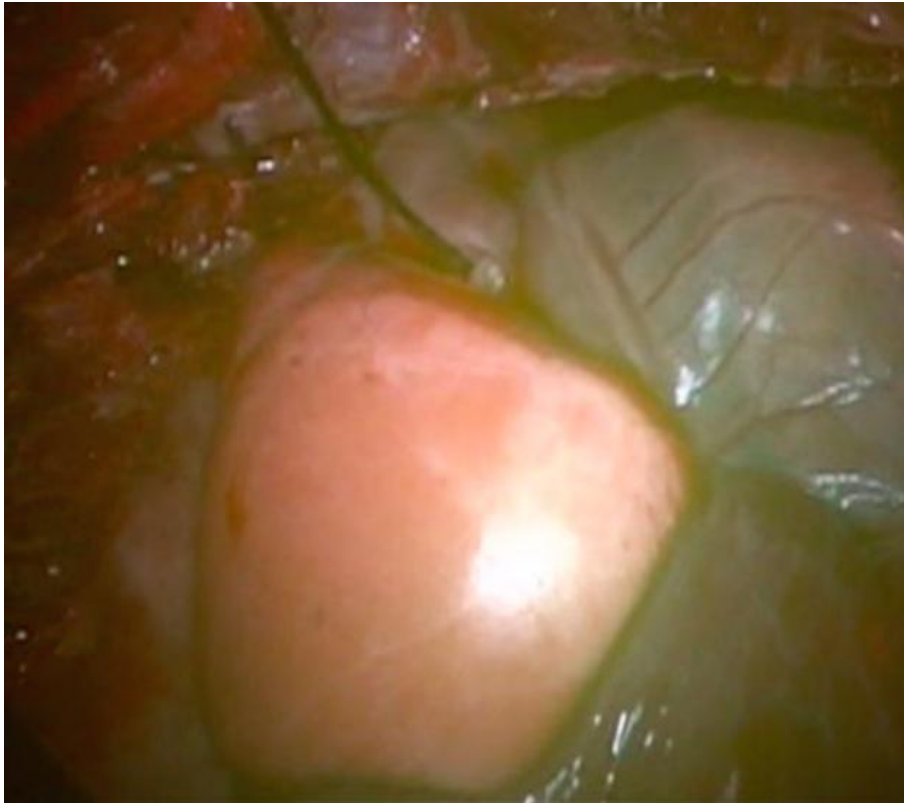


Figure 3    A   |   B

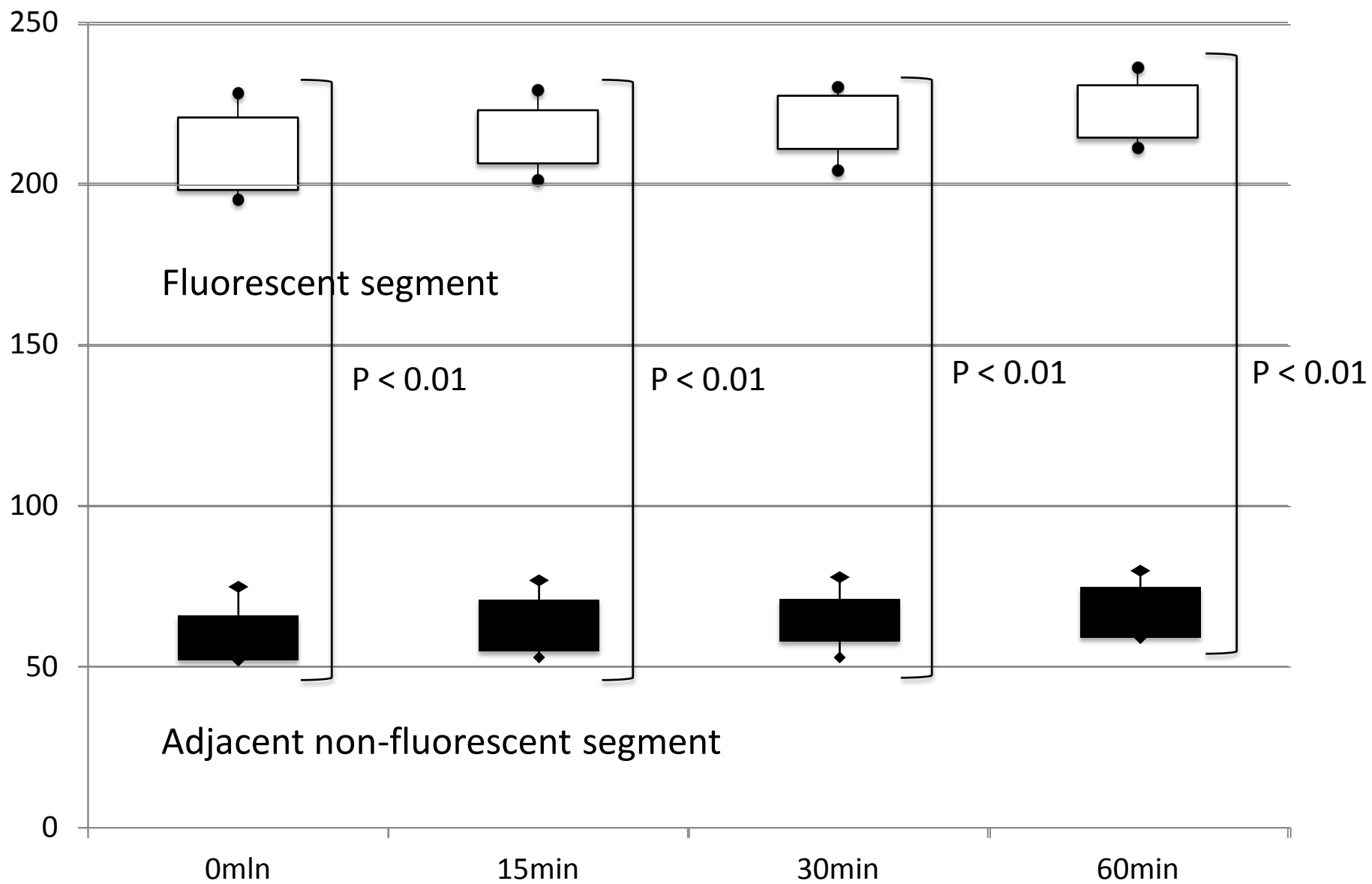


Figure 4