

# Imaging of interstitial fluid in skin and subcutaneous tissue using dual-frequency ultrasonography before and immediately after lymph drainage in breast cancer-related lymphedema patients

Misako Dai, Mihoe Katayama\*, Junko Sugama\*\*, Mayumi Okuwa\*\*,  
Takeshi Ueyama\*, Tomoko Minamiyama\*, Keiko Ota\*, Terumi Iuchi,  
Masaru Matsumoto, Toshio Nakatani\*, Hiromi Sanada\*\*\*

## Abstract

**Background:** Breast cancer-related lymphedema (BRCL) occurs in 12-28% of cases after radical lymph node surgery and/or radiotherapy of the lymph nodes. Quantitative assessments before and immediately after treatment for lymphedema are important to continue adequate treatment to prevent cellulitis and reduce edema. The present study aimed to assess skin hardness and the utility of dual-frequency ultrasonography of the skin and subcutaneous tissue for assessing BRCL before and immediately after manual lymph drainage (MLD).

**Methods:** This observational study examined 15 patients with unilateral secondary lymphedema attending two lymphedema clinics in Japan between June 2012 and June 2013. Skin hardness was assessed using a 10-cm visual analog scale (VAS). Ultrasonography was performed at 20 MHz for skin and 10 MHz for subcutaneous tissue. Edema was evaluated using circumference, skin elasticity and skin moisture.

**Results:** Patients were assigned to Group A (n=10) with decreased VAS and Group B (n=5) with unchanged VAS. Results of ultrasonography and other characteristics were then compared between groups. Group A showed decreased numbers of low-echogenic pixels (LEPs) and decreased pixel uniformity after MLD, whereas Group B did not. Edema evaluations showed small differences or were unchanged.

**Conclusion:** These findings suggest that interstitial fluid in the dermis and subcutaneous tissue is decreased after lymph drainage in patients who report softening of the skin after MLD, and can therefore be used as a quantitative indicator for the effectiveness of MLD.

## Key words

lymphedema, ultrasound imaging, quantitative assessment, lymph drainage, prevention

## Introduction

Breast cancer-related lymphedema (BRCL) remains an important complication, occurring in 12-28% of cases after radical lymph node surgery and/or radiotherapy of the lymph nodes<sup>1-3)</sup>. Lymphedema is

a particular type of edema caused by dysfunction of the lymphatic system, resulting in the accumulation of protein-rich fluid in the dermis and hypodermis<sup>4-6)</sup>. Initially presenting as unilateral painless swelling that usually starts on the dorsal aspect of the arm,

---

Doctoral Course, Deviation of Health Science, Kanazawa University

\* Kanazawa Card: ovascular Hospital

\*\* Institute of Medical, Pharmaceutical and Health Sciences, Kanazawa University

\*\*\* Department of erotological nursing/ wound care management, division of health science and nursing, graduate school of medicine, the University of Tokyo

including non-pitting edema, later stages include increased volume of the upper limb, hardening of the skin, and a risk of recurrent infection<sup>7)</sup>. Lymphedema management programs are often associated with combined decongestive physical therapy (CDP), which aims to reduce limb volume, restore limb shape, and improve skin and tissue condition<sup>8)</sup>. Patients have to continue lymphedema management for the long term<sup>8)</sup>. In particular, lymph drainage is typically performed by hand, so the effects will not be the same for each condition every time. Adequate assessment of fluid accumulation is important for patients and clinicians to assess the effectiveness of treatment. In most cases, effects on clinical findings are assessed qualitatively before and immediately after lymph drainage based on pitting of the skin on the affected limb<sup>9)</sup>. This method has a long history, but provides no direct information about edema within the dermis and subcutaneous tissue<sup>10)</sup>. This is problematic for assessing improvements in morbidity, preventing cellulitis and maintaining quality of life (QOL). Several researchers have described reductions in limb volume and improved QOL following CDP including lymph drainage for at least 4 weeks<sup>11 · 12)</sup>. However, these effects were assessed over the long term, not before and immediately after treatments. Quantitative analyses have been reported using lymphoscintigraphy<sup>13)</sup> and near-infrared fluorescence imaging<sup>14)</sup>. Immediately after lymph drainage, lymph flow rate and lymph volume were increased. However, these imaging methods do not show changes in the condition of the skin and subcutaneous tissue. In addition, these methods are time-consuming and expensive, and require intradermal injection of a radionuclide. Quantitative, non-invasive, real-time methods of assessment have therefore yet to be reported.

Ultrasonography is an imaging modality that has been routinely used for more than 20 years in dermatology, and can demonstrate dermal edema. The ultrasonography device enables simple, non-invasive, quantitative imaging in real time. Some studies have identified particular aspects of lymphedema on ultrasonography<sup>15-17)</sup>. The affected limbs have shown increases in both skin thickness<sup>16)</sup> and the number of low echogenicity pixels (LEPs)<sup>15)</sup>

<sup>16)</sup> using a 20-MHz probe. Subcutaneous tissue has shown a cobblestone appearance and thickening on imaging at 7.5-10 MHz<sup>16 · 17)</sup>. Such studies have revealed characteristics of skin and subcutaneous tissue showing lymphedema, but have not made comparisons to clinical assessments or assessed the effects of treatment. Balzarini reported skin hardness and ultrasound imaging in subcutaneous tissue at 7.5 MHz and provided qualitative assessments of “soft fluid”, “medium mix”, and “hard fibrosis”<sup>17)</sup>. However, the method used to classify skin hardness is unknown and only subcutaneous tissue was tested without control. Changes in imaging results for accumulation of fluid in the skin and subcutaneous tissue before and immediately after have thus yet to be researched in detail.

The purpose of the present study was to assess skin hardness and clarify the utility of dual-frequency ultrasonography of the skin and subcutaneous tissue for assessing BRCL before and immediately after lymph drainage.

## Materials and Methods

### 1. Study design and participants

This observational study was performed from June 2012 to June 2013, involving a series of patients with unilateral secondary lymphedema attending two lymphedema clinics in Japan.

Subjects who fulfilled the following criteria were eligible for the study: unilateral upper limb lymphedema after treatment for breast cancer; >12 months after surgery or adjuvant treatment, in order to provide a reliable follow-up period to detect any possible metastases; lymphedema stage II or late II according to the criteria of the International Society of Lymphedema<sup>18)</sup>; and continued CDP including lymph drainage. Exclusion criteria included subjects with active cancer and those on diuretic therapy or other edema-influencing drugs. Patients were identified and recruited by physicians specializing in lymphedema. A researcher and patient then measured each parameter before and immediately after manual lymph drainage (MLD). MLD was performed by a therapist licensed in lymph drainage by the Medical Lymph Drainage Association of Japan.

All protocols were approved by the ethics

committee at Kanazawa University and all participants provided written informed consent prior to enrolment in the study.

## **2. Procedures**

Before the start of measurements, the investigator marked the site of examinations at 10 cm proximal to the ulnar styloid process for both affected and unaffected arms. The patients assessed skin hardness by themselves using pinch and lift of a skinfold. A researcher then performed edema evaluations and ultrasound imaging. Measurements were completed each day between 13:00 and 16:00 and the patient sat in a chair with the arm supported initially in abduction. The researcher provided supervision on how to perform assessment and analyze ultrasound imaging for 2 physicians specializing in lymphedema and 3 sonographers.

## **3. Ultrasonography**

Images of the skin were recorded before and immediately after MLD using a Dermascan C ultrasound system (Cortex Technology, Smedevaenget, Denmark) at 20 MHz. Ultrasound gel was applied liberally to the skin and the probe placed transversely on the arm. Field size was set to 13.42 mm wide and 22.40 mm deep. A two-dimensional image of the skin was produced and recorded by computer and viewed in gray scale. Gain was adjusted as necessary to optimize image quality and boundary definition.

Images of subcutaneous tissue were recorded before and immediately after MLD using Mylab5 (Hitachi Medical, Chiba, Japan) with a frequency of 10 MHz. Imaging of the skin, subcutaneous tissue, muscle, and sometimes bone was possible. Ultrasound gel was again applied to the area being examined. In addition, a gel “stand-off” (a small polyethylene bag containing ultrasound gel) was placed on the arm to aid delineation and identification of the gel/skin boundary. Measurement dimensions were set to 4.0 cm wide and 5.0 cm deep to encompass the full depth of subcutaneous tissue. Gain was adjusted to increase resolution of the deeper boundaries and compensate for the natural attenuation in signal as the sound wave passes through tissue.

The patient sat in a chair with the arm supported initially in abduction. Gain was adjusted to increase

resolution of the deeper boundaries and compensate for the natural attenuation in signal as the sound wave passes through tissue.

We decided quantitative parameters through qualitative assessment. In each image of the skin, the number of LEPS<sup>16-19)</sup> and subcutaneous pixel uniformity<sup>20)</sup> was measured using Image J analysis software (v1.42q; National Institutes of Health). In this system, amplitudes of echoes from single image elements (pixels) are assigned to a numeric scale (0 to 255). The low echogenic range extends from 0 to 30.

$LEP (\%) = \frac{\text{number of low echogenic pixels (0-30)}}{\text{number of total pixels (0-255)}} \times 100$

The uniformity of subcutaneous tissue considered as control was computed.

$$\text{Pixel uniformity} = \frac{ROI_{max} - ROI_{min}}{ROI_{max} + ROI_{min}} \times 100$$

where  $ROI_{max}$  and  $ROI_{min}$  were the maximum and minimum pixel values in the same region of interest (ROI), respectively, in the medial forearm. Care was taken to avoid including edge artifacts in the ROI. To help minimize the effect of noise on measurement, the image was convolved with a 9-point low-pass filter<sup>21)</sup>.

## **4. Skin hardness**

Skin hardness was assessed before and immediately after MLD by each patient using a 10-cm visual analog scale (VAS), with 0 cm as soft and 10 cm as hard. After MLD, we considered skin hardness to be softened when VAS decreased more than 0.5 cm. The researcher and physical therapists were blinded to group allocations.

## **5. Edema evaluations**

The principal researcher undertook measurements of arm circumference using a tape measure at 10 cm below the elbow<sup>18)</sup>. Skin elasticity was determined using a non-invasive, in vivo suction skin elastin meter (Cutometer MPA580; Curage & Khazaka, Cologne, Germany) with 450 mbar and 2-mm aperture size probe<sup>22, 23)</sup>. We determined the following parameters: R0, which looks at the maximum amplitude and represents the passive behavior of the skin to force; R2, gross elasticity (resistance versus ability to return) and R7, portion of elasticity compared to the complete curve. Skin moisture was measured using a Moisture Meter D (Delfin Technologies, Kuopio, Finland) with a 2-mm probe

head<sup>24</sup>).

## 6. Characteristics

These data included age, body mass index (BMI), circumference at baseline, and duration of lymphedema.

## 7. Analysis

We divided patients into Group A if VAS immediately after MLD was decreased compared to before MLD, and to Group B if VAS was unchanged. We compared these groups in terms of the main outcomes of findings on ultrasonography imaging and edema evaluations. Data are presented as mean  $\pm$  standard. We used the Wilcoxon test and paired t test for comparisons before and just after lymph drainage. A value of  $p < 0.05$  was chosen as the level of significance. JMP<sup>®</sup> statistical software (SAS Institute, State of North Carolina, USA) was used for all calculations.

## Results

A total of 21 patients were initially recruited, but 6 patients did not meet the inclusion criteria. As a result, analysis was performed for 15 patients. Ten patients felt their skin had softened and were categorized as Group A. Five patients considered their skin was unchanged and thus comprised Group B (Table 1). Groups A and B showed no significant differences in arm circumferences, age, BMI, or duration of lymphedema (Table 2).

### 1. LEPs in the skin

The dermis was easily identified on ultrasound images and defined as the space between the epidermal entrance echo and the interface with the hypo-echogenic subcutaneous space (Figure 1).

Images from Group A showed decreased hypo-echogenicity of images after MLD, whereas no

changes were seen in Group B. The results of LEP measurements are shown in Figures 2 and 3. Group A showed decreased LEPs in skin immediately after MLD ( $p=0.01$ ), while Group B showed no changes.

Subcutaneous tissue showed a cobblestone appearance on ultrasonography in Group A (Figure 4). The unevenness of the internal echo appeared more even in Group A, but again no change was seen in Group B. Group A showed decreased pixel uniformity in subcutaneous tissue immediately after MLD ( $p=0.03$ ), while Group B showed no change (Figures 5, 6).

### 2. Edema evaluations

Circumference of the upper limb was significantly decreased immediately after MLD compared to before MLD ( $p=0.00$ ), by 0.2 cm in Group A and by 0.3 cm in Group B. R2 was significantly decreased immediately after MLD in Group A ( $p=0.01$ ), and R0 was significantly decreased after MLD in Group B ( $p=0.00$ ). Differences were small in both circumference and skin viscoelasticity. Skin moisture was unchanged after MLD in both groups (Table 3).

## Discussion

This study is the first to report changes in skin and subcutaneous tissue immediately after MLD using LEP and pixel uniformity from ultrasound imaging.

Table 1. Skin hardness (VAS) before and immediately after MLD

VAS (cm)	Before MLD			After MLD			P
	Median	Min	Max	Median	Min	Max	
Group A (n=10)	7.4	6.5	8.4	5.6	4.0	7.0	0.00*
Group B (n=5)	5.2	5.0	5.5	5.2	5.0	5.5	0.35

n, number of women in test; Min, minimum value;

Max, maximum value

\*  $p < 0.05$ , Wilcoxon test

The skin became softer in Group A

Skin hardness did not change in Group B

Table 2. Characteristics of subjects in Groups A and B

Parameters (n=15)	Group A (n=10)			Group B (n=5)			P
	Median	Min	Max	Median	Min	Max	
Age (years)	58	52	66	59	30	64	0.19
BMI (kg/m <sup>2</sup> )	24.7	20.5	27.4	23.3	20.8	24.9	0.29
Duration of lymphedema (years)	5.0	2.0	21.0	4.5	3.0	7.0	0.12
Difference in circumference between affected and unaffected limbs (cm)	2.0	0.0	11.5	0.2	0.0	5.6	0.07

n, number of women in test ; Min, minimum value; Max, maximum value

\*  $p < 0.05$ , Wilcoxon test

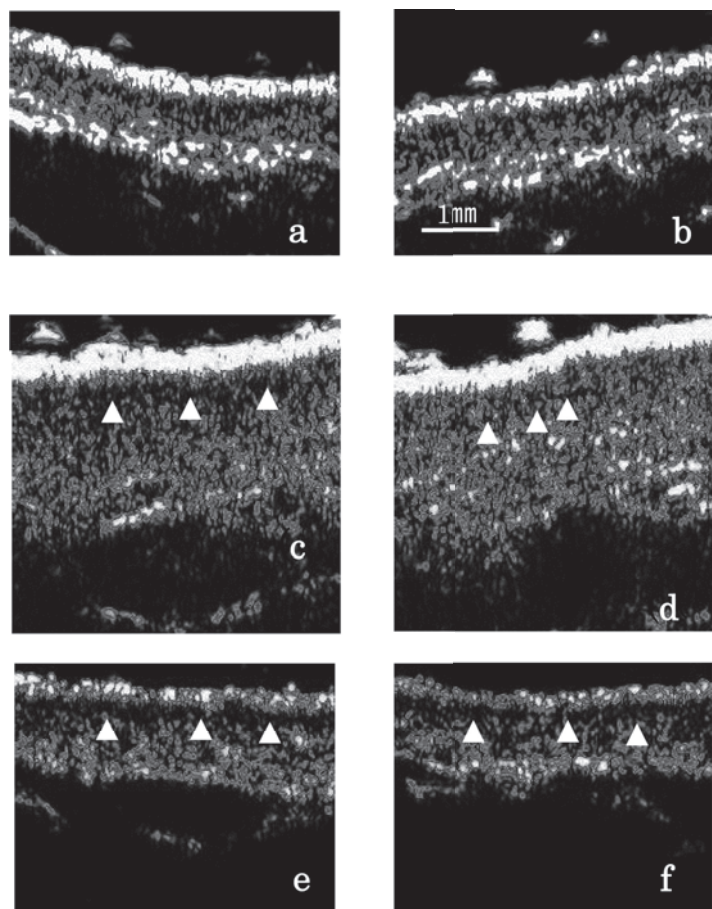


Figure 1. Ultrasonographic images of the dermal layer before and immediately after MLD of a woman (52 years old). (a) before MLD in unaffected limb; (b) immediately after MLD in unaffected limb; (c) before MLD in group A; (d) immediately after MLD in group A; (e) before MLD in group B; (f) immediately after MLD in group B. Group A shows decreased low-intensity findings in the superficial layer just after MLD (white arrowheads). No changes are apparent in Group B and unaffected limb.

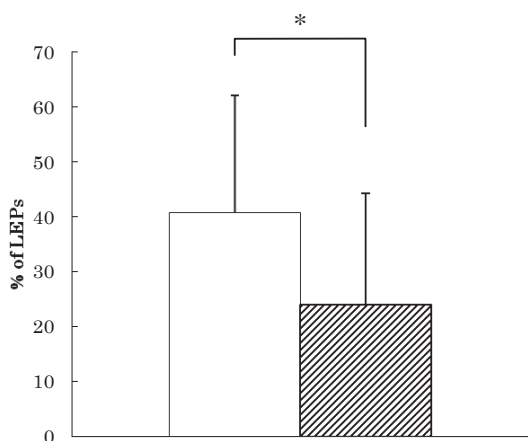


Figure 2. Dermal echogenicity of before MLD (open bar) and immediately after MLD (shaded bar) in Group A.

LEPs in dermal images, shown as a percentage of the total number of pixels. Data are shown as mean values with standard deviation.

\* $p < 0.05$

LEP decreased significantly in Group A ( $p=0.01$ ), while Group B showed no change.

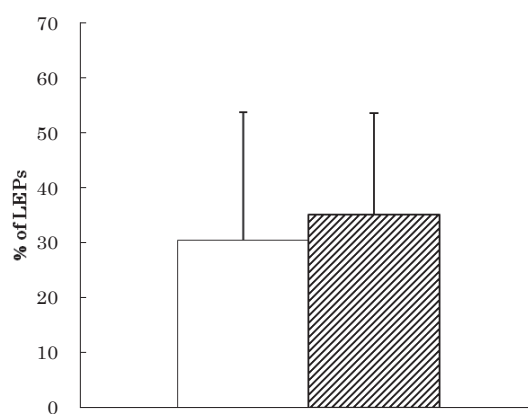


Figure 3. Dermal echogenicity of before MLD (open bar) and immediately after MLD (shaded bar) in Group B.

LEPs in dermal images, shown as a percentage of the total number of pixels. Data are shown as mean values with standard deviation.

No significant differences are seen between before and immediately after MLD.

The study focused on changes in skin hardness from before to immediately after lymph drainage and assessed changes of fluid accumulation in skin and subcutaneous tissue using dual-frequency ultrasound imaging. Following lymph drainage, LEP of the dermis and pixel uniformity of the subcutaneous tissue were significantly decreased only in Group A. These findings suggest that interstitial fluid in the dermis and subcutaneous tissue are decreased after lymph drainage in patients who report the skin becoming softer. In addition, even if edema evaluations appear unchanged, LEP can show changes in skin. Clinical assessment using ultrasonography therefore appears feasible.

The reduction in LEP following lymph drainage in the present study was due to decreased levels of water in the dermal layer. In a previous study, LEP was reportedly increased in limbs affected by lymphedema<sup>15</sup>. Histological findings from a previous study indicated that collagen bundles in the papillary dermis are thin<sup>25</sup>. In addition, the histological findings of Tassenov<sup>26</sup> show decreased collagen density in the dermal layer and low pigmentation on the medial side of the affected forearm. In other words, collagen in the dermal layer is below the resolution of the ultrasonography device (60  $\mu\text{m}$ ), and does not reflect ultrasound. In a study that used magnetic resonance imaging (MRI), LEP and the  $T_2$  value on MRI showed a positive correlation<sup>27</sup>. The  $T_2$  value indicates the amount of water. Pixel uniformity in subcutaneous tissue was significantly decreased after MLD in those patients in whom the skin became softer. Subcutaneous tissue in lymphedema has already been reported to include irregular fat cells<sup>26</sup>. In addition, MRI spectroscopy has shown that limbs affected by lymphedema contain more water than healthy limbs<sup>26</sup>. In other words, subcutaneous tissue contains not only irregular fat, but also an accumulation of excess water. Pixel uniformity enables quantification of internal heterogeneity on ultrasonography<sup>20</sup>. The decrease in pixel uniformity in the present study was therefore thought to indicate a reduction in the amount of water in subcutaneous tissue. LEP and pixel uniformity will therefore offer original quantitative parameters to assess the effect of lymph drainage. Based on the results for patient characteristics,

severity was low among those patients who had no changes in skin hardness. These patients also required continuation of self-management. Decreases in LEP can be shown even without changes in skin hardness or circumference. Our hope is that these findings will serve as a great motivation for continuing self-management over the long-term. Clinically significant changes between before and after lymph drainage were not observed for circumference, which has been the gold standard for assessment methods, or for skin viscoelasticity and the amount of water in the dermis, which have been used in clinical studies. However, the difference in data was very small. Changes in the dermal layer and subcutaneous tissue in terms of LEP and pixel uniformity were identified, and ultrasonography was found to be useful for assessments immediately before and after lymph drainage.

The present results suggest that ultrasonography is useful for clinicians and researchers to assess lymphedema, allowing comparison between individuals and assessment of the pathological state.

The key limitation to the present study was considered to be the small number of subjects.

In conclusion, edema in the skin and subcutaneous tissue were reduced immediately after MLD in patients who reported softening of the skin. LEP and pixel uniformity appear useful for clinicians and researchers in assessing the effects of MLD.

#### **Acknowledgment**

This work was supported by Grant-in-Aid for Young Scientists (B) Grant Number 25862142.

#### **Disclosure**

None.

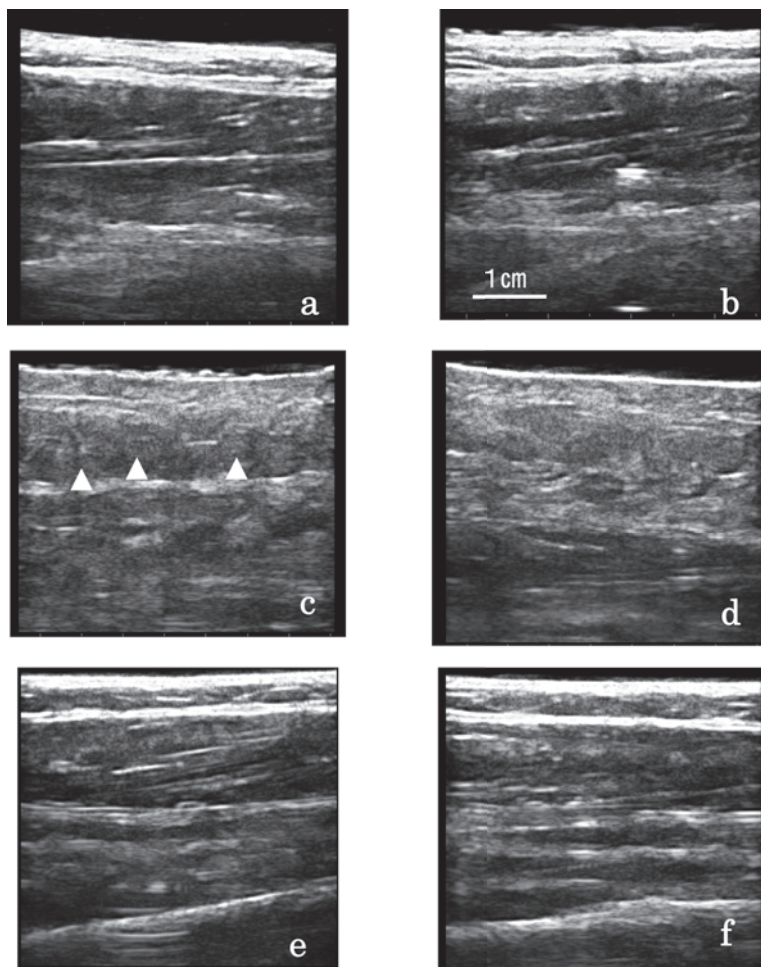


Figure 4. Ultrasonographic images of the subcutaneous tissue before and immediately after MLD of a woman (60 years old) (a) before MLD in unaffected limb; (b) immediately after MLD in unaffected limb; (c) before MLD in group A; (d) immediately after MLD in group A; (e) before MLD in group B; (f) immediately after MLD in group B. Unevenness in the internal echo within subcutaneous tissue (white arrowheads) appears to become more even in Group A, but no change is seen in Group B and unaffected limb.

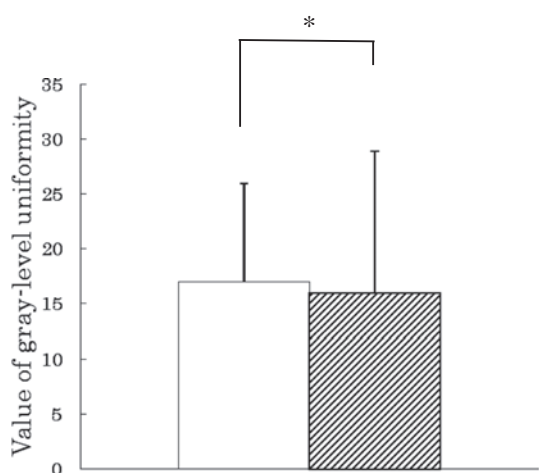


Figure 5. Pixel uniformity in subcutaneous tissue before MLD (open bar) and immediately after MLD (shaded bar) in Group A.

Data are shown as mean values with standard deviation.

\* $P < 0.05$

Pixel uniformity decreased significantly in Group A, while Group B showed no change. ( $p=0.03$ )

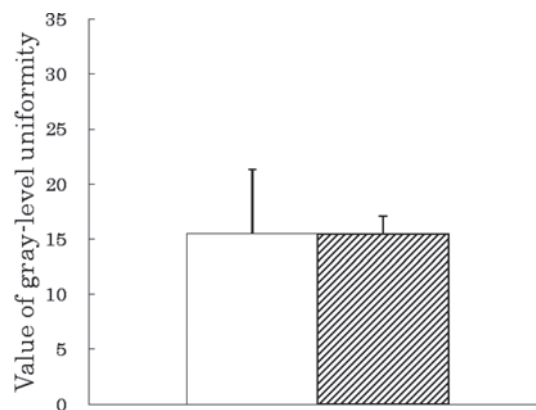


Figure 6. Pixel uniformity in subcutaneous tissue before MLD (open bar) immediately after MLD (shaded bar) in Group B.

Data shown are mean values with standard deviation.

No significantly changes before and immediately after MLD.

Table 3. Edema evaluations before and immediately after MLD

Parameters	Before MLD			After MLD			P
	Mean	±	SD	Mean	±	SD	
Group A (n=10)							
Circumference (cm)	25.8	±	4.5	25.5	±	4.3	0.00*
Skin elasticity							
R0 (mm)	0.17	±	0.07	0.21	±	0.14	0.07
R2	0.77	±	0.12	0.72	±	0.11	0.01*
R7	0.41	±	0.12	0.38	±	0.72	0.07
Skin moisture (g/m <sup>2</sup> h)	49.49	±	18.61	50.94	±	17.96	0.16
Group B (n=5)							
Circumference (cm)	22.0	±	2.0	21.8	±	1.9	0.00*
Skin elasticity							
R0 (mm)	0.17	±	0.02	0.19	±	0.03	0.00*
R2	0.84	±	0.06	0.87	±	0.06	0.27
R7	0.51	±	0.14	0.53	±	0.13	0.19
Skin moisture (g/m <sup>2</sup> h)	31.56	±	2.06	32.37	±	3.19	0.11

n, number of women in test; SD, standard deviation

\* $p < 0.05$ , Paired t test

## References

- 1) Meric F, Buchholz TA, Mirza NQ, et al: Long-term complications associated with breast-conservation surgery and radiotherapy. *Ann Surg Oncol* 9: 543-549, 2002
- 2) Ozaslan C, Kuru B: Lymphedema after treatment of breast cancer. *Am J Surg* 187: 69-72, 2004
- 3) Clark B, Sitzia J, Harlow W: Incidence and risk of arm oedema following treatment for breast cancer; a three-year follow-up study. *Q J Med* 98: 343-348, 2005
- 4) Vignes S: Lipoedema. *Ann Dermatol Venereol* 133: 91-3, 2006
- 5) Kerchner K, Fleischer A, Yosipovitch G: Lower extremity lymphedema update: pathophysiology, diagnosis, and treatment guidelines. *J Am Acad Dermatol* 59: 324-31, 2008
- 6) Rudkin GH, Miller TA: Lipedema: a clinical entity distinct from lymphedema. *Plast Reconstr Surg* 94: 841-7, 1994
- 7) Mortimer PS: Managing lymphedema. *Clin Dermatol* 13(5): 499-505, 1995
- 8) Ko DSC, Lerner R, Klose G: Effective treatment of lymphedema of the extremities. *Arch Surg* 133: 452-8, 1998
- 9) Mani R, Ross JN, Keefe M: Measurements of limb oedema in chronic venous disease. *Skin Res Technol* 1: 51-4, 1995
- 10) Barnes MD, Mani R, Barrett DF, et al: How to measure changes in oedema in patients with chronic venous ulcers? *Phlebology* 7: 31-5, 1992
- 11) Williams AF, Vadgama A, Franks PJ, et al: A randomized controlled crossover study of manual lymphatic drainage therapy in women with breast cancer-related lymphedema. *Eur J Cancer Care (Engl)* 11(4): 254-61, 2002
- 12) McNeely ML, Magee DJ, Lees AW, et al: The addition of manual lymph drainage to compression therapy for breast cancer related lymphedema: a randomized controlled trial. *Breast Cancer Res Treat* 86(2): 95-106, 2004
- 13) Kafelijan-Haddad AP, Janeiro Perez MC, Castiglioni MLV, et al: Lymphoscintigraphic evaluation of manual lymphatic drainage for lower extremity lymphedema. *Lymphology* 39: 41-8, 2006
- 14) Tan IC, Maus EA, Maus JC, et al: Assessment of lymphatic contractile function after manual lymphatic drainage using near-infrared fluorescence imaging. *Arch Phys Med Rehabil* 92(5): 756-64, 2011
- 15) Gniadecka M: Localization of dermal edema in lipodermatosclerosis, lymphedema, and cardiac insufficiency. *J Am Acad Dermatol* 35(1): 37-41, 1996
- 16) Naouri M, Samimi M, Atlan M, et al: High-resolution cutaneous ultrasonography to differentiate lipoedema from lymphedema. *Br J Dermatol* 163: 296-301, 2010
- 17) Balzarini A, Milella M, Civelli E, et al: Ultrasonography of arm edema after axillary dissection for breast cancer: a preliminary study. *Lymphology* 34: 152-5, 2001
- 18) Piller N, Carati C: The diagnosis and treatment of peripheral lymphedema. *Lymphology* 42: 146-147, 2009
- 19) Gniadecka M, Gniadecki R, Serup J, et al: Ultrasound structure and digital image analysis of the subepidermal low echogenic band in aged human skin: diurnal changes and interindividual variability. *J Invest Dermatol* 102(3): 362-365, 1994
- 20) Ueta M, Sugama J, Konya C, et al: Use of ultrasound in assessment of necrotic tissue in pressure ulcers with adjacent undermining. *J Wound Care* 20(11): 1-5, 2011
- 21) Price RR, Axel L, Morgan T, et al: Quality assurance methods and phantoms for magnetic resonance imaging. *Med Phys* 17(2): 287-295, 1990
- 22) Ohshima H, Kinoshita S, Oyobikawa M, et al: Use of Cutometer area parameters in evaluating age-related changes in the skin elasticity of the cheek. *Skin Res*



- Technol 19: 238-242, 2013
- 23) Dobrev H: *In vivo* study of skin mechanical properties in psoriasis vulgaris. Acta Derm Venereol 80: 263-266, 2000
- 24) Mayrovitz HN, Davey S, Shapiro E: Suitability of single tissue dielectric constant measurements to assess local tissue water in normal and lymphedematous skin. Clin Physical Funct Imaging 29: 123-7, 2009
- 25) de Rigal J, Escoffier C, Querleux B, et al: Assessment of aging of the human skin by *in vivo* ultrasonic imaging. J Invest Dermatol 93(5): 621-5, 1989
- 26) Tassenoy A, De Mey J, Stadnik T, et al: Histological findings compared with magnetic resonance and ultrasonographic imaging in irreversible postmastectomy lymphedema: a case study. Lymphat Res Biol 7(3): 145-151, 2009
- 27) Gniadecka M, Jemec G.B.E: Quantitative evaluation of chronological ageing and photoageing *in vivo*: studies on skin echogenicity and thickness. Br J Dermatol 139: 815-821, 1998

## 乳癌術後の上肢リンパ浮腫患者に対するリンパドレナージ前後の皮膚と皮下組織の超音波診断画像による組織間液量変化の定量的評価

臺 美佐子, 片山美豊恵\*, 須釜 淳子\*\*, 大桑麻由美\*\*, 上山 武史\*, 南山 朋子\*, 太田 恵子\*, 井内 映美, 松本 勝, 中谷 壽男\*\*, 真田 弘美\*\*\*

### 要 旨

#### 【背景】

乳癌術後の上肢リンパ浮腫 (BRCL) に対する、標準治療のうち特に徒手リンパドレナージ (MLD) の直前・直後の皮膚と皮下組織の病態変化を定量的に評価することは、浮腫悪化防止、蜂窩織炎予防を目標とした適切なケア継続に重要である。本研究の目的は、MLD前後の皮膚硬さおよび皮膚・皮下組織を超音波診断装置で明らかにすることである。

#### 【方法】

研究デザインは観察研究、解析対象者はBRCL15名、測定部位は前腕内側部とした。MLD前後に皮膚硬さを Visual analog scale(VAS)で評価した。超音波診断装置は、皮膚に対して20MHzで低輝度所見割合 (LEP) を算出し、皮下組織に対して10MHzでPixel uniformityを算出した。臨床指標は周囲径、皮膚粘弾性、真皮水分量を測定した。いずれもMLD前後を比較した。

#### 【結果】

VAS変化により皮膚が柔らかくなった群10名、変わらない群5名であった。両者の基礎情報に統計学的有意差はなかった。超音波診断画像からLEPとPixel uniformityは柔らかくなった群でMLD後が前と比較して統計学的有意に減少した。臨床指標は両群ともに臨床的意義のある差はなかった。

#### 【結論】

BRCLのMLD前後で皮膚が柔らかくなった者の皮膚、皮下組織の組織間液減少がLEPとPixel uniformityより推測された。皮膚硬さが変わらない者は組織間液は変化しなかった。視覚的に観察可能な非侵襲的指標として今後臨床応用が期待できる。一方、皮膚硬さが変わらない者に対するケア継続のための看護援助検討が課題である。